

SonoVue (sulphur hexafluoride microbubbles) – contrast agent for contrast-enhanced ultrasound imaging of the liver

Diagnostics guidance

Published: 29 August 2012

www.nice.org.uk/guidance/dg5

Your responsibility

This guidance represents the view of NICE, arrived at after careful consideration of the evidence available. When exercising their judgement, healthcare professionals are expected to take this guidance fully into account, and specifically any special arrangements relating to the introduction of new interventional procedures. The guidance does not override the individual responsibility of healthcare professionals to make decisions appropriate to the circumstances of the individual patient, in consultation with the patient and/or guardian or carer.

All problems (adverse events) related to a medicine or medical device used for treatment or in a procedure should be reported to the Medicines and Healthcare products Regulatory Agency using the [Yellow Card Scheme](#).

Commissioners and/or providers have a responsibility to implement the guidance, in their local context, in light of their duties to have due regard to the need to eliminate unlawful discrimination, advance equality of opportunity, and foster good relations. Nothing in this guidance should be interpreted in a way that would be inconsistent with compliance with those duties. Providers should ensure that governance structures are in place to review, authorise and monitor the introduction of new devices and procedures.

Commissioners and providers have a responsibility to promote an environmentally sustainable health and care system and should [assess and reduce the environmental impact of implementing NICE recommendations](#) wherever possible.

Contents

1 Recommendations	4
2 The technology	5
3 Clinical need and practice	6
Current practice and the problem addressed	6
4 The diagnostic tests	11
SonoVue	11
Comparator	12
5 Outcomes	13
How outcomes were assessed	13
Clinical effectiveness	14
Economic analysis	17
6 Considerations	26
7 Recommendations for further research	32
8 Implementation	33
9 Diagnostics advisory committee members and NICE project team	34
Diagnostics advisory committee	34
NICE project team	35
Sources of evidence considered by the committee	36

1 Recommendations

- 1.1 Contrast-enhanced ultrasound with SonoVue is recommended for characterising incidentally detected focal liver lesions in adults in whom an unenhanced ultrasound scan is inconclusive. An unenhanced ultrasound scan in which a focal liver lesion is detected, but not characterised, is defined as inconclusive.
- 1.2 Contrast-enhanced ultrasound with SonoVue is recommended for investigating potential liver metastases in adults:
- if contrast-enhanced computed tomography (CT) is not clinically appropriate, is not accessible or is not acceptable to the person, **and**
 - in whom an unenhanced ultrasound scan is unsatisfactory and contrast is needed for further diagnosis.
- 1.3 Contrast-enhanced ultrasound with SonoVue is recommended for characterising focal liver lesions in adults whose cirrhosis is being monitored:
- if contrast-enhanced magnetic resonance imaging (MRI) is not clinically appropriate, is not accessible or is not acceptable to the person, **and**
 - when unenhanced ultrasound scan is inconclusive.

2 The technology

- 2.1 SonoVue (Bracco UK), a pharmaceutical agent for diagnostic use only, is a contrast agent involving sulphur hexafluoride microbubbles. It is indicated for contrast-enhanced ultrasound imaging in adults when unenhanced imaging has been inconclusive. SonoVue has a European marketing authorisation for use in echocardiography, doppler imaging of macrovasculature (for example, cerebral arteries) and of microvasculature (for example, breast and liver lesions). Following input during the scoping phase of the evaluation, this evaluation focuses on the use of SonoVue for liver imaging. Additional details of the clinical condition and the technology are provided in sections 3 and 4 respectively.

3 Clinical need and practice

Current practice and the problem addressed

3.1 Ultrasound scanning, along with other imaging technologies such as CT and MRI, is important in diagnosing and planning treatment for many people with liver disease. Liver imaging sometimes identifies focal abnormalities that cannot be characterised initially and another test may be needed to further explore the abnormality. The main aim of subsequent liver imaging is to distinguish between cancer and benign abnormalities that are not likely to need further treatment. Liver lesions are commonly found at an initial unenhanced ultrasound scan. If the abnormality is not characterised by an unenhanced ultrasound scan, the person is usually referred for either MRI and/or CT. The definition of the term 'inconclusive' in this evaluation is an unenhanced ultrasound scan in which a focal liver lesion is detected but not characterised. The aim of this evaluation was to compare the clinical and cost effectiveness of contrast-enhanced ultrasound using the contrast agent SonoVue with contrast-enhanced CT and contrast-enhanced MRI for investigating and characterising focal liver lesions in adults, in whom previous liver imaging has been inconclusive. Three specific clinical indications were assessed:

- characterising focal liver lesions identified through monitoring of people with cirrhosis
- investigating potential liver metastases in people with colorectal cancer
- characterising incidentally detected focal liver lesions unrelated to the clinical indication for which the imaging was requested.

The condition

Focal liver lesions

3.2 In the context of this evaluation, the term focal liver lesion refers to any focal area

of perceived difference seen on imaging that occurs in 1 specific area of the liver. Focal liver lesions can be broadly classified as benign (for example, haemangioma, focal nodular hyperplasia, focal fatty infiltration or sparing, and adenoma) or malignant (for example, primary hepatocellular carcinoma, cholangiocarcinoma and liver metastases). Identifying or excluding malignancy is the primary aim of diagnostic imaging.

- 3.3 The distinction between benign and malignant lesions helps to determine the prognosis and subsequent treatment strategy. Benign asymptomatic liver lesions, which comprise as many as 70% to 75% of the focal liver lesions assessed in the UK, usually do not need treatment. Depending on the type of lesion, the person may be discharged or their condition may be monitored and the lesion rescanned in 6 to 12 months. If a malignant lesion is identified it is important to distinguish between primary and secondary cancers because this is likely to affect how the condition is managed. Malignant lesions may be treated with a range of interventions, including chemotherapy, surgery and local ablative therapy.

Liver malignancy – epidemiology, incidence and prognosis

- 3.4 There are 2 main types of liver cancer. A cancer that starts in the liver is known as a primary liver cancer and a cancer that spreads to the liver from another part of the body is known as metastatic cancer. Approximately 3,200 people in the UK are diagnosed with primary liver cancer each year, whereas approximately 90,000 people are diagnosed with liver metastases.
- 3.5 Most people with a diagnosis of primary liver cancer (approximately 85%) have a hepatocellular carcinoma. A major risk factor for developing hepatocellular carcinoma is underlying cirrhosis (scarring of liver tissue). Cirrhosis commonly results from alcoholism, hepatitis B and C, and fatty liver disease. Primary liver cancer is the second most rapidly increasing cancer in men and the third in women (increases of 38% and 28% respectively in the past decade).
- 3.6 Primary liver cancer in adults has a poor prognosis because it tends to be diagnosed in the advanced stages. Only a minority of cases of primary liver cancer are diagnosed in the early stages when surgery may help. The prognosis of primary liver cancer depends on the extent of disease and underlying liver

function. About 20% of people with primary liver cancer live for at least 1 year after diagnosis. Around 5% live for at least 5 years.

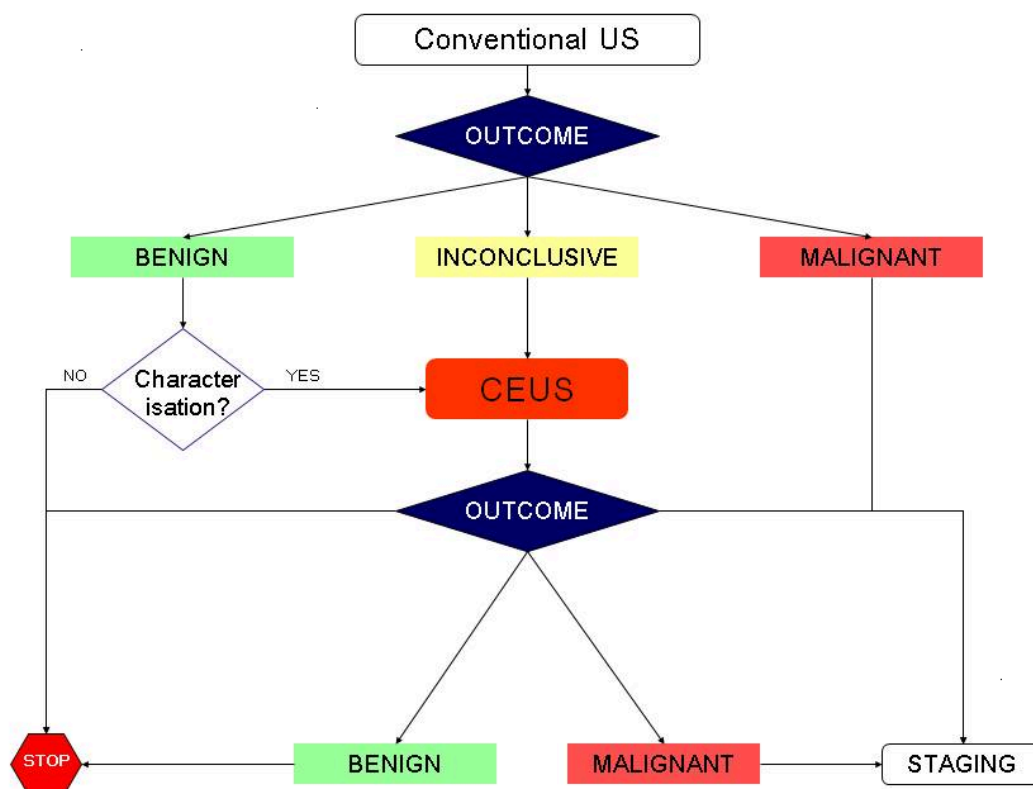
- 3.7 The primary cancers most commonly leading to metastases in the liver originate in the breast, lung and bowel (colorectal). The origin of the primary cancer is important because the cells of the liver metastases are the same as those of the primary cancer, and liver metastases are likely to be treated according to the cell type of the primary cancer. The prognosis of liver metastases depends on the extent of the disease and comorbidities. For example, 40% to 60% of people with stage 4 colorectal cancer with resectable liver metastases will live for 5 years after surgery.

The diagnostic and care pathways

Diagnostic pathway

- 3.8 Contrast-enhanced ultrasound could be included in the diagnostic pathway as a replacement for contrast-enhanced CT/contrast-enhanced MRI (figure 1), or as a triage step to reduce the use of contrast-enhanced CT/contrast-enhanced MRI. The available data only allowed contrast-enhanced ultrasound with SonoVue as a replacement for contrast-enhanced CT/contrast-enhanced MRI to be included in the economic analysis.

Figure 1 Diagnostic pathway for liver imaging with contrast-enhanced ultrasound (CEUS) as a replacement for contrast-enhanced CT/contrast-enhanced MRI



Care pathway

- 3.9 In general, care pathways for people with liver cancer are guided by prognosis. Prognosis depends on both the extent of the tumour and on comorbidity. Improvements in survival as a result of treatment largely depend on the disease stage at diagnosis: the earlier the diagnosis is made, the greater the chance for successful treatment. Detailed care pathways for the 3 indications considered in this assessment can be found in section 3.4 of the diagnostics assessment report.
- 3.10 The European Federation of Societies for Ultrasound in Medicine and Biology (EFSUMB) produced guidelines and good clinical practice recommendations for contrast-enhanced ultrasound in 2004. The latest version was published in 2008 and is currently being updated.
- 3.11 The 2008 EFSUMB guidelines recommend the use of contrast-enhanced ultrasound for the characterisation of focal liver lesions in a range of indications.

The guidelines also provide information on the typical enhancement patterns associated with various types of benign and malignant liver lesions.

- 3.12 The treatment of primary hepatocellular carcinoma has been addressed in published technology appraisals guidance, and NICE has issued interventional procedure guidance on a number of individual interventions for primary hepatocellular carcinoma and liver metastases (see the [NICE website](#) for details). [NICE's guideline on colorectal cancer](#) recommends the use of CT in staging of colorectal cancer, which includes the identification of liver metastases. Expert opinion suggests that there may be significant regional variation within the NHS in the characterisation of focal liver lesions.

4 The diagnostic tests

SonoVue

- 4.1 SonoVue is a second-generation contrast agent that uses sulphur hexafluoride microbubbles for contrast-enhanced ultrasound imaging in adults. SonoVue is a low solubility gas contrast agent that allows imaging at low mechanical index, which leads to effective suppression of the tissue signal. It is used to enhance the echogenicity of the blood and can thus improve the signal to noise ratio in ultrasound. SonoVue has a UK marketing authorisation for diagnostic use only. The summary of product characteristics states that SonoVue improves display of the blood vessels in liver lesions during doppler sonography, allowing more specific characterisation of lesions. The summary of product characteristics also states that SonoVue should only be used in people in whom unenhanced ultrasound is inconclusive.
- 4.2 SonoVue consists of a kit containing a vial of sulphur hexafluoride gas and phospholipid powder, a prefilled syringe of solvent (sodium chloride solution) and a transfer and ventilation system (mini spike). The saline is introduced into the vial by the mini spike delivery system and once reconstituted, microbubbles are formed. These microbubbles are the contrast agent which is injected into a peripheral vein at the antecubital fossa. When the ultrasound probe is placed on the abdomen, ultrasound waves cause the microbubbles to resonate so that a signal is picked up by a transducer and an image is formed on a screen.
- 4.3 SonoVue remains within the blood vessels and, depending on the type of lesion, it shows a pattern of uptake similar to that of contrast agents used for imaging blood vessels in CT or MRI. The contrast agent is broken down by the body after a few minutes. The sulphur hexafluoride gas is exhaled through the lungs and the phospholipid component of the microbubble shell is metabolised (re-entering the endogenous phospholipid metabolic pathway).

Comparator

- 4.4 People with inconclusive unenhanced ultrasound are currently referred for contrast-enhanced CT and/or contrast-enhanced MRI. These are the comparators for this assessment. Contrast-enhanced MRI generally uses gadolinium-based vascular contrast agents. These can differentiate between benign and malignant focal liver lesions by vascular enhancement patterns in a similar way to contrast agents used for contrast-enhanced CT and contrast-enhanced ultrasound. However, contrast-enhanced MRI of the liver can also use hepatocyte-specific contrast agents. These include superparamagnetic iron oxide (SPIO) and gadolinium ethoxybenzyl diethylenetriamine pentaacetic acid (Gd-EOB-DTPA).
- 4.5 Expert opinion indicated that biopsy would not be performed as the next test when unenhanced ultrasound was inconclusive. Therefore, biopsy was not considered a relevant comparator in this assessment.
- 4.6 The comparators used in the model were:
- contrast-enhanced CT
 - contrast-enhanced MRI using gadolinium as the contrast agent
 - contrast-enhanced MRI using SPIO as the contrast agent.

5 Outcomes

- 5.1 The diagnostics advisory committee ([section 10](#)) considered evidence from a number of sources.

How outcomes were assessed

- 5.2 A systematic review of the effectiveness of contrast-enhanced ultrasound using SonoVue compared with contrast-enhanced CT and contrast-enhanced MRI was undertaken by the external assessment group. The outcome measures included:
- the effect of testing on the treatment plan (for example, surgical or medical management, or palliative care)
 - the effect of pre-treatment testing on clinical outcome (for example, overall survival, progression-free survival)
 - prognosis – the ability of the test result to predict clinical outcome (for example, overall survival, progression-free survival, response to treatment)
 - test accuracy and number of people or lesions for which no conclusive diagnostic information could be obtained with contrast-enhanced ultrasound using SonoVue.
- 5.3 Radiation exposure was not considered a relevant outcome because the population is mostly older adults in whom additional incident cancers as a result of imaging are likely to be minimal.
- 5.4 A systematic review of the evidence on cost effectiveness for SonoVue was undertaken by the external assessment group. The external assessment group constructed multiple de novo models. The outcomes of interest for the modelling were costs and the morbidity and mortality associated with the investigation and characterisation of focal liver lesions and their treatment. These included survival and health-related quality of life, including the impact of adverse events associated with treatment (such as chemotherapy).

5.5 Diagnostic technologies themselves do not usually have direct evidence for health-related quality of life, and the de novo models therefore followed a linked evidence approach in which intermediate outcomes (results of the test/s) were linked to the care pathway to estimate clinical outcomes and hence quality-adjusted life year (QALY) gains. Costs and QALYs were assigned to SonoVue and the comparators.

Clinical effectiveness

5.6 A total of 17 studies in 18 publications were included in the assessment. All of the included studies were test accuracy studies:

- 7 concerned the use of contrast-enhanced ultrasound with SonoVue for characterising focal liver lesions identified during routine monitoring of people with cirrhosis
- 4 assessed the performance of contrast-enhanced ultrasound with SonoVue for investigating potential liver metastases in people with known primary cancers (mostly colorectal cancer)
- 6 concerned the use of contrast-enhanced ultrasound with SonoVue for characterising incidentally detected focal liver lesions.

5.7 Only 1 of the studies of test accuracy included in this assessment reported information on adverse events related to testing. In this study there were no adverse events associated with contrast-enhanced ultrasound with SonoVue. There was no information about the comparator (contrast-enhanced MRI with gadolinium). A large, retrospective safety study of contrast-enhanced ultrasound with SonoVue in abdominal imaging did not meet the inclusion criteria for this assessment but reported data from 23,188 investigations in 29 centres in Italy. This study found 29 incidents of adverse events, of which 2 were graded as serious, 1 as severe, 3 as moderate and 23 as mild. There were no fatal adverse events. Most non-serious adverse events resolved without intervention.

5.8 All included studies were published in 2006 or later. Most were conducted in Europe (most in Italy or Spain). Two studies reported funding from the manufacturer of SonoVue.

Results by clinical indication

5.9 Test accuracy data in relation to each clinical indication assessed are summarised below.

Characterising focal liver lesions identified during monitoring of people with cirrhosis

5.10 Studies conducted in people with cirrhosis during routine monitoring all concerned the differentiation of hepatocellular carcinoma from other lesion types in small to medium (less than 30 mm) focal liver lesions. The definition of a positive test for hepatocellular carcinoma varied across studies. Studies assessing contrast-enhanced MRI used 3 contrast agents: gadolinium (a vascular contrast agent), SPIO (a hepatocyte-specific contrast agent) and Gd-EOB-DTPA (a 'combined' vascular and hepatocyte-specific contrast agent). There was no consistent evidence for any significant difference in test performance between the 3 imaging modalities (contrast-enhanced ultrasound, contrast-enhanced CT and contrast-enhanced MRI) and the 3 MRI contrast media assessed. When the definition of hepatocellular carcinoma given in the EFSUMB guidelines (arterial phase enhancement followed by portal-venous washout) was used, estimates of the sensitivity and specificity of each of the imaging modalities varied across studies. There was some evidence, from 1 study comparing contrast-enhanced ultrasound and contrast-enhanced MRI using gadolinium, that these imaging techniques may be better at ruling out hepatocellular carcinoma in focal liver lesions between 11 and 30 mm (sensitivities were 92% and 95% respectively) than in small focal liver lesions 10 mm or less (sensitivities 27% and 73% respectively). However, this study did not use the EFSUMB definition of hepatocellular carcinoma. It is therefore possible that some of the variation in sensitivity estimates in studies of focal liver lesions smaller than 30 mm may be a result of differences in the size distribution of focal liver lesions included. The evidence suggested that contrast-enhanced ultrasound alone may be adequate to rule out hepatocellular carcinoma for focal liver lesions between 11 mm and 30 mm.

Investigating potential liver metastases in people with known primary malignancy

5.11 Studies of the diagnosis of liver metastases using imaging with vascular contrast media (contrast-enhanced ultrasound, contrast-enhanced CT and contrast-enhanced MRI with gadolinium), in which definitions of a positive imaging test were reported, gave various descriptions of peripheral rim enhancement as the criteria for liver metastases. Two studies also reported data for contrast-enhanced MRI with SPIO. There was no evidence of any consistent difference in test performance between the 3 imaging modalities and the different contrast media assessed. Per patient sensitivity estimates, from 2 studies, were generally high: 83% for all imaging modalities and both MRI contrast agents in 1 study of people with colorectal cancer and more than 95% for both contrast-enhanced ultrasound and contrast-enhanced CT in a second study of people with various primary cancers (mostly colorectal cancer). The only previous systematic review of contrast-enhanced ultrasound with SonoVue for the diagnosis of liver metastases did not include any comparator tests and reported sensitivities ranging from 79% to 100%. The limited data available indicate that contrast-enhanced ultrasound alone may be adequate to rule out liver metastases in people with known primary malignancies.

Characterising incidentally detected focal liver lesions

5.12 The primary outcome measure reported by studies conducted in people with incidentally detected focal liver lesions was test accuracy for the differentiation of malignant from benign liver lesions. Studies consistently used definitions of the imaging criteria for hepatocellular carcinoma and liver metastases which were similar to those reported in the EFSUMB guidelines on the use of contrast-enhanced ultrasound. All studies reported no significant difference in the accuracy of contrast-enhanced ultrasound, contrast-enhanced CT and contrast-enhanced MRI for characterising focal liver lesions. The pooled estimates of sensitivity for the detection of 'any liver malignancy' were approximately 95% for both contrast-enhanced ultrasound and contrast-enhanced CT. The pooled estimates of specificity were 94% and 93% respectively, based on data from 4 studies. The single study comparing contrast-enhanced ultrasound with contrast-enhanced MRI used gadolinium for MRI in all people, with the addition of SPIO in

an unspecified number. This study reported sensitivity estimates of 91% and 82% respectively, and corresponding specificity estimates of 67% and 63%. Data from 1 study indicated that combined imaging using both contrast-enhanced ultrasound and contrast-enhanced CT did not increase sensitivity when a positive result on either modality was treated as 'test positive'. This, combined with the high estimates of sensitivity, indicates that contrast-enhanced ultrasound alone may be adequate to rule out liver malignancy in people with incidentally detected focal liver lesions.

Economic analysis

- 5.13 Four studies were identified that met the inclusion criteria for an economic analysis of the use of SonoVue in contrast-enhanced ultrasound.
- 5.14 Although all the studies were of reasonably good quality, they did not fully address the cost effectiveness of SonoVue as defined in this assessment. Limitations included restricted information about disease management and progression, choice of equipment and administrative procedures in different settings, inclusion of costing elements in the calculation, and health outcomes. Zaim et al. (2011) was the only study that modelled disease management and reported health outcomes relevant to this assessment, but the follow-up was only 24 months.
- 5.15 The external assessment group performed a de novo analysis to address specifically the decision problem for this evaluation and to estimate the cost effectiveness of SonoVue in England.
- 5.16 The external assessment group conducted an analysis of contrast-enhanced ultrasound using SonoVue for assessing focal liver lesions in adults, in whom unenhanced ultrasound or other liver imaging has been inconclusive. Three separate models were used for 3 clinical applications for which the most data on test performance were available and experts suggested there was most likely to be clinical benefit:
- cirrhosis surveillance (for characterising focal liver lesions identified through monitoring of people with cirrhosis)

- investigating potential liver metastases in colorectal cancer
- characterising incidentally detected focal liver lesions.

5.17 In each model, contrast-enhanced ultrasound with SonoVue was compared with contrast-enhanced CT, contrast-enhanced MRI using gadolinium and/or contrast-enhanced MRI using SPIO. Average costs, expected life years and expected QALYs per person were calculated for the above technologies.

Costs

5.18 Costs of contrast-enhanced and unenhanced ultrasound were informed by expert clinical opinion and cost information provided the manufacturer of SonoVue. The costs of using the contrast agent, including cannulation, were assumed to be £48.70 (estimate supplied by the manufacturer and agreed by clinicians). In addition, contrast-enhanced ultrasound was expected to take longer than unenhanced ultrasound. Therefore, the external assessment group used the difference between the reference costs of an ultrasound taking less than 20 minutes (£55) and an ultrasound taking more than 20 minutes (£71) as the additional time costs of contrast-enhanced ultrasound. The total additional cost was therefore estimated to be £65. This assumed that contrast-enhanced ultrasound is performed in the same appointment as the unenhanced scan. Costs of the other diagnostic tests were based on 2011 NHS reference costs.

Cost effectiveness

5.19 A model description, test accuracy data and results of the base-case and additional analyses are provided below for each of the 3 models.

Cirrhosis surveillance model

Model description

5.20 The model was a modified version of a model produced by the Peninsula Technology Assessment Group (the PenTAG cirrhosis surveillance model). The population consisted of people with a diagnosis of compensated cirrhosis entering a surveillance programme (aged 70 years or younger with no pre-existing medical conditions that would preclude treatment with liver transplant or hepatic resection [including current alcohol or intravenous drug misuse]). The time horizon was a lifetime and the cycle duration was 1 month. Patients in the model can develop hepatocellular carcinoma. In the base-case analysis monitoring takes place every 6 months, and stops when people reach 70 years.

Test accuracy data used in the model

5.21 It was assumed that the first test used for monitoring was unenhanced ultrasound. The test performance of unenhanced ultrasound used in the model is shown in table 1 and was based on the study by Bennett et al. (2002) as used in the health technology assessment report by Thompson Coon et al. (2007). This study was preferred over other studies because it distinguished between small, medium and large tumours, and had a reasonable sample size (n=200).

Table 1 Test performance of unenhanced ultrasound used in the cirrhosis surveillance model (based on Bennett et al. 2002), with a false-positive rate of 0.04

Tumour size	Sensitivity
Small	0.11
Medium	0.29
Large	0.75

5.22 Additional imaging takes place when unenhanced ultrasound is inconclusive. About 43% of unenhanced ultrasounds were estimated to be inconclusive, based on information provided by the manufacturer of SonoVue. In the base-case analysis, the probability of identifying hepatocellular carcinoma and the proportion of people with a false-positive test result were taken from Leoni et al. (2010). Data from this study were used because diagnostic criteria matched the EFSUMB guidance on the use of contrast-enhanced ultrasound and the performance of contrast-enhanced ultrasound, contrast-enhanced CT and contrast-enhanced MRI with gadolinium was reported in the same population. The study included people with liver lesions between 1 cm and 3 cm. In the base-case analysis the external assessment group used these results to model the diagnostic accuracy for both small (less than 2 cm) and medium (2 cm to 5 cm) tumours (table 2). The sensitivity for identifying large hepatocellular carcinomas was assumed to be 100% for all confirmatory imaging tests, and this assumption was agreed by the clinical experts.

Table 2 Test performance of confirmatory imaging used in the cirrhosis surveillance model (based on Leoni et al. 2010)

Test	Sensitivity for identifying small and medium tumours	False-positive rates
Contrast-enhanced ultrasound	0.67	0.03
Contrast-enhanced CT	0.67	0.03
Contrast-enhanced MRI with gadolinium	0.82	0.01

Base-case cost effectiveness results

5.23 Contrast-enhanced ultrasound had the lowest discounted lifetime costs per person (£35,744), followed by contrast-enhanced CT (£36,124) and contrast-enhanced MRI with gadolinium (£36,807). Compared with contrast-enhanced ultrasound, contrast-enhanced CT was as effective but more costly, and was thus considered to be dominated by contrast-enhanced ultrasound. Contrast-enhanced MRI with gadolinium cost £1,063 more per person than contrast-enhanced ultrasound, but also yielded 0.022 more QALYs, giving an incremental

cost-effectiveness ratio (ICER) of £48,454 per QALY gained. Contrast-enhanced ultrasound is more cost-effective than contrast-enhanced MRI at £20,000 per QALY gained because although less effective it costs less and the ICER for contrast-enhanced MRI compared with contrast-enhanced ultrasound is above this value.

Additional analyses

- 5.24 A range of additional analyses were performed by the external assessment group. Compared with contrast-enhanced MRI with gadolinium (and contrast-enhanced CT), contrast-enhanced ultrasound was the most cost effective option in many of the additional analyses, except when it was assumed that all positive (true and false) unenhanced ultrasound examinations were subject to confirmatory testing instead of only the inconclusive results, and when the proportion of people estimated to have an inconclusive unenhanced ultrasound was considerably lower (20% instead of 43%). These 2 analyses resulted in ICERs for contrast-enhanced MRI with gadolinium compared with contrast-enhanced ultrasound of £12,806 and £16,121 per QALY gained respectively (contrast-enhanced CT was dominated by contrast-enhanced ultrasound in both cases).
- 5.25 In probabilistic sensitivity analysis with over 5,000 replications, at £20,000 per QALY gained the probability that contrast-enhanced ultrasound, contrast-enhanced CT or contrast-enhanced MRI with gadolinium was most cost effective was 99%, 0% and 1% respectively.

Investigating potential liver metastases from colorectal cancer model

Model description

- 5.26 The model was a modified version of the model developed by Brush et al. (2011). The population consisted of people who had previously had surgery for primary colorectal cancer and who, during routine follow-up, were identified as potentially having a metastatic recurrence. The time horizon was a lifetime and the cycle duration was 1 year.

Test accuracy data used in the model

- 5.27 The test performance used in the base case was from Mainenti et al. (2010) because this study compared all 3 alternative tests (contrast-enhanced CT, contrast-enhanced MRI with gadolinium, contrast-enhanced MRI with SPIO) with contrast-enhanced ultrasound (table 3).

Table 3 Test performance of imaging used in the investigation of potential liver metastases model (based on Mainenti et al. 2010)

Test	Sensitivity	Specificity
Contrast-enhanced ultrasound	0.83	0.86
Contrast-enhanced CT	0.83	0.96
Contrast-enhanced MRI with gadolinium	0.83	0.96
Contrast-enhanced MRI with SPIO	0.83	1.00

Base-case cost effectiveness results

- 5.28 In the base-case analysis, using the different imaging techniques to investigate potential liver metastases from colorectal cancer resulted in equal expected lifetime QALYs (8.364). Contrast-enhanced ultrasound and contrast-enhanced CT were the least costly tests, with expected lifetime costs of approximately £7,510 per person. Contrast-enhanced MRI with gadolinium (£7,688) and contrast-enhanced MRI with SPIO (£7,722) were both more costly than, and thus dominated by, contrast-enhanced CT and contrast-enhanced ultrasound. Contrast-enhanced ultrasound and contrast-enhanced CT were cost-effective technologies, with equal expected costs and effectiveness.

Additional analyses

- 5.29 A range of additional analyses were performed by the external assessment group. Analyses that had an impact on the results of the base-case analysis are summarised here. In the base-case analysis it was assumed that people who were incorrectly diagnosed with liver metastases would have a biopsy and the

incorrect diagnosis would be discovered before treatment. If this is not assumed, and people could receive unnecessary treatment, the lower specificity of contrast-enhanced ultrasound had larger consequences. This led to contrast-enhanced ultrasound being both the most costly and the least effective option, and contrast-enhanced MRI with gadolinium dominating all other tests. When alternative sources of test performance were used, from Jones et al. (2011) and Clevert et al. (2009), contrast-enhanced ultrasound was the cost-effective option in both scenarios.

- 5.30 In probabilistic sensitivity analysis with 5,000 replications, at £20,000 per QALY gained contrast-enhanced CT had the highest probability of being cost effective (48%), followed by contrast-enhanced ultrasound (47%), contrast-enhanced MRI with gadolinium (3%) and contrast-enhanced MRI with SPIO (2%).

Characterising incidentally detected focal liver lesions

Model description

- 5.31 People with incidentally detected focal liver lesions can have a variety of conditions, ranging from malignant lesions such as hepatocellular carcinoma and metastases to different types of benign lesions. The prognosis and costs for people diagnosed with hepatocellular carcinoma were modelled using the cirrhosis surveillance model, whereas the prognosis and costs for people with liver metastases were modelled using the liver metastases model. The model took a lifetime time horizon. The costs, life years and QALYs for people with a malignancy other than hepatocellular carcinoma or metastases were assumed to be equal to those in people with hepatocellular carcinoma. However, it was known in advance of the modelling that the costs and QALYs for these people would have a limited effect on the cost effectiveness of contrast-enhanced ultrasound, because its sensitivity was very similar to that of the comparators and the prior probability of other malignancies was small.

Test accuracy data used in the model

- 5.32 The approach used in the base case was to take the results from the meta-

analysis of 4 studies that compared contrast-enhanced ultrasound with contrast-enhanced CT for the differentiation of malignant and benign lesions. Table 4 illustrates the similar performance of the 2 tests.

Table 4 Sensitivity and specificity of contrast-enhanced ultrasound and contrast-enhanced CT for characterising any malignancy in incidentally detected focal liver lesions (pooled estimates from the meta-analysis of 4 studies)

-	Estimate	95% confidence interval (exact method)
Sensitivity of contrast-enhanced ultrasound	95.1%	93.3% to 96.6%
Sensitivity of contrast-enhanced CT	94.6%	92.7% to 96.1%
Specificity of contrast-enhanced ultrasound	93.8%	90.4% to 96.3%
Specificity of contrast-enhanced CT	93.1%	89.6% to 95.8%

5.33 Only 1 study, Seitz (2010), compared the test accuracy of contrast-enhanced ultrasound with MRI (a sensitivity of 77.3% and 63.6% and a specificity of 75.0 and 76.7, respectively, were used in the base case). This study reported that all people in a subgroup had contrast-enhanced MRI with gadolinium, and that a subset of these people also had MRI with a SPIO contrast agent. It was difficult to determine the different accuracies of MRI with the 2 different contrast agents from the study, and therefore sections relating to the use of MRI in the characterisation of incidentally detected focal liver lesions refer to contrast-enhanced MRI overall.

Base-case cost-effectiveness results

5.34 The lower costs of contrast-enhanced ultrasound combined with slightly better test performance meant that contrast-enhanced ultrasound dominated both contrast-enhanced CT (contrast-enhanced ultrasound cost £52 less and yielded 0.0002 additional QALYs) and contrast-enhanced MRI (contrast-enhanced ultrasound cost £131 less and yielded 0.0026 additional QALYs).

Additional analyses

- 5.35 A range of additional analyses were performed by the external assessment group. Although these analyses changed the absolute costs and effectiveness of the different strategies, they did not lead to any significant changes in the incremental costs and effectiveness of contrast-enhanced ultrasound compared with contrast-enhanced CT or contrast-enhanced MRI. The cost of the tests was the most critical factor in the analyses. The impact of other factors (for example, prior probabilities of a particular diagnosis and costs of treatment) was minimal because the accuracy of the tests was so similar.
- 5.36 Probabilistic sensitivity analyses showed that the probability of contrast-enhanced ultrasound being cost effective compared with contrast-enhanced CT and contrast-enhanced MRI was greater than 95% at £20,000 per QALY gained.

6 Considerations

- 6.1 The diagnostics advisory committee reviewed the evidence on the clinical and cost effectiveness of contrast-enhanced ultrasound with SonoVue and noted that the technology was assessed in 3 clinical indications, in adults, when unenhanced ultrasound is inconclusive:
- characterising incidentally detected focal liver unrelated to the clinical indication for which the imaging was requested
 - investigating potential liver metastases in people with colorectal cancer
 - characterising focal liver lesions identified through monitoring of people with cirrhosis.
- 6.2 In general, the committee noted that most of the studies identified in the systematic review of clinical effectiveness were of diagnostic test accuracy and that the quality assessment of these studies, using QUADAS 2, highlighted significant limitations in the data. In particular, there was a 'high' risk of bias rating for the 'patient selection' domain from the use of a retrospective study design or from inappropriate exclusions of particular patient groups (for example, exclusion of people with a low probability of malignancy).
- 6.3 The committee thought that the large retrospective safety study of contrast-enhanced ultrasound with SonoVue in abdominal imaging showed that the safety profile of SonoVue was comparable to, if not better than, contrast-enhanced CT and contrast enhanced MRI.
- 6.4 The committee also considered the impact of the use of gadolinium ethoxybenzyl diethylenetriamine pentaacetic acid (Gd-EOB-DTPA), as a newer 'combined' vascular and hepatocyte-specific contrast agent for MRI. The external assessment group noted that, although most of the evidence for MRI was based on older contrast agents (such as SPIO), a study of people with cirrhosis by Blondin et al. (2011) did not suggest that the accuracy of Gd-EOB-DTPA was significantly different to that of contrast-enhanced ultrasound. Blondin et al. showed that sensitivity estimates were similar and high (more than 90%) for both contrast-enhanced ultrasound and Gd-EOB-DTPA contrast-enhanced MRI.

Specificity appeared lower for contrast-enhanced ultrasound than for Gd-EOB-DTPA contrast-enhanced MRI, but the small number of people with benign lesions in this study resulted in high imprecision in specificity estimates: 50% (95% confidence interval [CI] 42 to 88%) for contrast-enhanced ultrasound and 83% (95% CI 36 to 100%) for Gd-EOB-DTPA contrast-enhanced MRI.

- 6.5 The committee considered contrast-enhanced ultrasound with SonoVue for characterising incidentally detected focal liver lesions and noted that, in liver imaging, this clinical indication would likely be the most common application of the technology. The committee noted that the base-case analysis showed clinically insignificant increases in effectiveness for contrast-enhanced ultrasound compared with contrast-enhanced CT and MRI (incremental QALYs for contrast-enhanced ultrasound compared with contrast-enhanced CT were 0.00016, and for contrast-enhanced ultrasound compared with contrast-enhanced MRI, 0.0026). Moreover, there were cost decreases with contrast-enhanced ultrasound (£52 compared with contrast-enhanced CT, and £131 compared with contrast-enhanced MRI). Thus contrast-enhanced ultrasound with SonoVue dominated the comparators. Probabilistic sensitivity analysis revealed that there was little uncertainty about the cost effectiveness of contrast-enhanced ultrasound compared with the other 2 imaging techniques. Additional analyses did not lead to significant changes in the incremental costs and effectiveness of contrast-enhanced ultrasound compared with contrast-enhanced CT or contrast-enhanced MRI. Therefore, the committee concluded that it could recommend contrast-enhanced ultrasound with SonoVue for characterising incidentally detected focal liver lesions.
- 6.6 The committee considered contrast-enhanced ultrasound with SonoVue for investigating potential liver metastases in people with colorectal cancer and noted that [NICE's guideline on colorectal cancer](#) recommends the use of CT in staging of colorectal cancer, which includes the identification of liver metastases. Therefore, the use of contrast-enhanced ultrasound with SonoVue would only be applicable in a small number of cases (for example, if contrast-enhanced CT is not clinically appropriate, is not accessible, is not acceptable to the person, or is inconclusive). The committee considered the economic analysis performed by the external assessment group and noted that the base-case analysis showed that contrast-enhanced CT was cost effective; however, contrast-enhanced ultrasound with SonoVue generated equal benefits and was only £1 more costly.

The committee considered a range of additional analyses performed by the external assessment group. In the base-case analysis it was assumed that people who were incorrectly diagnosed with liver metastases (false-positives) would receive biopsy and the incorrect diagnosis would be discovered before treatment. If this is not assumed, then people could receive unnecessary treatment and the lower specificity of contrast-enhanced ultrasound resulted in increased costs and reduced effectiveness. Contrast-enhanced MRI with gadolinium dominates all other tests under this assumption. The committee discussed that although the diagnostic pathway varies depending on the clinical scenario, most people would be unlikely to receive unnecessary treatment. This is because the multidisciplinary team would probably seek assurance (from further imaging or a watch and wait strategy) before starting treatment. Direct biopsies of liver metastases may make the metastases inoperable, so they are unlikely to be performed. Therefore, the committee recommended the use of contrast-enhanced ultrasound with SonoVue for investigating potential liver metastases from colorectal cancer, when contrast-enhanced CT is not clinically appropriate, is not accessible or is not acceptable to the person.

- 6.7 The committee considered the applicability of the colorectal cancer analysis to metastases from other primary cancers. It concluded that the data for diagnostic accuracy are equally applicable to liver metastases from other primary cancers (because the liver is being imaged in all cases). Although the treatment of metastases may vary by type of primary cancer, the committee did not consider that this would affect the cost effectiveness of SonoVue sufficiently for it to modify its decision not to limit its recommendations to potential liver metastases from colorectal cancer.
- 6.8 The committee considered contrast-enhanced ultrasound with SonoVue for characterising focal liver lesions identified through monitoring people with cirrhosis. The committee considered the economic analysis performed by the external assessment group and noted that the base-case analysis showed that contrast-enhanced ultrasound with SonoVue was cost effective. The committee felt that the clinical evidence base was weaker for this indication, as noted in the diagnostics assessment report.
- 6.9 The committee considered several circumstances that would result in contrast-enhanced ultrasound being less cost effective. First, the modelling assumed that

all people with diagnoses of hepatocellular carcinoma on characterisation scans, regardless of modality, would have subsequent scans with CT or MRI for treatment planning. The committee heard from experts that although lesions characterised with contrast-enhanced ultrasound would need subsequent CT or MRI scans, focal liver lesions characterised with CT or MRI would not usually need a second scan. The external assessment group determined that the extra scans did not add significantly to the overall cost and would not affect the overall cost effectiveness.

- 6.10 The committee also noted that in the base case, a high proportion of people who had an initial unenhanced ultrasound were assumed to have inconclusive scans (43%, from data supplied by the manufacturer of SonoVue). The committee noted that it was difficult for the external assessment group to ascertain accurate estimates for this parameter in people with cirrhosis because of variation in the definition of 'inconclusive' in the studies and clinical practice. The committee heard from clinical experts that this estimate did not reflect clinical practice and that inconclusive scans normally occur in a much lower proportion of people (10% to 15%) who then need further imaging to characterise their lesion(s). The external assessment group reviewed data submitted by the manufacturer and concluded that the percentage of inconclusive unenhanced scans in people with cirrhosis could not be calculated from these data for a variety of reasons, particularly because the data contained estimates that encompassed both non-diagnostic and diagnostic images, and the use of contrast-enhanced ultrasound rather than unenhanced ultrasound in the studies. The committee concluded that the percentage of inconclusive unenhanced ultrasound scans was likely to be nearer 10% to 15%. At this level, contrast-enhanced MRI with gadolinium was more effective than contrast-enhanced ultrasound and had an ICER of £16,100 per QALY gained. Therefore, contrast-enhanced ultrasound was not a cost-effective option under this circumstance. Contrast-enhanced CT was dominated by contrast-enhanced ultrasound with a 10% to 15% rate of inconclusive scans. Given the uncertainty in the estimate of the prevalence of inconclusive unenhanced ultrasound scans, particularly in people with cirrhosis, and given that the optimal diagnostic strategy depends on this estimate, the committee recommended further research on this issue (see [section 7](#)).
- 6.11 The committee discussed the pressures on MRI departments in the NHS, many of which faced substantially greater demand for MRI than current capacity could

supply. It was thought that, from anecdotal evidence, approximately 5.5% of people who would otherwise have been referred for an MRI scan did not have one, either because it was not available or not clinically appropriate (for example, those with a pacemaker) or because they would not tolerate a scan. The committee recommended the use of contrast-enhanced ultrasound with SonoVue for people who would not or could not receive a contrast-enhanced MRI scan.

- 6.12 The committee also considered whether patient preferences might impact on the selection of imaging modality. Given that contrast-enhanced ultrasound is less expensive than CT or MRI, the small improvements in health-related quality of life arising from CT and particularly MRI might be outweighed by a personal preference for ultrasound over the other modalities. No data on patient preferences were identified by the external assessment group's systematic review. The committee recommended research on patient preferences, and their impact on quality of life, for contrast-enhanced ultrasound and other imaging modalities and whether there are likely differences between contrast-enhanced ultrasound and the other imaging modalities (see [section 7](#)).
- 6.13 The committee discussed the level of training needed to perform a contrast-enhanced ultrasound. It was noted that an appropriate level of operator experience was needed to be able to successfully perform contrast-enhanced ultrasound and that currently there was a shortage in appropriately trained sonographers. The committee concluded that it would be desirable to develop a clinical support framework for sharing and discussing experiences of contrast-enhanced ultrasound. Moreover, NHS departments offering contrast-enhanced ultrasound for liver imaging should review whether they have appropriately trained staff and offer training if necessary by using, for example, the minimum training guidelines provided by the EFSUMB.
- 6.14 The committee noted that the economic analysis was based on the assumption that the contrast-enhanced ultrasound scan would be performed in the same appointment as the unenhanced ultrasound scan. Although alternative scenarios exploring the need to book an additional outpatient appointment (in 50% and 67% of cases) were assessed by the external assessment group, this did not affect the results of the economic analysis. The committee stated that there were significant benefits from having contrast-enhanced ultrasound performed in the same appointment as the unenhanced ultrasound scan, including patient

convenience and the potential for reducing anxiety by ruling out a malignant lesion sooner. Also, savings from reducing the number of appointments are likely. In the committee's view the potential benefit of reducing anxiety by rapidly ruling out malignancy would be a significant advantage compared with the other imaging modalities and is a consequence of being able to perform contrast-enhanced ultrasound during the same appointment. In the committee's view performing contrast-enhanced ultrasound in the same appointment as unenhanced ultrasound was the optimal model of service delivery.

- 6.15 The committee considered possible equality impacts. It noted that although obesity may be a general barrier to the use of ultrasound in some people, its impact on image quality on an individual basis is unpredictable. The committee concluded that the recommendations would be unlikely to disadvantage those with obesity or protected groups.

7 Recommendations for further research

- 7.1 Research is recommended on the percentage of unenhanced ultrasound scans that are inconclusive, particularly in people with cirrhosis. Such studies should explicitly define and describe why scans are 'inconclusive'.
- 7.2 Research is recommended on patient preferences, and their impact on quality of life, for contrast-enhanced ultrasound and other imaging modalities. Ideally such research should compare all appropriate imaging modalities in the same patient group.

8 Implementation

- 8.1 NICE intends to develop tools, in association with relevant stakeholders, to help organisations put this guidance into practice. NICE will also support this guidance with a range of activities to promote the recommendations for further research. This will include incorporating the recommendations for research in [section 7](#) into the [NICE guidance research recommendations database](#) and highlighting these recommendations to public research bodies. The research proposed will also be put forward to NICE's Medical Technologies Evaluation Programme research facilitation team for consideration of the development of specific research protocols.

9 Diagnostics advisory committee members and NICE project team

Diagnostics advisory committee

The diagnostics advisory committee is an independent committee consisting of 22 standing members and additional specialist members. A list of the committee members who participated in this assessment appears below.

Standing committee members

Dr Trevor Cole

Consultant Clinical Geneticist, Birmingham Women's Hospital Foundation Trust

Dr Simon Fleming

Consultant in Clinical Biochemistry and Metabolic Medicine, Royal Cornwall Hospital

Professor Noor Kalsheker

Professor of Clinical Chemistry, Molecular Medical Sciences, University of Nottingham

Dr Mark Kroese

Consultant in Public Health Medicine, PHG Foundation and UK Genetic Testing Network

Professor Adrian Newland (Chair)

Consultant Haematologist, Barts and the London NHS Trust

Dr Richard Nicholas

Consultant Neurologist, Heatherwood and Wexham Park Hospital, Imperial Healthcare Trust

Ms Margaret Ogden

Lay member

Professor Mark Sculpher

Professor of Health Economics, University of York

Professor Ron Akehurst

Professor in Health Economics, School of Health & Related Research (SchARR) University of Sheffield

Dr Steve Thomas

Senior Lecturer and Consultant Radiologist, University of Sheffield

Dr Sue Crawford

General Practitioner (GP) Principal, The Health Centre, Devon

Mr Christopher Wiltsher

Lay member

Specialist committee members

Dr Tim Hoare

Consultant Radiologist with Special Interest in Abdominal Imaging, Newcastle Hospitals NHS Trust

Mrs Gail Coster

Advanced Practitioner Sonographer, Mid Yorkshire Hospitals NHS Trust

Mrs Jane Smith

Consultant Sonographer Practitioner, St James's University Hospital

Dr Kofi Ernest Oppong

Consultant Gastroenterologist, Newcastle Hospitals NHS Trust

Mr Richard Hall

Patient Support Group Manager, British Liver Trust

NICE project team

Each diagnostics assessment is assigned to a team consisting of 1 technical analyst (who acts as the topic lead), a technical adviser and a project manager.

Gurleen Jhuti

Topic Lead

Hanan Bell

Technical Adviser

Jackson Lynn

Project Manager

Sources of evidence considered by the committee

The diagnostics assessment report for this evaluation was prepared by the Kleijnen Systematic Reviews Ltd Assessment Group.

- Westwood M, Joore M, Grutters J. et al. Contrast enhanced ultrasound using SonoVue (sulphur hexafluoride microbubbles), compared with contrast-enhanced computed tomography and contrast-enhanced magnetic resonance imaging, for the characterisation of focal liver lesions and detection of liver metastases: a systematic review and cost-effectiveness analysis. January 2012.

Registered stakeholders

Registered stakeholders were recruited from the following organisations but do not necessarily represent the views of that organisation. They were invited to attend the scoping workshop and to comment on the diagnostics assessment report and the diagnostics consultation document.

Manufacturers/sponsors

Technology under consideration:

- Bracco UK Ltd.

Comparator(s):

- None.

Other:

- GE Healthcare.

Professional/specialist and patient/carer groups

- Royal College of Nursing
- British Medical Ultrasound Society
- Echocardiography Department, Princess Royal University Hospital, London
- Gateshead Health NHS Foundation Trust
- British Liver Trust
- British Society of Gastrointestinal and Abdominal Radiology
- Peterborough City Hospital.

ISBN: 978-1-4731-0912-4