

# Interventional procedure overview of endoscopic ultrasound-guided biliary drainage for biliary obstruction

## Contents

Indications and current treatment.....	2
What the procedure involves.....	3
Outcome measures.....	4
Evidence summary .....	4
Population and studies description.....	4
Procedure technique .....	20
Efficacy.....	20
Safety.....	25
Validity and generalisability .....	31
Existing assessments of this procedure .....	34
Interventional procedures .....	36
NICE guidelines.....	36
Professional societies .....	36
Company engagement.....	37
References.....	37
Methods .....	38
Other relevant studies.....	42

**Table 1 Abbreviations**

<b>Abbreviation</b>	<b>Definition</b>
CI	Confidence interval
DMBO	Distal malignant biliary obstruction
EMBS	Endoscopic metal biliary stent
EORTC	European Organisation for Research and Treatment of Cancer
EPBS	Endoscopic plastic biliary stent
ERCP	Endoscopic retrograde cholangiopancreatography
ESGE	European Society of Gastrointestinal Endoscopy
EUS-AGS	Endoscopic-guided antegrade approach
EUS-BD	Endoscopic ultrasound-guided biliary drainage
EUS-CDS	Endoscopic ultrasound-guided choledochoduodenostomy
EUS-GBD	Endoscopic ultrasound-guided gallbladder drainage
EUS-HGS	Endoscopic ultrasound-guided hepaticogastrostomy
EUS-RV	Endoscopic ultrasound-guided rendezvous technique
HR	Hazard ratio
ITT	Intention to treat
IQR	Interquartile range
LAMS	Lumen-apposing metal stents
OR	Odds ratio
PTBD	Percutaneous transhepatic biliary drainage
RCT	Randomised controlled trial
SD	Standard deviation
SEMS	Self-expandable metal stents

## Indications and current treatment

Biliary obstruction involves blockage of any duct that carries bile from the liver to the gallbladder or from the gallbladder to the small intestine. It may have benign

IP overview: endoscopic ultrasound-guided biliary drainage for biliary obstruction

or malignant causes, and can lead to symptoms including jaundice, nausea and abdominal pain, itching, pale stools and dark urine.

Current standard management of biliary obstruction usually includes stenting using ERCP or PTBD. In the case of malignant obstruction, treatment may also include chemotherapy, biological therapies, photodynamic therapy and radiofrequency ablation.

## **What the procedure involves.**

EUS-BD is used as an alternative procedure when ERCP is not possible; ERCP failure occurs in a small proportion of people because of the nature of the obstruction or the person's anatomy (which may be altered because of disease progression or previous surgery). EUS-BD is also a minimally invasive alternative to PTBD, which is conventionally offered when ERCP has failed. The aim of the procedure is to reduce biliary obstruction and allow the biliary tract to drain.

EUS-BD may be done under conscious sedation or general anaesthesia. It involves inserting an echoendoscope through the mouth and oesophagus into the stomach or duodenum. Using ultrasound guidance, the biliary tract is punctured with a needle. A contrast agent may be injected to enhance imaging.

A guidewire is then passed into the biliary tract at the site of the puncture, which is dilated to create a fistula. Finally, a metal or plastic stent is deployed into the biliary tract to allow for biliary drainage into the stomach or small intestine. Stent delivery systems may also be used to do EUS-BD without needle puncture, dilation or insertion of a guidewire.

EUS-BD can be done using several different techniques and stents deployed via multiple access routes. The 2 most common techniques, EUS-CDS and EUS-HGS, both use a transluminal approach. In EUS-CDS, the extrahepatic bile duct is punctured and stent deployed from the duodenal bulb. In EUS-HGS, the left hepatic duct is punctured and stent deployed via the stomach.

Stents may also be deployed using a transpapillary approach in which the guidewire is passed into the duodenum. In EUS-AGS, the stent is placed across the biliary obstruction. In EUS-RV, the echoendoscope is swapped with an ERCP duodenoscope after placement of the guidewire and a conventional ERCP is done before stent placement. The choice of technique depends on the cause of the biliary obstruction and the anatomy of the person having the procedure.

IP overview: endoscopic ultrasound-guided biliary drainage for biliary obstruction

## Outcome measures

The main efficacy outcomes included technical success and clinical success according to reduction in symptoms or bilirubin levels.

Relief of biliary obstruction can be determined through measuring bilirubin serum levels; in several of the key studies reduction of serum bilirubin by at least 50% was the threshold for clinical success of EUS-BD.

Improvement in quality of life was used as a secondary efficacy outcome in 1 study. It was evaluated using the EORTC QLQ-C30, which measures the physical, psychological and social functions of people with cancer and may be of use for people with malignant biliary obstruction.

Other key measurements include stent patency, survival and improvement in quality of life, and rates of reintervention.

## Evidence summary

### Population and studies description

This overview is based on approximately 2,700 patients from 1 systematic review and meta-analysis, 2 RCTs, 1 non-randomised comparative study, 5 case series and 1 case report. There may be some patient overlap between the studies. This is a rapid review of the literature, and a flow chart of the complete selection process is shown in [figure 1](#). This overview presents 10 studies as the key evidence in [table 2](#) and [table 3](#), and lists 79 other relevant studies in [table 5](#). Due to the large body of evidence for this procedure, studies that met the criteria but had fewer than 50 patients were not included in table 5.

The studies were done in Italy, the UK, Ireland, the US, France, Ecuador, Spain, India, Brazil, South Korea, Germany and Japan. The systematic review was done in the US but locations of included studies were not reported. Of the case series reported, 4 were retrospective and 1 was prospective, and the single non-randomised comparative study included was prospective.

The study from Fugazza (2022) was a multicentre analysis of 256 people with jaundice caused by DMBO who had EUS-CDS after ERCP failure. The case series from On (2022) was a multicentre review of EUS-CDS in 120 consecutive patients with DMBO. An additional case series of 205 patients who had EUS-HGS looked at the procedure specifically in the context of malignant biliary obstruction (Marx 2022a). A case report highlighted an adverse event that

IP overview: endoscopic ultrasound-guided biliary drainage for biliary obstruction

occurred after EUS-HGS in a person with pancreatic adenocarcinoma (Takahashi 2022).

There was 1 RCT of 125 people that compared EUS-BD and ERCP safety and efficacy in people with unresectable malignant distal biliary obstruction (Paik 2018). Another RCT of 56 people, most of whom had malignant biliary obstruction, compared EUS-HGS with PTBD (Marx 2022b). The primary outcome in this study was 30-day morbidity. Randomisation to the PTBD arm was stopped prematurely after 21 people because of a high number of complications.

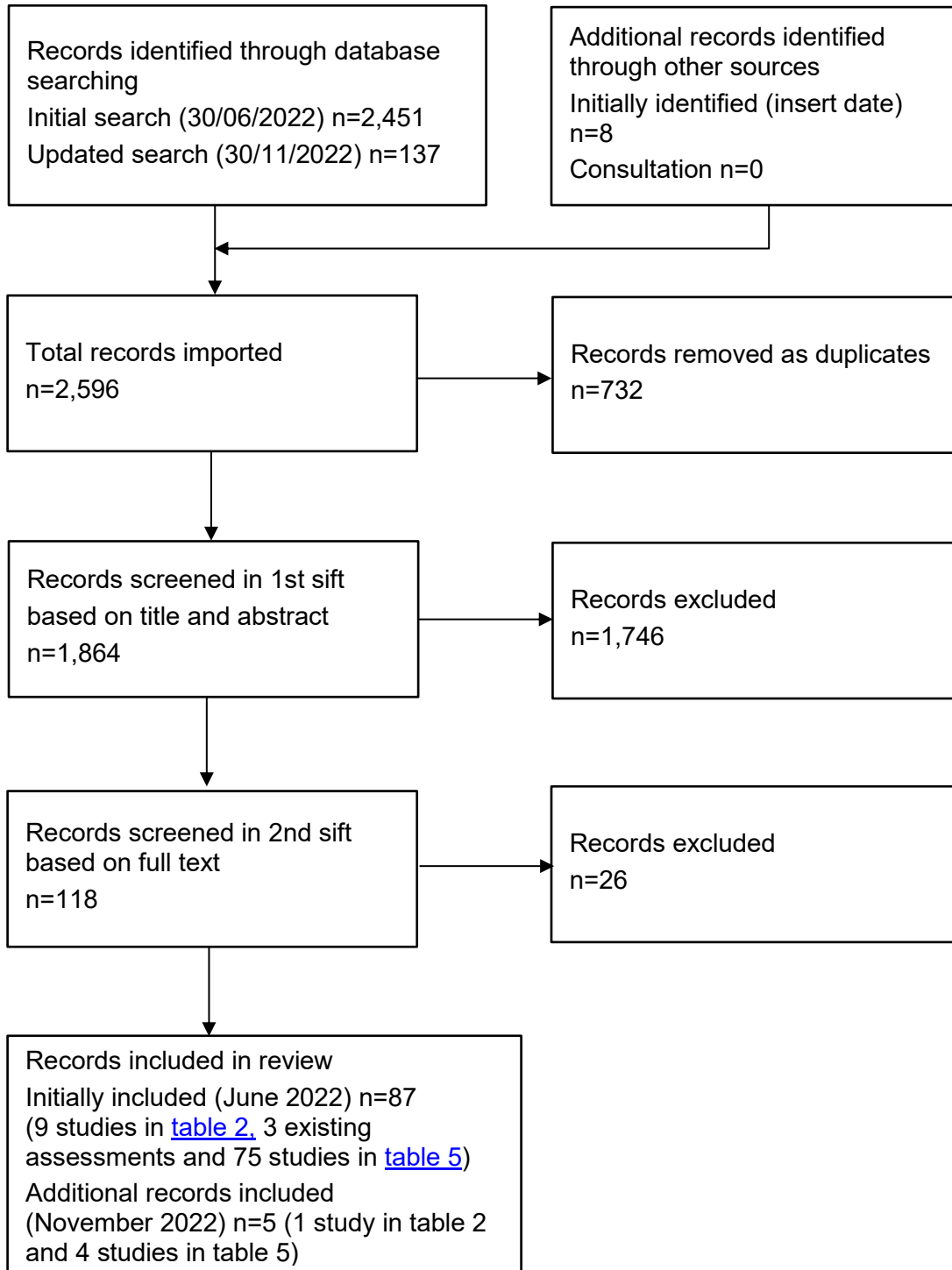
The systematic review from Dhindsa (2022) included 1,437 patients who had EUS-BD across 23 studies and did not exclude studies on the basis of benign or malignant biliary obstruction.

The prospective non-randomised comparative study of 182 people (Tyberg 2022) comparing EUS-CDS and EUS-HGS, which recruited people from the US, Brazil, India, Ecuador, France and Spain, did not specifically exclude cases of benign biliary obstruction. But, in the final analysis 91% (165/182) of included people had malignant biliary obstruction as an indication.

Two studies looked at people with biliary obstruction because of benign causes. The case series of 215 people from Hathorn (2022) was a retrospective single-centre study in the US that compared EUS-guided transhepatic biliary drainage outcomes in populations with benign and malignant causes of biliary obstruction. The case series of 103 people from Fuldner (2021) was a single-centre study that also examined the efficacy and safety of EUS-BD after failed ERCP in people with benign biliary obstruction.

Follow up of all key studies ranged from a median of 70 days to a mean of 257 days; however, study follow up was not reported in the systematic review and meta-analysis or the case report. The mean age of patients ranged from 62.9 years to 73.4 years.

[Table 2](#) presents study details.

**Figure 1 Flow chart of study selection**

IP overview: endoscopic ultrasound-guided biliary drainage for biliary obstruction

**Table 2 Study details**

Study no.	First author, date country	Patients (male: female)	Age (years)	Study design	Inclusion criteria	Intervention	Follow up
1	Dhindsa 2020 (SR+MA done in the US, countries not reported for included studies)	1,437 (774:663)	Mean 67	Systematic review and meta-analysis	Cohort studies looking at EUS-BD with information on adverse events, subcategories of adverse events, technical success rate, and clinical success rate.	EUS-BD (transgastric 29.5%, transduodenal 34.4%, other techniques 19.8%)	Not reported
2	Fugazza 2022 Italy	256 (141:115)	Mean 73.4	Case series	Patients with jaundice caused by DMBO after ERCP failure.	EUS-CDS	Mean 151±162 days
3	On 2022 UK and Ireland	120 (66:54)	Mean 73	Case series	Patients with DMBO.	EUS-CDS	Median 70 days (range 3 to 869)
4	Hathorn 2022 US	215 (101:114) (130 malignant, 85 benign)	Mean 62.9	Case series	Patients who had EUS-guided transhepatic biliary drainage.	EUS-HGS	Mean 257.31 ± 308.11 days (124.53± 229.86 days for benign disease, 457.27 ± 466.31 days for malignant disease)
5	Marx 2022a France	205 (104:101)	Mean 68	Case series	Patients that had EUS-HGS between 2002 and 2018 for	EUS-HGS	Median 6.4 months (95% CI

IP overview: endoscopic ultrasound-guided biliary drainage for biliary obstruction

Study no.	First author, date country	Patients (male: female)	Age (years)	Study design	Inclusion criteria	Intervention	Follow up
					malignant biliary obstruction.		4.1 to 10 months)
6	Tyberg 2022 US, France, Ecuador, Spain, India, Brazil	182 (93:89) (95 EUS-HGS versus 87 EUS-CDS)	Mean 70	Non-randomised comparative study	Patients with biliary obstruction with prior failed ERCP who had EUS-HGS or EUS-CCD; at least 6-month follow-up data or death within 6 months.	EUS-HGS and EUS-CDS	6 months or until death
7	Paik 2018 South Korea	125 (67:58) (64 EUS-BD versus 61 ERCP)	Mean 66.8	RCT	Presence of unresectable malignant distal biliary obstruction (more than 2 cm distal to the hilum) with pathological or radiological diagnosis before endoscopic intervention; over 18 years old; a Karnofsky index of 30% or greater, no serious or uncontrolled coexisting medical illness.	EUS-BD (EUS-CDS 50%, EUS-HGS 50%) and ERCP	Median 155 days (IQR 100 to 234 days)
8	Marx 2022b France	56 (38:18) (35 EUS-HGS, 21 PTBD)	Mean 64 (EUS-HGS), 66 (PTBD)	RCT	Age 18 to 80 years; obstructive jaundice because of a benign or malignant stenosis of the common or left bile duct with impossible retrograde biliary drainage because of	EUS-HGS PTBD	Median 89 days (EUS-HGS)  [the main body of the text states 89 months but

IP overview: endoscopic ultrasound-guided biliary drainage for biliary obstruction



Study no.	First author, date country	Patients (male: female)	Age (years)	Study design	Inclusion criteria	Intervention	Follow up
					failed biliary cannulation or inaccessible papilla.		the table states 89 days]
9	Fuldner 2021 Germany	103	66	Case series	Patients with benign biliary obstruction and previously failed ERCP.	EUS-BD (transgastric 70%, transduodenal 16%, transjejunal 14%)	Not reported
10	Takahashi 2022 Japan	1 (female)	77	Case report	-	EUS-HGS	Not reported

IP overview: endoscopic ultrasound-guided biliary drainage for biliary obstruction

© NICE 2023. All rights reserved. Subject to [Notice of rights](#).

Table 3 Study outcomes

First author, date	Efficacy outcomes	Safety outcomes
Dhindsa, 2020	<ul style="list-style-type: none"> <li>• Pooled rate of technical success: 91.5% (95% CI 87.7% to 94.2%; n = 23 studies; I<sup>2</sup> = 76.5%)</li> <li>• Pooled rate of clinical success: 87% (95% CI 82.3% to 90.6%; n = 21 studies; I<sup>2</sup> = 72.4%)</li> <li>• Pooled rate of reintervention: 6.5% (95% CI 3.8% to 10.8%; n = 19 studies; I<sup>2</sup> = 69.3%)</li> </ul>	<ul style="list-style-type: none"> <li>• Pooled rate of all adverse events: 17.9% (95% CI 14.3% to 22.2%; n=23 studies; I<sup>2</sup> = 69.1%)</li> <li>• Pooled rate of bile leak: 4.1% (95% CI 2.7% to 6.2%; n=23 studies; I<sup>2</sup> = 46.7%)</li> <li>• Pooled rate of bleeding: 3.5% (95% CI 2.3% to 5.3%, n=23 studies; I<sup>2</sup> = 41.8%)</li> <li>• Pooled rate of pneumoperitoneum: 3.3% (95% CI 2.3% to 4.6%; n=23 studies; I<sup>2</sup> = 2%)</li> <li>• Pooled rate of stent migration: 3.9% (95% CI 2.5% to 6.2%; n=22 studies; I<sup>2</sup> = 43.5%)</li> <li>• Pooled rate of infection: 3.8% (95% CI 2.8% to 5.1%; n=22 studies; I<sup>2</sup> = 0%)</li> </ul>
Fugazza, 2022	<p>Technical success of EUS-CDS: 93.3% (239/256)</p> <p>Rate of reintervention (endoscopic or radiologic): 9.2% (22/239)</p> <p><b>Clinical success</b></p> <p>Clinical success (decrease in bilirubin level of at least 50% within 2 weeks of procedure): 96.2% (230/239)</p> <p>Mean percentage decrease in bilirubin levels: 72% (4.11 mg/dl ± 3.96 mg/dl at 2 weeks from baseline 14.7 mg/dl ± 7.11 mg/dl [p&lt;0.001]).</p> <p><b>Death (from underlying disease): 56.1% (134/239)</b></p>	<p><b>Adverse events</b></p> <ul style="list-style-type: none"> <li>• <b>Overall: 27 events, 10.5% of patients (25/239)</b></li> <li>• Bleeding: 1.7% (4/239) – 3 moderate, 1 severe</li> <li>• Stent migration: 0.8% (2/239) – moderate</li> <li>• Infection: 2.1% (5/239) – 3 mild, 1 moderate, 1 severe</li> <li>• Stent occlusion: 6.7% (16/239) – 15 moderate, 1 severe</li> </ul>

IP overview: endoscopic ultrasound-guided biliary drainage for biliary obstruction

First author, date	Efficacy outcomes	Safety outcomes
On, 2022	<p>Technical success of EUS-CDS: 90.8% (109/120) Reintervention: 8.3% (9/109)</p> <p><b>Clinical success</b></p> <p>Clinical success (decrease in bilirubin level of at least 50% within 2 weeks of procedure): 94.8% (92/97).</p> <p>Clinical success could not be determined in 12 patients because of a lack of laboratory values within the stipulated time frame (n=5), loss to follow up (n=3), and death because of underlying disseminated disease (n=4).</p> <p>Serum bilirubin levels: Median serum bilirubin 2 weeks after procedure 76.5 micromoles/litre (range 8 to 352) compared with 222.5 micromoles/litre (range 45 to 687) at baseline (p&lt;0.001).</p>	<p><b>Adverse events</b></p> <p><b>Overall: 17.5% (21/120)</b></p> <p><b>Severe adverse events</b></p> <p>Duodenal perforation: 1.7% (2/120)</p> <p><b>Moderate adverse events</b></p> <p>Stent migration: 1.7% (2/120) Stent occlusion (no cholangitis): 0.8% (1/120) Combined cholangitis and stent occlusion: 5% (6/120) Bile leak: 1.7% (2/120)</p> <p><b>Mild adverse events</b></p> <p>Pneumoperitoneum: 1.7% (2/120) Retroperitoneal air: 0.8% (1/120) Cholangitis (no stent occlusion): 6.6% (5/120)</p>
Hathorn, 2022	<p>Technical success (all patients): 94.9% (204/215) Technical success (malignant patients): 96.9% (126/130) Technical success (benign patients): 91.8% (78/85)</p> <p><b>Clinical success (defined by appropriate reduction in serum bilirubin; exact threshold not reported)</b></p> <p>Clinical success (all patients): 87.3% (89/102)</p>	<p><b>Adverse events</b></p> <p>Overall (all patients): 18.6% (40/215) Overall (benign patients): 22.3% (19/85) Overall (malignant patients): 16.1% (21/130)</p> <p><b>Severe adverse events (more than 7 days spent in hospital post procedure or because of procedure-related readmit, or technical issue resulting in procedural termination or surgery):</b></p>

IP overview: endoscopic ultrasound-guided biliary drainage for biliary obstruction

First author, date	Efficacy outcomes	Safety outcomes
	<p>Clinical success (malignant patients): 86% (63/72) Clinical success (benign patients): 90% (27/30)</p> <p><b>Rate of reintervention</b> In patients with malignant disease in whom at least a 6-month follow up was available, 17.4% (22/126) of patients required reintervention.</p> <p><b>Survival</b></p> <ul style="list-style-type: none"> <li>66 deaths in malignant group due to progressive disease) – mean time to death 142 ± 238 days)</li> <li>8 deaths in benign group (unrelated to procedure)</li> </ul>	<p>Perforation: 0.5% (1/215; benign) Septic shock: 1.9% (4/215; all malignant) Haemodynamic instability: 0.5% (1/215; malignant)</p> <p><b>Moderate adverse events (required additional monitoring and length of stay less than 7 days):</b></p> <p>Moderate abdominal pain (prolonged hospital stay: 0.5% (1/215; benign) Haematemesis (unrelated to stent): 0.5% (1/215; benign) Respiratory distress: 0.5% (1/215; benign) Cholangitis: 2.8% (6/215; benign) Sepsis (secondary to cholangitis): 2.3% (5/215; all malignant) Perihepatic abscess or biloma: 1.3% (3/215; all malignant) Bacteraemia: 0.5% (1/215; malignant) Fungaemia: 0.5% (1/215; malignant) Bile leak: 0.5% (1/215; malignant) Mallory-Weiss tear (triggered by postprocedural nausea and vomiting): 0.5% (1/215; malignant)</p> <p><b>Mild adverse events (no additional hospital monitoring or procedure required)</b></p>

IP overview: endoscopic ultrasound-guided biliary drainage for biliary obstruction

First author, date	Efficacy outcomes	Safety outcomes
		<ul style="list-style-type: none"> <li>• Mild postprocedural pain: 2.3% (5/215; 3 benign, 2 malignant)</li> <li>• Bacteraemia: 1.3% (3/215; all benign)</li> <li>• Biloma (requiring antibiotics): 0.9% (2/215; all benign)</li> <li>• Fever (requiring antibiotics): 0.9% (2/215; 1 benign, 1 malignant)</li> <li>• Minor bleeding: 0.5% (1/215; malignant)</li> </ul>
Marx, 2022a	<p><b>Clinical success</b></p> <p>Proportion of patients with more than 50% decrease in plasma bilirubin 1 month after procedure or improvement in the patient's health condition allowing discharge of the patient: 93% (143/153)</p> <p>(22 patients lost to follow up, 30 patients died before bilirubin data could be collected)</p> <p><b>Survival</b></p> <p>Median survival 5.3 months (95% CI 2.9 to 7.5 months).</p> <p>All mortality within 30 days: 15% (30/205)</p> <p><b>Reintervention</b></p> <ul style="list-style-type: none"> <li>• Recurrent biliary obstruction (requiring reintervention): 36% (47/130)</li> </ul>	<p><b>Procedure-related deaths:</b> 5% (10/205)</p> <p><b>Causes of death:</b></p> <ul style="list-style-type: none"> <li>• Biliary leakage n=1</li> <li>• Severe sepsis n=1</li> <li>• Stent obstruction n=1</li> <li>• Stent migration n=3</li> <li>• Acute kidney injury, n=1</li> <li>• Acute pulmonary oedema, n=1</li> <li>• Combination of minor complications causing progressive deterioration of the patient's health condition leading to death, n=2)</li> </ul> <p><b>Early complications: 46 across 37/205 patients (18%)</b></p> <ul style="list-style-type: none"> <li>• Stent migration: 9.3% (19/205)</li> <li>• Stent occlusion: 3.9% (8/205)</li> </ul>

IP overview: endoscopic ultrasound-guided biliary drainage for biliary obstruction

First author, date	Efficacy outcomes	Safety outcomes
	<ul style="list-style-type: none"> <li>• Mean number of reinterventions per patient for stent revision: 1.7</li> </ul> <p>Stent patency: mean 153±433 days</p>	<ul style="list-style-type: none"> <li>• Cholangitis: 2.4% (5/205)</li> <li>• Bile leakage: 2.9 (6/205)</li> <li>• Pneumoperitoneum: 2.4% (5/205)</li> <li>• Bleeding: 1.5% (3/205)</li> </ul> <p>Late stent migration (more than 30 days after EUS-HGS): 0.7% (1/130)</p>
Tyberg, 2022	<p><b>Technical success</b></p> <p>Technical success EUS-HGS: 92% (87/95)          Technical success EUS-CDS: 92% (80/87)</p> <p><b>Clinical success</b></p> <p>Clinical success (defined as relief of cholangitis, jaundice, and/or pruritus with at least a 30% decrease in pre-treatment bilirubin level within a week after placement or normalisation of bilirubin within 30 days):</p> <ul style="list-style-type: none"> <li>• EUS-HGS: 86% (75/87)</li> <li>• EUS-CDS: 100% (80//80)</li> </ul> <p><b>Stent patency and reintervention</b></p> <ul style="list-style-type: none"> <li>• Rate of re-stenting EUS-HGS: 29% (25/87)</li> <li>• Rate of re-stenting EUS-CDS: 10% (8/80)</li> </ul> <p>p value for difference =0.01</p>	<p><b>Adverse events</b></p> <p>All adverse events EUS-HGS: 21% (20/95)          All adverse events EUS-CDS: 30% (26/87)          (p value for difference=0.17)</p> <p>Biloma: 1% (1/95) EUS-HGS          Cholangitis: 2.1% (2/95) EUS-HGS, 1.1% (1/87) EUS-CDS          Bleeding: 6.3% (6/95) EUS-HGS, 3.4% (3/87) EUS-CDS          Peritonitis: 1% (1/95) EUS-HGS          Perforation: 2.1% (2/95) EUS-HGS, 2.3% (2/87) EUS-CDS          Migration: 1% (1/95) EUS-HGS, 1.1% (1/87) EUS-CDS          Infection: 2.1% (2/95) EUS-HGS, 3.4% (3/87) EUS-CDS</p>

IP overview: endoscopic ultrasound-guided biliary drainage for biliary obstruction

First author, date	Efficacy outcomes	Safety outcomes
	<p>EUS-CDS was 4.5 times more likely than EUS-HGS to achieve longer stent patency (more than 30 days) or manage obstruction. OR 4.5 (95% CI 1.15 to 17.65, p=0.0302)</p> <p><b>Survival</b></p> <ul style="list-style-type: none"> <li>6 months survival (all patients): 42% (77/182)</li> </ul>	<p>Other events (events not specified): 5.3% (5/95) EUS-HGS, 11.5% (10/87) EUS-CDS</p>
Paik 2018	<p><b>Technical success</b></p> <ul style="list-style-type: none"> <li>Technical success all EUS-BD: 93.8% (60/64)</li> <li>Technical success EUS-CDS: 90.6% (29/32)</li> <li>Technical success EUS-HGS 96.9% (31/32)</li> <li>Technical success ERCP: 90.2% (55/61)</li> <li>Difference 3.6% (95% CI -4.4% to 11.6%)</li> </ul> <p>p value for noninferiority between EUS-BD and ERCP = 0.003</p> <ul style="list-style-type: none"> <li>Length of hospital stay ERCP: median 5 days (IQR 4 to 6 days)</li> <li>Length of hospital stay EUS-BD: median 4 days (IQR 3 to 5 days)</li> <li>p value for significance in hospital length of stay = 0.03</li> </ul>	<p><b>Adverse events</b></p> <p>Early adverse events (less than 2 weeks, procedure related): 6.3% (4/64) for EUS-BD, 19.7% (12/61) for ERCP (p=0.03)</p> <p>Late adverse events 4.7% (3/64) for EUS-BD versus 19.7% (12/61) for ERCP (p=0.03)</p> <p>EUS-BD adverse events:</p> <ul style="list-style-type: none"> <li>Self-limited pneumoperitoneum: 3.1% (2/64)</li> <li>Bile peritonitis: 1.6% (1/64)</li> <li>Acute cholangitis: 6.3% (4/64)</li> </ul> <p>ERCP adverse events:</p>

IP overview: endoscopic ultrasound-guided biliary drainage for biliary obstruction

First author, date	Efficacy outcomes	Safety outcomes
	<p><b>Clinical success (defined as reduction in bilirubin to 50% less than pre-treatment levels within 1 week or less than 25% of pre-treatment levels within 4 weeks):</b></p> <ul style="list-style-type: none"> <li>• Clinical success EUS-BD: 90% (54/60)</li> <li>• Clinical success ERCP: 94.5% (52/55)</li> </ul> <p>p value for difference = 0.49</p> <p><b>Rate of reintervention</b></p> <ul style="list-style-type: none"> <li>• Rate of reintervention (EUS-BD, ITT analysis): 15.6% (10/64)</li> <li>• Rate of reintervention (ERCP, ITT analysis): 42.6% (26/61)</li> </ul> <p>p value for difference = 0.001</p> <p><b>Stent patency</b></p> <ul style="list-style-type: none"> <li>• Stent patency EUS-BD (6 months, Kaplan–Meier estimate): 85.1% (n=15)</li> <li>• Stent patency ERCP (6 months, Kaplan–Meier estimate): 48.9% (n=20)</li> </ul> <p>p value for significance = 0.001</p> <ul style="list-style-type: none"> <li>• Mean stent patency time: 208 days for EUS-BD, 165 days for ERCP</li> </ul> <p><b>Survival</b></p>	<ul style="list-style-type: none"> <li>• Acute pancreatitis: 14.8% (9/61)</li> <li>• Acute cholecystitis: 8.2% (5/61)</li> <li>• Acute cholangitis: 9.8% (6/61)</li> <li>• Stent occlusion: 4.9% (3/61)</li> <li>• Stent migration: 1.6% (1/61)</li> </ul>

IP overview: endoscopic ultrasound-guided biliary drainage for biliary obstruction



First author, date	Efficacy outcomes	Safety outcomes
	<ul style="list-style-type: none"> <li>• Deaths due to disease progression, 6 months (ITT analysis): 71.9% (46/64) for EUS-BD, 83.6% (51/61) for ERCP</li> <li>• Median overall survival (Kaplan–Meier estimate): 178 days EUS-BD versus 144 days ERCP, p=0.92</li> </ul> <p><b>Quality of life (12 weeks after procedure, assessed using EORTC QLQ-C30 – scored 1 to 100)</b></p> <ul style="list-style-type: none"> <li>• Change in global functioning score: +4.17 for EUS-BD versus -9.03 ERCP, p=0.001</li> <li>• Change in emotional functioning score: +1.62 for EUS-BD versus -9.72 ERCP, p=0.001</li> <li>• Change in cognitive functioning score: +0.93 for EUS-BD versus -11.11 ERCP, p=0.003</li> <li>• Change in fatigue score: -3.40 for EUS-BD versus +8.02 ERCP, p=0.02</li> <li>• Change in pain score: -17.59 for EUS-BD versus +4.63 ERCP, p=0.01</li> <li>• Change in financial difficulties score: +2.78 for EUS-BD versus 18.52 ERCP, p=0.01</li> </ul>	
Marx 2022b	<b>Technical success</b> (defined as correct bile duct puncture with stent or drain placement confirmed by fluoroscopy)	<b>Morbidity at 30 days</b>

IP overview: endoscopic ultrasound-guided biliary drainage for biliary obstruction

First author, date	Efficacy outcomes	Safety outcomes
	<ul style="list-style-type: none"> <li>• EUS-HGS=94.3% (33/35)</li> <li>• PTBD=100% (20/20), p=0.28</li> </ul> <p><b>Clinical success</b> (more than 50% decrease in plasma bilirubin level after 15 days)</p> <ul style="list-style-type: none"> <li>• EUS-HGS=80.0% (20/25)</li> <li>• PTBD=66.7% (10/15), p=0.35</li> </ul> <p><b>External drain</b> (Percutaneous drain in PTBD group and nasobiliary drain in EUS-HGS group)</p> <ul style="list-style-type: none"> <li>• EUS-HGS=42.9% (15/35)</li> <li>• PTBD=66.7% (14/21)</li> </ul> <p><b>Mean time to drain removal (days)</b></p> <ul style="list-style-type: none"> <li>• EUS-HGS=3 (SD 1.4)</li> <li>• PTBD=10 (SD 8.7), p&lt;0.01</li> </ul> <p><b>Reintervention for recurrent biliary obstruction</b></p> <ul style="list-style-type: none"> <li>• EUS-HGS=37% (10/27)</li> <li>• PTBD=79% (11/14), p=0.02</li> </ul> <p>There was no statistically significant difference in overall survival between the 2 groups (p=0.71).</p>	<ul style="list-style-type: none"> <li>• EUS-HGS=28.6% (10/35), 95% CI 16.4 to 43.6%</li> <li>• PTBD=61.9% (13/21); 95% CI 41.7 to 79.4%</li> </ul> <p><b>Bleeding</b></p> <ul style="list-style-type: none"> <li>• EUS-HGS=8.6% (3/35)</li> <li>• PTBD=23.8% (5/21)</li> </ul> <p><b>Bile leak</b></p> <ul style="list-style-type: none"> <li>• EUS-HGS=0% (0/35)</li> <li>• PTBD=4.8% (1/21)</li> </ul> <p><b>Cholangitis</b></p> <ul style="list-style-type: none"> <li>• EUS-HGS=2.9% (1/35)</li> <li>• PTBD=14.3% (3/21)</li> </ul> <p><b>Peritonitis</b></p> <ul style="list-style-type: none"> <li>• EUS-HGS=2.9% (1/35)</li> <li>• PTBD=4.8% (1/21)</li> </ul> <p><b>Sepsis</b></p> <ul style="list-style-type: none"> <li>• EUS-HGS=20.0% (7/35)</li> <li>• PTBD=28.6% (6/21)</li> </ul> <p><b>Procedure-related mortality</b></p> <ul style="list-style-type: none"> <li>• EUS-HGS=11.4% (4/35)</li> <li>• PTBD=14.3% (3/21)</li> </ul>

IP overview: endoscopic ultrasound-guided biliary drainage for biliary obstruction

First author, date	Efficacy outcomes	Safety outcomes
Fuldner 2021	<p><b>Technical success</b></p> <p>Technical drainage success rate: 96% (99/103)</p> <p>Stent placement rate 86% (85/99)</p> <p>2/103 patients included did not need intervention, 17/103 patients had stone extraction without stent placement</p> <ul style="list-style-type: none"> <li>• Rate of reintervention: 18.8% (19/103)</li> </ul>	<p>Overall complication rate: 25.2% (26/103)</p> <p>Complications:</p> <ul style="list-style-type: none"> <li>• Post-interventional pain: 2% (2/103)</li> <li>• Biloma/liver abscess: 3% (3/103)</li> <li>• Bleeding: 6% (6/103)</li> <li>• Perforation: 1% (1/103)</li> <li>• Bile leakage: 3% (3/103)</li> <li>• Stent dislocation: 11% (11/103)</li> </ul>
Takahashi 2022	None reported.	<p>Patient displayed fever and cognitive dysfunction 73 days after EUS-HGS. Abdominal CE-CT scan showed large infected biloma and liver abscess in the left hepatic lobe, and CT imaging showed brain abscess. Successfully treated with antibiotics and additional stenting, and patient discharged from hospital 48 days after admission.</p> <p>Suspected cause: Bile leakage from puncture tract of the EUS-HGS owing to dysfunction of the HGS stent, and biloma was formed, which then became infected (causing liver and brain abscess).</p>

## Procedure technique

Of the 10 studies included, 9 specified the exact technique used; the systematic review specified the proportion of interventions that were transgastric, transduodenal or used another route, but was not more specific (Dhindsa 2020).

Of the remaining 9 studies, 7 studies used EUS-HGS, and 5 studies used EUS-CDS (3 studies used both techniques). The case series of 103 people used multiple stenting techniques in addition to EUS-HGS and EUS-CDS, which included EUS-RV and antegrade internal drainage (Fuldner 2021).

A variety of plastic and metal stents were used in the key evidence papers, but the most commonly named stents were the HotAXIOS stents (Boston Scientific), and the Hanarostent (MiTech), which were each named in 2 of the 9 studies.

## Efficacy

### Technical success

Technical success was reported in 8 studies. In the systematic review and meta-analysis of 1,437 people, the pooled rate of technical success (defined as successful stent deployment) was 92% (95% CI 87.7% to 94.2%; n=23 studies;  $I^2=76.5%$ ; Dhindsa 2020).

In the case series of 256 people with jaundice caused by DMBO, the rate of technical success (defined as successful stent placement) of EUS-CDS was 93% (239/256; Fugazza 2022).

In the case series of 120 people with DMBO, the technical success rate of EUS-CDS (defined as successful stent placement) was 91% (109/120; On 2022).

In the case series of 215 people, overall technical success rate of transhepatic EUS-BD was 95% (204/215). When split by indication, reported technical

IP overview: endoscopic ultrasound-guided biliary drainage for biliary obstruction

success in malignant patients was 97% (126/130) and technical success in benign patients was 92% (78/85; Hathorn 2022).

In the non-randomised comparative study of 182 people, technical success was 92% for both EUS-CDS (80/87) and EUS-HGS (87/95; Tyberg 2022).

In the RCT of 125 people, technical success of EUS-BD was 94% (60/64) and was comparable to ERCP technical success of 90% (55/61); difference 3.6% (95% CI -4.4% to 11.6%,  $p=0.003$  for noninferiority between procedures; Paik 2018).

In the RCT of 56 people, technical success was 94% (33/35) for EUS-HGS and 100% (20/20) for PTBD ( $p=0.28$ ; Marx 2022b).

In the case series of 103 people with benign biliary obstruction, the technical drainage success rate was 96% (99/103) and stent placement rate was 86% (85/99; Fuldner 2021).

### **Clinical success**

Clinical success, largely defined by reduction in bilirubin serum levels, was reported in 8 studies. In the systematic review and meta-analysis of 1,437 people, the pooled rate of clinical success (defined in most included studies as a reduction in serum total bilirubin by 50% at 1 week or less than 3 mg/dl at 2 weeks after the procedure) was 87% (95% CI 82.3% to 90.6%;  $n=21$  studies;  $I^2=72.4%$ ; Dhindsa 2020).

In the case series of 256 people with jaundice caused by DMBO, the proportion of people with a decrease in bilirubin levels of at least 50% within 2 weeks of EUS-CDS was 96% (230/239). The mean percentage decrease in bilirubin levels decreased by 72% to 4.11 mg/dl  $\pm$  3.96 mg/dl 2 weeks after the procedure from an initial baseline of 14.7 mg/dl  $\pm$  7.11 mg/dl ( $p<0.001$ ; Fugazza 2022).

IP overview: endoscopic ultrasound-guided biliary drainage for biliary obstruction

In the case series of 120 people, decrease in bilirubin levels of at least 50% within 2 weeks of procedure was 95% (92/97). The median serum bilirubin levels 2 weeks after procedure were 76.5 micromoles/litre (range 8 to 352) compared with 222.5 micromoles/litre (range 45 to 687) at baseline ( $p < 0.001$ ; On 2022).

In the case series of 215 people, clinical success (defined by an appropriate reduction in serum bilirubin – exact threshold not reported) was 87% (89/102) across all patients in which this outcome data was available. When split by indication, clinical success in malignant patients was 86% (63/72) and clinical success in benign patients was 90% (27/30; Hathorn 2022).

In the case series of 205 people, the proportion of people with either a decrease of more than 50% in plasma bilirubin 1 month after procedure or sufficient improvement in health for discharge was 93% (143/153) in patients with available data (Marx 2022a).

In the non-randomised comparative study of 182 people, clinical success (defined as relief of cholangitis, jaundice, or pruritus with at least a 30% decrease in pre-treatment bilirubin level within a week of placement or normalisation of bilirubin within 30 days) was 86% (75/87) in EUS-HGS and 100% in EUS-CDS (80/80; Tyberg 2022).

In the RCT of 125 people, clinical success of EUS-BD was 90% (54/60); compared with ERCP which had clinical success of 95% (52/55), there was no statistically significant difference ( $p = 0.49$ ; Paik 2018).

In the RCT of 56 people, clinical success was 80% (20/25) for EUS-HGS and 67% (10/15) for PTBD ( $p = 0.35$ ; Marx 2022b).

## Rate of reintervention

Rates of reintervention were reported in 8 studies. In the systematic review and meta-analysis of 1,437 people, the pooled rate of reintervention was 7% (95% CI 3.8% to 10.8%; n=19 studies;  $I^2=69.3\%$ ; Dhindsa 2020).

The rate of reintervention was 9% (22/239) in the case series of 256 people with DMBO (Fugazza 2022), 8% (9/109) in the case series of 120 people with DMBO (On 2022), and 19% (19/103) in the case series of 103 people with benign biliary obstruction (Fuldner 2021).

In the case series of 215 people, 17% (22/126) of patients with malignant disease with 6-month follow up required reintervention (Hathorn 2022).

In the case series of 205 people, 36% (47/130) of people experienced recurrent biliary obstruction requiring reintervention, with a mean number of 1.7 reinterventions per patient (Marx 2022a).

In the non-randomised comparative study of 182 people, the rate of re-stenting was 29% (25/87) for EUS-HGS and 10% (8/80) for EUS-CDS; this difference in rate of re-intervention between EUS-BD techniques was statistically significant ( $p=0.01$ ; Tyberg 2022).

In the RCT of 125 people, there was a statistically significant lower rate of rate of reintervention for EUS-BD in ITT analysis compared to ERCP (16% [10/64] versus 43% [26/61],  $p=0.001$ ; Paik 2018). There was also a statistically significantly lower rate of reintervention for EUS-HGS (37% [10/27]) compared with PTBD (79% [11/14]) in the RCT of 56 people ( $p=0.02$ ; Marx 2022b).

## Stent patency

Stent patency was reported in 3 studies. In the case series of 205 people, mean stent patency duration was  $153\pm 433$  days (Marx 2022a).

IP overview: endoscopic ultrasound-guided biliary drainage for biliary obstruction

In a non-randomised comparative study of 182 people, EUS-CDS was 4.5 times more likely than EUS-HGS to achieve longer stent patency (more than 30 days) or manage obstruction (OR 4.5 [95% CI 1.15 to 17.65],  $p=0.0302$ ; Tyberg 2022).

In an RCT of 125 people, stent patency at 6 months according to Kaplan–Meier estimation was 85% for EUS-BD and 49% for ERCP, with a statistically significant difference in stent patency between the 2 techniques ( $p=0.001$ ; Paik 2018).

## Survival

Survival and mortality was reported in 4 studies. In the case series of 215 people, 51% (66/130) of people with malignant biliary obstruction died within a mean follow-up period of 457 days because of progressive disease, and 9% (8/85) people with benign disease died during a mean follow up of 125 days due to causes unrelated to the procedure (Hathorn 2022).

In the case series of 205 people with malignant biliary obstruction, the median survival was 5.3 months (95% CI 2.9 to 7.5 months), and 15% (30/205) patients died within 30 days of the procedure (Marx 2022a).

In the non-randomised comparative study of 182 people, 42% (77/182) survived for at least 6 months following the procedure (Tyberg 2022).

In the RCT of 125 people, the median overall survival according to Kaplan–Meier estimation was 178 days for EUS-BD and 144 days for ERCP, with no statistically significant difference between the two ( $p=0.92$ ). In the ITT analysis, the percentage of deaths due to disease progression was 72% (46/64) for EUS-BD and 84% (51/61) in ERCP (Paik 2018).

## Improvement in quality of life

IP overview: endoscopic ultrasound-guided biliary drainage for biliary obstruction



Improvement in quality of life was reported in 1 study. In the RCT of 125 people, quality of life at 12 weeks was assessed using the EORTC QLQ-C30 (scored 1 to 100 for each parameter); there were statistically significant differences between EUS-BD and ERCP in mean change in global functioning (+4.17 EUS-BD versus -9.03 ERCP,  $p=0.001$ ), mean change in emotional functioning (+1.62 EUS-BD versus -9.72 ERCP,  $p=0.001$ ) and mean change in cognitive functioning (+0.93 for EUS-BD versus -11.11 ERCP,  $p=0.003$ ), where higher scores in these domains indicate improved quality of life.

In the same study, there were also statistically significant differences in EORTC QLQ-C30 (scored 1 to 100 for each parameter) between EUS-BD and ERCP in mean change in fatigue score (-3.40 for EUS-BD versus +8.02 ERCP,  $p=0.02$ ), mean change in pain score (-17.59 for EUS-BD versus +4.63 ERCP,  $p=0.01$ ) and mean change in financial difficulties (+2.78 for EUS-BD versus 18.52 ERCP,  $p=0.01$ ), where higher scores in these domains indicate worse symptoms or outcomes (Paik 2018).

## **Safety**

### **Procedural death**

Procedure-related death was reported in 2 studies. In the case series of 205 people with malignant biliary obstruction, 5% (10/205) of people died of procedure-related causes; in 1 person this was due to biliary leakage, in 1 person this was due to severe sepsis, in 1 person this was due to stent obstruction, in 3 people this was due to stent migration, in 1 person this was due to acute kidney injury, in 1 person this was due to acute pulmonary oedema, and in 2 people this was due to a combination of minor complications (Marx 2022a).

Procedure-related mortality was reported in 11% (4/35) of people who had EUS-HGS and 14% (3/21) of people who had PTBD in the RCT of 56 people (Marx 2022b).

IP overview: endoscopic ultrasound-guided biliary drainage for biliary obstruction

## Perforation

Perforation was reported in 4 studies. Duodenal perforation was reported in 2% (2/120) of people in the case series of 120 people (On 2022). Perforation was also reported in 1 person in the case series of 215 people (Hathorn 2022), in 1 person in the case series of 103 people (Fuldner 2021), and in 2% of people in both EUS-HGS (2/95) and EUS-CDS (3/87) in the non-randomised comparative study of 182 people (Tyberg 2022).

## Sepsis

Sepsis was reported in 3 studies. In the case series of 215 people, 2% (5/215) of people had sepsis secondary to cholangitis and 2% (4/215) of people had septic shock (Hathorn 2022). In the case series of 205 people, there was 1 procedural related death from severe sepsis (Marx 2022a). In the RCT of 56 people, sepsis was reported in 20% (7/35) of those who had EUS-HGS and 29% (6/21) of those who had PTBD (Marx 2022b).

## Biloma

Biloma was reported in 3 studies and a case report. The case report outlined the case of a woman with formation of biloma that then became infected, leading to liver and brain abscesses. This was successfully treated with antibiotics and additional stenting (Takahashi 2022).

Biloma or abscess was reported in 2% (5/215) of people in the case series of 215 people (Hathorn 2022), and biloma was reported in 1 person who had EUS-HGS in the non-randomised comparative study of 182 people (Tyberg 2022).

In the case series of 103 people, 3% (3/103) of people had either biloma or a liver abscess (Fuldner 2021).

## Infection

IP overview: endoscopic ultrasound-guided biliary drainage for biliary obstruction

Infection was reported in 4 studies. In the systematic review of 1,437 people, the pooled rate of infection was 4% (95% CI 2.8% to 5.1%,  $I^2 = 0\%$ ; Dhindsa 2020)

Infection was also reported in 2% of people in the in the case series of 256 people (Fugazza 2022), and in the non-randomised comparative study of 182 people, infection was reported in 2% (2/95) of patients who had EUS-HGS and 3% (3/87) of patients who had EUS-CDS (Tyberg 2022).

In the case series of 215 people, bacteraemia was reported in 2% (4/215) of people (3 cases in the benign group and 1 in the malignant group), and fungaemia was reported in 1 person. Fever requiring antibiotics was reported in less than 1% (2/215) of people (Hathorn 2022).

### **Stent migration**

Stent migration was reported in 7 studies. In the systematic review of 1,437 people, the pooled rate of stent migration was 4% (95% CI 2.5% to 6.2%,  $I^2=43.5\%$ ; Dhindsa 2020).

Stent migration was also reported in less than 1% of people (2/239) in the case series of 256 people (Fugazza 2022), in 1 person without combined cholangitis and 5% (6/120) of people with combined cholangitis in the case series of 120 people (On 2022), in 10% (20/205) of people (with 3 subsequent deaths) in the case series of 205 people (Marx 2022a), in 1 person in the RCT of 125 people (Paik 2018) and in 11% (11/103) of people in the case series of 103 people (Fuldner 2021).

Stent migration was reported in 1 person in the EUS-HGS group and 1 person in the EUS-CDS group in the non-randomised comparative study of 182 people (Tyberg 2022).

### **Stent occlusion**

IP overview: endoscopic ultrasound-guided biliary drainage for biliary obstruction

Stent occlusion was reported in 3 studies. Stent occlusion was reported in 7% (16/239) of people in the case series of 256 people (Fugazza 2022), in 6% (7/120, 6 with combined cholangitis, 1 without cholangitis) of people in the case series of 120 people (On 2022), in 4% (8/205) of people in the case series of 205 people (with 1 subsequent death; Marx 2022a).

### **Cholangitis**

Cholangitis without accompanying stent occlusion was reported in 5 studies.

Cholangitis was reported in 7% (5/120) of people in the case series of 120 people (On 2022), 3% (6/215) of people in the case series of 215 people (Hathorn 2022), 2% (5/205) of people in the case series of 205 people (Marx 2022a), and in 6% (4/64) of people in the RCT of 125 people (Paik 2018).

In the non-randomised comparative study of 182 people, cholangitis was reported in 2% (2/95) of people who had EUS-HGS, and in 1% (1/87) of people who had EUS-CDS (Tyberg 2022). In the RCT of 56 people, cholangitis was reported in 3% (1/35) of those who had EUS-HGS and 14% (3/21) of those who had PTBD (Marx 2022b).

### **Bile leak**

Bile leak was reported in 7 studies, including the case report of biloma described above (Takahashi 2022). In the systematic review of 1,437 people, the pooled rate of bile leak was 4% (95% CI 2.7% to 6.2%,  $I^2 = 46.7%$ ; Dhindsa 2020).

Bile leak was also reported in 2% (2/120) of people in the case series of 120 people (On 2022), in 1 person in the case series of 215 people (Hathorn 2022), in 3% (6/205) of people in the case series of 205 people (1 of which led to subsequent death; Marx 2022a) and in 3% (3/103) of people in the case series of 103 people (Fuldner 2021).

IP overview: endoscopic ultrasound-guided biliary drainage for biliary obstruction

In the RCT of 56 people, there were no reports of bile leak in the EUS-HGS group and there was 1 person with bile leak in the PTBD group (Marx 2022b).

## **Bleeding**

Bleeding was reported in 6 studies. In the systematic review of 1,437 people, the pooled rate of bleeding was 4% (95% CI 2.3% to 5.3%,  $I^2 = 41.8%$ ; Dhindsa 2020).

Bleeding was also reported in 2% (4/239) of people in the case series of 256 people (3 moderate cases, 1 severe case; Fugazza 2022), in 1 person in the case series of 215 people (Hathorn 2022), in 2% (3/205) of people in the case series of 205 people (Marx 2022a), and 6% (6/103) of people in the case series of 103 people (Fuldner 2021).

In the non-randomised comparative study of 182 people, bleeding was reported in 6% (6/95) of people who had EUS-HGS and 3% (3/87) of people who had EUS-CDS (Tyberg 2022). In the RCT of 56 people, bleeding was reported in 9% (3/35) of people who had EUS-HGS and 24% (5/21) of people who had PTBD (Marx 2022b).

The case series of 215 people also reported haematemesis in 1 person (Hathorn 2022).

## **Peritonitis**

Peritonitis was reported in 3 studies; in 1 person who had EUS-HGS in the non-randomised comparative study of 182 people (Tyberg 2022), and in 1 person in the RCT of 125 people (Paik 2018). Peritonitis was reported in 1 person who had EUS-HGS and 1 person who had PTBD in the RCT of 56 people (Marx 2022b).

## **Pneumoperitoneum**

IP overview: endoscopic ultrasound-guided biliary drainage for biliary obstruction

Pneumoperitoneum was reported in 4 studies. In the systematic review of 1,437 people, the pooled rate of pneumoperitoneum was 3% (95% CI 2.3% to 4.6%,  $I^2=2%$ ; Dhindsa 2020).

Pneumoperitoneum was also reported in 2% (2/120) of people in the case series of 120 people (On 2022) and in 2% (5/205) of people in the case series of 205 people (Marx 2022a). Self-limited pneumoperitoneum was also reported in 3% (2/64) of people in the RCT of 125 people (Paik 2018).

One person in the case series of 120 people experienced retroperitoneal air as a result of the procedure (On 2022).

### **Pain**

Pain was reported in 2 studies; in 3% (6/215) of people in the case series of 215 people (Hathorn 2022), and 2% (2/103) of people in the case series of 103 people (Fuldner 2021).

### **Other adverse events**

Other adverse events were reported in 2 studies. In the case series of 215 people, 1 person reported haemodynamic instability, 1 person reported respiratory distress and 1 person reported a Mallory-Weiss tear as a result of postprocedural nausea and vomiting (Hathorn 2022).

In the non-randomised comparative study of 182 people the rate of non-specified adverse events was 5% (5/95) in the EUS-HGS group and 12% (10/87) in the EUS-CDS group (Tyberg 2022).

### **Anecdotal and theoretical adverse events**

Expert advice was sought from consultants who have been nominated or ratified by their professional society or royal college. They were asked if they knew of any other adverse events for this procedure that they had heard about

IP overview: endoscopic ultrasound-guided biliary drainage for biliary obstruction

(anecdotal), which were not reported in the literature. They were also asked if they thought there were other adverse events that might possibly occur, even if they have never happened (theoretical).

For this procedure, professional experts did not describe any additional anecdotal or theoretical adverse events.

Four professional expert questionnaires for this procedure were submitted. Find full details of what the professional experts said about the procedure in the [specialist advice questionnaires for this procedure](#).

## **Validity and generalisability**

- The total sample size was large (more than 2,500), with studies conducted across Europe, Asia, North America and South America; a case series of n=120 conducted in the UK and Ireland was included in the key evidence.
- Mean follow-up duration was no longer than 257 days; during follow-up periods there was significant death across multiple studies largely because of progressive malignant disease. The possibility of conducting further studies with longer follow up is limited by survival in malignant disease.
- The population assessed was largely patients with malignant biliary obstruction (for which there were mixed aetiologies), but there were 2 studies that reported outcomes in patients with benign biliary obstructions (Fuldner 2021; Hathorn 2022).
- Quality of life outcomes were only reported in a single study (Paik 2018).
- There was significant variation in the types of stents and techniques used in this procedure.
- There may be a difference in efficacy and safety between EUS-HGS and EUS-CDS but the evidence is limited and non-conclusive.
- The systematic review and meta-analysis reported significant heterogeneity across studies and risk of publication bias (Dhindsa 2020).

IP overview: endoscopic ultrasound-guided biliary drainage for biliary obstruction

- 6 studies reported conflicts of interest (Fugazza 2022, Hathorn 2022, Marx 2022a, Tyberg 2022, On 2022). These conflicts involved editorial responsibility in the publishing journal (Tyberg 2022, Marx 2022b), and consultancy or speaker fees for manufacturers of the devices used in the procedure (Fugazza 2022, Hathorn 2022, Marx 2022a, Tyberg 2022, On 2022)
- Multiple studies (Dhindsa 2020, Fugazza 2022, Hathorn 2022, Marx 2022a) specify that the results may be impacted by the learning curve of the procedure.
- There are numerous ongoing studies relating to the procedure, including those listed below:
  - [EUS-guided Biliary Drainage of First Intent With the Lumen Apposing Metal Stent vs. ERCP in the Management of Malignant Distal Biliary Obstruction](#) (NCT03870386); RCT; Canada; estimated enrolment n=144; study start date March 2019; estimated study completion date March 2023
  - [Comparison of endoscopic ultrasound-guided choledochoduodenostomy and endoscopic retrograde cholangiopancreatography in first-line biliary drainage for malignant distal bile duct obstruction: A multicentre randomised controlled trial](#) (UMIN000041343); RCT; Japan; estimated enrolment 95; study start date September 2020; estimated study completion date October 2022.
  - [EUS-guided Biliary Drainage With EC-LAMS vs ERCP as a Primary Intervention for Endoscopic Treatment of Patients With Distal Malignant Biliary Obstruction](#) (NCT04099862); observational cohort study; Italy; estimated enrolment n=220; study start date February 2021, estimated study completion date December 2022
  - [Multicentre, Randomised and Comparative Study of Lumen-apposing Metal Stents With or Without Coaxial Plastic Stent for Endoscopic Ultrasound-guided Transmural Biliary Drainage](#) (NCT04595058); RCT; Spain;

IP overview: endoscopic ultrasound-guided biliary drainage for biliary obstruction



estimated enrolment n = 60; study start date November 2022; estimated study completion date November 2023.

- [Comparison of Efficacy and Safety of Endoscopic Biliary Drainage and Percutaneous Transhepatic Biliary Drainage for the Management of Perihilar Malignant Biliary Obstruction: a Monocentric Retrospective Study](#) (NCT05078801); observational cohort study; France; estimated enrolment n=100; study start date July 2021; estimated study completion date October 2022
- [Endoscopic Ultrasound-Guided Choledochoduodenostomy Versus Endoscopic Retrograde Cholangiopancreatography for Primary Biliary Decompression in Distal Malignant Biliary Obstruction](#) (NCT04898777); RCT; Egypt; estimated enrolment n=50; study start date July 2021; estimated study completion date January 2023
- [Feasibility of EUS-guided Biliary Drainage With LAMS for the Treatment of Patients With Distal Malignant Biliary Obstruction \(SPAXUS\)](#) (NCT04723199); observational cohort study; Italy; estimated enrolment n=20; study start date December 2020; estimated study completion date December 2021 (results yet to be published)
- [Feasibility and Safety of a Dedicated Biliary Stent for Transmural EUS-guided Hepatico-gastrostomy: the FIT Study](#) (NCT04403893); observational cohort study; Italy; estimated enrolment n=20; study start date June 2020; estimated study completion date December 2021 (results yet to be published)
- [Prospective Multi-site Study of Ultrasound-guided Percutaneous Biliary Drainage and Endoscopic Ultrasound-guided Biliary Drainage With Implantation of a Self-expanding Metal Stent in Patients With Malignant, Distal Bile Duct Obstruction](#) (NCT03546049); RCT; Germany; estimated enrolment n=216; study start date December 2018; estimated study completion date December 2022

IP overview: endoscopic ultrasound-guided biliary drainage for biliary obstruction

- [Efficacy and Safety of Lumen Apposing Metal Stents: a Retrospective Multicentre Study](#) (NCT03903523); observational cohort study; Italy; estimated enrolment n=500; study start date April 2019; estimated study completion date December 2023

## Existing assessments of this procedure

A guideline on the use of therapeutic endoscopic ultrasound-guided procedures was published by the ESGE in 2022 (van der Merwe 2022). The ESGE made the following recommendations regarding EUS-BD:

- ‘ESGE recommends the use of EUS-BD over PTBD after failed ERCP in malignant distal biliary obstruction when local expertise is available’ (strong recommendation, moderate quality evidence).
- ESGE recommends ERCP for primary drainage of malignant distal biliary obstruction, but EUS-guided biliary drainage could also be used in this setting for inoperable patients at high volume expert centres (strong recommendation, moderate quality evidence).
- ESGE suggests EUS-BD with hepaticogastrostomy only for malignant inoperable hilar biliary obstruction with a dilated left hepatic duct when inadequately drained by ERCP and/or PTBD in high volume expert centres (weak recommendation, moderate quality evidence).
- ESGE suggests EUS-BD in malignant post-surgical biliary obstruction and a long biliary limb with dilated intrahepatic bile ducts (weak recommendation, low quality evidence).

IP overview: endoscopic ultrasound-guided biliary drainage for biliary obstruction

- ESGE suggests EUS-BD only after failed enteroscopy-assisted ERCP in the management of benign post-surgical biliary obstruction or common bile duct stones (weak recommendation, low quality evidence).
- ESGE suggests an EUS-guided rendezvous technique after a second failed ERCP in benign biliary disease and normal gastrointestinal anatomy in high volume expert centres (weak recommendation, low quality evidence).

A consensus statement published in 2020 by the Journal of Gastroenterology and Hepatology (Nakai 2020) made the following statement about EUS-BD:

Where expertise is available, EUS-BD may be an option in these situations: (i) failed ERCP, (ii) Post-surgical anatomy and (iii) difficult biliary cannulation (strong recommendation, moderate level of evidence).

An additional consensus statement published in 2018 on the optimal management in interventional EUS procedures (Teoh 2018) made several recommendations relating to EUS-BD, including the following:

- EUS-BD is recommended as the procedure of choice for biliary drainage in patients with failed ERCP if expertise is available (appropriate level of agreement, high level of evidence)
- EUS-BD is an alternative procedure to obtain biliary drainage in patients with altered postoperative anatomy or duodenal stenosis precluding ERCP if expertise is available (appropriate level of agreement, moderate level of evidence)
- In patients with distal common bile duct obstruction, transduodenal and transhepatic approaches for EUS-BD are used (appropriate level of agreement, moderate level of evidence)

IP overview: endoscopic ultrasound-guided biliary drainage for biliary obstruction

- A transhepatic approach to EUS-BD is recommended for hilar blocks (appropriate level of agreement, low level of evidence)
- Multidisciplinary support including interventional radiologist, surgeons and anaesthesiologist to prevent and manage complications is recommended in centres performing EUS-BD (appropriate level of agreement, very low level of evidence)
- Training of EUS-BD should be done at expert centres with facilities and expertise in EUS, ERCP and PTBD (appropriate level of agreement, very low level of evidence)
- Training in EUS-BD should only commence in those endoscopists experienced in EUS-FNA, wire manipulation techniques and biliary stent placement (appropriate level of agreement, very low level of evidence)

## Related NICE guidance

### Interventional procedures

- [NICE interventional procedures guidance on endoscopic bipolar radiofrequency ablation for treating biliary obstruction caused by cancer.](#)  
Recommendation: special arrangements.

### NICE guidelines

- [NICE guideline on diagnosis and management of gallstones.](#)

### Professional societies

- Association of Upper Gastrointestinal Surgeons of Great Britain and Northern Ireland (AUGIS)
- British Society of Gastroenterology

IP overview: endoscopic ultrasound-guided biliary drainage for biliary obstruction

- British Society of Interventional Radiology
- British Association for the Study of the Liver

## Company engagement

NICE asked companies who manufacture a device potentially relevant to this procedure for information on it. NICE received 1 completed submission. This was considered by the IP team and any relevant points have been taken into consideration when preparing this overview.

## References

1. Dhindsa BS, Mashiana HS, Dhaliwal A et al. (2020). EUS-guided biliary drainage: A systematic review and meta-analysis. *Endoscopic Ultrasound* 9(2): 101–9
2. Fugazza A, Fabbri C, Di Mitri R et al. (2022). EUS-guided choledochoduodenostomy for malignant distal biliary obstruction after failed ERCP: a retrospective nationwide analysis. *Gastrointestinal Endoscopy* 95(5): 896-904
3. On W, Paranandi B, Smith AM et al. (2022). EUS-guided choledochoduodenostomy with electrocautery-enhanced lumen-apposing metal stents in patients with malignant distal biliary obstruction: multicentre collaboration from the United Kingdom and Ireland. *Gastrointestinal Endoscopy* 95(3): 432–42
4. Hathorn KE, Canakis A, Baron TH. (2022). EUS-guided transhepatic biliary drainage: a large single-centre U.S. experience. *Gastrointestinal Endoscopy* 95(3): 443–51
5. Marx M, Caillol F, Sfumato P et al. (2022). EUS-guided hepaticogastrostomy in the management of malignant biliary obstruction: Experience and learning curve in a tertiary referral centre. *Digestive and Liver Disease* 54: 1236-42
6. Tyberg A, Napoleon B, Robles-Medranda C et al. (2022). Hepaticogastrostomy versus choledochoduodenostomy: An international multicentre study on their long-term patency. *Endoscopic Ultrasound* 11(1): 38–43
7. Paik WH, Lee TH, Park DH et al. (2018). EUS-guided biliary drainage versus ERCP for the primary palliation of malignant biliary obstruction: a

IP overview: endoscopic ultrasound-guided biliary drainage for biliary obstruction

multicentre randomised clinical trial. *The American Journal of Gastroenterology* 113(7): 987-997

8. Marx M, Caillol F, Autret A et al. (2022) EUS-guided hepaticogastrostomy in patients with obstructive jaundice after failed or impossible endoscopic retrograde drainage: A multicenter, randomized phase II Study. *Endoscopic Ultrasound* 11: 495–502
9. Földner F, Meyer F, Will U. (2021). EUS-guided biliary interventions for benign diseases and unsuccessful ERCP - a prospective unicentre feasibility study on a large consecutive patient cohort. *Zeitschrift für Gastroenterologie* 59(9): 933–43
10. Takahashi, K., Ohyama, H., Nagashima, H. et al. Successful endoscopic treatment of huge infected biloma and hepatic abscess after endoscopic ultrasound-guided hepaticogastrostomy with brain abscess. *Clinical Journal of Gastroenterology*
11. van der Merwe SW, Van Wanrooij RLJ, Bronswijk M et al. (2022). Therapeutic endoscopic ultrasound: European Society of Gastrointestinal Endoscopy (ESGE) Guideline. *Endoscopy* 54(2): 185–205
12. Nakai Y, Isayama H, Wang H et al. (2020). International consensus statements for endoscopic management of distal biliary stricture. *Journal of Gastroenterology and Hepatology* 35(6): 967–79
13. Teoh AYB, Dhir V, Kida M et al. (2018). Consensus guidelines on the optimal management in interventional EUS procedures: results from the Asian EUS group RAND/UCLA expert panel. *Gut* 67(7): 1209–28

## Methods

NICE identified studies and reviews relevant to endoscopic ultrasound-guided biliary drainage for biliary obstruction from the medical literature. The following databases were searched between the date they started to 30 November 2022: MEDLINE, PREMEDLINE, EMBASE, Cochrane Library and other databases. Trial registries and the internet were also searched (see the [literature search strategy](#)). Relevant published studies identified during consultation or resolution that are published after this date may also be considered for inclusion.

The following inclusion criteria were applied to the abstracts identified by the literature search.

IP overview: endoscopic ultrasound-guided biliary drainage for biliary obstruction

- Publication type: clinical studies were included with emphasis on identifying good quality studies. Abstracts were excluded if they did not report clinical outcomes. Reviews, editorials, and laboratory or animal studies, were also excluded and so were conference abstracts, because of the difficulty of appraising study methodology, unless they reported specific adverse events that are not available in the published literature.
- Patients with biliary obstruction.
- Intervention or test: Endoscopic ultrasound-guided biliary drainage.
- Outcome: articles were retrieved if the abstract contained information relevant to the safety, efficacy, or both.

If selection criteria could not be determined from the abstracts the full paper was retrieved.

Potentially relevant studies not included in the main evidence summary are listed in the section on [other relevant studies](#).

Find out more about [how NICE selects the evidence for the committee](#).

**Table 4 literature search strategy**

<b>Databases</b>	<b>Date searched</b>	<b>Version/files</b>
MEDLINE (Ovid)	30/11/2022	1946 to November 29, 2022
MEDLINE In-Process (Ovid)	30/11/2022	1946 to November 29, 2022
MEDLINE Epubs ahead of print (Ovid)	30/11/2022	November 29, 2022
EMBASE (Ovid)	30/11/2022	1974 to 2022 November 29
EMBASE Conference (Ovid)	30/11/2022	1974 to 2022 November 29
Cochrane Database of Systematic Reviews – CDSR (Cochrane Library)	30/11/2022	
Cochrane Central Database of Controlled Trials – CENTRAL (Cochrane Library)	30/11/2022	Issue 11 of 12, November 2022
International HTA database (INAHTA)	30/11/2022	n/a

#### Trial sources searched

- Clinicaltrials.gov
- ISRCTN
- WHO International Clinical Trials Registry

#### Websites searched

- National Institute for Health and Care Excellence (NICE)
- NHS England
- Food and Drug Administration (FDA) - MAUDE database
- Australian Safety and Efficacy Register of New Interventional Procedures – Surgical (ASERNIP – S)
- Australia and New Zealand Horizon Scanning Network (ANZHSN)
- General internet search

The following search strategy was used to identify papers in MEDLINE. A similar strategy was used to identify papers in other databases.

IP overview: endoscopic ultrasound-guided biliary drainage for biliary obstruction



**MEDLINE search strategy**

- 1 Endosonography/
- 2 Endosonography.tw.
- 3 (Endoscop\* adj4 guided adj4 (Ultrasound or Ultrasonic\* or Ultrasonog\* or Echo) adj4 (transluminal or choledochoduodenostomy or hepaticogastrostomy or biliary or rendezvous or antegrade or drain\*)).tw.
- 4 (EUS-BD or EUS-HGS or EUS-CDS).tw.
- 5 (EUS adj4 (transluminal or choledochoduodenostomy or hepaticogastrostomy or biliary or rendezvous or antegrade)).tw.
- 6 ((percutaneous adj4 transhepatic adj4 biliary adj4 drain\*) or ptcd or ptbd).tw.
- 7 or/1-6
- 8 Bile Duct Neoplasms/ or Biliary Tract Neoplasms/
- 9 ((bile or biliary) adj4 (neoplasm\* or cancer\* or tumo?r\* or carcinoma)).tw.
- 10 Cholangiocarcinoma/
- 11 Cholangiocarcinoma.tw.
- 12 Cholestasis/
- 13 Cholestasis.tw.
- 14 Jaundice, Obstructive/
- 15 (jaundice adj4 obstructive).tw.
- 16 (Biliary adj4 stricture).tw.
- 17 or/8-
- 18 drain\*.tw.
- 19 17 and 18
- 20 8 or 10 or 12 or 14
- 21 Drainage/
- 22 20 and 21
- 23 19 or 22
- 24 7 and 23
- 25 (block\* or obstruct\* or stricture or restrict\*).tw.
- 26 24 and 25
- 27 (Hot adj4 AXIOS adj4 stent).tw.
- 28 (GIOBOR adj4 stent).tw. 0
- 29 (HANAROSTENT adj4 biliary).tw. 0
- 30 or/27-29
- 31 26 or 30
- 32 Animals/ not Humans/
- 33 31 not 32

IP overview: endoscopic ultrasound-guided biliary drainage for biliary obstruction

## Other relevant studies

Other potentially relevant studies to the IP overview that were not included in the main evidence summary (tables 2 and 3) are listed in table 5.

Due to the large body of available evidence, studies with fewer than 50 patients have not been included in the appendix.

**Table 5 additional studies identified**

Article	Number of patients and follow up	Direction of conclusions	Reason study was not included in main evidence summary
Amato A, Sinagra E, Celsa C et al. (2021). Efficacy of lumen-apposing metal stents or self-expandable metal stents for endoscopic ultrasound-guided choledochoduodenostomy : a systematic review and meta-analysis. <i>Endoscopy</i> 53(10): 1037–47	Systematic review and meta-analysis n=820 EUS-CDS	This meta-analysis showed that LAMS and SEMS are comparable in terms of efficacy for EUS-CDS. Clinical and technical success, post-procedure adverse events, and reintervention rates were similar between LAMS and SEMS use; however, adverse events require further investigation.	Larger systematic review (Dhindsa 2020) already included.
Bang JY, Navaneethan U, Hasan M et al. (2018). Stent placement by EUS or ERCP for primary biliary decompression in pancreatic cancer: a randomised trial (with videos). <i>Gastrointestinal Endoscopy</i> 88(1):18-20	RCT n=67 (33 EUS-BD versus 34 ERCP) Follow up: until death or minimum 6 months (median 190 days)	Given the similar rates of adverse events and treatment outcomes in this randomised trial, EUS-BD is a practical alternative to ERCP for primary biliary decompression in pancreatic cancer.	Studies with more people or longer follow up are included.
Baniya R, Upadhaya S, Madala S et al. (2017). Endoscopic ultrasound-guided biliary drainage versus percutaneous transhepatic biliary drainage after failed	Systematic review and meta-analysis n=312 (6 studies; 161 EBGD versus 151 PTBD)	Technical (OR 0.34, CI 0.10 to 1.14, p=0.05) and clinical (OR 1.48, CI 0.46 to 4.79, p=0.51) success rates were not statistically significant between the EUS-BD and PTBD groups. Mild adverse	Larger systematic review already included.

IP overview: endoscopic ultrasound-guided biliary drainage for biliary obstruction

endoscopic retrograde cholangiopancreatography : a meta-analysis. <i>Clinical and Experimental Gastroenterology</i> 10: 67–74		events were not significantly different (OR 0.36, CI 0.10 to 1.24, $p=0.11$ ) but not the moderate-to-severe adverse events (OR 0.16, CI 0.08 to 0.32, $p\leq 0.00001$ ) and total adverse events (OR 0.34, CI 0.20 to 0.59, $p\leq 0.0001$ ). EUS-BD is equally effective but safer than PTBD.	
Bapaye A, Dubale N, Aher A. (2013). Comparison of endosonography-guided vs. percutaneous biliary stenting when papilla is inaccessible for ERCP. <i>United European Gastroenterology Journal</i> 1(4): 285–93	Non-randomised comparative study  n=50 (25 EUS-BD versus 25 PTBD)	In this retrospective study comparing success and complications of EUS-BD and PTBD in patients with inoperable malignant biliary obstruction and inaccessible papilla, EUS-BD was found superior to PTBD for both comparators.	Studies with more people or longer follow up are included.
de Benito Sanz M, Nájera-Muñoz R, de la Serna-Higuera C et al. (2021). Lumen apposing metal stents versus tubular self-expandable metal stents for endoscopic ultrasound-guided choledochoduodenostomy in malignant biliary obstruction. <i>Surgical Endoscopy</i> 35(12): 6754–62	Non-randomised comparative study  n=57 (37 LAMS versus 20 SEMs)  Follow up: mean 376 ±145 days	EUS-guided choledochoduodenostomy after failed ERCP has equally high technical and clinical success rates with either LAMS or SEMs in patients with malignant biliary obstruction. No differences in adverse events, reinterventions and survival were seen with either type of stent.	Studies with more people or longer follow up are included.
Bill JG, Darcy M, Fujii-Lau LL et al. (2016). A comparison between endoscopic ultrasound-guided rendezvous and percutaneous biliary drainage after failed ERCP for malignant distal biliary obstruction. <i>Endoscopy International Open</i> 4(9): e980–5	Non-randomised comparative study  n=50 (25 rendezvous EUS-BD versus 25 PTBD)  Follow up: median 37 days for EUS-BD, median 11 days PTBD	Initial technical success with EUS-RV was significantly lower than with PTBD, however when EUS-RV was successful, patients had a significantly shorter post-procedure hospital stay and required fewer follow-up biliary interventions.	Studies with more people or longer follow up are included.

IP overview: endoscopic ultrasound-guided biliary drainage for biliary obstruction

<p>Bill JG, Ryou M, Hathorn KE et al. (2022). Endoscopic ultrasound-guided biliary drainage in benign biliary pathology with normal foregut anatomy: a multicentre study. <i>Surgical Endoscopy</i> 36(2): 1362–8</p>	<p>Non-randomised comparative study</p> <p>n=86 (36 rendezvous EUS-BD versus 50 ERCP)</p> <p>Follow up: not reported</p>	<p>EUS-BD remains a viable therapeutic option in the setting of benign biliary disease, with success rates of 78%. Adverse events were significantly more common with EUS-BD versus repeat ERCP, emphasising the need to perform in expert centres with appropriate multidisciplinary support and to strongly consider the urgency of biliary decompression before considering same session EUS-BD after failed initial biliary access.</p>	<p>Studies with more people or longer follow up are included.</p>
<p>Bishay K, Boyne D, Yaghoobi M et al. (2019). Endoscopic ultrasound-guided transmural approach versus ERCP-guided transpapillary approach for primary decompression of malignant biliary obstruction: a meta-analysis. <i>Endoscopy</i> 51(10): 950-60</p>	<p>Meta-analysis</p> <p>n=396 (5 studies; 147 EUS-BD versus 249 ERCP)</p> <p>Follow up: median 95 to 298 days</p>	<p>EUS-BD had similar clinical success rates and occlusion rates to ERCP in the primary decompression of malignant biliary obstruction from meta-analysis including a modest number of patients. EUS-BD may be a practical alternative to the ERCP-guided approach in such patients, but further well-designed prospective studies with larger numbers of patients are required to more clearly delineate potential differences in adverse events and cost.</p>	<p>Larger meta-analysis already included.</p>
<p>Boonmee C, Summart U, Tantraworasin A et al. (2021). Mortality rates of EUS-guided biliary drainage (EUS-BD) in malignant biliary obstruction patients in EUS-BD era versus non-EUS-BD era: A retrospective cohort study. <i>Journal of Clinical and Diagnostic Research</i> 15(3): 4–7</p>	<p>Non-randomised comparative study</p> <p>n=124 (30 EUS-BD versus 94 ERCP)</p> <p>Follow up: median 7.12 months EUS-BD, median 2.43 months non-EUS-BD</p>	<p>From the present study it can be concluded that EUS-BD in people with malignant biliary obstruction achieves lower mortality rate at 1 year follow up. For conclusive findings of the benefit of EUS-BD, a prospective long-term study with larger numbers of subjects should be done.</p>	<p>Studies with more people or longer follow up are included.</p>

IP overview: endoscopic ultrasound-guided biliary drainage for biliary obstruction

Chin JY-L, Seleg S, Weilert F. (2020). Safety and outcomes of endoscopic ultrasound-guided drainage for malignant biliary obstruction using cautery-enabled lumen-apposing metal stent. <i>Endoscopy International Open</i> 8(11): e1633–8	Case series  n=60 (56 EUS-CDS, 4 gallbladder drainage)  Follow up: mean 7.9 months	EUS-CDS and EUS-GBD using ECE-LAMS are effective EUS-based techniques for managing patients with malignant biliary obstruction. Adverse events are usually mild and resolved by reintervention.	Mixed interventions for which results are not reported separately.
Cho DH, Lee SS, Oh D et al. (2017). Long-term outcomes of a newly developed hybrid metal stent for EUS-guided biliary drainage (with videos). <i>Gastrointestinal Endoscopy</i> 85(5): 1067–75	Case series  n=54 (21 EUS-HGS and 33 EUS-CDS)  Follow up: median 148.5 days	EUS-BD with the hybrid metal stent is technically feasible and can effectively treat biliary obstruction after failed ERCP. EUS-BD with the hybrid metal stent can reduce stent-related adverse events, especially stent migration.	Studies with more people or longer follow up are included.
Cho JH, Park SW, Kim EJ et al. (2022) Long-term outcomes and predictors of adverse events of EUS-guided hepatico-gastrostomy for malignant biliary obstruction: Multicenter, retrospective study. <i>Surgical Endoscopy</i> 36: 8950-8958	Retrospective cohort study  n=120	The technical and clinical success rates were 96% (102/106) and 83% (88/106). The median duration of stent patency was longer in SEMS compared to plastic stents (158 versus 108 days). Kaplan–Meier analysis indicated that the type of stent was not associated with stent patency (HR 0.997, 95% CI 0.53 to 1.90) or overall survival. In addition, multivariate analysis indicated that hilar malignant biliary obstruction was significantly associated with stent dysfunction (HR 2.34; 95% CI 1.03 to 5.3, p=0.043) and late adverse events.	Studies with more patients or longer follow up are included.
Chow HS, Chan JCY, Cheung WH et al. (2022) A comparison between endoscopic ultrasound-guided and percutaneous biliary drainage after failed endoscopic retrograde	Retrospective cohort study  n=86  Follow up: mean 93 days (EUS-BD)	The clinical success rates for EUS-BD and PTBD were 96% (25/26) and 72% (43/60) respectively (p=0.01). The technical success rates were 96% (25/26) and 95% (57/60) respectively (p>0.99). Among	Studies with more people or longer follow up are included.

IP overview: endoscopic ultrasound-guided biliary drainage for biliary obstruction

<p>cholangiopancreatography for malignant biliary obstruction: A retrospective cohort study. Surgical Practice DOI: 10.1111/1744-1633.12586</p>		<p>those technically successful cases, complications were significantly fewer in the EUS-BD group (4%) than in the PTBD group (33%). There were statistically significantly fewer reinterventions, shorter length of hospitalisation and fewer in-hospital deaths in the EUS-BD group. No statistically significant difference in stent/PTBD patency was noted between the 2 groups.</p>	
<p>Dhir V, Artifon EL, Gupta K et al. (2014). Multicentre study on endoscopic ultrasound-guided expandable biliary metal stent placement: choice of access route, direction of stent insertion, and drainage route. Digestive Endoscopy: Official Journal of the Japan Gastroenterological Endoscopy Society 26(3): 430–5</p>	<p>Non-randomised comparative study  n=68 (34 transhepatic EUS-BD versus 31 transduodenal EUS-BD) Follow up: minimum 3 months</p>	<p>EUS-BD can be done with high success rates regardless of the choice of access route, stent direction or drainage route. However, complications are significantly higher with transhepatic access. The transduodenal route should be chosen for EUS-guided and rendezvous stent placements, when both routes are available.</p>	<p>Studies with more people or longer follow up are included.</p>
<p>Dhir V, Bhandari S, Bapat M et al. (2012). Comparison of EUS-guided rendezvous and precut papillotomy techniques for biliary access (with videos). Gastrointestinal Endoscopy 75:360-1</p>	<p>Non-randomised comparative study  n=202 (58 EUS-BD versus 144 precut papillotomy)  Follow up: minimum 3 months</p>	<p>In this study, the EUS-guided rendezvous technique was found to be superior to precut papillotomy for single-session biliary access. Prospective randomised trials are needed to confirm these preliminary but promising findings.</p>	<p>More recent studies included.  Study included in Dhindsa (2020) systematic review.</p>
<p>El Chafic AH, Shah JN, Hamerski C et al. (2019). EUS-guided choledochoduodenostomy for distal malignant biliary obstruction using electrocautery-enhanced</p>	<p>Case series  n=57 EUS-CDS</p>	<p>EUS-CD using LAMS with cautery-enhanced delivery systems has high technical and clinical success rates, with a low rate of adverse events. Inserting an axis-orienting stent through the</p>	<p>Studies with more people or longer follow up are included.</p>

IP overview: endoscopic ultrasound-guided biliary drainage for biliary obstruction

lumen-apposing metal stents: first US, multicentre experience. <i>Digestive Diseases and Sciences</i> 64(11): 3321–7		lumen of the LAMS may reduce the need for biliary reinterventions.	
Fabbri C, Luigiano C, Lisotti A et al. (2014). Endoscopic ultrasound-guided treatments: Are we getting evidence based - a systematic review. <i>World Journal of Gastroenterology</i> 20(26): 8424–48	Systematic review n=312 studies	Several EUS-guided treatments are now available in the endosonographer's armamentarium. The usefulness of EUS-guided drainage of pancreatic fluid collections and of EUS- celiac plexus neurolysis has been well established in studies with high levels of evidence. Other techniques including EUS-guided biliary drainage have been tested only in studies with medium-low levels of evidence and thus should still be done either in referral centres by experienced endosonographers or in investigational/research settings. Well-designed RCTs are warranted to further elucidate the safety and benefits of EUS-guided treatments in comparison to the standards of care.	Mixed interventions.  No meta-analysis.
Fábián A, Bor R, Gede N et al. (2020). Double stenting for malignant biliary and duodenal obstruction: a Systematic review and meta-analysis. <i>Clinical and Translational Gastroenterology</i> 11(4): e00161	Systematic review  n=80 studies	Substantially high technical and clinical success can be achieved with double stenting. Based on the adverse-event profile, ERCP can be recommended as the first choice for biliary stenting as part of double stenting, if feasible. Prospective comparative studies with well-defined outcomes and cohorts are needed.	Study focuses on stenting technique.  Mixed indications.
Facciorusso A, Mangiavillano B, Paduano D et al. (2022). Methods for drainage of distal	Systematic review and network meta-analysis	In conclusion, all interventions seem to be effective for the drainage of DMBO, although PTBD	Larger systematic review (Dhindsa

IP overview: endoscopic ultrasound-guided biliary drainage for biliary obstruction

malignant biliary obstruction after ERCP failure: a systematic review and network meta-analysis. <i>Cancers</i> 14(13): 3291	n=217 (5 studies; 84 EUS-CDS versus 73 EUS-HGS versus 44 PBDT versus 16 surgical hepaticojejunostomy)	showed a trend towards higher rates of adverse events.	2020) already included.
Ginestet C, Sanglier F, Hummel V et al. (2022). EUS-guided biliary drainage with electrocautery-enhanced lumen-apposing metal stent placement should replace PTBD after ERCP failure in patients with distal tumoural biliary obstruction: a large real-life study. <i>Surgical Endoscopy</i> 36(5): 3365–73	Non-randomised comparative study  n=95 (50 EUS-BD versus 45 PTBD)  Follow up: 1 month	Our results are in favour of EUS-BD using electrocautery-enhanced lumen-apposing metal stent in case of ERCP failure for a distal tumour biliary obstruction. Operators performing ERCP for distal tumour biliary obstruction must learn this backup procedure because of its superiority over percutaneous transhepatic biliary drainage in terms of clinical success, safety, cost, and overall survival.	Studies with more people or longer follow up are included.
Gupta K, Perez-Miranda M, Kahaleh M et al. (2014). Endoscopic ultrasound-assisted bile duct access and drainage: multicentre, long-term analysis of approach, outcomes, and complications of a technique in evolution. <i>Journal of Clinical Gastroenterology</i> 48(1): 80–7	Case series  n=240  Follow up not reported	The EUS-BD technique is currently limited by a lack of dedicated devices and large data reporting outcomes and complications. Larger prospective and multicentre studies are needed to better define the indications, outcomes, and complications. With greater experience and dedicated devices, EUS-BD can be an effective alternative.	More recent studies included.  Study included in Dhindsa (2020) systematic review.
Hamada T, Nakai Y, Lau JY et al. (2018). International study of endoscopic management of distal malignant biliary obstruction combined with duodenal obstruction. <i>Scandinavian Journal of</i>	Non-randomised comparative study  n=110 (10 EUS-CDS versus 10 EUS-HGS versus 90 ERCP)	Transpapillary or transmural endoscopic biliary drainage with a duodenal stent was effective, irrespective of the timing or location of duodenal obstruction. A prospective study is required considering the trade-off of technical	Studies with more people or longer follow up are included.

IP overview: endoscopic ultrasound-guided biliary drainage for biliary obstruction



Gastroenterology 53(1): 46–55	Follow up: until death (median survival 199 days)	success rate, stent patency, and adverse events.	
Han SY, Kim S-O, So H et al. (2019). EUS-guided biliary drainage versus ERCP for first-line palliation of malignant distal biliary obstruction: A systematic review and meta-analysis. Scientific Reports 9(1): 1-9	Systematic review and meta-analysis n=756 (10 studies, 331 EUS-BD versus 425 ERCP)	As first-line palliation of MDBO, EUS-BD was similar to ERCP in technical and clinical success and safety; however, larger randomised trials comparing EUS-CDS and ERCP in this setting with endoscopically accessible papilla may be required.	Larger systematic review (Dhindsa 2020) already included.
Hao F, Zheng M, Qin M. (2014). The effect of endoscopic ultrasonography in treatment of distal inflammatory biliary stricture: a retrospective analysis of 165 cases. Hepato-Gastroenterology 61(136): 2177–80	Case series n=165 Follow up: mean 27.6 months	EUS for distal inflammatory biliary stricture can be selected as a safe, effective and minimally invasive therapeutic method.	Studies with more people or longer follow up are included.
Harai S, Hijioka S, Nagashio Y et al. (2022) Usefulness of the laser-cut, fully covered, self-expandable metallic stent for endoscopic ultrasound-guided hepaticogastrostomy. Journal of hepato-biliary-pancreatic sciences 29: 1035-1043	Retrospective case series n=95 Follow up: 12 months	Technical and clinical success rates were 100% and 96%, respectively. Median time to recurrent biliary obstruction was 398 days. Recurrent biliary obstruction causes were hyperplasia (7%), debris (3%), and migration (4%). Adverse events occurred in 9 patients (10%). Non-occlusion and focal cholangitis occurred in 4 patients (4%) each.	Studies with more patients or longer follow up are included.
Hathorn KE, Bazarbashi AN, Sack JS et al. (2019). EUS-guided biliary drainage is equivalent to ERCP for primary treatment of malignant distal biliary obstruction: A systematic review and meta-analysis. Endoscopy	Systematic review and meta-analysis n=318 (7 studies, 193 EUS-BD versus 159 ERCP)	Primary EUS-BD is an effective treatment with few adverse events. Comparing EUS-BD versus ERCP, EUS-BD has comparable efficacy and improved safety as a primary treatment for malignant biliary obstruction. Further randomised trials should be done to identify	Larger systematic review (Dhindsa 2020) already included.

IP overview: endoscopic ultrasound-guided biliary drainage for biliary obstruction

International Open 7(11): e1432–41		patient populations and clinical scenarios in which primary EUS-BD would be most appropriate.	
Hayat U, Bakker C, Dirweesh A et al. (2022). EUS-guided versus percutaneous transhepatic cholangiography biliary drainage for obstructed distal malignant biliary strictures in patients who have failed endoscopic retrograde cholangiopancreatography : A systematic review and meta-analysis. Endoscopic Ultrasound 11(1): 4–16	Systematic review and meta-analysis n=1131 (567 EUS-BD versus 564 PTC)	This meta-analysis indicates that EUS-BD is equally effective but safer in terms of acute and total adverse events than PTBD for biliary decompression in patients with malignant biliary strictures who have failed an ERCP.	Larger systematic review and meta-analysis (Dhindsa 2020) already included.
Huang P, Zhang H, Zhang X-F et al. (2017). Comparison of endoscopic ultrasonography guided biliary drainage and percutaneous transhepatic biliary drainage in the management of malignant obstructive jaundice after failed ERCP. Surgical Laparoscopy, Endoscopy & Percutaneous Techniques 27(6):127-31	Non-randomised comparative study n=66 (36 EUS-BD versus 30 PTBD) Follow up: 1 month	In the treatment of malignant obstructive jaundice, endoscopic ultrasonography guided biliary drainage is safer and more effective than percutaneous transhepatic biliary drainage when done by experienced practitioners after failed ERCP. Its more widespread use is recommended.	Studies with more people or longer follow up are included.
Huang P, Zhang H, Zhang X-F et al. (2020). Application and value of endoscopic ultrasonography guided biliary interventional therapy in patients with biliary obstruction and surgically altered anatomy. Surgical Laparoscopy, Endoscopy & Percutaneous Techniques 30(5): 454–8	Non-randomised comparative study n=60 (33 EUS-BD versus 27 PTBD) Follow up: up to 6 months	EUS-BD may be the first choice for patients with biliary obstruction and surgically altered anatomy after a failed endoscopic retrograde cholangiography in centres with expertise in EUS-BD procedures.	Studies with more people or longer follow up are included.
Imai H, Takenaka M, Omoto S et al. (2017).	Non-randomised comparative	Although the technical success rate of EUS-HGS	Studies with more people

IP overview: endoscopic ultrasound-guided biliary drainage for biliary obstruction

<p>Utility of Imai H, Takenaka M, Omoto S et al. (2017). Utility of endoscopic ultrasound-guided hepaticogastrostomy with antegrade stenting for malignant biliary obstruction after failed endoscopic retrograde cholangiopancreatography . Oncology 93(Suppl. 1): 69–75</p>	<p>study</p> <p>n=79 (42 EUS-HGS versus 37 EUS-HGS+AGS)</p> <p>Follow up: not reported</p>	<p>with antegrade stenting was lower than that of EUS-HGS, it was superior in terms of adverse-event rate and stent patency in patients receiving chemotherapy.</p>	<p>or longer follow up are included.</p>
<p>Ishiwatari H, Ishikawa K, Niiya F et al. (2022). Endoscopic ultrasound-guided hepaticogastrostomy versus hepaticogastrostomy with antegrade stenting for malignant distal biliary obstruction. Journal of Hepato-Biliary-Pancreatic Sciences 29: 703-12</p>	<p>Non-randomised comparative study</p> <p>n=96 (58 EUS-HGS versus 38 EUS-HGS+AGS)</p> <p>Follow up: not reported</p>	<p>Endoscopic ultrasound-guided hepaticogastrostomy with antegrade stenting prolonged the time to recurrent biliary obstruction compared with EUS-HGS alone for biliary drainage in patients with DMBO.</p>	<p>Studies with more people or longer follow up are included.</p>
<p>Ishiwatari H, Satoh T, Sato J et al. (2021). Bile aspiration during EUS-guided hepaticogastrostomy is associated with lower risk of postprocedural adverse events: a retrospective single-centre study. Surgical Endoscopy 35(12): 6836–45</p>	<p>Non-randomised comparative study</p> <p>n=96 (45 EUS-HGS versus 51 EUS-HGS+AGS)</p> <p>Follow up: not reported</p>	<p>Bile aspiration of more than 10 ml during EUS-HGS contributes to reducing the rate of postprocedural adverse events.</p>	<p>Study focuses on procedural technique.</p>
<p>Iwashita T, Uemura S, Mita N et al. (2020). Endoscopic ultrasound guided-antegrade biliary stenting vs percutaneous transhepatic biliary stenting for unresectable distal malignant biliary obstruction in patients with surgically altered anatomy. Journal of</p>	<p>Non-randomised comparative study</p> <p>n=64 (45 EUS-AGS versus 29 PTBD)</p> <p>Follow up: not reported</p>	<p>Similar to PTBD, EUS-AGS can effectively and safely manage DMBO in patients with surgically altered anatomy. Further well-designed trials are warranted to confirm these findings.</p>	<p>Studies with more people or longer follow up are included.</p>

IP overview: endoscopic ultrasound-guided biliary drainage for biliary obstruction

Hepato-Biliary-Pancreatic Sciences 27(12): 968–76			
Jacques J, Privat J, Pinard F et al. (2019). Endoscopic ultrasound-guided choledochoduodenostomy with electrocautery-enhanced lumen-apposing stents: a retrospective analysis. <i>Endoscopy</i> 51(6): 540–7	Case series n=52 EUS-CDS Follow up: mean 157 days	EUS-CDS with an electrocautery-enhanced LAMS is efficacious and safe in distal malignant obstruction of the common bile duct and could be proposed as the first option in cases of ERCP failure.	Studies with more people or longer follow up are included.
Jacques J, Privat J, Pinard F et al. (2020). EUS-guided choledochoduodenostomy by use of electrocautery-enhanced lumen-apposing metal stents: a French multicentre study after implementation of the technique (with video). <i>Gastrointestinal Endoscopy</i> 92(1): 134–41	Case series n=70 EUS-CDS Follow up: mean 153 days	EUS-CDS with the electrocautery-enhanced LAMS is efficacious and safe in distal malignant obstruction of the common bile duct in cases of ERCP failure with impressive results once expertise is acquired and the recommended technique (direct fistulotomy, pure cut current, and 6-mm stent) is followed.	Studies with more people or longer follow up are included.
Jagielski M, Zielinski M, Piatkowski J et al. (2021). Outcomes and limitations of endoscopic ultrasound-guided hepaticogastrostomy in malignant biliary obstruction. <i>BMC Gastroenterology</i> 21(1): 202	Case series n=53 EUS-HGS Follow up: mean 155 days	In the event of transpapillary biliary drainage proving ineffective, extra-anatomical anastomoses of intrahepatic bile ducts to the gastrointestinal tract provide an effective method for the treatment of patients with malignant biliary obstruction.	Studies with more people or longer follow up are included.
Jagielski M, Zielinski M, Piatkowski J et al. (2022). The role of endoscopic ultrasound-guided transmural approach in the management of biliary obstructions. <i>Surgical Laparoscopy, Endoscopy &amp; Percutaneous Techniques</i> 32(3): 285–91	Case series n=124 EUS-BD Follow up: mean 9 months	Various methods of EUS-guided transmural access to bile ducts improves endotherapy outcomes of patients with biliary obstruction. Endoscopic transmural access is highly effective and associated with an acceptable number of complications.	Studies with more people or longer follow up are included.
Jiang XW, Tang SH, Yang JQ et al. (2014).	Non-randomised comparative	Endoscopic biliary drainage under ultrasound guidance	Studies with more people

IP overview: endoscopic ultrasound-guided biliary drainage for biliary obstruction

<p>Ultrasound-guided endoscopic biliary drainage: a useful drainage method for biliary decompression in patients with biliary obstructions. <i>Digestive Diseases and Sciences</i> 59(1): 161–67</p>	<p>study</p> <p>n=125 (63 ultrasound-guided endoscopic biliary versus 62 fluoroscopy-guided endoscopic biliary drainage)</p> <p>Follow up: not reported</p>	<p>and under fluoroscopy guidance is equally effective and safe for patients with lower or upper/middle obstructions of the common bile duct. The EUS-BD technique is especially suitable for special patients, such as critically ill patients, pregnant woman, etc.</p>	<p>or longer follow up are included.</p>
<p>Jin Z, Wei Y, Lin H et al. (2020). Endoscopic ultrasound-guided versus endoscopic retrograde cholangiopancreatography-guided biliary drainage for primary treatment of distal malignant biliary obstruction: A systematic review and meta-analysis. <i>Digestive Endoscopy: Official Journal of the Japan Gastroenterological Endoscopy Society</i> 32(1): 16–26</p>	<p>Systematic review and meta-analysis</p> <p>n=361 (171 EUS-BD versus 190 ERCP), 5 studies</p> <p>Follow up: median 95 to 298 days</p>	<p>With adequate endoscopy expertise, EUS-BD could show similar efficacy and safety when compared with ERCP-BD for primary palliation of DMBO and exhibits several clinical advantages.</p>	<p>Larger systematic review and meta-analysis (Dhindsa 2020) already included.</p>
<p>Kakked G, Salameh H, Cheesman A et al. (2020). Primary EUS-guided biliary drainage versus ERCP drainage for the management of malignant biliary obstruction: A systematic review and meta-analysis. <i>Endoscopic Ultrasound</i> 9(5): 298–307</p>	<p>Systematic review and meta-analysis</p> <p>n=302 (137 EUS-BD versus 165 ERCP), 4 studies</p> <p>Follow up: median 95 to 298 days</p>	<p>EUS-BD has comparable technical and clinical success to ERCP and can potentially be used as a first-line palliative modality for malignant biliary obstruction where expertise is available. ERCP-related pancreatitis, which can cause significant morbidity, can be completely avoided with EUS.</p>	<p>Larger systematic review and meta-analysis (Dhindsa 2020) already included.</p>
<p>Kanno Y, Koshita S, Ogawa T et al. (2019). EUS-guided biliary drainage for unresectable malignant biliary obstruction: 10-year</p>	<p>Case series</p> <p>n=99 EUS-BD</p> <p>Follow up: mean 136 days</p>	<p>EUS-BD was found to be feasible. However, there were a few patients with an unfavourable course after successful EUS-BD.</p>	<p>Studies with more people or longer follow up are included.</p>

IP overview: endoscopic ultrasound-guided biliary drainage for biliary obstruction

experience of 99 cases at a single centre. <i>Journal of Gastrointestinal Cancer</i> 50(3): 469–77			
Kawakubo K, Isayama H, Kato H et al. (2014). Multicentre retrospective study of endoscopic ultrasound-guided biliary drainage for malignant biliary obstruction in Japan. <i>Journal of Hepato-Biliary-Pancreatic Sciences</i> 21(5): 328–34	Case series n=64 EUS-BD  Follow up: mean 136 days	This Japanese multicentre study revealed a high success rate in EUS-BD. However, the complication rate was as high as that in previous series. Covered metal stents may be useful to reduce bile leakage in EUS-BD.	Studies with more people or longer follow up are included.
Kawakubo K, Kawakami H, Kuwatani M et al. (2016). Endoscopic ultrasound-guided choledochoduodenostomy vs. transpapillary stenting for distal biliary obstruction. <i>Endoscopy</i> 48(2): 164–9	Case series n=82 (26 EUS-CDS versus 56 endoscopic transpapillary stenting)  Follow up: mean 136 days	EUS-CDS done by expert endoscopists was associated with a short procedure time and no risk of pancreatitis, and would therefore be feasible as a first-line treatment for patients with distal malignant biliary obstruction.	Studies with more people or longer follow up are included.
Khan MA, Akbar A, Baron TH et al. (2016). Endoscopic ultrasound-guided biliary drainage: a systematic review and meta-analysis. <i>Digestive Diseases and Sciences</i> 61(3): 684–703	Systematic review and meta-analysis  n=1186, 20 studies	In cases of failure of traditional ERCP to achieve biliary drainage, EUS-BD appears to be an emerging therapeutic modality with a cumulative success rate of 90% and cumulative adverse events rate of 17%. Randomised controlled trials are required to further evaluate the efficacy and safety of the procedure along with the comparison to traditional modalities like percutaneous transhepatic biliary drainage.	Larger systematic review and meta-analysis (Dhindsa 2020) already included.
Khashab M, Messallam A, Penas I et al. (2016). International multicentre comparative trial of transluminal EUS-guided biliary drainage via hepatogastrostomy vs.	Non-randomised comparative study  n=121 (60 EUS-CDS versus 61 EUS-HGS)	Both EUS-CDS and EUS-HGS are effective and safe techniques for the treatment of distal biliary obstruction after failed ERCP. However, EUS-CDS is associated with shorter hospital stay,	Studies with more people or longer follow up are included.

IP overview: endoscopic ultrasound-guided biliary drainage for biliary obstruction

choledochoduodenostomy approaches. Endoscopy International Open 4(2): e175–81	Follow up: mean 151 days	improved stent patency, and fewer procedure- and stent-related complications. Metallic stents should be placed whenever feasible and non-coaxial electrocautery should be avoided when possible, as plastic stenting and non-coaxial electrocautery were independently associated with occurrence of adverse events.	
Khashab MA, El Zein MH, Sharzei K et al. (2016). EUS-guided biliary drainage or enteroscopy-assisted ERCP in patients with surgical anatomy and biliary obstruction: An international comparative study. Endoscopy International Open 4(12): e1322–7	Non-randomised comparative study  n=98 (49 EUS-BD versus 49 ERCP)  Follow up: not reported	EUS-BD can be done with a higher degree of clinical efficacy and shorter procedure time than enteroscopy-assisted ERCP in patients with surgically altered upper gastrointestinal anatomy. Whether or not this approach should be first-line therapy in this patient population is highly dependent on the indication for the procedure, the patient's anatomy, and local practice and expertise.	Studies with more people or longer follow up are included.
Khashab MA, Valeshabad AK, Afghani E et al. (2015). A comparative evaluation of EUS-guided biliary drainage and percutaneous drainage in patients with distal malignant biliary obstruction and failed ERCP. Digestive Diseases and Sciences 60(2): 557–65	Non-randomised comparative study  n=73 (22 EUS-BD versus 51 PTBD)  Follow up: not reported	EUS-BD and PTBD are comparably effective techniques for treatment of distal malignant biliary obstruction after failed ERCP. However, EUS-BD is associated with decreased adverse events rate and is significantly less costly due to the need for fewer reinterventions. Our results suggest that EUS-BD should be the technique of choice for treatment of these patients at institutions with experienced interventional endosonographers.	Studies with more people or longer follow up are included.
Khashab MA, Van Der Merwe S, Kunda R et al.	Non-randomised comparative	This study on EUS-BD demonstrates excellent	Studies with more people

IP overview: endoscopic ultrasound-guided biliary drainage for biliary obstruction

(2016). Prospective international multicentre study on endoscopic ultrasound-guided biliary drainage for patients with malignant distal biliary obstruction after failed endoscopic retrograde cholangiopancreatography. <i>Endoscopy International Open</i> 4(4): e487–96	study  n=98 (49 EUS-BD versus 49 ERCP)  Follow up: median 94 days	efficacy and safety of EUS-BD when done by experts.	or longer follow up are included.
Krishnamoorthi R, Dasari CS, Thoguluva Chandrasekar V et al. (2020). Effectiveness and safety of EUS-guided choledochoduodenostomy using lumen-apposing metal stents (LAMS): a systematic review and meta-analysis. <i>Surgical Endoscopy</i> 34(7): 2866–77	Systematic review and meta-analysis  n=284, 7 studies	EUS-CDS using LAMS/EC-LAMS is an effective and safe technique for biliary decompression in patients who failed ERCP. Further studies are needed to assess EUS-CDS using LAMS as primary treatment modality for biliary obstruction.	Larger systematic review and meta-analysis (Dhindsa 2020) already included.
Kunda R, Perez-Miranda M, Will U et al. (2016). EUS-guided choledochoduodenostomy for malignant distal biliary obstruction using a lumen-apposing fully covered metal stent after failed ERCP. <i>Surgical Endoscopy</i> 30(11): 5002–8	Case series  n=57 EUS-CDS  Follow up: mean 151 days	Our study shows that EUS-CDS using the AXIOS and the Hot AXIOS devices is a safe procedure, with high technical and clinical success rates.	Studies with more people or longer follow up are included.
Kuraoka N, Hara K, Okuno N et al. (2020). Outcomes of EUS-guided choledochoduodenostomy as primary drainage for distal biliary obstruction with covered self-expandable metallic stents. <i>Endoscopy International Open</i> 8(7): e861–68	Case series  n=92 EUS-CDS  Follow up: not reported	EUS-CDS as a primary drainage technique using SEMS has high technical and clinical success rates. It should be considered an effective drainage method with respect to long-term stent patency, low reintervention rates, and absence of severe complications.	Studies with more people or longer follow up are included.
Lee TH, Choi J-H, Park DH et al. (2016). Similar	RCT	EUS-BD and PTBD had similar levels of efficacy in	Studies with more people

IP overview: endoscopic ultrasound-guided biliary drainage for biliary obstruction



<p>efficacies of endoscopic ultrasound-guided transmural and percutaneous drainage for malignant distal biliary obstruction. Clinical Gastroenterology and Hepatology: The Official Clinical Practice Journal of the American Gastroenterological Association 14(7): 1011-9</p>	<p>n=66 (34 EUS-BD versus 32 PTBD)  Follow up: minimum 3 months</p>	<p>patients with unresectable malignant distal biliary obstruction and inaccessible papilla based on rates of technical and functional success and quality of life. However, EUS-BD produced fewer procedure-related adverse events and unscheduled reinterventions.</p>	<p>or longer follow up are included.</p>
<p>Li D-F, Zhou C-H, Wang L-S et al. (2019). Is ERCP-BD or EUS-BD the preferred decompression modality for malignant distal biliary obstruction? A meta-analysis of randomised controlled trials. Revista Espanola de Enfermedades Digestivas : Organo Oficial de La Sociedad Espanola de Patologia Digestiva 111(12): 953–60</p>	<p>Meta-analysis  n=220, 3 studies</p>	<p>Technical success, treatment success, procedure duration, and overall adverse-event rate were comparable between ERCP-BD and EUS-BD in decompressing malignant distal biliary obstruction. Nevertheless, EUS-BD had a significantly lower rate of post-ERCP pancreatitis and a lower tendency toward stent reintervention than ERCP-BD. Therefore, EUS-BD might be a suitable alternative to ERCP-BD when done by experts.</p>	<p>Larger meta-analysis (Dhindsa 2020) already included.</p>
<p>Lou X, Yu D, Li J et al. (2019). Efficacy of endoscopic ultrasound-guided and endoscopic retrograde cholangiopancreatography-guided biliary drainage for malignant biliary obstruction: a systematic review and meta-analysis. Minerva Medica 110(6): 564–74</p>	<p>Systematic review and meta-analysis  n=428, 4 studies</p>	<p>EUS-BD and ERCP-BD in terms of relief of malignant biliary obstruction presented the similarity rate of technical success, clinical success and there is no significant difference in adverse events of two procedures. EUS-BD could be used as a substitute for ERCP-BD, even considered as first-line treatment.</p>	<p>Larger systematic review and meta-analysis (Dhindsa 2020) already included.</p>
<p>Lyu Y, Li T, Cheng Y et al. (2021). Endoscopic ultrasound-guided vs ERCP-guided biliary drainage for malignant biliary obstruction: A up-</p>	<p>Systematic review and meta-analysis  n=634, 9 studies</p>	<p>EUS-BD was associated with lower reintervention rates compared with ERCP-BD, with comparable safety and efficacy outcomes. However,</p>	<p>Larger systematic review and meta-analysis (Dhindsa</p>

IP overview: endoscopic ultrasound-guided biliary drainage for biliary obstruction

to-date meta-analysis and systematic review. Digestive and Liver Disease: Official Journal of the Italian Society of Gastroenterology and the Italian Association for the Study of the Liver 53(10): 1247–53		more high-quality randomised trials are required.	2020) already included.
Mao K, Hu B, Sun F et al. (2021). Choledochoduodenostomy versus hepaticogastrostomy in endoscopic ultrasound-guided drainage for malignant biliary obstruction: a meta-analysis and systematic review. Surgical Laparoscopy, Endoscopy & Percutaneous Techniques 32(1): 124–32	Systematic review and meta-analysis  n=222 (359 EUS-CDS versus 400 EUS-HGS), 9 studies	EUS-CDS and EUS-HGS have comparable technical and clinical success rates, adverse events, and overall survival. However, EUS-CDS has less reintervention and stent obstruction.	Larger systematic review and meta-analysis (Dhindsa 2020) already included.
Miller CS, Barkun AN, Martel M et al. (2019). Endoscopic ultrasound-guided biliary drainage for distal malignant obstruction: A systematic review and meta-analysis of randomised trials. Endoscopy International Open 7(11): e1563–73	Systematic review and meta-analysis  n=354, 9 studies	In a meta-analysis of randomised trials comparing EUS-BD to conventional biliary drainage modalities, no difference in technical or clinical success was observed. Importantly, EUS-BD was associated with decreased risks of stent/catheter dysfunction when compared to both PTBD and ERCP, and decreased post-procedure pancreatitis when compared to ERCP, suggesting the potential role for EUS-BD as an alternative first-line therapy in distal malignant biliary obstruction.	Larger systematic review and meta-analysis (Dhindsa 2020) already included.
Moole H, Bechtold ML, Forcione D et al. (2017). A meta-analysis and systematic review: Success of endoscopic	Systematic review and meta-analysis  n=528, 16 studies	In patients with inoperable malignant biliary strictures who failed an ERCP-guided biliary stenting, EUS-BD seems to be an excellent	Larger systematic review and meta-analysis

IP overview: endoscopic ultrasound-guided biliary drainage for biliary obstruction

ultrasound guided biliary stenting in patients with inoperable malignant biliary strictures and a failed ERCP. <i>Medicine</i> 96(3): e5154		management option with higher successful biliary drainage rates and relatively fewer complications. EUS-BD seems to be significantly superior to PTBD with higher successful drainage rates and fewer complications. In patients with failed ERCP and altered biliary and duodenal anatomy, EUS-BD should be preferred to PTBD when appropriate operator expertise and infrastructure is available.	(Dhindsa 2020) already included.
Nakai Y, Sato T, Hakuta R et al. (2020). Long-term outcomes of a long, partially covered metal stent for EUS-guided hepaticogastrostomy in patients with malignant biliary obstruction (with video). <i>Gastrointestinal Endoscopy</i> 92(3): 623-31	Case series n=110 EUS-HGS  Follow up: not reported	EUS-HGS using a long, partially covered metal stent for unresectable malignant biliary obstruction was safe and effective. Recurrent biliary obstruction was not uncommon, but reintervention through the EUS-HGS route was technically possible in most cases.	Studies with more people or longer follow up are included.
Park DH, Jang JW, Lee SS et al. (2011). EUS-guided biliary drainage with transluminal stenting after failed ERCP: predictors of adverse events and long-term results. <i>Gastrointestinal Endoscopy</i> 74(6): 1276–84	Case series n=57 EUS-BD  Follow up: mean 205 days	EUS-HGS and EUS-CDS may be relatively safe and can be used as an alternative to PTBD after failed ERCP. Both techniques offer durable and comparable stent patency. The use of a needle-knife for fistula dilation in EUS-BDS should be avoided if possible.	Studies with more people or longer follow up are included.
Peng Z, Li S, Tang Y et al. (2021). Efficacy and safety of EUS-guided choledochoduodenostomy using electrocautery-enhanced lumen-apposing metal stents (ECE-LAMS) in the treatment of biliary obstruction: A systematic review and meta-analysis. <i>Canadian Journal of</i>	Systematic review and meta-analysis  n=270, 6 studies	EUS-CDS using electrocautery-enhanced LAMS provides favourable outcomes in patients with biliary obstruction. It has been associated with a higher success rate and a lower rate of adverse events when compared with the biliary drainage approaches previously used. Large and randomised controlled	Larger systematic review and meta-analysis (Dhindsa 2020) already included.

IP overview: endoscopic ultrasound-guided biliary drainage for biliary obstruction

Gastroenterology and Hepatology 6696950		observational studies are required to further refine the findings in the present analysis.	
Poincloux L, Rouquette O, Buc E et al. (2015). Endoscopic ultrasound-guided biliary drainage after failed ERCP: cumulative experience of 101 procedures at a single centre. Endoscopy 47(9): 794–801	Case series n=101 EUS-BD  Follow up: mean 280 days	EUS-guided biliary drainage is an efficient technique, but is associated with significant morbidity that seems to decrease with the learning curve. It should be done in tertiary care centres in selected patients. Prospective randomised studies are needed to compare EUS-guided biliary drainage with percutaneous transhepatic cholangiography drainage.	Studies with more people or longer follow up are included.
Puga M, Pallares N, Velasquez-Rodriguez J et al. (2019). Endoscopic biliary drainage in unresectable biliary obstruction: the role of endoscopic ultrasound-guidance in a cohort study. Revista Espanola de Enfermedades Digestivas : Organo Oficial de La Sociedad Espanola de Patologia Digestiva 111(9): 683–9	Case series n=52 EUS-BD  Follow up: minimum 1 year	The requirement of EUS-BD in palliative biliopancreatic pathology is not marginal. EUS-BD is associated with a lower survival rate and a higher rate of fatal adverse events, which argues against its use as a first choice procedure.	Studies with more people or longer follow up are included.
Sawas T, Bailey N, Yeung K et al. (2022) Comparison of EUS-guided choledochoduodenostomy and percutaneous drainage for distal biliary obstruction: A multicenter cohort study. Endoscopic Ultrasound 11: 223-230	Retrospective cohort study n=86 Follow up: median 164 days	EUS-CD is a technically and clinically highly successful procedure with a trend toward lower adverse events compared to PTBD. EUS-CD minimises the need for reintervention, which may enhance end-of-life quality in patients with malignant biliary obstruction and expected survival longer than 50 days.	Studies with more patients or longer follow up are included.
Sharaiha RZ, Khan MA, Kamal F et al. (2017). Efficacy and safety of EUS-guided biliary	Systematic review and meta-analysis	When ERCP fails to achieve biliary drainage, EUS-guided interventions may be preferred over PTBD if	Larger systematic review and meta-

IP overview: endoscopic ultrasound-guided biliary drainage for biliary obstruction

<p>drainage in comparison with percutaneous biliary drainage when ERCP fails: a systematic review and meta-analysis. <i>Gastrointestinal Endoscopy</i> 85(5): 904–14</p>	<p>n=483 (252 EUS-BD versus 231 PTBD), 9 studies</p>	<p>adequate advanced endoscopy expertise and logistics are available. EUS-BD is associated with significantly better clinical success, lower rate of post-procedure adverse events, and fewer reinterventions.</p>	<p>analysis (Dhindsa 2020) already included.</p>
<p>Sharaiha RZ, Kumta NA, Desai AP et al. (2016). Endoscopic ultrasound-guided biliary drainage versus percutaneous transhepatic biliary drainage: predictors of successful outcome in patients who fail endoscopic retrograde cholangiopancreatography. <i>Surgical Endoscopy</i> 30(12): 5500–5</p>	<p>Case series n=60 (47 EUS-BD versus 13 PTBD) Follow up: not reported</p>	<p>Despite similar technical success rates compared to PTBD, EUS-BD results in a lower need for reintervention, decreased rate of late adverse events, and lower pain scores, and is the sole predictor for clinical success and long-term resolution. EUS-BD should be the treatment of choice after a failed ERCP.</p>	<p>Studies with more people or longer follow up are included.</p>
<p>Sportes A, Camus M, Greget M et al. (2017). Endoscopic ultrasound-guided hepaticogastrostomy versus percutaneous transhepatic drainage for malignant biliary obstruction after failed endoscopic retrograde cholangiopancreatography: A retrospective expertise-based study from two centres. <i>Therapeutic Advances in Gastroenterology</i> 10(6): 483–93</p>	<p>Case series n=51 (31 EUS-HGS versus 20 PTBD) Follow up: until death or transfer to palliative care centre</p>	<p>EUS-HGS can be an effective and safe mini-invasive-procedure alternative to PTBD, with similar success and adverse-event rates, but with lower rates of reintervention and length of hospitalisation.</p>	<p>Studies with more people or longer follow up are included.</p>
<p>Tellez-Avila FI, Figueredo-Zacarias MA, Munoz-Anaya E et al. (2021). EUS-guided biliary drainage in patients with distal malignant biliary obstruction requires fewer interventions and has a lower cost compared to</p>	<p>Non-randomised comparative study n=124 (24 EUS-BD versus 60 ERCP with plastic stent-PS versus 40 ERCP</p>	<p>EUS-BD requires fewer reinterventions and has a lower cost compared to drainage by ERCP with metal or plastic stents.</p>	<p>Studies with more people or longer follow up are included.</p>

IP overview: endoscopic ultrasound-guided biliary drainage for biliary obstruction

ERCP biliary drainage. <i>Surgical Endoscopy</i> 35(6): 2531–36	with metal stent) Follow up: not reported		
Tellez-Avila FI, Herrera-Mora D, Duarte-Medrano G et al. (2018). Biliary Drainage in Patients With Failed ERCP: Percutaneous Versus EUS-guided Drainage. <i>Surgical Laparoscopy, Endoscopy &amp; Percutaneous Techniques</i> 28(3): 183–87	Non-randomised comparative study n=62 (30 EUS-BD versus 32 PTBD) Follow up: not reported	EUS-BD is associated with a higher clinical success rate and safety, shorter hospital stays, and lower cost compared with PTBD.	Studies with more people or longer follow up are included.
Teoh AYB, Kongkam P, Bapaye A et al. (2021). Use of a novel lumen apposing metallic stent for drainage of the bile duct and gallbladder: Long-term outcomes of a prospective international trial. <i>Digestive Endoscopy: Official Journal of the Japan Gastroenterological Endoscopy Society</i> 33(7): 1139–45	Non-randomised comparative study n=53 (26 EUS-CDS versus 27 EUS-GBD) Follow up: mean 131 days	The self-approximating LAMS with lower lumen-apposing force was effective and safe with a low risk of buried stent syndrome and bleeding in the longer term.	Studies with more people or longer follow up are included.
Tyberg A, Desai AP, Kumta NA et al. (2016). EUS-guided biliary drainage after failed ERCP: a novel algorithm individualized based on patient anatomy. <i>Gastrointestinal Endoscopy</i> 84(6): 941–46	Case series n=52 EUS-BD Follow up: mean 12.5 weeks	EUS-BD after failed conventional ERCP is successful and safe when this novel algorithm is used.	Studies with more people or longer follow up are included.
Uemura RS, Khan MA, Otoch JP et al. (2018). EUS-guided Choledochoduodenostomy Versus Hepaticogastrostomy. <i>Journal of Clinical Gastroenterology</i> 52(2): 123–30	Systematic review and meta-analysis n=434 (208 EUS-HGS versus 226 EUS-CDS), 10 studies	EUS-CDS and EUS-HGS have equal efficacy and safety and are both associated with a very high technical and clinical success. The choice of approach may be selected based on patient anatomy.	Larger systematic review and meta-analysis (Dhindsa 2020) already included.

IP overview: endoscopic ultrasound-guided biliary drainage for biliary obstruction

Wang K, Zhu J, Xing L et al. (2016). Assessment of efficacy and safety of EUS-guided biliary drainage: a systematic review. <i>Gastrointestinal Endoscopy</i> 83(6): 1218–27	Systematic review and meta-analysis  n=1192 (42 studies)	Although it is associated with significant morbidity, EUS-BD is an effective alternative procedure for relieving biliary obstruction. There was no significant difference between the transduodenal and transgastric approaches for EUS-BD.	Larger systematic review and meta-analysis (Dhindsa 2020) already included.
Wang Y, Lyu Y, Li T et al. (2021). Comparing outcomes following endoscopic ultrasound-guided biliary drainage versus percutaneous transhepatic biliary drainage for malignant biliary obstruction: a systematic review and meta-analysis. <i>Journal of Laparoendoscopic &amp; Advanced Surgical Techniques. Part A</i>	Systematic review and meta-analysis  n=512 (256 EUS-BD versus 256 percutaneous transhepatic biliary drainage), 9 studies	The available literature suggests that EUS-BD is associated with fewer adverse events, greater clinical success, and comparable technical success compared with percutaneous transhepatic biliary drainage. According to the shortcomings of our study, more large, high-quality, randomised controlled trials are needed to compare these techniques and confirm our findings.	Larger systematic review and meta-analysis (Dhindsa 2020) already included.
Will U, Fuedner F, Kern C et al. (2015). EUS-guided bile duct drainage (EUBD) in 95 patients. <i>Ultraschall in Der Medizin (Stuttgart, Germany: 1980)</i> 36(3): 276–83	Case series  n=95 EUS-BD  Follow up: mean 8 months	EUS-BD is a promising therapy for bile duct obstruction in patients predominantly with malignant diseases. Using EUS-BD, an excellent interventional approach is available for long-term internal drainage to prevent percutaneous drainage. EUS-guided drainage is challenging and needs extraordinary interventional expertise, preferentially in tertiary gastroenterological and endoscopic centres.	Studies with more people or longer follow up are included.
Xie J, Garg S, Perisetti A et al. (2022). Comparison of biliary drainage techniques for malignant biliary obstruction: a systematic review and network meta-analysis.	Systematic review and network meta-analysis  n=1566 (419 EUS-BD versus	The available evidence did not favour any intervention for drainage of malignant biliary obstruction across all the outcomes assessed. ERCP with or without EUS should be considered first to allow	Systematic review and meta-analysis with more EUS-BD patients (Dhindsa

IP overview: endoscopic ultrasound-guided biliary drainage for biliary obstruction

Journal of Clinical Gastroenterology 56(1): 88–97	478 ERCP versus 649 PTBD), 17 studies	simultaneous tissue acquisition and biliary drainage.	2020) already included.
Zhang HC, Tamil M, Kukreja K et al. (2020). Review of simultaneous double stenting using endoscopic ultrasound-guided biliary drainage techniques in combined gastric outlet and biliary obstructions. Clinical Endoscopy 53(2): 167–75	Non-randomised comparative study  n=152 (24 PTBD versus 44 EPBS versus 48 EMBS versus 36 EPBS+EMBS)  Follow up: not reported	Simultaneous double stenting with EUS-BD and gastroduodenal stenting for gastric outlet and biliary obstruction is associated with high success rates. It is a feasible and practical alternative to percutaneous biliary drainage or surgery for palliation in patients with associated advanced malignancies.	Study focuses on stenting technique.
Zhao X, Shi L, Wang J et al. (2022). Clinical value of preferred endoscopic ultrasound-guided antegrade surgery in the treatment of extrahepatic bile duct malignant obstruction. Clinics (Sao Paulo, Brazil) 77: 100017	Case series  n=58 EUS-AGS  Follow up: not reported	EUS-AGS operation has short time, low incidence of complications, safe, effective, and can be used as the preferred treatment plan for patients with extrahepatic biliary duct malignant obstruction associated with intrahepatic biliary duct expansion; EUS-AGS operation has more unique clinical advantages for patients with altered gastrointestinal anatomy or upper gastrointestinal obstruction.	Studies with more people or longer follow up are included.
Zhou Z, Liu H, Xu X et al. (2016). Comparison of efficiency and prognostic analysis in four biliary drainages for treatment of malignant obstructive jaundice. International Journal of Clinical and Experimental Medicine 9(6): 11409–18	Systematic review  n=51, 7 studies	The EMBS combined with plastic stent drainage method may improve the successful biliary drainage, have lower complications, longer patency, and longer survival time than other drainage methods.	Studies with more people or longer follow up are included.  No meta-analysis

IP overview: endoscopic ultrasound-guided biliary drainage for biliary obstruction