

# Interventional procedure overview of minimally invasive fusionless posterior-approach surgery to correct idiopathic scoliosis in children and young people

## Contents

Indications and current treatment.....	2
What the procedure involves.....	3
Outcome measures.....	3
Evidence summary .....	4
Population and studies description.....	4
Procedure technique .....	16
Efficacy.....	16
Safety.....	19
Validity and generalisability .....	21
Existing assessments of this procedure .....	22
Related NICE guidance .....	22
Interventional procedures.....	22
Medical technologies.....	23
Ongoing studies.....	23
Professional societies .....	23
Company engagement.....	24
References.....	24
Methods.....	25
Other relevant studies.....	28

IP overview: Minimally invasive fusionless posterior-approach surgery to correct idiopathic scoliosis in children and young people

© NICE 2023. All rights reserved. Subject to [Notice of rights](#).

**Table 1 Abbreviations**

<b>Abbreviation</b>	<b>Definition</b>
AIS	Adolescent idiopathic scoliosis
FDA	Food and Drug Administration
MCID	Minimal clinically important differences
MHRA	Medicines and healthcare products regulatory agency
MID-C system	Minimally invasive deformity correction system
SRS-22	Scoliosis Research Society-22 questionnaire
PDDC	Posterior dynamic deformity correction
PROMs	Patient reported outcome measures
VBT	Vertebral body tethering

## Indications and current treatment

Scoliosis is a 3-dimensional change to the spine in the coronal, sagittal, and axial planes. It causes the bones of the spine to twist or rotate so that the spine curves sideways. Scoliosis curves most commonly occur in the thoracic spine but can also occur in the lumbar spine. Occasionally, they occur in both the thoracic and lumbar spine.

AIS is the most common type of scoliosis in children and young people. It is progressive and its exact cause is unknown. Mild to moderate spinal curvature does not cause any health problems but can cause cosmetic concerns. Severe spinal curvature with secondary rib changes can also cause significant pain and lung problems.

Treatment of AIS depends on several factors, including skeletal maturity, location of the spinal curve, speed of curve progression and size of the curve.

Conservative treatments for mild to moderate AIS include routine surveillance (spinal imaging to monitor progression) and physical therapy. For severe AIS, interventions include casting or bracing (for curves of more than 25 degrees), or spinal fusion surgery (for curves of more than 40 degrees) with various instrumented metallic fixation techniques and grafting to fuse vertebrae.

Minimally invasive growth modulating and fusionless surgical techniques to correct idiopathic scoliosis include vertebral body stapling, VBT, magnetically controlled growing rods and sublaminar polyester bands. These are also being

IP overview: Minimally invasive fusionless posterior-approach surgery to correct idiopathic scoliosis in children and young people

used for AIS in some people. The aim is to correct the scoliosis, prevent progression, restore balance, and reduce pain and morbidity.

## What the procedure involves

Minimally invasive fusionless posterior approach surgery to correct idiopathic scoliosis is intended to treat AIS in selected people aged 8 years to 17 years whose bones have not fully matured. It is mainly used to correct flexible single curves (a thoracic major curve, or thoracolumbar or lumbar major curve) with a Cobb angle of up to 60 degrees that reduces to 30 degrees or less on lateral side-bending radiographs and thoracic kyphosis of less than 55 degrees (as measured from T5 to T12).

The procedure is done under general anaesthesia and fluoroscopic guidance using a posterior unilateral approach. The concave side of the spinal curve is exposed through an incision around the apex of the curve. Two pedicle screws are inserted into the vertebral bodies through the pedicle above and below the apex of the spinal curvature to serve as anchor points. A ratchet rod with an extender and 2 polyaxial joints (that allow a degree of spinal motion) is then fixed to the spine with pedicle screws that are implanted around the apex of the curve. Distraction during surgery is applied with a manual instrument to expand the rod and to straighten the spine. After the procedure people are allowed to weight bear during everyday activities.

About 2 to 3 weeks after surgery, people are advised to exercise daily. This is to allow the rod additional unilateral elongation so there may be further gradual straightening of the spine while the person continues to grow. Because the procedure does not involve any spinal fusion, spinal motion is preserved. This minimises length of hospital stay and recovery time.

## Outcome measures

The main outcomes included were curve correction and PROMs. The measures used were:

The **Cobb angle**: this is used to quantify the magnitude of spinal deformities, especially in the case of scoliosis, on plain radiographs. Scoliosis is defined as a lateral spinal curvature with a Cobb angle of 10 degree or more. A Cobb angle can also aid kyphosis or lordosis assessment in the sagittal plane. Overall, if a greater than 10 degree change in Cobb angle is measured, it is 95% likely to represent a true difference.

IP overview: Minimally invasive fusionless posterior-approach surgery to correct idiopathic scoliosis in children and young people

© NICE 2023. All rights reserved. Subject to [Notice of rights](#).

The **Risser classification**: this is used to grade skeletal maturity and the potential for future growth based on the level of ossification and fusion of the iliac crest apophyses. It is primarily used in planning corrective surgery for scoliosis and consists of stage 0 to 5:

- stage 0: no ossification centre at the level of iliac crest apophysis
- stage 1: apophysis under 25% of the iliac crest
- stage 2: apophysis over 25% to 50% of the iliac crest
- stage 3: apophysis over 50% to 75% of the iliac crest
- stage 4: apophysis over 75% of the iliac crest
- stage 5: complete ossification and fusion of the iliac crest apophysis

The **Lenke (AO) classification**: this has 6 categories based on site and type of curves:

- Type 1: thoracic
- Type 2: double thoracic
- Type 3: double major
- Type 4: triple major
- Type 5: thoracolumbar
- Type 6: thoracolumbar or lumbar

The **SRS-22** questionnaire: this is used to assess health-related quality of life in patients with scoliosis. It includes 22 items distributed among 5 domains (pain, self-image, function or activity, mental health and satisfaction with management). Each item is scored from 1 (worst) to 5 (best).

## Evidence summary

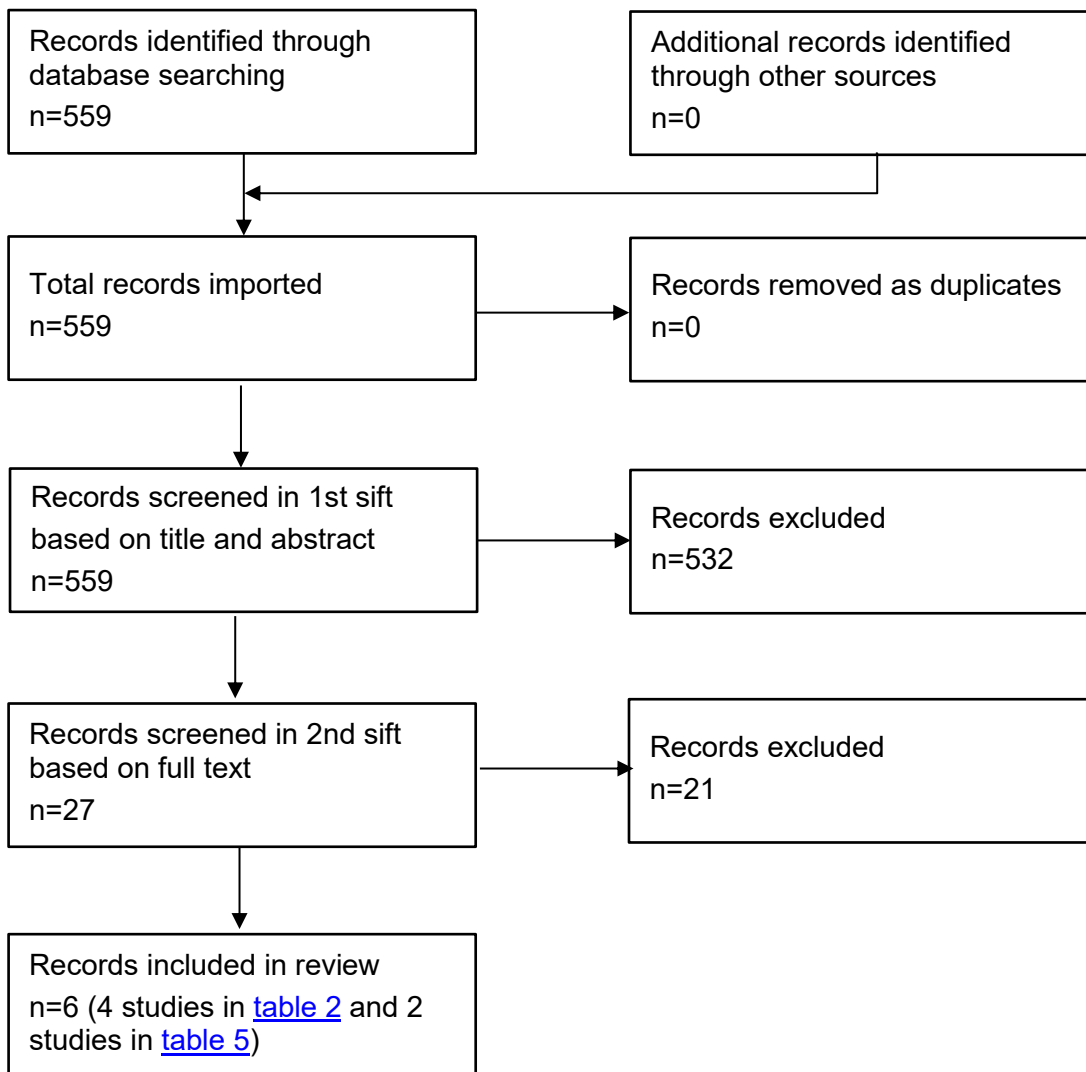
### Population and studies description

This interventional procedures overview is based on 90 patients from 2 retrospective case series (Floman 2020, Floman 2015), 1 retrospective cohort study (Floman 2021), and 1 prospective cohort study (Stadhouders 2021). There was some patient overlap between studies. This is a rapid review of the literature, IP overview: Minimally invasive fusionless posterior-approach surgery to correct idiopathic scoliosis in children and young people

and a flow chart of the complete selection process is shown in [figure 1](#). This overview presents 4 studies as the key evidence in [table 2](#) and [table 3](#), and lists 2 other relevant studies in [table 5](#).

The 4 studies included patients from Israel and the Netherlands. The recruitment period ranged from 2015 to 2021. Studies had a mean follow up of between 2 years and 3 years. [Table 2](#) presents study details.

**Figure 1 Flow chart of study selection**



IP overview: Minimally invasive fusionless posterior-approach surgery to correct idiopathic scoliosis in children and young people

© NICE 2023. All rights reserved. Subject to [Notice of rights](#).

**Table 2 Study details**

Study no.	First author, date country	Patients (male: female)	Age	Study design	Inclusion criteria	Intervention	Follow up
1	Floman Y 2020, Israel (multicentre study 2015 to 2016)	22 (3:19)	13 to 17 years	Retrospective case series (phase 3 design of the device)	Single AIS structural curve between 40° to 60°. Curve flexibility 30° or more. Risser grades 2 or above. Lenke type 1 or type 5 curves up to 60° that reduce on lateral bending views to 30° or less and kyphosis of 50° or less.	PDDC device (ApiFix- MID-C system) PDDC surgery spanning 5-6 disc spaces.	Minimum 2-year follow up (range 2 to 3 years)
2	Floman Y 2021 Israel (2015 to 2018)	45 (4:41)	11 to 17 years	Retrospective cohort study (multicentre, phase 3 design of the device)	Risser grades 0 to 5, with minimum 2-years of follow up. indications for surgery:	PDDC device (ApiFix- MID-C system) 35 with Lenke type 1 curves 10 Lenke type 5 curves.	Average 2.3 years follow up (range 2 to 4 years)

IP overview: Minimally invasive fusionless posterior-approach surgery to correct idiopathic scoliosis in children and young people

© NICE 2023. All rights reserved. Subject to [Notice of rights](#).

Study no.	First author, date country	Patients (male: female)	Age	Study design	Inclusion criteria	Intervention	Follow up
					40° to 60° curves, reduced on lateral bending views to 35° or less with kyphosis not exceeding 55°. Non-compliant braced patients or patients with Lenke 5 curves with Cobb angles 35° or above		
3	Floman Y 2015, Israel	3 (0:3)	13 to 16 years	Case series	Preoperative thoracic curve of 43° to 53° Age 13 to 16 years Risser 1 to 4	PDDC device (ApiFix- MID-C system)	6 months to 2 years
4	Stadhouder A 2021, the Netherlands	20 (1:19)	12 to 17 years	Prospective cohort study (single centre, phase 2 design of the device)	Diagnosis of AIS Age 12 to 17 years Risser 1 to 4	PDDC device (ApiFix- MID-C system) phase 2 design FDA	Mean 3.4 ±1.0 years Minimum 2 years

IP overview: Minimally invasive fusionless posterior-approach surgery to correct idiopathic scoliosis in children and young people

© NICE 2023. All rights reserved. Subject to [Notice of rights](#).

Study no.	First author, date country	Patients (male: female)	Age	Study design	Inclusion criteria	Intervention	Follow up
					<p>Single structural curve (Lenke type 1 or 5)  Major Cobb angle of 40° to 55°  Reduction of the major curve to less than 35° on a supine lateral bending radiograph  Apical vertebral rotation of less than 15° (Bunnell scoliometer)</p>	<p>approved device  Procedure done by single surgeon.  Amount of distraction to achieve curve correction was based on surgeon assessment and was not standardised.  Lenke type 1 (n=14)  Type 5 (n=6)  Risser stage mean 2.5  Vertebral spanning mean 5.1</p>	
5	FDA Submission <a href="#">Summary of Safety and Probable Benefit</a>	Total: 252 Target population: 25 patients implanted with	Target population: Mean age: 15.0 ±1.7	Retrospective analysis of studies outside US.	Lenke type 1 or 5 curves Risser grade 2 or above	PDDC - MID-C system (phase 1 to 3 without extender component and	Up to 24 months

IP overview: Minimally invasive fusionless posterior-approach surgery to correct idiopathic scoliosis in children and young people



Study no.	First author, date country	Patients (male: female)	Age	Study design	Inclusion criteria	Intervention	Follow up
	<a href="#">(SSPB) Template (fda.gov)</a> August-December 2019	the Humanitarian Use Device version.  Extended target population n=49 patients - combination of the target population (n=25) and patients (n=24) with 40 to 44 degree curves.	Range: 13 to 19 years	Prospective, multicentre, non-randomised open label clinical study (n=20) and additional data from other studies: post-market clinical studies (n=26), commercial use (n=197), special access (n=9).	Preoperative Cobb angle between 40 and 60°  Flexible major curve – defined as lateral bending correction to 30 degrees or less.  Thoracic kyphosis less than 55°	phase 4 with extender component)  Older versions of the device were used in some procedures.	

**Table 3 Study outcomes**

First author, date	Efficacy outcomes	Safety outcomes
Yizhar Floman, 2020	<u>Curve correction (based on radiographic data):</u> mean preoperative curve was 47° (range 40° to 55°), the mean final major curve was 25° at 2-year follow up (a curve correction of 46%, (p<0.05).	Adverse events needing revision surgery 18% (4/22)  - nut loosening (n=2) occurred in the early postoperative course because of insufficient torque while tightening the nut

IP overview: Minimally invasive fusionless posterior-approach surgery to correct idiopathic scoliosis in children and young people

© NICE 2023. All rights reserved. Subject to [Notice of rights](#).

First author, date	Efficacy outcomes	Safety outcomes
	<p><u>Satisfactory outcome</u> (defined as the mean final Cobb angle of the major curve 30° or less [range 15 to 30] at final follow up) was achieved in 82% (18/22) patients.</p> <p>Trunk shift was corrected by 1.5 cm (range 0.4 to 4.3 cm).</p> <p>The mean minor curve reduced from 27° to 17° at final follow up (35% correction; p&lt;0.05).</p> <p><u>Change in kyphotic or lordotic curves (based on radiographic data):</u></p> <p>For Lenke type 1 curve, mean 2D thoracic kyphosis increased from 24° preoperatively to 27° at final follow up (p&lt;0.05).</p> <p>For Lenke type 5 curves, the mean lumbar lordosis reduced from 47° preoperatively to 42° at the final follow up (p&lt;0.05).</p> <p><u>PROMs</u></p> <p>The mean preoperative SRS-22 questionnaire score at 2-year follow up (increased from 2.74 ± 0.3 at baseline to 4.31 ± 0.4, p&lt;0.0001).</p> <p>The mean preoperative self-image score change was statistically significant (3.14 ± 0.39 versus 4.03 ± 0.41), but it did not meet the MCID of 0.98. Scores for other domains (pain, activity, and mental health) did not change statistically significantly.</p>	<ul style="list-style-type: none"> <li>- Pedicle screw back up (n=1)</li> <li>- device (ratchet) malfunction (n=1) occurred 3 years after surgery. The implant was removed in this patient without curve progression but retained in the other 3 patients</li> </ul>

IP overview: Minimally invasive fusionless posterior-approach surgery to correct idiopathic scoliosis in children and young people

© NICE 2023. All rights reserved. Subject to [Notice of rights](#).

First author, date	Efficacy outcomes	Safety outcomes
	<p>Patient satisfaction assessed by a questionnaire (score range 1 to 5) showed high satisfaction scores for general satisfaction with the procedure (4.8/5), the fact they would they choose the procedure again (4.8/5), and they would recommend it to a friend (4.8/5).</p>	
Yizhar Floman, 2021	<p><u>Vertebral wedging (measured only the coronal wedge deformation).</u></p> <p>In the overall cohort, the average preoperative coronal apical wedging of 7.4° (range 3.8° to 15°) was reduced to 5.7° (range 1° to 15°) at final follow up (p&lt;0.05). The average change in wedging was 1.7°.</p> <p>In the Risser 0 to 1 group (n=16), the average preoperative coronal apical wedging of 9.5° (range 6° to 14.5°) was reduced to 5.4° (range 1° to 8°) at final follow up (p&lt;0.05). The average change in wedging was 4.1°.</p> <p>In the Risser 2 to 3 group (n=15), the average preoperative coronal apical wedging of 7.7° (range 4° to 15°) was reduced to 7.0° (range 3° to 15°) at final follow up (not statistically significant). The average change in wedging was 0.7°.</p> <p>In the Risser 3 group (n=14), the average preoperative coronal apical wedging of 4.8° (range 3.8° to 6.5°) was reduced to 4.7° (range 3.7° to</p>	<p>Adverse events</p> <ul style="list-style-type: none"> <li>- nut loosening (n=1)</li> <li>- Pedicle screw misplacement (n=1)</li> <li>- device (ratchet) malfunction (n=1)</li> <li>- partial pedicle screw pull-out (n=1)</li> </ul> <p>All 4 patients had revision surgery, including 3 reinstallations of the implant. 1 case of screw pull-out was converted to VBT.</p> <p>No cases were converted to a fusion procedure.</p>

IP overview: Minimally invasive fusionless posterior-approach surgery to correct idiopathic scoliosis in children and young people

© NICE 2023. All rights reserved. Subject to [Notice of rights](#).

First author, date	Efficacy outcomes	Safety outcomes
	<p>6.5°) at final follow up (not statistically significant). The average change in wedging was 0.1°.</p> <p><u>Deformity correction (based on radiographic data):</u></p> <p>The average preoperative major curve angle, of both curve types (Lenke type 1 or 5), was similar among the 3 Risser groups: 47.6° (0 to 1 group, n=16), 46° (2 to 3 group, n=15) and 41.5° (4 to 5 group, n=14). Curves were reduced to 26.4°, 20.4° and 26.2° respectively, at final follow up (p&lt;0.05).</p> <p><u>Change in kyphotic or lordotic curves (based on radiographic data):</u></p> <p>At last follow-up visit, thoracic kyphosis increased on average by 7° in the Lenke 1 curves while lumbar lordosis decreased by 4° in the Lenke 5 curves.</p>	
Floman, 2015	<p><u>Case report 1 (female, 13, Risser 1)</u></p> <p>Thoracic curve correction from 53° to 33° at 1-year follow up.</p> <p><u>Case report 2 (female, 16, Risser 3)</u></p> <p>Thoracic curve was gradually corrected (with exercises) to 29° from a preoperative angle of 43°. Thoracic curve stabilised at 25° at 2-year follow up.</p> <p><u>Case report 3 (female, 15, Risser 4)</u></p> <p>At 6-months follow up, the thoracic curve had corrected to 22° from a preoperative angle of 45°.</p>	For <u>case report 2</u> , 'no evidence of implant related adverse events was present'.

IP overview: Minimally invasive fusionless posterior-approach surgery to correct idiopathic scoliosis in children and young people

© NICE 2023. All rights reserved. Subject to [Notice of rights](#).

First author, date	Efficacy outcomes	Safety outcomes
Stadhouder, 2021	<p>High complication rate (serious complications in 10/20 patients) led to the premature termination of this study.</p> <p>Note that efficacy results were reported on the remaining 50% (10/20) of patients <u>(based on radiographic data)</u>:</p> <p>Mean Cobb angle major curve reduced from 45.4° preoperatively to 31.4° at 2 weeks after surgery (<math>p &lt; 0.001</math>) with no statistically significant change between then and final follow up (31.4°).</p> <p>Mean Cobb angle minor curve reduced from 31.3° preoperatively to 26.1° at 2 weeks after surgery (<math>p = 0.03</math>) with no statistically significant change between then and final follow up (24.2°).</p> <p>No statistically significant change from preoperative lumbar lordosis (<math>17.6^\circ \pm 7.2^\circ</math> to <math>22.5^\circ \pm 8.8^\circ</math>, <math>p = 0.987</math>), thoracic kyphosis (<math>55.4^\circ \pm 1.8^\circ</math> to <math>55.4^\circ \pm 12.3^\circ</math>, <math>p = 0.183</math>) and rotation (<math>10.3^\circ \pm 2.4^\circ</math> to <math>8.8^\circ \pm 3.5^\circ</math>, <math>p = 0.100</math>) to final follow up.</p> <p>In 10 patients with implant in-situ, the mean preoperative SRS-22 questionnaire score improved statistically significantly at 2-year follow up (from <math>2.6 \pm 0.4</math> at baseline to <math>4.3 \pm 0.4</math>, <math>p &lt; 0.0001</math>). Scores for all individual domains (pain, function, self-image, mental health and satisfaction</p>	<p>11 adverse events needing revision/removal were recorded in 50% (10/20) of patients. Events occurred at a mean of 21 months after surgery (range 8 to 50 months). The authors described these adverse events as serious complications:</p> <p><u>Osteolysis</u> of one of the pedicle screws (<math>n = 6</math>) and breakage of screw (in 1); revision was done in 3 and device removed in 4 (including 1 who had a revision).</p> <p><u>Device failure</u></p> <ul style="list-style-type: none"> <li>- breakage of the pedicle screw (<math>n = 1</math>)</li> <li>- failure of the ratchet mechanism (<math>n = 1</math>)</li> <li>- breakage of a screw and the device (<math>n = 1</math>).</li> </ul> <p>Implant was removed in 1 and posterior fusion was done in 2.</p> <p><u>Pain</u> without abnormal radiographic findings (<math>n = 2</math>); the implant was removed in 1 at the patient's request.</p> <p>Culture specimens were obtained during 9 revision procedures, 6 of which were positive for <i>Cutibacterium acnes</i>.</p> <p>Macroscopic and microscopic metal particles were observed in all patients who had revision, around the ratchet and ball-and-socket joints.</p>

IP overview: Minimally invasive fusionless posterior-approach surgery to correct idiopathic scoliosis in children and young people

© NICE 2023. All rights reserved. Subject to [Notice of rights](#).

First author, date	Efficacy outcomes	Safety outcomes
	with management) also changed statistically significantly (p<0.001).	
FDA Submission August-December 2019	<p>Target population : the probable benefit endpoint was defined as Cobb angles 35° or less and no curve progression at 24 months compared with baseline following treatment with MID-C system.</p> <p><u>Expanded target population</u></p> <ul style="list-style-type: none"> <li>• Probable benefit success rate of 84.6% (22/26 patients) at 12 months and 90% (18/20) at 24 months.</li> <li>• Mean major curve correction at 24 months (n=20) was 24° (range: 7 to 37°) at 24 months compared with baseline (mean 45°, range: 40 to 59°). The mean improvement was 47% (range: 20 to 83%).</li> </ul> <p>Insufficient curve correction was identified in 8 patients needing reoperation – 6 of whom subsequently had spinal fusion.</p> <p>Target population</p> <ul style="list-style-type: none"> <li>• Probable benefit success rate of 75% (9/12 patients) at 12 months and 75% (6/8) at 24 months.</li> <li>• Mean major curve correction at 24 months (n=8) was 28° (range: 19 to 37°) at 24 months compared with baseline (mean</li> </ul>	<p>Primary safety endpoint: reoperation performed for any reason at any timepoint and included all serious adverse events.</p> <p>Reoperation rate in all patients 17.9% (45/252)</p> <ul style="list-style-type: none"> <li>• Mean timepoint for postoperative reoperation was 13 months.</li> <li>• 58% (26/45) of reoperations occurred within 12 months.</li> <li>• 13 reoperations occurred between 12 to 24 months and 6 reoperations after 24 months. <ul style="list-style-type: none"> <li>• 2.4% (6/45) reoperations likely attributable to the device</li> <li>• 10.7% (27/45) reoperations likely attributable to the procedure</li> <li>• 4.8% (12/45) were not attributable to the device or procedure</li> </ul> </li> <li>• Reasons for reoperation included: nut loosening (n=5), misplaced screws or migration (n=9), insufficient curve correction (n=8), screw pull-out (n=5), infection (n=8), screw fracture (n=1), rod fracture (n=2) screw dislocation from rod (n=2), unexpected rod movement (n=1),</li> </ul>

IP overview: Minimally invasive fusionless posterior-approach surgery to correct idiopathic scoliosis in children and young people

© NICE 2023. All rights reserved. Subject to [Notice of rights](#).

First author, date	Efficacy outcomes	Safety outcomes
	<p>49°, range: 45 to 59°). The mean improvement was 43% (range: 20 to 58%).</p> <p><u>Quality of life</u>  <u>N=20 patients from prospective study</u>  completed SRS-22 questionnaires at different periods:</p> <ul style="list-style-type: none"> <li>• <u>Function</u>: mean baseline score of 21.5 increased to 22.75 at 2 years.</li> <li>• <u>Pain</u>: mean baseline score of 19.55 increased to 21.5 at 2 years.</li> <li>• <u>Self-Image</u>: mean baseline score of 16.15 increased to 19.94 at 2 years.</li> <li>• <u>Mental Health</u>: mean baseline score of 18.9 improved to 20.31 at 2 years.</li> <li>• <u>Satisfaction with back management</u>: mean baseline score of 5.9 increased to 8.63 at 2 years.</li> </ul> <p><u>Patient satisfaction</u>  A subset of patients in the expanded target population (n=18), and a subset of patients who have had a reoperation procedure for device correction, device replacement, or device removal (n=22) reported overall satisfaction with their treatment.</p>	<p>pain (n=1), additional device distraction (n=1), extender misalignment (n=1) and unspecified device failure (n=1).</p> <p>Reoperation rate in the expanded target population was 12.2% (6/49).</p> <p>Reoperation rate in the target population was 12% (3/25)</p> <p>Other adverse events were only captured in the first 3 months postoperatively in a subset of patients at 4 centres (63/252 patients).</p> <ul style="list-style-type: none"> <li>• 21/63 patients experienced a non-serious adverse event</li> <li>• adverse events included: seroma (n=2), local haematoma (n=1), headaches (n=1), pain (n=13), limited range of motion of the spine (n=3), screw pull-out (n=1), vasovagal syncope (n=2), superficial wound infection (n=1), skin hypersensitivity (n=1), nausea (n=3) and knee hypoesthesia (n=1).</li> </ul> <p>Findings indicate that MID-C shows a higher reoperation rate in the target population (12.2%) than reported in the literature for spinal instrumentation and fusion for AIS (4.1 to 9.9%)</p>

IP overview: Minimally invasive fusionless posterior-approach surgery to correct idiopathic scoliosis in children and young people

© NICE 2023. All rights reserved. Subject to [Notice of rights](#).

## Procedure technique

All studies were phase 2 and phase 3 design studies and used the first version of the device, which is not currently in use. The company informed that the information for use has been updated with revised patient selection criteria and updated surgical technique.

## Efficacy

### Curve correction or improvement in curve

In a prospective cohort study of 20 patients with AIS who were treated with minimally invasive deformity correction without fusion, the device failed in 10 patients. In the remaining 10 patients with the implant in-situ, the Cobb angles statistically significantly reduced at follow up (mean major curve reduced from a baseline 45.4 degrees to 31.4 degrees at 2 weeks and remained at 31.4 degrees at the time of the latest follow up,  $p < 0.001$ ; mean minor curve reduced from a baseline 31.3 degrees to 26.1 degrees at 2 weeks and to 24.2 degrees at the time of the latest follow up,  $p = 0.03$ ; Stadhouders 2021).

In a retrospective case series of 22 patients with AIS curves (with a single curve of between 40 degrees and 60 degrees, Risser grades 2 or above, 13 with Lenke type 1 curves and 9 with type 5 curves) who had minimally invasive deformity correction without fusion (spanning 5 to 6 disc levels), there was curve correction at 2 years to 3 years follow up. The mean major curve statistically significantly improved from 47 degrees (range 40 degrees to 55 degrees) preoperatively to 25 degrees (46% correction,  $p < 0.05$ ) at 2-year follow up. There was a satisfactory result (defined as the mean final Cobb angle of the major curve of 30 degrees or less at final follow up) in 82% (18/22) of patients. The mean minor curve also statistically significantly reduced from 27 degrees to 17 degrees

IP overview: Minimally invasive fusionless posterior-approach surgery to correct idiopathic scoliosis in children and young people

© NICE 2023. All rights reserved. Subject to [Notice of rights](#).



(average 35% correction,  $p < 0.05$ ). The trunk shift was corrected by 1.5 cm (range 0.4 to 4.3 cm; Floman 2020).

In a retrospective cohort study of 45 patients with moderate AIS that was treated with minimally invasive deformity correction without fusion, who were followed up for a minimum of 2 years, the major Cobb angle (of either Lenke type 1 or 5 curve) reduced from baseline and was similar among the 3 groups in varying skeletal maturity stages at final follow up (Risser 0 to 1 stage group from 47.6 degrees to 26.4 degrees; Risser 2 to 3 from 46 degrees to 20.4 degrees; and Risser 4 to 5 from 41.5 degrees to 26.2 degrees respectively; Floman 2021).

In an FDA clinical evaluation, the probable benefit (defined as a Cobb angle of 35 degrees or less and no curve progression at 12 months and 24 months compared with baseline) in the target population ( $n=25$ ) was 75% (9/12). The probable benefit success rate was 85% (22/26) at 12 months and 90% (18/20) at 24 months in the extended target group. Mean major curve correction at 24 months ( $n=8$ ) was 28 degrees (range 19 to 37 degrees) compared with baseline (mean 49 degrees, range 45 to 59 degrees) in the target population. The mean improvement was 43% (range 20 to 58%; FDA 2019).

### **Change in kyphotic or lordotic curves**

In the prospective cohort study of 20 patients, in 10 patients with the implant in-situ, there were no statistically significant changes from baseline at latest follow up in lumbar lordosis (baseline 17.6 degrees to 22.5 degrees,  $p=0.987$ ), thoracic kyphosis (55.4 degrees to 55.4 degrees,  $p=0.183$ ) and in the scoliometer rotation measures (10.3 to 8.8,  $p=0.100$ ; Stadhouder 2021).

In the retrospective case series of 22 patients, for patients with Lenke type 1 patterns, the mean 2D thoracic kyphosis statistically significantly increased from 24 degrees before surgery to 27 degrees after surgery ( $p < 0.05$ ). For patients with

IP overview: Minimally invasive fusionless posterior-approach surgery to correct idiopathic scoliosis in children and young people

Lenke type 5 curves, the mean lumbar lordosis statistically significantly reduced from 47 degrees preoperatively to 42 degrees at final follow up ( $p < 0.05$ ; Floman 2020).

In the retrospective cohort study of 45 patients, thoracic kyphosis increased on average by 7 degrees in the Lenke 1 curves and lumbar lordosis decreased by 4 degrees in the Lenke 5 curves at 2-year follow up (Floman 2021).

### **Coronal plane wedging of the apical vertebra**

In the retrospective cohort study of 45 patients, preoperative coronal plane wedging of the apical vertebra was reduced after surgery in the overall cohort (from 7.4 degrees to 5.7 degrees,  $p < 0.05$ ). A subgroup analysis among the 3 groups at varying stages of skeletal maturity at final follow up showed a statistically significant reduction in vertebral wedging (Risser 0 to 1 stage group [ $n=16$ ] reduced from 9.5 degrees to 5.4 degrees; Risser 2 to 3 group [ $n=15$ ] reduced from 7.7 degrees to 7.0 degrees; and Risser 4 to 5 group [ $n=14$ ] reduced from 4.8 degrees to 4.7 degrees respectively; Floman 2021).

### **PROMs**

In the prospective cohort study of 20 patients, in the 10 patients with the implant in-situ, the mean preoperative SRS-22 questionnaire score improved statistically significantly at 2-year follow up (from  $2.6 \pm 0.4$  at baseline to  $4.3 \pm 0.4$ ,  $p < 0.0001$ ). Scores for all individual domains (pain, function, self-image, mental health and satisfaction with management also changed statistically significantly,  $p < 0.001$ ; Stadhouder 2021).

In the retrospective case series of 22 patients, the mean preoperative SRS-22 questionnaire score improved statistically significantly at 2-year follow up (from  $2.74 \pm 0.3$  at baseline to  $4.31 \pm 0.4$ ,  $p < 0.0001$ ). Also, the mean preoperative self-image score change was statistically significant ( $3.14 \pm 0.39$  compared with

4.03 ± 0.41), but it did not meet the MCID of 0.98. Scores for other domains (pain, activity, and mental health) did not change statistically significantly. Patient satisfaction assessed by a questionnaire (score range 1 to 5) showed high satisfaction scores for general satisfaction with the procedure (4.8 out of 5.0), the fact they would they choose the procedure again (4.8 out of 5.0), and that they would recommend it to a friend (4.8 out of 5.0; Floman 2020).

In the FDA submission, the prospective study of 20 patients reported consistent improvement across SRS-22 questionnaire scores from baseline up to 2 years for all 5 domains (intensity of pain, self-image, function or activity, mental health, and satisfaction from treatment). FDA data also showed that there was overall patient satisfaction on an unvalidated survey of 18 patients (FDA submission 2019).

## **Safety**

### **Revision surgery and device failure**

In the prospective case series of 20 patients, 11 adverse events needing revision or removal of the device were reported in 50% (10/20) of patients at an average 21 months after surgery. High complication rates led to the premature termination of this study:

- Osteolysis of 1 of the pedicle screws was reported in 6 cases. Revision was done in 3 and the device was removed in 4 (including 1 who had a revision).
- There was device failure in 3 patients (breakage of the pedicle screw in 1, failure of the ratchet mechanism in 1 and breakage of a screw and the device in 1). The implant was removed in 1 patient and posterior fusion was done in 2 patients.
- There was pain without abnormal radiographic findings in 2 patients. The implant was removed in 1 at the patient's request.

IP overview: Minimally invasive fusionless posterior-approach surgery to correct idiopathic scoliosis in children and young people

Culture specimens were obtained during 9 revision procedures, 6 of which were positive for *Cutibacterium acnes* (formerly known as *Propionibacterium acnes*).

Macroscopic and microscopic metal particles were seen in all patients who had revision, around the ratchet and ball-and-socket joints (Stadhouder 2021).

Revision surgery was done in 18% (4/22) of patients because of nut loosening (n=2), pedicle screw backup (n=1), and device ratchet malfunction (n=1) in the retrospective case series of 22 patients. Nut loosening occurred in 2 patients in the early postoperative period and this was attributed to insufficient torque while tightening the nuts. The ratchet malfunction occurred 3 years after surgery and the implant was removed in this patient. It was retained in the remaining 3 patients (Floman 2020).

Revision surgery was done in 9% (4/45) of patients because of nut loosening (n=1), pedicle screw misplacement (n=1), device ratchet malfunction (n=1) and partial screw pull-out (n=1) in the retrospective cohort study of 45 patients. Re-instrumentation with the implant was done in 3 patients and conversion to VBT was done in 1 patient (Floman 2021).

In the FDA submission, the overall reoperation rate was 18% (45/252) for all patients and 12% for both the target population (3/25) and expanded target population (6/49) with a preoperative curve 40 degrees to 60 degrees. The mean postoperative timepoint of reoperation was 13 months. Reoperation reasons include: nut loosening (n=5), misplaced screws or migration (n=9), insufficient curve correction (n=8), screw pull-out (n=5), infection (n=8), screw fracture (n=1), rod fracture (n=2), screw dislocation from rod (n=2), unexpected rod movement (n=1), pain (n=1), additional device distraction (n=1), extender misalignment (n=1) and unspecified device failure (n=1; FDA submission 2019).

IP overview: Minimally invasive fusionless posterior-approach surgery to correct idiopathic scoliosis in children and young people

© NICE 2023. All rights reserved. Subject to [Notice of rights](#).

### **Anecdotal and theoretical adverse events**

Expert advice was sought from consultants who have been nominated or ratified by their professional Society or Royal College. They were asked if they knew of any other adverse events for this procedure that they had heard about (anecdotal), which were not reported in the literature. They were also asked if they thought there were other adverse events that might possibly occur, even if they have never happened (theoretical).

They listed no anecdotal adverse events or theoretical adverse events.

Three professional expert questionnaires for this procedure were submitted. Find full details of what the professional experts said about the procedure in the [specialist advice questionnaires for this procedure](#).

### **Validity and generalisability**

- Authors of the Floman papers made substantial contribution to design of the device.
- Different versions of the ApiFix device (phase 2 and 3 design without the extender component) were used in the studies. There are no published studies with the current version of the device (phase 4 MID-C System with an extender component).
- Recruitment to the Stadhouter prospective study was terminated early because of high failure rates, so the analysis was based on a small cohort.
- Stadhouter 2021 suggests that the identified curve reduction occurs shortly after the treatment. Further study of the device's benefit throughout its deployment would be beneficial. The presence of metal debris at revision may indicate possible wear debris problems.
- Amount of distraction to achieve curve correction is based on surgeon assessment and was not standardised.

IP overview: Minimally invasive fusionless posterior-approach surgery to correct idiopathic scoliosis in children and young people

© NICE 2023. All rights reserved. Subject to [Notice of rights](#).

- Sample sizes were relatively small across papers and the analyses did not include any patients from the UK.
- Although some variation was observed, similar inclusion criteria were present across studies which are pertinent to this indication.
- Most studies had a mean follow up of between 2 and 3 years so there is a need for long-term outcomes.

## Existing assessments of this procedure

None

## Related NICE guidance

### Interventional procedures

- [NICE interventional procedures guidance 728](#) (2022) on vertebral body tethering for idiopathic scoliosis in children and young people.

### Recommendation

- 1.1 Evidence on the safety of vertebral body tethering for idiopathic scoliosis in children and young people is limited but raises concerns of serious complications. Evidence on its efficacy is inadequate in quality and quantity. Therefore, this procedure should only be used in the context of research. Find out what only in research means on the NICE interventional procedures guidance page.
- 1.2 Further research should include randomised controlled trials or analysis of registry data.
- 1.3 This procedure should only be done in specialist centres by spinal surgeons with specific training in anterior spinal surgery.

IP overview: Minimally invasive fusionless posterior-approach surgery to correct idiopathic scoliosis in children and young people

© NICE 2023. All rights reserved. Subject to [Notice of rights](#).

## Medical technologies

- NICE's medical technologies guidance 18 NICE's medical technologies guidance 18 on [the MAGEC system for spinal lengthening in children with scoliosis](#) (2014, withdrawn 2020).

**April 2020:** This guidance has been withdrawn while the MHRA conducts an investigation into the MAGEC system. The MHRA issued a Medical Device Alert [MDA/2020/011](#) for all MAGEC systems. This is in response to the manufacturer's latest [Field Safety Notice](#) and previous field safety notices for problems that may need early removal of devices and lead to inadequate treatment.

The MHRA is not recommending prophylactic removal of devices but the supply of all MAGEC systems is suspended in the UK while the MHRA investigation is ongoing. The MHRA has set out the following actions:

- Do not implant MAGEC rods in the UK until further notice.
- Identify all patients implanted with a MAGEC System and ensure systems are in place to follow up these patients.

## Ongoing studies

NCT04296903: Post-approval registry study to evaluate the continued safety and probable benefit of the MID-C System for 5 years post-implantation in adolescent idiopathic scoliosis (AIS); N=200, cohort study, Status: recruiting Completion date: 2028.

## Professional societies

- British Association of Spine Surgeons
- Society of British Neurological Surgeons

IP overview: Minimally invasive fusionless posterior-approach surgery to correct idiopathic scoliosis in children and young people

© NICE 2023. All rights reserved. Subject to [Notice of rights](#).

- British Scoliosis Society
- British Scoliosis Research Foundation
- United Kingdom Spinal Societies Board.

## Company engagement

NICE asked companies who manufacture a device potentially relevant to this procedure for information on it. NICE received one completed submission. This was considered by the IP team and any relevant points have been taken into consideration when preparing this overview.

## References

1. Yizhar Floman Y, El-Hawary R, Millgram MA et al. (2020) Surgical management of moderate adolescent idiopathic scoliosis with a fusionless posterior dynamic deformity correction device: interim results with bridging 5–6 disc levels at 2 or more years of follow-up. *J Neurosurg Spine*, 32, 748–754.
2. Floman Y, El-Hawary R, Lonner BS et al. (2021) Vertebral growth modulation by posterior dynamic deformity correction device in skeletally immature patients with moderate adolescent idiopathic scoliosis. *Spine Deformity*, 9, 149–153.
3. Stadhouder A, Holewijn RM, Haanstra TM et al. (2021) High failure rates of a unilateral posterior peri-apical distraction device (ApiFix) for fusionless treatment of adolescent idiopathic scoliosis. *J Bone Joint Surg Am*. 103, 1834–43.
4. Floman Y, Burnei G, Gavrilu S et al. (2015) Surgical management of moderate adolescent idiopathic scoliosis with ApiFix®: a short peri-apical fixation followed by post-operative curve reduction with exercises. *Scoliosis*, 10: 4.
5. FDA submission [Summary of Safety and Probable Benefit \(SSPB\) Template \(fda.gov\)](#) August-December 2019.

IP overview: Minimally invasive fusionless posterior-approach surgery to correct idiopathic scoliosis in children and young people

© NICE 2023. All rights reserved. Subject to [Notice of rights](#).



## Methods

NICE identified studies and reviews relevant to minimally invasive fusionless posterior-approach surgery to correct idiopathic scoliosis in children and young people from the medical literature. The following databases were searched between the date they started to 09.02.2023: MEDLINE, PREMEDLINE, EMBASE, Cochrane Library and other databases. Trial registries and the internet were also searched (see the [literature search strategy](#)). Relevant published studies identified during consultation or resolution that are published after this date may also be considered for inclusion.

The following inclusion criteria were applied to the abstracts identified by the literature search.

- Publication type: clinical studies were included with emphasis on identifying good quality studies. Abstracts were excluded if they did not report clinical outcomes. Reviews, editorials, and laboratory or animal studies, were also excluded and so were conference abstracts, because of the difficulty of appraising study methodology, unless they reported specific adverse events that not available in the published literature.
- Patients with AIS.
- Intervention or test: minimally invasive fusionless deformity correction surgery.
- Outcome: articles were retrieved if the abstract contained information relevant to the safety, efficacy, or both.

If selection criteria could not be determined from the abstracts the full paper was retrieved.

Potentially relevant studies not included in the main evidence summary are listed in the section on [other relevant studies](#).

IP overview: Minimally invasive fusionless posterior-approach surgery to correct idiopathic scoliosis in children and young people

© NICE 2023. All rights reserved. Subject to [Notice of rights](#).

Find out more about [how NICE selects the evidence for the committee](#).

**Table 4 literature search strategy**

Databases	Date searched	Version/files
MEDLINE (Ovid)	09/02/2023	1946 to February 08, 2023
MEDLINE In-Process (Ovid)	09/02/2023	1946 to February 08, 2023
MEDLINE Epubs ahead of print (Ovid)	09/02/2023	February 08, 2023
EMBASE (Ovid)	09/02/2023	1974 to 2023 February 08
EMBASE Conference (Ovid)	09/02/2023	1974 to 2023 February 08
Cochrane Database of Systematic Reviews – CDSR (Cochrane Library)	09/02/2023	Issue 2 of 12, February 2023
Cochrane Central Database of Controlled Trials – CENTRAL (Cochrane Library)	09/02/2023	Issue 2 of 12, February 2023
International HTA database (INAHTA)	09/02/2023	-

The following search strategy was used to identify papers in MEDLINE. A similar strategy was used to identify papers in other databases.

### **MEDLINE search strategy**

The MEDLINE search strategy was translated for use in the other sources.

- 1 Scoliosis/ 20124
- 2 scoliosis.tw. 19986
- 3 (Skeletal\* adj4 immatur\*).tw. 1864
- 4 or/1-3 26245
- 5 (Self adj4 adjust\* adj4 rod\*).tw. 0
- 6 (Fusionless or (Non adj4 fusion\*)).tw,kw.1669
- 7 (Deform\* adj4 correct\* adj4 (surger\* or device\* or system\*)).tw. 754
- 8 ((Posterior adj4 dynamic adj4 deformity adj4 correction) or PDDC).tw,kw. 22
- 9 (motion adj4 sparing adj4 posterior adj4 device).tw. 1
- 10 or/5-9 2437
- 11 4 and 10 347
- 12 ((Minimally adj4 Invasive adj4 Deformity adj4 Correction adj4 system) or MIDCS).tw. 1
- 13 (MID-C adj4 (correction or system)).tw. 1
- 14 ApiFix.tw. 3
- 15 or/11-14 348

IP overview: Minimally invasive fusionless posterior-approach surgery to correct idiopathic scoliosis in children and young people

© NICE 2023. All rights reserved. Subject to [Notice of rights](#).

16 Animals/ not Humans/ 5004195  
17 15 not 16 305  
18 limit 17 to ed=20220721-20230209 15

IP overview: Minimally invasive fusionless posterior-approach surgery to correct idiopathic scoliosis in children and young people

© NICE 2023. All rights reserved. Subject to [Notice of rights](#).

## Other relevant studies

Other potentially relevant studies to the IP overview that were not included in the main evidence summary (tables 2 and 3) are listed in table 5.

**Table 5 additional studies identified**

Article	Number of patients and follow up	Direction of conclusions	Reason study was not included in main evidence summary
Cheung ZB, Selverian S, Cho, BH et al. (2019) Idiopathic Scoliosis in Children and Adolescents: Emerging Techniques in Surgical Treatment. World Neurosurgery, 130: e737-e742,	Review of emerging techniques in the surgical treatment of idiopathic scoliosis in children and adolescents.	Major developments in the surgical techniques for idiopathic scoliosis have included robotic-assisted pedicle screw placement, vertebral body stapling, VBT, magnetically controlled growing rods, ApiFix and sublaminar polyester bands. Such growth-modulating fusionless surgical techniques have received increasing attention in recent years, especially for the younger scoliosis population with significant growth potential remaining.	Review
Arnin U, El-Hawary R, Betz, RR et al. (2019) Preclinical Bench Testing on a	Preclinical testing of a distractible PDDC device for	The features of the MID-C system, based on polyaxial joints and ceramic	In-vivo study

IP overview: Minimally invasive fusionless posterior-approach surgery to correct idiopathic scoliosis in children and young people

<p>Novel Posterior Dynamic Deformity Correction Device for Scoliosis. Spine Deformity 7, 203-212.</p>	<p>the treatment of AIS.</p>	<p>coating, resulted in favourable static, fatigue, and wear resistance properties. Wear properties were superior to those published for artificial spinal discs. Long-term outcomes from clinical use will be needed to correlate these bench tests to the in vivo reality of clinical use.</p>	
---	------------------------------	--	--

IP overview: Minimally invasive fusionless posterior-approach surgery to correct idiopathic scoliosis in children and young people

© NICE 2023. All rights reserved. Subject to [Notice of rights](#).