

Prostate Cancer: Diagnosis and management

[F] Evidence reviews for identifying prostate cancer clinical progression in people with low - intermediate risk cancer

NICE guideline <number>

Evidence reviews

[Month Year]

Draft for Consultation

*These evidence reviews were developed
by the NICE Guideline Updates Team*

Disclaimer

The recommendations in this guideline represent the view of NICE, arrived at after careful consideration of the evidence available. When exercising their judgement, professionals are expected to take this guideline fully into account, alongside the individual needs, preferences and values of their patients or service users. The recommendations in this guideline are not mandatory and the guideline does not override the responsibility of healthcare professionals to make decisions appropriate to the circumstances of the individual patient, in consultation with the patient and/or their carer or guardian.

Local commissioners and/or providers have a responsibility to enable the guideline to be applied when individual health professionals and their patients or service users wish to use it. They should do so in the context of local and national priorities for funding and developing services, and in light of their duties to have due regard to the need to eliminate unlawful discrimination, to advance equality of opportunity and to reduce health inequalities. Nothing in this guideline should be interpreted in a way that would be inconsistent with compliance with those duties.

NICE guidelines cover health and care in England. Decisions on how they apply in other UK countries are made by ministers in the [Welsh Government](#), [Scottish Government](#), and [Northern Ireland Executive](#). All NICE guidance is subject to regular review and may be updated or withdrawn.

Copyright

© National Institute for Health and Care Excellence, 2018. All rights reserved.

ISBN:

Contents

RQ3 identifying prostate cancer clinical progression in people with low - intermediate risk cancer	6
Review question	6
Introduction	6
Methods and process	7
Clinical evidence	7
Summary of clinical studies included in the evidence review	9
Quality assessment of clinical studies included in the evidence review	12
Economic evidence	12
Summary of studies included in the economic evidence review.....	12
Economic model.....	13
Evidence statements	13
Recommendations	15
Research recommendations.....	15
Rationale and impact.....	16
The committee’s discussion of the evidence.....	16
Appendices	19
Appendix A – Review protocols	19
Review protocol for identifying prostate cancer clinical progression in people with low - intermediate risk cancer	19
Appendix B – Methods	25
Evidence of effectiveness of interventions	25
Diagnostic test accuracy evidence.....	25
Evidence statements	26
Quality assessment	26
Methods for combining diagnostic test accuracy evidence	27
Modified GRADE for diagnostic test accuracy evidence	27
Publication bias	28
Methods for combining inter-rater agreement evidence	29
Modified GRADE for inter-rater agreement evidence.....	29
Appendix C – Literature search strategies	30
Search summary	30
Clinical searches	30
Study design filters and limits	31
Appendix D – Clinical evidence study selection	32
Clinical evidence –	32
Economic evidence –	33
Appendix E – evidence tables	34

Clinical evidence tables	34
Economic evidence	41
Appendix F – Forest plots.....	Error! Bookmark not defined.
Identifying prostate cancer clinical progression in people with low - intermediate risk cancer	Error! Bookmark not defined.
Appendix G – GRADE tables.....	43
Identifying prostate cancer clinical progression in people with low - intermediate risk cancer	43
Appendix H – Excluded studies	46
Clinical studies	46
Economic studies	60
Appendix I – References	63
Clinical studies - included	63
Clinical studies – excluded	63
Economic study - included.....	81
Economic studies - excluded	81
Appendix J – Research recommendations	82

1 RQ3 identifying prostate cancer clinical 2 progression in people with low - 3 intermediate risk cancer

Review question

- 5 • Which of the following, alone or in combination, constitutes the most clinically
6 and cost- effective pathway for excluding the clinically significant progression
7 of prostate cancer in people with low to intermediate risk (as defined in NICE
8 CG175): Multiparametric/ functional MRI, TRUS biopsy, Transperineal
9 template biopsy?

1 Introduction

11 Following histological diagnosis of prostate cancer, the biochemical, clinical,
12 histological features are combined, often with imaging features, to assess the risk
13 that the cancer poses to the person's health. Many cancers are deemed low or
14 intermediate risk, and the treatment of the cancer with radiotherapy or surgery may
15 be, in the short term at least, more potentially harmful than a surveillance strategy.

16 This review question set out to determine which tests are the most effective in
17 monitoring those on active surveillance, balancing the need for early detection of
18 disease progression and intervention against the morbidity and anxiety of repeated
19 biopsy.

20 The diagnostic accuracy of multiparametric MRI (mpMRI) alone, TRUS biopsy alone
21 and mpMRI influenced biopsy were compared, using transperineal template biopsy
22 and radical prostatectomy samples as reference standards.

23 This review identified studies that fulfilled the conditions specified in Table 1. For full
24 details of the review protocol, see appendix A.

25 **Table 1: PICO for identifying prostate cancer clinical progression in people**
26 **with low-intermediate risk cancer**

Population	<ul style="list-style-type: none"> • People with low to intermediate risk prostate cancer
Index tests	<ul style="list-style-type: none"> • Multiparametric MRI • MRI influenced TRUS biopsy (MRI-targeted and MRI-guided TRUS biopsy) TRUS biopsy alone (systematic or standard) <p><i>TRUS biopsy also referred to as saturation or extended biopsy</i></p>
Reference standard	<ul style="list-style-type: none"> • Transperineal template biopsy • TRUS biopsy • Radical prostatectomy
Outcomes	<ul style="list-style-type: none"> • Diagnostic accuracy <ul style="list-style-type: none"> ○ Sensitivity and specificity ○ Likelihood ratios <p><i>If available from studies reporting diagnostic accuracy we will also extract information on:</i></p> • Number of Adverse events

	<ul style="list-style-type: none">○ Haemorrhage○ Sepsis○ Failure to diagnose○ Pain○ Sexual dysfunction○ Urine retention○ Hospitalisation○ Prostatitis● Missed higher grade cancers● Health-related quality of life<ul style="list-style-type: none">○ psychological aspects of quality of life to be reported separately if possible
--	---

Methods and process

- 2 This evidence review was developed using the methods and process described in
3 [Developing NICE guidelines: the manual](#). Methods specific to this review question
4 are described in the review protocol in appendix A, and the methods section in
5 appendix B.
- 6 The search strategies used in this review are detailed in appendix C.
- 7 Declarations of interest were recorded according to [NICE's 2014 conflicts of interest](#)
8 [policy](#).

Clinical evidence

Included studies

- 11 This review was conducted as part of a larger update of the [NICE Prostate Cancer](#)
12 [guideline \(CG175\)](#).
- 13 A systematic literature search for diagnostic cross-sectional studies and systematic
14 reviews of diagnostic cross-sectional studies with a date limit of no earlier than 2007
15 yielded 5,716 references. These were screened on title and abstract, with 150 full-
16 text papers ordered as potentially relevant diagnostic cross-sectional studies or
17 systematic reviews of diagnostic cross-sectional studies.
- 18 Diagnostic cross-sectional studies were excluded if they did not meet the criteria of
19 enrolling patients diagnosed with low- to intermediate prostate cancer and if they did
20 not include the index tests and the reference standards as specified in the protocol.
21 Studies were further excluded at data extraction if it was not possible to calculate
22 sensitivity and specificity or if the study did not meet any of the other criteria in the
23 protocol.
- 24 Five papers were included after full text screening.
- 25 A second set of searches was conducted at the end of the guideline development
26 process for all updated review questions using the original search strategies, to
27 capture papers published whilst the guideline was being developed. These searches,
28 which included articles up to August 2018, returned 917 references for this review
29 question. These were screened on title and abstract and no additional relevant
30 references was found.

- 1 For the evidence tables, GRADE profiles and full references for included studies,
- 2 please see appendix E, F and appendix H.

Excluded studies

- 4 Details of the studies excluded at full-text review are given in appendix H along with a
- 5 reason for their exclusion. Full references are listed in Appendix I

6

Summary of clinical studies included in the evidence review

2 Table 2: Summary of studies identifying prostate cancer clinical progression in people who have low-intermediate risk

Study (year)	Study Period	N	Time on Active surveillance	Index test	Reference Standard	MRI Scoring	MRI Protocol	+ve MRI	Patients were reclassified if the following
Barzell (2012) USA	Between 2002 and 2009	77	3 months	Repeat TRUS Biopsy	Systematic template prostate mapping biopsy using brachytherapy grid under general anaesthesia.	n/a	n/a	n/a	1. UCL definition 1: Gleason $\geq 4+3$ and/or maximum cancer core length (CCLmax) ≥ 6 mm 2. UCL definition 2: Gleason $\geq 3+4$ and/or CCLmax ≥ 4 mm 3. Epstein 1 4. Epstein 2
Chen (2017) Singapore	Not reported	19	Not reported	MRI targeted biopsy	Robotic transperineal template biopsy	“PIRADS v1 2014 onwards used the PIRADS v2 “	Included - ‘3Tesla scanner - multi channel phased channel array coil - T2 weighted images in the axial, coronal and sagittal planes - Diffusion weighted imaging in the axial plane (b values 0-50, 500 and 1000s/mm ²) and DCE images	≥ 3	Gleason component Grade 4 or higher grade

Study (year)	Study Period	N	Time on Active surveillance	Index test	Reference Standard	MRI Scoring	MRI Protocol	+ve MRI	Patients were reclassified if the following
Da Rosa (2015) Canada	March 2011 to December 2012	81	Median (IQR) 38 months (0.9-162)	MRI ultrasound fusion	TRUS Biopsy	Likert Scale	3Tesla MRI imaging system without an endorectal coil. A six channel cardiac surface coil was positioned over the pelvis. Multiparametric MRI combining axial, sagittal and coronal t2-weighted, diffusion weighted , b values 100, 400, 1000 slice thickness 3 mm	≥4	Any cancer of Gleason score ≥7 - Gleason score = 6 with >50% involvement in any one core
Feng (2015) USA	January 2010 to July 2013	342	Not reported	mpMRI	Radical Prostatectomy	PIRADS	Imaging using 3.0T MRI system equipped with a 12-channel pelvic phased array coil. Anatomic images included T1- and T2 weighted turbo spin echo, acquired in the axial, sagittal and coronal planes. Diffusion weighted imaging was acquired using a standard single-shot echo planar imaging sequence. The orthogonal diffusion directions including a single b0	3 – 10uspicious Extracapsular Extension (ECE) 4 and 5-definite ECE	Presence of extracapsular extension disease – Defined as presence of tumour beyond the confines of the prostate

DRAFT FOR CONSULTATION

RQ3 identifying prostate cancer clinical progression in people with low - intermediate risk cancer

Study (year)	Study Period	N	Time on Active surveillance	Index test	Reference Standard	MRI Scoring	MRI Protocol	+ve MRI	Patients were reclassified if the following
							measurement were acquired at 2 nonzero b values 400 and 800s/mm2		
Pessoa (2017) Brazil	March 2014 to January 2016	105	Max 6 months	MRI targeted biopsy	12 core systematic biopsy	PIRADS v1	mpMRI images were evaluated using axial-oblique, fast spin-echo T2 –weighted, diffusion weighted imaging and dynamic contrast enhanced – MRI or a 16 channel cardiac surface external 3.0T MRI system.	≥2	If the confirmatory biopsy established significant cancer and was determined as any fragment with Gleason ≥7, more than three fragments positive for prostate cancer, or a highest tumour volume in any core >50%

1

1 See appendix E for full evidence tables.

Quality assessment of clinical studies included in the evidence review

3 See appendix G for full GRADE tables.

Economic evidence

5 Standard health economics filters were applied to the clinical search strategy for this
6 review question. In total, 802 references were returned, of which 790 could be
7 confidently excluded on screening of titles and abstracts. The remaining 12 studies
8 were reviewed in full text, and all of them were found not to be relevant.

9 An additional study was identified by the committee and found to be relevant.

Included studies

11 The role of multiparametric magnetic resonance imaging in active surveillance for
12 men with low-risk prostate cancer: A cost-effectiveness modelling study, by Patel et
13 al. (2018)

Excluded studies

15 Details of studies excluded after consideration at the full-text stage are provided in
16 appendix H.

Summary of studies included in the economic evidence review

18 Patel et al. (2018) developed a probabilistic lifetime Markov model with yearly cycles
19 to accumulate the cost, adopting the healthcare perspective and using the € of year
20 2016, and health outcomes, measured by quality adjusted life years (QALYs), of 3
21 strategies to follow-up people with low-risk prostate cancer. The strategies were:

- 22 • Trans-rectal ultrasound (TRUS) guided biopsy every 3 years;
- 23 • Multi-parametric magnetic resonance imaging (Mp-MRI), and if positive,
24 TRUS guided biopsy every 3 years;
- 25 • Mp-MRI only every 3 years.

26 The model consisted of 5 health states:

- 27 • Low-risk disease;
- 28 • Low-risk post-treatment;
- 29 • High-risk disease;
- 30 • High-risk post-treatment;
- 31 • Death due to prostate cancer or any other cause death.

32 Low-risk prostate cancer was defined as prostate serum antigen (PSA) ≤ 10 ; Gleason
33 score ≤ 6 . High-risk disease was defined as having Gleason score ≥ 7 . The accuracy
34 data of the tests and the health-related utility data were obtained from existing
35 literature. The authors applied decrement in utility caused by TRUS and by adverse
36 events associated with prostate cancer treatments. They found that the strategy,
37 where people with low-risk disease received Mp-MRI, and if positive, followed by
38 TRUS, was associated with greater QALYs and less costs than the other two
39 strategies.

Economic model

2 This question was not prioritised for economic modelling.

Evidence statements

4 The evidence statements in these sections are written with reference to the size of
5 the likelihood ratios in the GRADE tables in appendix G, using the interpretation
6 detailed in the methods section on diagnostic test accuracy ([Table 4](#)).

7 Clinical evidence statements

8 Evidence on **TRUS biopsy**

- 9 • *Results that indicate a person suspected of prostate cancer has an increased*
10 *probability of clinically significant disease (based on positive likelihood ratios):*
- 11 ○ A positive TRUS biopsy leads to a **slight increase** in the probability that a
12 person diagnosed with low- or intermediate-risk prostate cancer has clinically
13 significant disease (Very low-quality evidence from 1 prospective study
14 comprising 124 participants; 95% confidence intervals range from moderate
15 decrease to large increase).
- 16 • *Results that indicate a person suspected of prostate cancer has a decreased*
17 *probability of clinically significant disease (based on negative likelihood ratios):*
- 18 ○ A negative TRUS biopsy **does not alter the probability** that a person
19 diagnosed with low- or intermediate-risk prostate cancer has clinically
20 significant disease (Moderate-quality evidence from 1 prospective study
21 comprising 124 participants; 95% confidence intervals range from slight
22 decrease to slight increase).

23 Evidence on **MRI-influenced biopsy**

- 24 • *Results that indicate a person suspected of prostate cancer has an increased*
25 *probability of clinically significant disease (based on positive likelihood ratios):*
- 26 ○ A positive MRI-influenced biopsy has **no diagnostic value** in determining
27 clinically significant cancer in a person diagnosed with low risk prostate cancer
28 within 8 weeks of initial prostate biopsy (High quality evidence from 1 cross-
29 sectional study comprising 19 participants)
- 30 ○ A positive MRI-influenced biopsy leads to a **moderate increase** in the
31 probability of clinically significant cancer in a person diagnosed with low risk
32 prostate cancer within 6 months of initial prostate biopsy (High quality
33 evidence from 1 cross-sectional study comprising 87 participants, 95%
34 confidence intervals ranged from slight increase to moderate increase)
- 35 • *Results that indicate a person suspected of prostate cancer has a decreased*
36 *probability of clinically significant disease (based on negative likelihood ratios):*
- 37 ○ A negative MRI-influenced biopsy has **no diagnostic value** in determining
38 clinically significant cancer in a person diagnosed with low risk prostate cancer
39 within 8 weeks of initial prostate biopsy (High quality evidence from 1 cross-
40 sectional study comprising 19 participants)
- 41 ○ A negative MRI-influenced biopsy leads to a **moderate decrease** in the
42 probability of clinically significant cancer in a person diagnosed with low risk
43 prostate cancer within 6 months of initial prostate biopsy (High quality
44 evidence from 1 cross-sectional study comprising 87 participants, 95%
45 confidence intervals ranged from slight decrease to moderate decrease
46 moderate decrease to large decrease)

1 Evidence on **MRI/TRUS fusion biopsy**

- 2 • *Results that indicate a person suspected of prostate cancer has an increased*
3 *probability of clinically significant disease (based on positive likelihood ratios):*
 - 4 ○ A positive MRI/TRUS fusion biopsy leads to a **large increase** in the probability
5 of clinically significant cancer (defined as any cancer of Gleason score 7 or
6 greater) in a person on active surveillance for 38 months (range 0.9-
7 134.7months) (High quality evidence from 1 cross-sectional study comprising
8 72 participants, 95% confidence intervals ranged from moderate increase to
9 large increase)
 - 10 ○ A positive MRI/TRUS fusion biopsy leads to a **moderate increase** in the
11 probability of clinically significant cancer (defined as cancer of Gleason score 6
12 with greater than 50% involvement in any core) in a person on active
13 surveillance for 38 months (range 0.9-134.7months) (Moderate quality
14 evidence from 1 cross-sectional study comprising 72 participants, 95%
15 confidence intervals ranged from moderate increase to large increase)
- 16 • *Results that indicate a person suspected of prostate cancer has a decreased*
17 *probability of clinically significant disease (based on negative likelihood ratios)*
 - 18 ○ A negative MRI/TRUS fusion biopsy **does not alter the probability** of clinically
19 significant cancer (defined as any cancer of Gleason score 7 or greater) in a
20 person on active surveillance for 38 months (range 0.9-134.7months)
21 (Moderate quality evidence from 1 cross-sectional study comprising 72
22 participants, 95% confidence intervals ranged from slight decrease to very
23 large decrease)
 - 24 ○ A negative MRI/TRUS fusion biopsy leads to a **moderate decrease** in the
25 probability of clinically significant cancer (defined as cancer of Gleason score 6
26 with greater than 50% involvement in any core) in a person on active
27 surveillance for 38 months (range 0.9-134.7months) (Moderate quality
28 evidence from 1 cross-sectional study comprising 72 participants, 95%
29 confidence intervals ranged from slight decrease to large decrease)

30 Evidence on **multiparametric MRI**

- 31 • *Results that indicate a person suspected of prostate cancer has an increased*
32 *probability of clinically significant disease (based on positive likelihood ratios):*
 - 33 ○ A multiparametric MRI PIRADS score ≥ 4 leads to a **moderate increase** in the
34 probability of clinically significant cancer in a person diagnosed with low risk
35 prostate cancer within 6 months of initial prostate biopsy (High quality evidence
36 from 1 prospective study comprising 105 participants; 95% confidence intervals
37 range from moderate increase to large increase).
 - 38 ○ A multiparametric MRI PIRADS score ≥ 4 leads to a **very large increase** in
39 the probability of clinical progression (defined as definite extracapsular
40 extension) in a person diagnosed with low risk prostate cancer (High quality
41 evidence from 1 cross-sectional studies comprising 112 participants, 95%
42 confidence intervals ranged from moderate increase to very large increase)
 - 43 ○ A multiparametric MRI PIRADS score ≥ 3 leads to a **large increase** in the
44 probability of clinically significant cancer (defined as suspicious/definite
45 extracapsular extension) in a person diagnosed with low risk prostate cancer
46 (High quality evidence from 1 cross-sectional studies comprising 112
47 participants, 95% confidence intervals ranged from moderate increase to very
48 large increase)

49

- 1 • *Results that indicate a person suspected of prostate cancer has a decreased*
 2 *probability of clinically significant disease (based on negative likelihood ratios*
 3 ○ A multiparametric MRI PIRADS score < 4 leads to a **very large decrease** in
 4 the probability of clinically significant cancer in a person diagnosed with low
 5 risk prostate cancer within 6 months of initial prostate biopsy (High quality
 6 evidence from 1 cross-sectional study comprising 105 participants, 95%
 7 confidence intervals ranged from large decrease to very large decrease)
 8 ○ A multiparametric MRI PIRADS score < 4 **does not meaningfully alter** the
 9 probability of clinical progression (defined as definite extracapsular extension)
 10 in a person diagnosed with low risk prostate cancer (Moderate quality evidence
 11 from 1 cross-sectional studies comprising 112 participants, 95% confidence
 12 intervals ranged from slight decrease to moderate decrease)
 13 ○ A multiparametric MRI PIRADS score <3 leads to a **moderate decrease** in the
 14 probability of clinical progression (defined as suspicious/definite extracapsular
 15 extension) in a person diagnosed with low risk prostate cancer (Moderate
 16 quality evidence from 1 cross-sectional studies comprising 112 participants,
 17 95% confidence intervals ranged from slight decrease to large decrease)

1Recommendations

19 F1. Offer multiparametric MRI to people having active surveillance who have not had
 20 an MRI previously. If the MRI results do not agree with the biopsy findings, offer a
 21 new MRI-influenced biopsy. [2019]

22 F2. Consider using the protocol in Table 3 for people who have chosen active
 23 surveillance. [2019]

24 Table 3 Protocol for active surveillance

Timing	Tests ¹
Year 1 of active surveillance	Every 3–4 months: measure PSA ² Throughout active surveillance: monitor PSA kinetics ³ At 12 months: DRE ⁴ At 12-18 months: multiparametric MRI
Year 2 and every year thereafter until active surveillance ends	Every 6 months: measure PSA ² Throughout active surveillance: monitor PSA kinetics ³ Every 12 months: DRE ⁴
¹ If there is concern about clinical or PSA changes at any time during active surveillance, reassess with multiparametric MRI and/or re-biopsy. ² Could be carried out in primary care if there are agreed shared-care protocols and recall systems. ³ Could include PSA density and velocity. ⁴ Should be performed by a healthcare professional with expertise and confidence in performing digital rectal examination.	

2Research recommendations

26 What is the most clinically and cost effective pathway of excluding the clinically
 27 significant progression of prostate cancer in people with low to intermediate risk.

Rationale and impact

Why the committee made the recommendations

3 The committee made recommendations based on a good body of evidence that
4 multiparametric MRI can be used as part of an active surveillance protocol to identify
5 clinically significant cancer, and/or restage prostate cancer after diagnosis. The
6 committee considered the benefits observed in using multi-parametric MRI pre-
7 biopsy in people who are biopsy naïve and who have suspected prostate cancer and
8 concluded that this benefit can be extended to those enrolled on active surveillance
9 without a prior MRI to allow for confirmation or reclassification of the prostate cancer.

10 The committee amended the existing protocol for active surveillance based on their
11 expertise and good evidence on which PSA kinetics to monitor and the use of
12 multiparametric MRI to identify clinically significant prostate cancer.

13 Because of the limited evidence on the most effective pathway for excluding clinically
14 significant progression of prostate cancer in people with low to intermediate risk the
15 committee made research recommendations in this area. They also identified that
16 there was a gap in the evidence on the most suitable surveillance protocol for this
17 population group.

How the recommendations might affect practice

19 The use of multiparametric MRI in people who are enrolled on active surveillance will
20 influence active surveillance protocols across the country. This will have a substantial
21 impact on resources in the interim as people who have never had a multiparametric
22 MRI will now be referred for one as part of the new pathway. Multiparametric MRI is
23 clinically and cost effective as significant cancers are more likely to be identified,
24 therefore decisions on treatment can be made earlier in the diagnosis pathway
25 saving on future treatment costs.

The committee's discussion of the evidence

Interpreting the evidence

The outcomes that matter most

29 The committee agreed that the critical outcome was whether or not the index tests
30 could exclude or identify clinical progression of prostate cancer in people on active
31 surveillance for at least 2 years as expressed by likelihood ratios. The majority of the
32 evidence presented was from studies whose follow up was less than a year and
33 therefore it was highly unlikely that the disease would have progressed within the
34 short follow up period. The committee agreed that in studies with short follow up, any
35 changes in the severity of the cancer were likely to be because it was misclassified at
36 diagnosis rather than because the cancer had progressed.

The quality of the evidence

38 All 5 included studies were at either low or moderate risk of bias because they met
39 most of the elements of a good diagnostic cross-sectional study as assessed using
40 the QUADAS tool. None of the included studies were from the United Kingdom. The
41 studies had very small sample sizes ranging from 18 participants (Chen et al. 2017)
42 to 124 participants (Barzel et al. 2012).

- 1 The committee agreed that the evidence partially addressed the review question as
2 two of the studies addressed restaging of prostate after a few weeks or months of
3 diagnosis (Barzel et al. 2012; Chen et al. 2017; Pessoa et al. 2017) and not clinical
4 progression as investigated by Da Rosa et al. (2015) and Feng et al. (2015).
- 5 All the studies included participants diagnosed with low risk prostate cancer apart
6 from Feng et al. (2017) who only described participants as “on active surveillance”.
7 None of the study participants had ever had an MRI prior to initial diagnosis.
- 8 None of the studies could be meta-analysed because they were all different in terms
9 of index test investigated, reference standard used and definitions of restaging or
10 reclassification criteria.
- 11 Overall, when the evidence was assessed using GRADE, the evidence ranged from
12 very low to high quality. In cases where the study was very low quality this was due
13 to moderate risk of bias of the study and imprecise 95% confidence intervals.

1 Benefits and harms

- 15 The committee reflected on the evidence from [evidence review D](#) and [evidence review E](#) in this update investigating multiparametric MRI in biopsy naïve people who
16 are suspected of prostate cancer and people with at least one negative TRUS biopsy
17 respectively.
18
- 19 In [evidence review D](#) the committee made recommendations for clinicians to offer
20 multiparametric MRI as the first-line investigation to people with suspected clinically
21 localised prostate cancer. This was based on 3 studies of which two were from the
22 UK (PROMIS (Ahmed et al. 2017); PRECISION (Kasivisvanathan et al. 2018), and
23 Porpiglia et al. 2017). The committee discussed that as a result of these
24 recommendations, anyone suspected of prostate cancer will be offered
25 multiparametric MRI; however they understood that, there will be a cohort of people
26 who received a diagnosis based on prostate biopsy alone. Some of these people
27 may be on active surveillance.
- 28 The committee acknowledged that there is strong evidence (from the PROMIS and
29 PRECISION studies presented in [evidence review D](#)), on the efficacy of
30 multiparametric MRI in identifying lesions and this evidence could be extended to be
31 part of the monitoring pathway for those people who are on active surveillance.
- 32 Evidence from Pessoa et al. (2017) showed that a positive multiparametric MRI
33 influenced biopsy leads to a moderate increase in the probability of clinically
34 significant cancer in a person diagnosed with low risk cancer within 6 months,
35 resulting in restaging or reclassification of the disease. Evidence from Chen et al.
36 (2017) showed that there is no diagnostic value in carrying out the same investigation
37 in those diagnosed with low risk prostate cancer 8 weeks prior. The participants in
38 both studies had not had a pre-biopsy MRI.
- 39 Based on all the evidence described above, the committee made a “strong”
40 recommendation to offer multiparametric MRI to those people who are enrolled for
41 active surveillance and have not had a pre-biopsy MRI. The committee agreed that
42 multiparametric MRI should be used to either confirm or restage disease in people
43 initially diagnosed with low risk prostate cancer on prostate biopsy alone.
- 44 Based on the evidence, the committee recommended clinicians consider
45 multiparametric MRI in those people who have been on active surveillance and have
46 not had a multiparametric MRI before. Evidence from Feng et al. (2015) showed that
47 a positive multiparametric MRI score (defined as PIRADS score ≥ 3 and >4) has good

1 diagnostic value leading to a large or very large increase in the probability of
2 identifying clinical progression in people on active surveillance. The evidence from
3 Da Rosa (2015) also contributed to the evidence for this recommendation as the
4 study showed that a positive MRI/TRUS fusion biopsy leads to a large increase in the
5 probability of clinically significant cancer (defined as any cancer of Gleason score 7
6 or greater) in a person on active surveillance for 38 months. Both study populations
7 had not had a pre biopsy MRI prior to being on active surveillance.

8 The committee also noted that there is a UK study currently underway that will be
9 able to provide evidence to support this review question. However, the completion
10 date and likely publication date is unknown at the time of this review.

11 The committee considered the evidence from [evidence review E: 'Managing people
12 at risk'](#) to help amend the suggested active surveillance protocol ([table x](#)). They
13 suggested that clinicians should monitor PSA kinetics namely PSA density and PSA
14 velocity because the evidence from [review E](#) showed these tests had the best
15 balance between identifying and excluding prostate cancer.

16 Cost effectiveness and resource use

17 The committee reviewed the included economic evidence. It agreed that the included
18 cost-utility analysis provided partially applicable evidence as it was based on a non-
19 UK study. The committee noted some limitations of the analyses, particularly that the
20 MRI-influenced biopsy every three years was not compared to regimens with
21 different frequencies. In addition, it noted that any biopsy procedures should be
22 triggered by positive findings on screening tests, e.g. PSA density.

23 The committee agreed that the economic evidence provided by Patel et al. (2018)
24 was not sufficient to influence the recommendations made based on the clinical
25 evidence. It confirmed the positive role of the use of MRI to make prostate biopsy
26 more efficient and this would not have a significant resource impact. Thus, the
27 committee concluded that the clinical evidence is sufficient to underpin its
28 recommendation about considering the MRI-influenced prostate biopsy for people on
29 active surveillance showing positive findings on PSA derivatives tests, e.g. PSA
30 density to identify prostate cancer progression.

31

1 Appendices

Appendix A – Review protocols

3 Review protocol for identifying prostate cancer clinical progression in people with low - intermediate risk cancer

ID	Field (based on PRISMA-P)	Content
I	Review question	Which of the following, alone or in combination, constitutes the most clinical and cost-effective pathway for excluding the clinically significant progression of prostate cancer in people with low to intermediate risk (as defined in NICE CG175) <ul style="list-style-type: none"> • Multiparametric/ functional MRI • TRUS biopsy • Transperineal template biopsy?
II	Type of review question	Diagnostic
III	Objective of the review	To determine which of the following is the most effective accurate pathway for excluding the clinically significant progression of prostate cancer in people with low to intermediate risk who are on active surveillance:- Multiparametric/ functional MRI, TRUS biopsy, Transperineal template biopsy, MRI targeted biopsy
IV	Eligibility criteria – population/disease/condition/issue/domain	People with low to intermediate risk prostate cancer (as defined in NICE CG175) <ul style="list-style-type: none"> • Low risk - <10ng/ML PSA and ≤6 Gleason score and T1-T2a clinical stage • Intermediate risk – 10-20ng/m PSA or 7 Gleason score or T2b Clinical stage

		Or as defined by the study
V	Eligibility criteria – Index tests	<ul style="list-style-type: none"> • Biparametric/ Multiparametric MRI • MRI guided TRUS biopsy (MRI-targeted and MRI-guided TRUS biopsy) • TRUS biopsy alone (<i>TRUS biopsy also referred to as saturation or extended biopsy</i>)
VI	Eligibility criteria –reference (gold) standard	<ul style="list-style-type: none"> • Transperineal template biopsy • TRUS biopsy • Radical prostatectomy <i>TRUS biopsy also referred to as saturation or extended biopsy</i>
VII	Outcomes and prioritisation	<p>Diagnostic accuracy</p> <ul style="list-style-type: none"> • Sensitivity and specificity • Likelihood ratios <p>If available from studies reporting diagnostic accuracy we will also extract information on:</p> <ul style="list-style-type: none"> • Adverse events • Health-related quality of life
VIII	Eligibility criteria – study design	<ul style="list-style-type: none"> • Diagnostic cross sectional studies • Systematic reviews of diagnostic cross-sectional studies
IX	Other inclusion exclusion criteria	<ul style="list-style-type: none"> • Non English- language papers • Unable to calculate 2x2 tables
X	Proposed sensitivity/sub-group analysis, or meta-regression	<ul style="list-style-type: none"> • T stage • Gleason score or • PSA levels

XI	Selection process – duplicate screening/selection/analysis	10% of the abstracts will be reviewed by two reviewers, with any disagreements resolved by discussion or, if necessary, a third independent reviewer. If meaningful disagreements are found between the different reviewers, a further 10% of the abstracts will be reviewed by two reviewers, with this process continued until agreement is achieved between the two reviewers. From this point, the remaining abstracts will be screened by a single reviewer.
XII	Data management (software)	See appendix B below – section 1.3
XIII	Information sources – databases and dates	See appendix C of relevant chapter The committee advised that studies on MRI guided biopsy prior to 2007 would not reflect current practice. They advised a date cut off of 2007.
XIV	Identify if an update	Update. This is an update of the 2008 clinical guideline, however the 2008 guideline does not identify a specific clinical question. Related recommendations: 1.3.49 For men with evidence of biochemical relapse following radical treatment and who are considering radical salvage therapy:

		<ul style="list-style-type: none"> • do not offer routine MRI scanning prior to salvage radiotherapy in men with prostate cancer • offer an isotope bone scan if symptoms or PSA trends are suggestive of metastases. [2008]
XV	Author contacts	Guideline updates team, National Institute for Health and Care Excellence (contact adam.okeefe@nice.org.uk)
XVI	Highlight if amendment to previous protocol	For details please see section 4.5 of Developing NICE guidelines: the manual
XVII	Search strategy – for one database	For details please see appendix C of relevant chapter
XVIII	Data collection process – forms/duplicate	A standardised evidence table format will be used, and published as appendix E (clinical evidence tables) or H (economic evidence tables).
XIX	Data items – define all variables to be collected	For details please see evidence tables in appendix E (clinical evidence tables) or H (economic evidence tables).
XX	Methods for assessing bias at outcome/study level	See Appendix B below – see section 1.6.1
XXI	Criteria for quantitative synthesis (where suitable)	See Appendix B below

XXII	Methods for analysis – combining studies and exploring (in)consistency	See Appendix B below – see section 1.6.2
XXIII	Meta-bias assessment – publication bias, selective reporting bias	See Appendix B below – see section 1.6.3 and 1.6.5
XXIV	Assessment of confidence in cumulative evidence	See Appendix B below - see section 1.6.3
XXV	Rationale/context – Current management	For details please see the introduction to the evidence review in the main file.
XXVI	Describe contributions of authors and guarantor	<p>A multidisciplinary committee will develop the guideline update. The committee was convened by the NICE Guideline Updates Team and chaired by Waqaar Shah in line with section 3 of Developing NICE guidelines: the manual.</p> <p>Staff from NICE will undertake systematic literature searches, appraise the evidence, conduct meta-analyses and cost-effectiveness analyses where appropriate, and draft the evidence review in collaboration with the committee. For details please see Developing NICE guidelines: the manual.</p>
XXVI I	Sources of funding/support	The NICE Guideline Updates Team is an internal team within NICE.
XXVI II	Name of sponsor	The NICE Guideline Updates Team is an internal team within NICE.

DRAFT FOR CONSULTATION

RQ3 identifying prostate cancer clinical progression in people with low - intermediate risk cancer

XXIX	Roles of sponsor	The NICE Guideline Updates Team is an internal team within NICE.
XXX	PROSPERO registration number	N/A

1

2

Appendix B – Methods

Evidence of effectiveness of interventions

Diagnostic test accuracy evidence

4 In this guideline, diagnostic test accuracy (DTA) data are classified as any data in which a
5 feature – be it a symptom, a risk factor, a test result or the output of some algorithm that
6 combines many such features – is observed in some people who have the condition of
7 interest at the time of the test and some people who do not. Such data either explicitly
8 provide, or can be manipulated to generate, a 2x2 classification of true positives and false
9 negatives (in people who, according to the reference standard, truly have the condition) and
10 false positives and true negatives (in people who, according to the reference standard, do
11 not).

12 The 'raw' 2x2 data can be summarised in a variety of ways. Those that were used for
13 decision making in this guideline are as follows:

- 14 • **Positive likelihood ratios** describe how many times more likely positive features are in
15 people with the condition compared to people without the condition. Values greater than 1
16 indicate that a positive result makes the condition more likely.
 - 17 ○ $LR^+ = (TP/[TP+FN])/(FP/[FP+TN])$
- 18 • **Negative likelihood ratios** describe how many times less likely negative features are in
19 people with the condition compared to people without the condition. Values less than 1
20 indicate that a negative result makes the condition less likely.
 - 21 ○ $LR^- = (FN/[TP+FN])/(TN/[FP+TN])$
- 22 • **Sensitivity** is the probability that the feature will be positive in a person with the condition.
 - 23 ○ $sensitivity = TP/(TP+FN)$
- 24 • **Specificity** is the probability that the feature will be negative in a person without the
25 condition.
 - 26 ○ $specificity = TN/(FP+TN)$

27 The following schema, adapted from the suggestions of Jaeschke et al. (1994), was used to
28 interpret the likelihood ratio findings from diagnostic test accuracy reviews.

29 **Table 4: Interpretation of likelihood ratios**

Value of likelihood ratio	Interpretation
$LR \leq 0.1$	Very large decrease in probability of disease
$0.1 < LR \leq 0.2$	Large decrease in probability of disease
$0.2 < LR \leq 0.5$	Moderate decrease in probability of disease
$0.5 < LR \leq 1.0$	Slight decrease in probability of disease
$1.0 < LR < 2.0$	Slight increase in probability of disease
$2.0 \leq LR < 5.0$	Moderate increase in probability of disease
$5.0 \leq LR < 10.0$	Large increase in probability of disease
$LR \geq 10.0$	Very large increase in probability of disease

30 The schema above has the effect of setting a minimal important difference for positive
31 likelihoods ratio at 2, and a corresponding minimal important difference for negative

1 likelihood ratios at 0.5. Likelihood ratios (whether positive or negative) falling between these
2 thresholds were judged to indicate no meaningful change in the probability of disease.

3 **Evidence statements**

4 The evidence statements were based on likelihood ratios (a MID for positive likelihoods ratio
5 was set at 2, and a corresponding MID for negative likelihood ratios at 0.5) and these are
6 classified in to one of four categories:

- 7 • Situations where the data are only consistent, at a 95% confidence level, with an
8 effect in one direction (i.e. one that is 'statistically significant'), and the magnitude of
9 that effect is most likely to meet or exceed the MID (i.e. the point estimate is not in the
10 zone of equivalence). In such cases, we state that the index test lead to a moderate,
11 large and very large increase/decrease in probability of disease
- 12 • Situations where the data are only consistent, at a 95% confidence level, with an
13 effect in one direction (i.e. one that is 'statistically significant'), but the magnitude of
14 that effect is most likely to be less than the MID (i.e. the point estimate is in the zone
15 of equivalence). In such cases, we state that the index test could not meaningfully
16 alter the probability of disease.
- 17 • In all other cases, we state that the index test could not alter the probability between
18 the comparators
- 19 • When the likelihood ratios were reversed for example – positive likelihood ratio of 0.1
20 and negative likelihood ratio of 3, we state that the index test has no diagnostic value.

21

22 **Quality assessment**

23 Individual studies were quality assessed using the QUADAS-2 tool, which contains four
24 domains: patient selection, index test, reference standard, and flow and timing. Each
25 individual study was classified into one of the following two groups:

- 26 • Low risk of bias – Evidence of non-serious bias in zero or one domain.
- 27 • Moderate risk of bias – Evidence of non-serious bias in two domains only, or serious bias
28 in one domain only.
- 29 • High risk of bias – Evidence of bias in at least three domains, or of serious bias in at least
30 two domains.

31 Each individual study was also classified into one of three groups for directness, based on if
32 there were concerns about the population, index features and/or reference standard in the
33 study and how directly these variables could address the specified review question. Studies
34 were rated as follows:

- 35 • Direct – No important deviations from the protocol in population, index feature and/or
36 reference standard.
- 37 • Partially indirect – Important deviations from the protocol in one of the population, index
38 feature and/or reference standard.
- 39 • Indirect – Important deviations from the protocol in at least two of the population, index
40 feature and/or reference standard.

1 Methods for combining diagnostic test accuracy evidence

2 Meta-analysis of diagnostic test accuracy data was conducted with reference to the
3 Cochrane Handbook for Systematic Reviews of Diagnostic Test Accuracy (Deeks et al.
4 2010).

5 Where applicable, diagnostic syntheses were stratified by:

- 6 • Presenting symptomatology (features shared by all participants in the study, but not all
7 people who could be considered for a diagnosis in clinical practice).
- 8 • The reference standard used for true diagnosis.

9 Where five or more studies were available for all included strata, a bivariate model was fitted
10 using the `mada` package in R v3.4.0, which accounts for the correlations between positive
11 and negative likelihood ratios, and between sensitivities and specificities. Where sufficient
12 data were not available (2–4 studies), separate independent pooling was performed for
13 positive likelihood ratios, negative likelihood ratios, sensitivity and specificity, using Microsoft
14 Excel. This approach is conservative as it is likely to somewhat underestimate test accuracy,
15 due to failing to account for the correlation and trade-off between sensitivity and specificity
16 (see Deeks 2010).

17 Random-effects models (der Simonian and Laird) were fitted for all syntheses, as
18 recommended in the Cochrane Handbook for Systematic Reviews of Diagnostic Test
19 Accuracy (Deeks et al. 2010).

20 In any meta-analyses where some (but not all) of the data came from studies at high risk of
21 bias, a sensitivity analysis was conducted, excluding those studies from the analysis. Results
22 from both the full and restricted meta-analyses are reported. Similarly, in any meta-analyses
23 where some (but not all) of the data came from indirect studies, a sensitivity analysis was
24 conducted, excluding those studies from the analysis.

25 Modified GRADE for diagnostic test accuracy evidence

26 GRADE has not been developed for use with diagnostic studies; therefore a modified
27 approach was applied using the GRADE framework. GRADE assessments were only
28 undertaken for positive and negative likelihood ratios, as the MIDs used to assess
29 imprecision were based on these outcomes, but results for sensitivity and specificity are also
30 presented alongside those data.

31 Cross-sectional and cohort studies were initially rated as high-quality evidence if well
32 conducted, and then downgraded according to the standard GRADE criteria (risk of bias,
33 inconsistency, imprecision and indirectness) as detailed in Table 5 below.

34 **Table 5: Rationale for downgrading quality of evidence for diagnostic questions**

GRADE criteria	Reasons for downgrading quality
Risk of bias	<p>Not serious: If less than 33.3% of the weight in a meta-analysis came from studies at moderate or high risk of bias, the overall outcome was not downgraded.</p> <p>Serious: If greater than 33.3% of the weight in a meta-analysis came from studies at moderate or high risk of bias, the outcome was downgraded one level.</p> <p>Very serious: If greater than 33.3% of the weight in a meta-analysis came from studies at high risk of bias, the outcome was downgraded two levels.</p>

GRADE criteria	Reasons for downgrading quality
	Outcomes meeting the criteria for downgrading above were not downgraded if there was evidence the effect size was not meaningfully different between studies at high and low risk of bias.
Indirectness	<p>Not serious: If less than 33.3% of the weight in a meta-analysis came from partially indirect or indirect studies, the overall outcome was not downgraded.</p> <p>Serious: If greater than 33.3% of the weight in a meta-analysis came from partially indirect or indirect studies, the outcome was downgraded one level.</p> <p>Very serious: If greater than 33.3% of the weight in a meta-analysis came from indirect studies, the outcome was downgraded two levels.</p> <p>Outcomes meeting the criteria for downgrading above were not downgraded if there was evidence the effect size was not meaningfully different between direct and indirect studies.</p>
Inconsistency	<p>Concerns about inconsistency of effects across studies, occurring when there is unexplained variability in the treatment effect demonstrated across studies (heterogeneity), after appropriate pre-specified subgroup analyses have been conducted. This was assessed using the I^2 statistic.</p> <p>N/A: Inconsistency was marked as not applicable if data on the outcome was only available from one study.</p> <p>Not serious: If the I^2 was less than 33.3%, the outcome was not downgraded.</p> <p>Serious: If the I^2 was between 33.3% and 66.7%, the outcome was downgraded one level.</p> <p>Very serious: If the I^2 was greater than 66.7%, the outcome was downgraded two levels.</p> <p>Outcomes meeting the criteria for downgrading above were not downgraded if there was evidence the effect size was not meaningfully different between studies with the smallest and largest effect sizes.</p>
Imprecision	<p>If the 95% confidence interval for a positive likelihood ratio spanned 2, the outcome was downgraded one level, as the data were deemed to be consistent with a meaningful increase in risk and no meaningful predictive value. Similarly, negative likelihood ratios that spanned 0.5 led to downgrading for serious imprecision. Any likelihood ratios that spanned both 0.5 and 2 were downgraded twice, as suffering from very serious imprecision.</p> <p>Outcomes meeting the criteria for downgrading above were not downgraded if the confidence interval was sufficiently narrow that the upper and lower bounds would correspond to clinically equivalent scenarios.</p>

- 1 The quality of evidence for each outcome was upgraded if either of the following conditions
2 were met:
- 3 • Data showing an effect size sufficiently large that it cannot be explained by confounding
4 alone.
 - 5 • Data where all plausible residual confounding is likely to increase our confidence in the
6 effect estimate.

7 Publication bias

8 Publication bias was assessed in two ways. First, if evidence of conducted but unpublished
9 studies was identified during the review (e.g. conference abstracts or protocols without
10 accompanying published data), available information on these unpublished studies was
11 reported as part of the review. Secondly, where 10 or more studies were included as part of
12 a single meta-analysis, a funnel plot was produced to graphically assess the potential for
13 publication bias.

1 Methods for combining inter-rater agreement evidence

2 The reliability of agreement for diagnostic data between observers was evaluated using the
3 kappa coefficient. The measure calculates the level of agreement in classification. The
4 general rule of thumb to follow is: if there is no agreement among the classification, then
5 $\kappa \leq 0$; if there is complete agreement then $\kappa = 1$ (Fleiss 1971). The following schema
6 (see Table 6), adapted from the suggestions of Fleiss, was used to interpret the level of
7 agreement in diagnostic classification. Random-effects models (der Simonian and Laird)
8 were fitted for all syntheses in R v3.4.0.

9 In any meta-analyses where some (but not all) of the data came from studies at high risk of
10 bias, a sensitivity analysis was conducted, excluding those studies from the analysis. Results
11 from both the full and restricted meta-analyses are reported. Similarly, in any meta-analyses
12 where some (but not all) of the data came from indirect studies, a sensitivity analysis was
13 conducted, excluding those studies from the analysis.

14 Table 6: Interpretation of kappa coefficient

Value of kappa coefficients	Interpretation
$\kappa < 0$	No agreement
$0 < \kappa \leq 0.2$	Poor agreement
$0.2 < \kappa \leq 0.4$	Fair agreement
$0.4 < \kappa \leq 0.7$	Good agreement
$0.7 < \kappa < 1.0$	Excellent agreement
$\kappa = 1.0$	Complete agreement

15 Modified GRADE for inter-rater agreement evidence

16 GRADE has not been developed for use with inter-rater agreement; therefore a modified
17 approach was applied using the GRADE framework. Data from all study types was initially
18 rated as high quality, with the quality of the evidence for each outcome then downgraded or
19 not from this initial point.

20 Table 7: Rationale for downgrading evidence for inter-rater agreement

GRADE criteria	Reasons for downgrading quality
Risk of bias	<p>Not serious: If less than 33.3% of the weight in a meta-analysis came from studies at moderate or high risk of bias, the overall outcome was not downgraded.</p> <p>Serious: If greater than 33.3% of the weight in a meta-analysis came from studies at moderate or high risk of bias, the outcome was downgraded one level.</p> <p>Very serious: If greater than 33.3% of the weight in a meta-analysis came from studies at high risk of bias, the outcome was downgraded two levels.</p> <p>Outcomes meeting the criteria for downgrading above were not downgraded if there was evidence the effect size was not meaningfully different between studies at high and low risk of bias.</p>
Inconsistency	<p>Not serious: If less than 33.3% of the weight in a meta-analysis came from partially indirect or indirect studies, the overall outcome was not downgraded.</p> <p>Serious: If greater than 33.3% of the weight in a meta-analysis came from partially indirect or indirect studies, the outcome was downgraded one level.</p>

GRADE criteria	Reasons for downgrading quality
	<p>Very serious: If greater than 33.3% of the weight in a meta-analysis came from indirect studies, the outcome was downgraded two levels.</p> <p>Outcomes meeting the criteria for downgrading above were not downgraded if there was evidence the effect size was not meaningfully different between direct and indirect studies.</p>
Indirectness	<p>Concerns about inconsistency of effects across studies, occurring when there is unexplained variability in the treatment effect demonstrated across studies (heterogeneity), after appropriate pre-specified subgroup analyses have been conducted. This was assessed using the I^2 statistic.</p> <p>N/A: Inconsistency was marked as not applicable if data on the outcome was only available from one study.</p> <p>Not serious: If the I^2 was less than 33.3%, the outcome was not downgraded.</p> <p>Serious: If the I^2 was between 33.3% and 66.7%, the outcome was downgraded one level.</p> <p>Very serious: If the I^2 was greater than 66.7%, the outcome was downgraded two levels.</p> <p>Outcomes meeting the criteria for downgrading above were not downgraded if there was evidence the effect size was not meaningfully different between studies with the smallest and largest effect sizes.</p>
Imprecision	<p>If the 95% confidence interval for the kappa coefficient spanned two of the categories in Table 6, it was downgraded one level. If the 95% confidence interval for the kappa coefficient spanned three or more of the categories in Table 6, it was downgraded two levels.</p> <p>Outcomes meeting the criteria for downgrading above were not downgraded if the confidence interval was sufficiently narrow that the upper and lower bounds would correspond to clinically equivalent scenarios.</p>

Appendix C – Literature search strategies

Search summary

3 The search strategies are based on the review protocol provided. The MRI/biopsy terms
4 have been taken from the search strategy used in CG175.

Clinical searches

6 Source searched for this review question:

- 7 • Cochrane Database of Systematic Reviews – CDSR (Wiley)
- 8 • Cochrane Central Register of Controlled Trials – CENTRAL (Wiley)
- 9 • Database of Abstracts of Reviews of Effects – DARE (Wiley)
- 10 • Health Technology Assessment Database – HTA (Wiley)
- 11 • EMBASE (Ovid)
- 12 • MEDLINE (Ovid)
- 13 • MEDLINE In-Process (Ovid)

14 The clinical searches were conducted in January 2018.

15 The MEDLINE search strategy is presented below. It was translated for use in all other
16 databases.

1

Database: Ovid MEDLINE(R)

1 exp Prostatic Neoplasms/
 2 Prostatic Intraepithelial Neoplasia/
 3 (prostat* adj4 (neoplas* or cancer* or carcinoma* or adenocarcinom* or tumour* or tumor*
 or malignan* or metasta* or angiosarcoma* or sarcoma* or teratoma* or lymphoma* or
 blastoma* or microcytic* or carcino* or leiomyosarcoma* or lump*)).tw.
 4 PIN.tw.
 5 or/1-4
 6 *Magnetic Resonance Imaging/
 7 (magnet* adj2 (resonance* or imag* or scan* or spectroscop*)).tw.
 8 (MR adj2 (resonance* or imag* or scan* or spectroscop*)).tw.
 9 (Dynamic contrast* enhanc* adj2 (MR* or magnet*)).tw.
 10 (contrast* adj2 (imag* or scan*)).tw.
 11 ((MRI or MRSI or MP-MR* or MPMR*) adj4 prostat*).tw.
 12 turbo spin echo*.tw.
 13 ((diffusion* or weight*) adj2 imag*).tw.
 14 ((DWI or DCE-MRI or T2W or TSE or T2-weighted MRI*) adj4 prostat*).tw.
 15 (Multi-parametric or multiparametric* or biparametric* or bi-parametric*).tw.
 16 *biopsy/ or *image-guided biopsy/
 17 ((transrectal* or trans-rectal* or transperineal* or trans-perineal*) adj2 (ultrasound* or
 biops*)).tw.
 18 ((saturat* or extend* or templat*) adj2 (ultrasound* or biops*)).tw.
 19 ((TRUS or TRUSB) adj4 prostat*).tw.
 20 or/6-19
 21 5 and 20

Study design filters and limits

3 A diagnostic filter was appended to the review question above. The MEDLINE filter is
 4 presented below. It were translated for use in the MEDLINE In-Process and Embase
 5 databases.

6 An English language limit has been applied.

7 A date limit from 2007 was applied as the committee members were confident we would
 8 unlikely find studies on MRI guided biopsy prior to 2007 that reflect current practice.

9 Animal studies and certain publication types (letters, historical articles, comments, editorials,
 10 news and case reports) have been excluded.

11

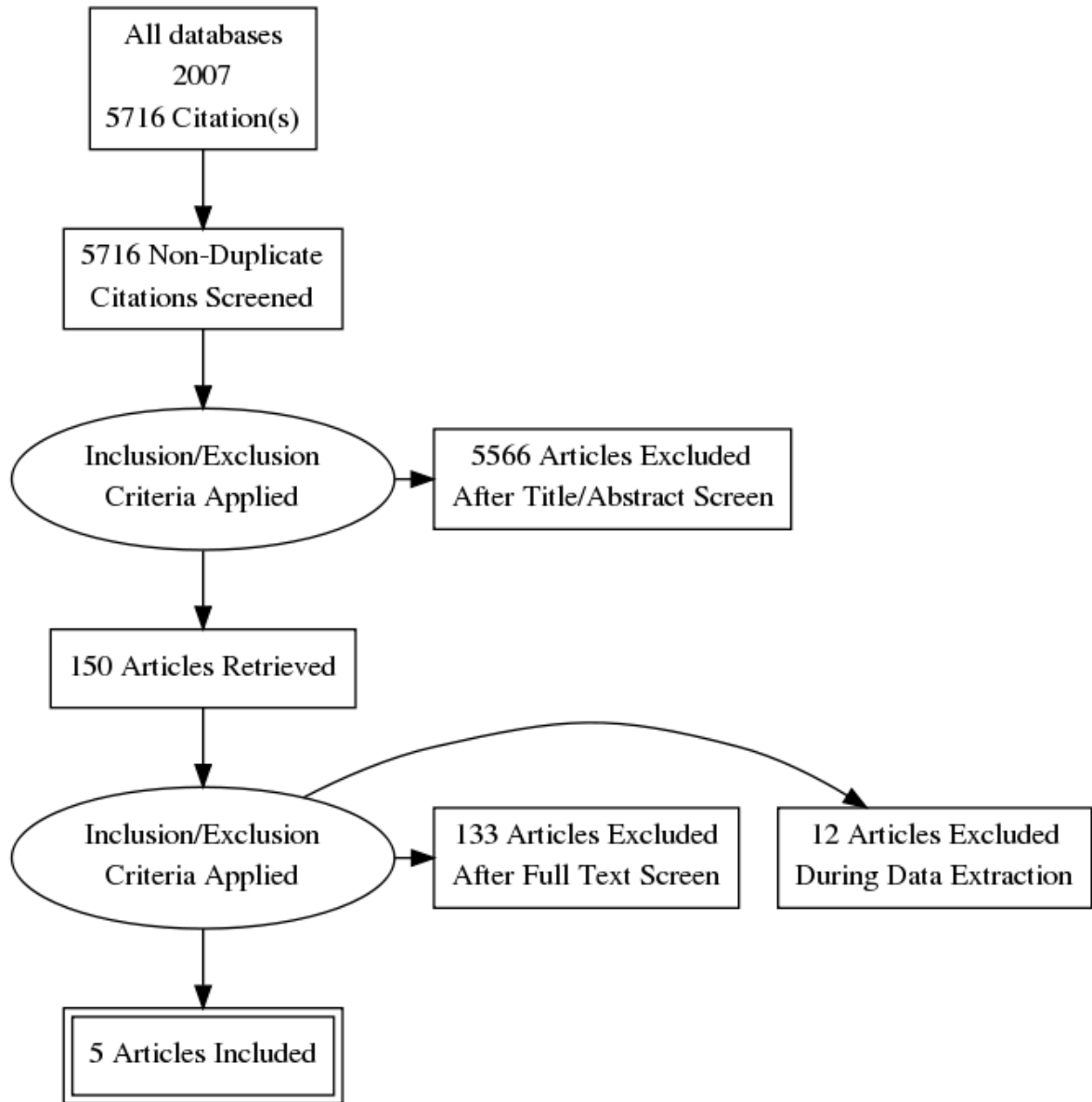
The MEDLINE diagnostic filter

1 (sensitiv: or diagnos:).mp. or di.fs.
 2 Prostate/dg or Prostatic Neoplasms/dg
 3 or/1-3

12

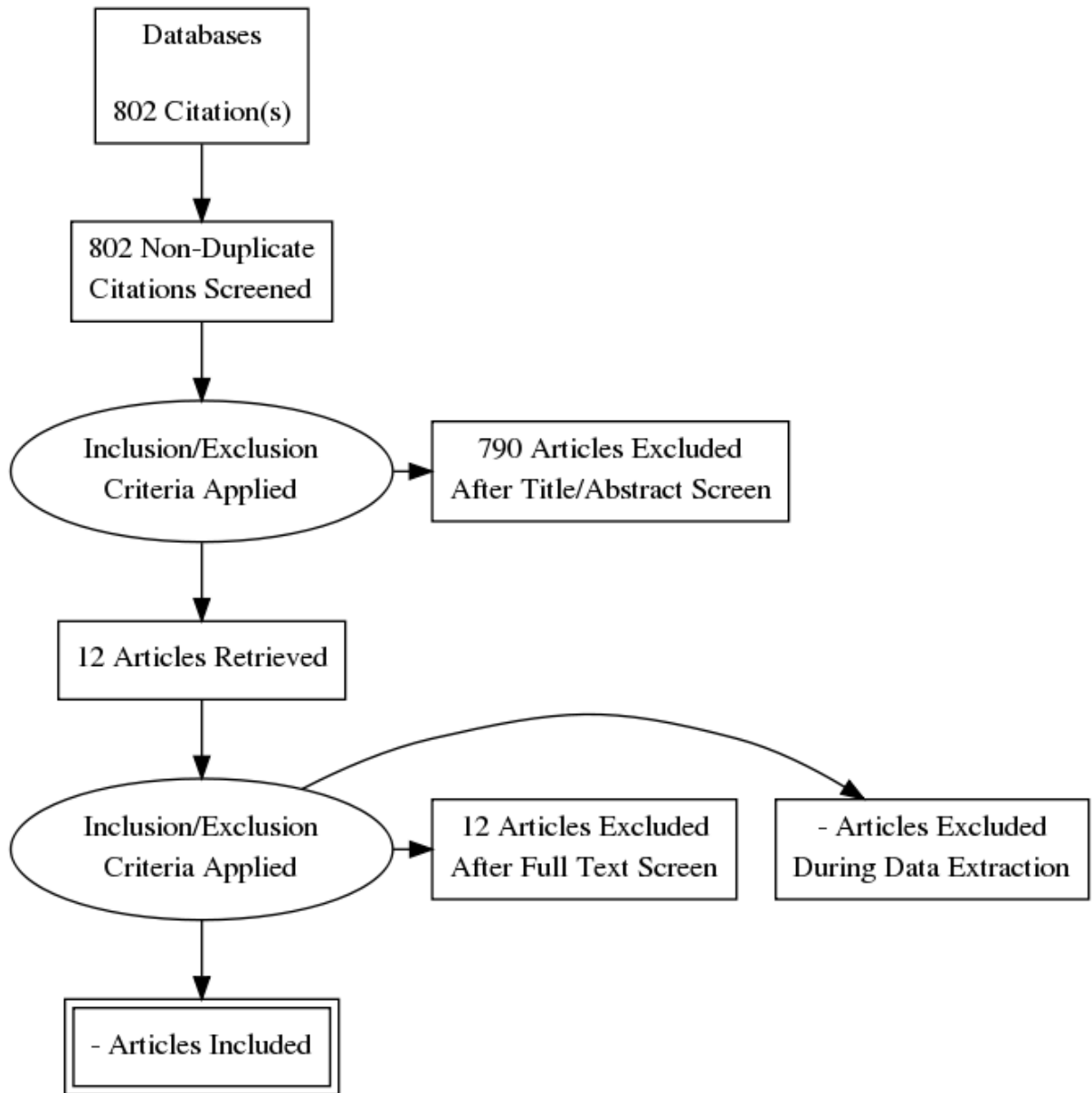
Appendix D – Clinical evidence study selection

Clinical evidence –



3
4
5
6
7
8
9
10

Economic evidence –



2
3
4
5

Appendix E – evidence tables

Clinical evidence tables

Identifying prostate cancer clinical progression in people with low - intermediate risk cancer

Short title	Title	Study Characteristics	Quality Assessment
Barzell (2012)	Identifying candidates for active surveillance: An evaluation of the repeat biopsy strategy for men with favourable risk prostate cancer	<p>Study details</p> <p>Study location USA</p> <p>Study setting Hospital</p> <p>Study dates Between 2002 and 2009</p> <p>Sources of funding Department of Health's National institute for Health Research Biomedical Research Centres funding scheme, the Medical Research Council (UK). Pelican cancer foundation, Prostate Action and St Peter's Trust</p> <p>Inclusion criteria Men who fulfilled the Epstein low risk definition for prostate cancer</p> <p>Exclusion criteria None reported</p> <p>Sample characteristics</p> <p>Sample size 124 people</p> <p>Mean age (SD) 69.4 years (no SD reported)</p> <p>Mean prostate volume (sd)</p>	<p>Patient selection</p> <p>Unclear risk of bias</p> <p>No details were provided on the sampling technique of the study participants. The study was not of a case control design, all patients had both tests done. The authors did not state any exclusion criteria</p> <p>Index test</p> <p>Unclear risk of bias</p> <p>Both tests were carried out at the same time.. it is unclear whether the researchers were blind to either test results. The thresholds used were all predetermined</p> <p>Reference standard</p> <p>Low risk of bias</p> <p>The reference standard was chosen by the committee and was regarded as gold standard</p> <p>Flow and timing</p> <p>Low risk of bias</p> <p>The TRUS and transperineal biopsy was carried out at the same time. All patients received the same reference standard All patients were included in the analysis</p>

Short title	Title	Study Characteristics	Quality Assessment
		<p>46.3 ml (no SD) Mean PSA ng/ml 0.14 ng/ml (no SD)</p> <p>Index test(s) TRUS biopsy repeat biopsy</p> <p>Reference standard(s) Transperineal prostate biopsy</p>	<p>Overall risk of bias Moderate Due to uncertainties surrounding patient selection</p> <p>Directness Directly applicable</p>
Chen (2017)	Outcomes of combination MRI-targeted and transperineal template biopsy in restaging low-risk prostate cancer for active surveillance	<p>Study type Cross-sectional study</p> <p>Study details Study location Singapore Study setting No details provided Study dates No dates provided Sources of funding None disclosed</p> <p>Inclusion criteria Low risk, low grade, localised prostate cancer Gleason score 6 or less Serum PSA level 10ng/ml or less Clinical stage less than or equal to T2a</p> <p>Sample characteristics Sample size 19 participants- 18 went through to MRI targeted biopsy</p>	<p>Patient selection Unclear risk of bias Patient selection details not provided</p> <p>Index test Low risk of bias ".. The surgeon was blinded to the MRI findings ..." and the reference standard was carried out before the targeted biopsy. The MRI threshold was pre specified using the PIRADS version 1 and 2 depending on the study time period.</p> <p>Reference standard Low risk of bias The reference standard matches protocol and is regarded as the "gold standard"</p> <p>Flow and timing Low risk of bias The authors did not provide the time lapse between the 2 tests. All the patients received the same reference standard and all patients were included in</p>

Short title	Title	Study Characteristics	Quality Assessment
		<p>%female n/a Mean age (SD) 65.4 (4.9) years Mean PSA ng/ml 7.3 (1.7) ng/ml</p> <p>Index test(s) Multiparametric MRI high field mpMRI examination obtained with a 3.0T MRI imaging system using a multichannel pelvic phased array coil. High spatial resolution T2-weighted imaging in the axial, sagittal and coronal planes, diffusion weighted imaging in the axial plane (b values 0-50, 500 and 1000s/mm²) and dynamic contrast-enhanced (DCE) images. Targeted biopsy was then planned and performed by cognitive fusion using the same robotic biopsy platform at the same setting as the systematic template biopsy. PIRADS version 1.0 and PIRADS version 2 for studies after December 2014.</p> <p>Reference standard(s) Systematic template biopsy performed under general anaesthetic with the surgeon blinded to the MRI findings, using a robotic transperineal biopsy guidance platform.</p>	<p>the analysis</p> <p>Overall risk of bias Low</p> <p>Directness Directly applicable</p>
Da Rosa (2015)	A prospective comparison of MRI-US fused targeted biopsy versus systematic ultrasound-guided biopsy for detecting clinically significant prostate cancer	<p>Study type Cross-sectional study</p> <p>Study details Study location Canada</p>	<p>Patient selection Unclear risk of bias No patient selection details were provided</p> <p>Index test Low risk of bias</p>

Short title	Title	Study Characteristics	Quality Assessment
	in patients on active surveillance	<p>Study setting Single institution Study dates From March 2011 to December 2012 Sources of funding No financial support declared</p> <p>Inclusion criteria All patient were on active surveillance Referred for biopsy due to rising PSA or appropriate re-biopsy interval according to the AS protocol</p> <p>Exclusion criteria None reported</p> <p>Sample characteristics Sample size 81 participants - 72 included in analysis %female n/a Mean age (SD) 64.8 (range 41-79) years Mean PSA ng/ml 5.0 (range 1.1-17.6) ng/ml Median months on active surveillance 38.0months (range 0.9-134.7)</p> <p>Index test(s) MRI-ultrasound fusion biopsy The MRI protocol was - 3.0T MR imaging system, without an endorectal coil, combining axial, sagittal and coronal T2- weighted, diffusion weighted, b values 100, 400, 1000 and dynamic contrast</p>	<p>"...The uro-radiologist was blinded to prior biopsy results and previous pathological findings.." the threshold was predefined, they used a LIKERT scale.</p> <p>Reference standard Low risk of bias The reference was chosen by the committee as the "gold standard" for this review.</p> <p>Flow and timing Low risk of bias the index test and the reference test was carried out by the same operator, however the there was a second operator who was blinded to the location of suspicious lesions on MRI.</p> <p>Overall risk of bias Low</p> <p>Directness Directly applicable</p>

Short title	Title	Study Characteristics	Quality Assessment
		<p>enhanced imaging.</p> <p>Reference standard(s) TRUS biopsy</p>	
Feng (2015)	Multiparametric magnetic resonance imaging localizes established extracapsular extension of prostate cancer	<p>Study type Cross-sectional study</p> <p>Study details Study location USA Study setting No details provided Study dates Between January 2010 and July 2014 Sources of funding None disclosed</p> <p>Inclusion criteria None reported</p> <p>Exclusion criteria Patients receiving preoperative androgen deprivation therapy</p> <p>Sample characteristics Sample size 112 participants %female n/a Mean age (SD) 62.8 (7.5) years Mean PSA ng/ml</p>	<p>Patient selection Unclear risk of bias Patient selection details not provided. The index test thresholds were predetermined using PIRADS</p> <p>Index test Low risk of bias ".. All cases were reviewed by a single radiologist with expertise in Prostate MR images..."</p> <p>Reference standard Low risk of bias The reference standard matches protocol and is regarded as the "gold standard".</p> <p>Flow and timing Unclear risk of bias The authors did not provide the time lapse between the 2 tests. All the patients received the same reference standard and all patients were included in the analysis</p> <p>Overall risk of bias Moderate – as a result of the uncertainties surrounding patients selection</p>

Short title	Title	Study Characteristics	Quality Assessment
		<p>8.2 (7.2) ng/ml</p> <p>Index test(s) Multiparametric MRI imaging using 3.0T MRI system equipped with a 12-channel pelvic phased array coil. Anatomic images included T1- and T2 weighted turbo spin echo, acquired in the axial, sagittal and coronal planes. Diffusion weighted imaging was acquired using a standard single-shot echo planar imaging sequence. The orthogonal diffusion directions including a single b0 measurement were acquired at 2 nonzero b values 400 and 800s/mm².</p> <p>Reference standard(s) Radical prostatectomy</p>	<p>Directness Directly applicable</p>
Pessoa (2017)	Value of 3-Tesla multiparametric magnetic resonance imaging and targeted biopsy for improved risk stratification in patients considered for active surveillance	<p>Study type Prospective cohort study</p> <p>Study details Study location Brazil Study setting No details provided Study dates Between March 2014 and January 2016 Sources of funding None declared</p> <p>Inclusion criteria Standard Biopsy taken a maximum of 6 months before Low risk, low grade, localised prostate cancer</p>	<p>Patient selection Unclear risk of bias Patient selection details not provided, the participants were referrals from other centres, it is unclear if the patient selection strategy could have increased risk of bias.</p> <p>Index test Unclear risk of bias Every man underwent sampling of 12 systematic sites, independent of mpMRI results, MRI images were then considered and appeared on the screen adjacent to the ultrasound, allowing real-time visual estimation comparison of methods and zones of interest.</p>

Short title	Title	Study Characteristics	Quality Assessment
		<p>Clinical Stage t1c-t12a cancer Gleason score 6 or less Serum PSA level 10ng/ml or less Life expectancy of >5years</p> <p>Exclusion criteria Previous history of prostate biopsy Prostate surgery Had any contraindication to MRI (e.g. claustrophobia, pacemaker, estimated glomerular filtration rate \leq50)</p> <p>Sample characteristics Sample size 105 participants %female N/A Median Age (IQR) 67 (48-81) years Median PSA level (IQR) ng/ml 7.5 (1.2 - 10.0) Median PSAD (ng/ml/ml) 0.11 (0.04 -0.28) ng/ml/ml</p> <p>Index test(s) Multiparametric MRI Axial-oblique, fast spin-echo T2-weighted, diffusion weighted imaging (DWI), and dynamic contrast-enhanced (DCE) – MRI on a 16 channel cardiac surface, external phased -array coil 3.0t MRI system with standard widespread recommendation for image acquisition. PIRADS version 1</p>	<p>Reference standard Unclear risk of bias The reference standard matches protocol and is regarded as the "gold standard".</p> <p>Flow and timing Unclear risk of bias The authors did not provide the time lapse between the 2 tests. All the patients received the same reference standard and all patients were included in the analysis</p> <p>Overall risk of bias Moderate as a result of the uncertainties surrounding patients selection and index test results interpretation</p> <p>Directness Directly applicable</p>

Short title	Title	Study Characteristics	Quality Assessment
		Reference standard(s) Confirmatory Biopsy included a standard biopsy and visual estimation-guided TRUS biopsy	

Economic evidence

Study, population, country and quality	Data sources	Other comments	Strategy	Total		ICER (€/QALY)	Authors' conclusions	Uncertainty
				Cost (€)	Effect (QALYs)			
The Role of MpMRI in AS for Men with Low-risk PCa: A Cost-effectiveness Modeling Study Partially applicable very serious limitations ^{a, b, c}	<u>Effectiveness:</u> accuracy data for TRUS, Mp-MRI and MRI-TRUS, obtained from existing literature (Schoots 2015 and PROMIS) <u>Cost:</u> healthcare perspective, prices in €, 2016 <u>Utility:</u> derived from existing literature, applying decrement associated with biopsy that last for 3 weeks. Also, decrement due to AEs associated with RP or RT	A Markov model with a cycle length of 1 year; consisting of 5 health states: Low-risk, low-risk-post-treatment, high-risk, high-risk-post-treatment and death due to PCa or other causes. Cost and QALYs discounted by 4 and 1.5% annually 3 strategies for AS were compared: TRUS every 3 years; MRI-TRUS every 3 years; MRI only every 3 years Accuracy data were obtained from studies that addressed different population (people with suspicion of PCa) Transition probability from low-risk to high-risk: was not explicitly clear it was derived.	Base case			Mp-MRI, if positive, followed by TRUS every 3 years resulted in greater QALYs and less costs than TRUS only and Mp-MRI only every 3 years to identify high-risk prostate cancer within people with low-risk disease.	Probabilistic model run for 10,000 iterations. Optimal strategy remained the same in 90% of the iterations; the results were robust in one-way sensitivity analysis and scenario analysis.	
			1	5,150	18.66			-
			2	4,848	18.67			Dominant
			3	5,994	18.27			Dominated

Study, population, country and quality	Data sources	Other comments	Strategy	Total			Authors' conclusions	Uncertainty
				Cost (€)	Effect (QALYs)	ICER (€/QALY)		
a) Techniques used in MRI-targeted TRUS not specified b) Evidence on accuracy data of tests obtained from studies with different population c) Uncertainty in the long-run outcome related to progression rate from low- to high-risk								

1

Appendix F – GRADE tables

Identifying prostate cancer clinical progression in people with low - intermediate risk cancer

3

No. of studies	Study design	Sample size	Sensitivity (95%CI)	Specificity (95%CI)	Effect size (95%CI)	Risk of bias	Inconsistency	Indirectness	Imprecision	Quality
TRUS biopsy- (reference standard: transperineal template mapping biopsy)										
1 study Barzell (2012)	Cross-sectional	124	0.10 (0.04, 0.21)	0.93 (0.85, 0.97)	LR- 0.97 (0.87, 1.08)	Serious ¹	N/A	Not serious	Not serious	Moderate
					LR+ 1.43 (0.44, 4.69)	Serious ¹	N/A	Not serious	Very Serious ²	Very Low
MRI influenced biopsy (reference standard: robotic transperineal template biopsy)										
1 study Chen (2017)	Cross-sectional	18	0.03(0.01, 0.13)	0.87 (0.74, 0.94)	LR- 1.12 (0.98, 1.25)	Not serious	N/A	Not serious	Not serious	High
					LR+0.27 (0.06, 1.26)	Not serious	N/A	Not serious	Serious ³	Moderate
						Serious				
Multiparametric MRI (reference standard: TRUS biopsy) (people with Clinical Stage t1c-t12a cancer, Gleason score 6 or less Serum PSA level 10ng/ml or less)										
1 study Pessoa (2017)	Cross-sectional	105	0.95 (0.85, 0.98)	0.79(0.65, 0.88)	LR- 0.07 (0.02, 0.20)	Not serious	N/A	Not serious	Not serious	High
					LR+ 4.46 (2.56, 7.75)	Not serious	N/A	Not serious	Not serious	High
MRI influenced biopsy (reference standard: TRUS Biopsy) (people with Clinical Stage t1c-t12a cancer, Gleason score 6 or less Serum PSA level 10ng/ml or less)										
1 study Pessoa (2017)	Cross-sectional	87	0.85 (0.70, 0.93)	0.69 (0.54, 0.80)	LR- 0.22 (0.11, 0.48)	Not serious	N/A	Not serious	Not serious	High
					LR+ 2.71 (1.74, 4.21)	Not serious	N/A	Not serious	Serious ³	Moderate
MRI/TRUS fusion targeted biopsy (reference standard: TRUS) (people on Active surveillance)										

Reclassification criteria - Any cancer of Gleason score 7 or greater										
1 study Da Rosa (2015)	Cross-sectional	72	0.83(0.52, 0.96)	0.88 (0.76, 0.94)	LR- 0.19 (0.05, 0.67)	Not serious	N/A	Not serious	Serious ³	Moderate
					LR+ 7.14 (3.41, 14.98)	Not serious	N/A	Not serious	Not serious	High
Reclassification criteria - Gleason score of 6 with >50% involvement in any core										
1 study Da Rosa (2015)	Cross-sectional	72	0.76 (0.54, 0.90)	0.80 (0.67, 0.89)	LR- 0.30 (0.14, 0.64)	Not serious	N/A	Not serious	Serious ³	Moderate
					LR+ 3.89 (2.12, 7.14)	Not serious	N/A	Not serious	Not serious	High
Multiparametric MRI (reference standard: Radical prostatectomy)										
Reclassification criteria – suspicious/definite extracapsular extension (mpMRI score ≥3) (participants with clinical prostate stage T1c – T2a)										
1 Study Feng (2015)	Cross-sectional	112	0.72(0.54, 0.86)	0.90 (0.82, 0.95)	LR- 0.31 (0.17, 0.55)	Not serious	N/A	Not serious	Serious ³	Moderate
					LR+ 7.51 (3.75, 15.07)	Not serious	N/A	Not serious	Not serious	High
Reclassification criteria – definite extracapsular extension (mpMRI PIRADS score ≥4 (participants with clinical prostate stage T1c – T2a)										
1 study Feng (2015)	Cross-sectional	112	0.41 (0.25, 0.60)	0.99(0.92, 1.00)	LR – 0.59 (0.44, 0.81)	Not serious	N/A	Not serious	Serious ³	Moderate
					LR+ 34.35 (4.67, 252.69)	Not serious	N/A	Not serious	Not serious	High
<ol style="list-style-type: none"> 1. Moderate risk of bias – due to selection bias – unclear how the study participants were selected, downgraded once 2. 95% confidence interval for likelihood ratio crosses both ends of a defined MID interval – (0.5, 2), downgraded twice 3. 95% confidence interval for likelihood ratio crosses one end of a defined MID interval – (0.5, 2), downgraded once 										

- 1
- 2
- 3

Appendix G – Excluded studies

Clinical studies

Short Title	Title	Reason for Exclusion
Abd-Alazeez (2014)	Can multiparametric magnetic resonance imaging predict upgrading of transrectal ultrasound biopsy results at more definitive histology?	Not possible to calculate a 2x2 table from data presented in the study
Abdi (2015)	Multiparametric magnetic resonance imaging enhances detection of significant tumor in patients on active surveillance for prostate cancer	Not possible to calculate a 2x2 table from data presented in the study
Ahallal (2016)	Clinical performance of transperineal template guided mapping biopsy for therapeutic decision making in low risk prostate cancer	Study does not contain any relevant index tests
Alberts (2017)	Risk-stratification based on magnetic resonance imaging and prostate-specific antigen density may reduce unnecessary follow-up biopsy procedures in men on active surveillance for low-risk prostate cancer	MRI protocol does not satisfy the following criteria - diffusion weighted, contrast enhanced, at least 1.5T and b value of at least 800s/mm ²
Anderson (2015)	Age is associated with upgrading at confirmatory biopsy among men with prostate cancer treated with active surveillance	Study does not contain any relevant index tests
Arani (2011)	The feasibility of endorectal MR elastography for prostate cancer localization	No reference standard
Bains (2014)	Diffusion-weighted magnetic resonance imaging detects significant prostate cancer with high probability	Mixed cancer populations
Bianchi (2016)	Multiparametric magnetic resonance imaging and frozen-section analysis efficiently predict upgrading, upstaging, and extraprostatic extension in patients undergoing nerve-sparing robotic-assisted radical prostatectomy	MRI protocol does not satisfy the following criteria - diffusion weighted, contrast enhanced, at least 1.5T and b value of at least 800s/mm ²
Billing (2015)	Preoperative mp-MRI of the prostate provides little information about staging of prostate carcinoma in daily clinical practice	MRI protocol does not satisfy the following criteria - diffusion weighted, contrast enhanced, at least 1.5T and b value of at least 800s/mm ²
Bloch (2007)	Prostate cancer: Accurate determination of extracapsular extension with high-spatial-	MRI protocol does not satisfy

Short Title	Title	Reason for Exclusion
	resolution dynamic contrast-enhanced and T2-weighted MR imaging - Initial results	the following criteria - diffusion weighted, contrast enhanced, at least 1.5T and b value of at least 800s/mm ² Does not give details of the b values
Borkowetz (2015)	Assessment of tumour aggressiveness in tranperineal mri/ultrasound-fusion biopsy in comparison to transrectal systematic prostate biopsy	Conference abstract
Borkowetz (2016)	Direct comparison of multiparametric magnetic resonance imaging (MRI) results with final histopathology in patients with proven prostate cancer in MRI/ultrasonography-fusion biopsy	MRI protocol does not satisfy the following criteria - diffusion weighted, contrast enhanced, at least 1.5T and b value of at least 800s/mm ²
Bosco (2016)	Confirmatory biopsy for the assessment of prostate cancer in men considering active surveillance: Reference centre experience	Not possible to calculate a 2x2 table from data presented in the study
Brock (2015)	Fusion of Magnetic Resonance Imaging and Real-Time Elastography to Visualize Prostate Cancer: A Prospective Analysis using Whole Mount Sections after Radical Prostatectomy	MRI protocol does not satisfy the following criteria - diffusion weighted, contrast enhanced, at least 1.5T and b value of at least 800s/mm ²
Cerantola (2013)	Can 3T multiparametric magnetic resonance imaging accurately detect prostate cancer extracapsular extension?	Study population unclear
Chabanova (2011)	Prostate cancer: 1.5 T endo-coil dynamic contrast-enhanced MRI and MR spectroscopy - Correlation with prostate biopsy and prostatectomy histopathological data	MRI protocol does not satisfy the following criteria - diffusion weighted, contrast enhanced, at least 1.5T and b value of at least 800s/mm ² Does not give details of the b values
Chamie (2014)	The role of magnetic resonance imaging in delineating clinically significant prostate cancer	Does not contain a population with low risk or intermediate cancer
De Rooij (2014)	Accuracy of multiparametric MRI for prostate cancer detection: A meta-analysis	Systematic review- no additional articles identified for inclusion in this review

Short Title	Title	Reason for Exclusion
de Rooij (2016)	Accuracy of Magnetic Resonance Imaging for Local Staging of Prostate Cancer: A Diagnostic Meta-analysis	Duplicate reference
Dekalo (2017)	High cancer detection rate using cognitive fusion - targeted transperineal prostate biopsies	Does not contain a population with low risk or intermediate cancer
Delongchamps (2011)	Multiparametric MRI is helpful to predict tumor focality, stage, and size in patients diagnosed with unilateral low-risk prostate cancer	Restrospective study looking at participants before their follow up MRI or Biopsy
Delongchamps (2015)	Detection of significant prostate cancer with magnetic resonance targeted biopsies - Should transrectal ultrasound-magnetic resonance imaging fusion guided biopsies alone be a standard of care?	MRI protocol does not satisfy the following criteria - diffusion weighted, contrast enhanced, at least 1.5T and b value of at least 800s/mm ²
Dianat (2014)	Performance of multiparametric magnetic resonance imaging in the evaluation and management of clinically low-risk prostate cancer	Systematic review- no additional articles identified for inclusion in this review
Donati (2014)	Prostate MRI: Evaluating tumor volume and apparent diffusion coefficient as surrogate biomarkers for predicting tumor Gleason score	Study population unclear
Eisenberg (2011)	The importance of tumor palpability and transrectal ultrasonographic appearance in the contemporary clinical staging of prostate cancer	No reference standard
Flavell (2014)	Abnormal findings on multiparametric prostate magnetic resonance imaging predict subsequent biopsy upgrade in patients with low risk prostate cancer managed with active surveillance	MRI protocol does not satisfy the following criteria - diffusion weighted, contrast enhanced, at least 1.5T and b value of at least 800s/mm ² B value = 0+600s/mm ²
Frye (2017)	Magnetic Resonance Imaging-Transrectal Ultrasound Guided Fusion Biopsy to Detect Progression in Patients with Existing Lesions on Active Surveillance for Low and Intermediate Risk Prostate Cancer	MRI protocol does not satisfy the following criteria - diffusion weighted, contrast enhanced, at least 1.5T and b value of at least 800s/mm ²
Gallina (2012)	Unilateral positive biopsies in low risk prostate cancer patients diagnosed with extended transrectal ultrasound-guided biopsy schemes do not predict unilateral prostate cancer at radical prostatectomy	Restrospective study looking at participants before their follow up MRI or Biopsy

Short Title	Title	Reason for Exclusion
Girouin (2007)	Prostate dynamic contrast-enhanced MRI with simple visual diagnostic criteria: Is it reasonable?	MRI protocol does not satisfy the following criteria - diffusion weighted, contrast enhanced, at least 1.5T and b value of at least 800s/mm ²
Goeb (2007)	MRI spectroscopy in screening of prostate cancer	Not a relevant study design (crosssectional study)
Gondo (2014)	Multiparametric 3T MRI for the prediction of pathological downgrading after radical prostatectomy in patients with biopsy-proven Gleason score 3 + 4 prostate cancer	Study populaton have high risk prostate cancer
Gordon (2017)	Cost-effectiveness analysis of multiparametric MRI with increased active surveillance for low-risk prostate cancer in Australia	Health economics paper
Guo (2015)	Magnetic resonance imaging on disease reclassification among active surveillance candidates with low-risk prostate cancer: A diagnostic meta-analysis	Systematic review- no additional articles identified for inclusion in this review
Gupta (2016)	Multiparametric prostate MRI: focus on T2-weighted imaging and role in staging of prostate cancer	Review article but not a systematic review
Haider (2016)	Multiparametric Magnetic Resonance Imaging in the Diagnosis of Prostate Cancer: A Systematic Review	Does not contain a population with low risk or intermediate cancer
Hamoen (2018)	Value of Serial Multiparametric Magnetic Resonance Imaging and Magnetic Resonance Imaging-guided Biopsies in Men with Low-risk Prostate Cancer on Active Surveillance After 1 Yr Follow-up	Reference standard in study does not match that specified in protocol
Heijmink (2007)	Prostate cancer: Body array versus endorectal coil MR imaging at 3T - Comparison of image quality, localization, and staging performance	MRI protocol does not satisfy the following criteria - diffusion weighted, contrast enhanced, at least 1.5T and b value of at least 800s/mm ²
Hoeks (2014)	Value of 3-T multiparametric magnetic resonance imaging and magnetic resonance-guided biopsy for early risk restratification in active surveillance of low-risk prostate cancer: A prospective multicenter cohort study	Reference standard in study does not match that specified in protocol

Short Title	Title	Reason for Exclusion
Hwii (2011)	The predictability of T3disease in staging MRI following prostate biopsy decreases in patients with high initial PSA and Gleason score	MRI protocol does not satisfy the following criteria - diffusion weighted, contrast enhanced, at least 1.5T and b value of at least 800s/mm2
Itatani (2014)	Triage of low-risk prostate cancer patients with PSA levels 10 ng/mL or less: Comparison of apparent diffusion coefficient value and transrectal ultrasound-guided target biopsy	Does not contain a population with low risk or intermediate cancer
Jin (2015)	Pathological upgrading in prostate cancer patients eligible for active surveillance: Does prostate-specific antigen density matter?	Study does not contain any relevant index tests
Jung (2012)	Local staging of prostate cancer: Comparative accuracy of T2-weighted endorectal MR imaging and transrectal ultrasound	MRI protocol does not satisfy the following criteria - diffusion weighted, contrast enhanced, at least 1.5T and b value of at least 800s/mm2
Kan (2014)	Pre-operative tumor localization and evaluation of extra-capsular extension of prostate cancer: how misleading can it be?	Restrospective study looking at participants before their follow up MRI or Biopsy
Kang (2016)	Predictors of pathological upgrading in low-risk prostate cancer patients without hypointense lesions on an apparent diffusion coefficient map of multiparametric magnetic resonance imaging	No reference standard
Kasivisvanathan (2013)	Transperineal magnetic resonance image targeted prostate biopsy versus transperineal template prostate biopsy in the detection of clinically significant prostate cancer	Included a mixed population of suspected prostate cancer and proven prostate cancer with no sub group analysis
Katz (2014)	Comparison of transperineal mapping biopsy results with whole-mount radical prostatectomy pathology in patients with localized prostate cancer	Study does not contain any relevant index tests
Kim (2014)	Low-risk prostate cancer: The accuracy of multiparametric MR imaging for detection	Not possible to calculate a 2x2 table from data presented in the study The MPMRI modalities were reported separately, unable to combine to see full effect of the MPMRI

Short Title	Title	Reason for Exclusion
Kryvenko (2012)	Findings in 12-core transrectal ultrasound-guided prostate needle biopsy that predict more advanced cancer at prostatectomy: analysis of 388 biopsy-prostatectomy pairs	Does not contain a population with low risk or intermediate cancer
Kuhl (2017)	Abbreviated biparametric prostate MR imaging in men with elevated prostate-specific antigen	MRI protocol does not satisfy the following criteria - diffusion weighted, contrast enhanced, at least 1.5T and b value of at least 800s/mm ²
Kulkarni (2007)	Clinical predictors of gleason score upgrading: Implications for patients considering watchful waiting, active surveillance, or brachytherapy	Study does not contain any relevant index tests
Lai (2017)	Factors predicting prostate cancer upgrading on magnetic resonance imaging-targeted biopsy in an active surveillance population	MRI protocol does not satisfy the following criteria - diffusion weighted, contrast enhanced, at least 1.5T and b value of at least 800s/mm ² B value not specified
Leapman (2017)	Association between a 17-gene genomic prostate score and multi-parametric prostate MRI in men with low and intermediate risk prostate cancer (PCa)	No reference standard
Lee (2010)	Is endorectal coil necessary for the staging of clinically localized prostate cancer? Comparison of non-endorectal versus endorectal MR imaging	MRI protocol does not satisfy the following criteria - diffusion weighted, contrast enhanced, at least 1.5T and b value of at least 800s/mm ²
Li (2013)	Diagnostic Performance of Contrast Enhanced Ultrasound in Patients with Prostate Cancer. A Meta-Analysis	Study does not contain any relevant index tests
Loggitsi (2017)	Multiparametric Magnetic Resonance Imaging of the Prostate for Tumour Detection and Local Staging: Imaging in 1.5T and Histopathologic Correlation	Follow up of less than 4 weeks
Ma (2017)	The Role of Multiparametric Magnetic Resonance Imaging/Ultrasound Fusion Biopsy in Active Surveillance	Reference standard in study does not match that specified in protocol
Margel (2012)	Impact of multiparametric endorectal coil prostate magnetic resonance imaging on disease reclassification among active surveillance candidates: A prospective cohort study	MRI protocol does not satisfy the following criteria - diffusion weighted, contrast enhanced, at least 1.5T and b value of at

Short Title	Title	Reason for Exclusion
		least 800s/mm ² Does not give details of the b values
Marliere (2014)	The role of MRI-targeted and confirmatory biopsies for cancer upstaging at selection in patients considered for active surveillance for clinically low-risk prostate cancer	MRI protocol does not satisfy the following criteria - diffusion weighted, contrast enhanced, at least 1.5T and b value of at least 800s/mm ²
McCammack (2016)	Restriction spectrum imaging improves MRI-based prostate cancer detection	Reference standard in study does not match that specified in protocol
Meng (2016)	Relationship between Prebiopsy Multiparametric Magnetic Resonance Imaging (MRI), Biopsy Indication, and MRI-ultrasound Fusion-targeted Prostate Biopsy Outcomes	Included a mixed population of suspected prostate cancer and proven prostate cancer with no sub group analysis
Min (2012)	Usefulness of a combined approach of T1-weighted, T2-weighted, dynamic contrast-enhanced, and diffusion-weighted imaging in prostate cancer	MRI protocol does not satisfy the following criteria - diffusion weighted, contrast enhanced, at least 1.5T and b value of at least 800s/mm ² Study comparing MRI protocols
Monni (2017)	Magnetic resonance imaging in prostate cancer detection and management: A systematic review	Review article but not a systematic review
Moon (2010)	Predictive factors of Gleason score upgrading in localized and locally advanced prostate cancer diagnosed by prostate biopsy	Study does not contain any relevant index tests
Mullins (2013)	Multiparametric magnetic resonance imaging findings in men with low-risk prostate cancer followed using active surveillance	Reference standard in study does not match that specified in protocol
Muthigi (2017)	Missing the Mark: prostate Cancer Upgrading by Systematic Biopsy over Magnetic Resonance Imaging/Transrectal Ultrasound Fusion Biopsy	Not possible to calculate a 2x2 table from data presented in the study
Nahar (2017)	Reclassification Rates of Patients Eligible for Active Surveillance After the Addition of Magnetic Resonance Imaging-Ultrasound Fusion Biopsy: An Analysis of 7 Widely Used Eligibility Criteria	Does not contain a population with low risk or intermediate cancer

Short Title	Title	Reason for Exclusion
Nelson (2013)	Repeat prostate biopsy strategies after initial negative biopsy: meta-regression comparing cancer detection of transperineal, transrectal saturation and MRI guided biopsy (Provisional abstract)	Does not contain a population with low risk or intermediate cancer
Nogueira (2010)	Focal Treatment or Observation of Prostate Cancer: Pretreatment Accuracy of Transrectal Ultrasound Biopsy and T2-weighted MRI	MRI protocol does not satisfy the following criteria - diffusion weighted, contrast enhanced, at least 1.5T and b value of at least 800s/mm ²
Novis (2011)	Clinically low-risk prostate cancer: evaluation with transrectal doppler ultrasound and functional magnetic resonance imaging	MRI protocol does not satisfy the following criteria - diffusion weighted, contrast enhanced, at least 1.5T and b value of at least 800s/mm ²
Numao (2007)	Improved Accuracy in Predicting the Presence of Gleason Pattern 4/5 Prostate Cancer by Three-Dimensional 26-Core Systematic Biopsy	Reference standard in study does not match that specified in protocol
Ouzzane (2015)	Magnetic Resonance Imaging Targeted Biopsy Improves Selection of Patients Considered for Active Surveillance for Clinically Low Risk Prostate Cancer Based on Systematic Biopsies	Does not contain a population with low risk or intermediate cancer
Park (2007)	Comparison of phased-array 3.0-T and endorectal 1.5-T magnetic resonance imaging in the evaluation of local staging accuracy for prostate cancer	MRI protocol does not satisfy the following criteria - diffusion weighted, contrast enhanced, at least 1.5T and b value of at least 800s/mm ² Does not give details of the b values and contrast enhancement
Park (2010)	The role of endorectal magnetic resonance imaging in predicting extraprostatic extension and seminal vesicle invasion in clinically localized prostate cancer	MRI protocol does not satisfy the following criteria - diffusion weighted, contrast enhanced, at least 1.5T and b value of at least 800s/mm ²
Park (2014)	Prostate cancer: Role of pretreatment multiparametric 3-T MRI in predicting biochemical recurrence after radical prostatectomy	Study population have high risk prostate cancer
Park (2014)	Influence of magnetic resonance imaging in the decision to preserve or resect	MRI protocol does not satisfy the following criteria - diffusion

Short Title	Title	Reason for Exclusion
	neurovascular bundles at robotic assisted laparoscopic radical prostatectomy	weighted, contrast enhanced, at least 1.5T and b value of at least 800s/mm ² Does not give details of the b values
Park (2014)	Role of multiparametric 3.0-Tesla magnetic resonance imaging in patients with prostate cancer eligible for active surveillance	Restrospective study looking at participants before their follow up MRI or Biopsy
Park (2016)	Prediction of biochemical recurrence after radical prostatectomy with PI-RADS version 2 in prostate cancers: initial results	Study does not contain any relevant index tests
Peltier (2016)	Results of a comparative analysis of magnetic resonance imaging-targeted versus three-dimensional transrectal ultrasound prostate biopsies: Size does matter	Does not contain a population with low risk or intermediate cancer
Pepe (2016)	Detection rate for significant cancer at confirmatory biopsy in men enrolled in Active Surveillance protocol: 20 cores vs 30 cores vs MRI/TRUS fusion prostate biopsy	MRI protocol does not satisfy the following criteria - diffusion weighted, contrast enhanced, at least 1.5T and b value of at least 800s/mm ²
Pepe (2016)	Can MRI/TRUS fusion targeted biopsy replace saturation prostate biopsy in the re-evaluation of men in active surveillance?	MRI protocol does not satisfy the following criteria - diffusion weighted, contrast enhanced, at least 1.5T and b value of at least 800s/mm ²
Pepe (2017)	Confirmatory biopsy of men under active surveillance: extended versus saturation versus multiparametric magnetic resonance imaging/transrectal ultrasound fusion prostate biopsy	MRI protocol does not satisfy the following criteria - diffusion weighted, contrast enhanced, at least 1.5T and b value of at least 800s/mm ²
Ploussard (2011)	Prostate cancer antigen 3 score accurately predicts tumour volume and might help in selecting prostate cancer patients for active surveillance	Study does not contain any relevant index tests
Ploussard (2013)	Detailed biopsy pathologic features as predictive factors for initial reclassification in prostate cancer patients eligible for active surveillance	Study does not contain any relevant index tests
Pokorny (2014)	Prospective study of diagnostic accuracy comparing prostate cancer detection by transrectal ultrasound-guided biopsy versus magnetic resonance (MR) imaging with	Does not contain a population with low risk or intermediate

Short Title	Title	Reason for Exclusion
	subsequent mr-guided biopsy in men without previous prostate biopsies	cancer
Presti (1996)	Prediction of focal extracapsular extension at radical prostatectomy: Relative merit of transrectal ultrasound, endorectal magnetic resonance imaging, prostate specific antigen, prostate specific antigen density, and systematic biopsy	MRI protocol does not satisfy the following criteria - diffusion weighted, contrast enhanced, at least 1.5T and b value of at least 800s/mm ²
Puech (2013)	Prostate cancer diagnosis : Multiparametric mr-targeted biopsy with cognitive and transrectal us-mr fusion guidance versus systematic biopsy-prospective multicenter study	Does not contain a population with low risk or intermediate cancer
Radtke (2016)	Further reduction of disqualification rates by additional MRI-targeted biopsy with transperineal saturation biopsy compared with standard 12-core systematic biopsies for the selection of prostate cancer patients for active surveillance	Not possible to calculate a 2x2 table from data presented in the study
Radtke (2016)	Reduced disqualification rates when MRI-targeted transperineal fusion biopsies are used instead of standard 12-core systematic biopsies for selection of prostate cancer patients for active surveillance	Duplicate reference
Raventos (2010)	Preoperative prediction of pathologically insignificant prostate cancer in radical prostatectomy specimens: the role of prostate volume and the number of positive cores	Study does not contain any relevant index tests
Recabal (2016)	The Efficacy of Multiparametric Magnetic Resonance Imaging and Magnetic Resonance Imaging Targeted Biopsy in Risk Classification for Patients with Prostate Cancer on Active Surveillance	Not possible to calculate a 2x2 table from data presented in the study
Renard-Penna (2017)	Role of prostate MRI, TRUS fusion biopsies and new markers in the diagnostic strategy of prostate cancer	Study not reported in English
Rosenkrantz (2012)	Prostate cancer foci detected on multiparametric magnetic resonance imaging are histologically distinct from those not detected	No reference standard
Rosenkrantz (2013)	Utility of diffusional kurtosis imaging as a marker of adverse pathologic outcomes among prostate cancer active surveillance candidates undergoing radical prostatectomy	No reference standard
Russo (2015)	Detection of prostate cancer index lesions with multiparametric magnetic resonance imaging (mp-MRI) using whole-mount histological sections as the reference standard	Reference standard in study does not match that specified in protocol

Short Title	Title	Reason for Exclusion
Sahibzada (2016)	Validating multiparametric MRI for diagnosis and monitoring of prostate cancer in patients for active surveillance	MRI protocol does not satisfy the following criteria - diffusion weighted, contrast enhanced, at least 1.5T and b value of at least 800s/mm ²
Satasivam (2016)	Can Confirmatory Biopsy be Omitted in Patients with Prostate Cancer Favorable Diagnostic Features on Active Surveillance?	MRI protocol does not satisfy the following criteria - diffusion weighted, contrast enhanced, at least 1.5T and b value of at least 800s/mm ²
Schoots (2015)	Magnetic resonance imaging in active surveillance of prostate cancer: A systematic review	Systematic review- no additional articles identified for inclusion in this review
Schoots (2015)	Magnetic Resonance Imaging-targeted Biopsy May Enhance the Diagnostic Accuracy of Significant Prostate Cancer Detection Compared to Standard Transrectal Ultrasound-guided Biopsy: A Systematic Review and Meta-analysis	Study population is biopsy naive
Schoots (2017)	Role of MRI in low-risk prostate cancer: Finding the Wolf in sheep's clothing or the sheep in Wolf's clothing?	Review article but not a systematic review
Schulman (2017)	The Contemporary Role of Multiparametric Magnetic Resonance Imaging in Active Surveillance for Prostate Cancer	Systematic review- no additional articles identified for inclusion in this review
Scott (2015)	Is transperineal prostate biopsy more accurate than transrectal biopsy in determining final Gleason score and clinical risk category? A comparative analysis	Not a relevant study design (cross-sectional study)
Scott (2017)	The role of magnetic resonance image guided prostate biopsy in stratifying men for risk of extracapsular extension at radical prostatectomy	Conference abstract
Siddiqui (2013)	Magnetic resonance imaging/ultrasound-fusion biopsy significantly upgrades prostate cancer versus systematic 12-core transrectal ultrasound biopsy	Included a mixed population of suspected prostate cancer and proven prostate cancer with no sub group analysis
Siddiqui (2015)	Comparison of MR/ultrasound fusion-guided biopsy with ultrasound-guided biopsy for the diagnosis of prostate cancer	MRI protocol does not satisfy the following criteria - diffusion weighted, contrast enhanced, at least 1.5T and b value of at

Short Title	Title	Reason for Exclusion
		least 800s/mm ²
Siddiqui (2015)	Clinical implications of a multiparametric magnetic resonance imaging based nomogram applied to prostate cancer active surveillance	Study does not contain any relevant index tests Assessing a nomogram
Simmons (2014)	The PICTURE study - prostate imaging (multi-parametric MRI and Prostate HistoScanning™) compared to transperineal ultrasound guided biopsy for significant prostate cancer risk evaluation	Does not contain a population with low risk or intermediate cancer
Starobinets (2017)	Characterization and stratification of prostate lesions based on comprehensive multiparametric MRI using detailed whole-mount histopathology as a reference standard	Conference abstract
Syer (2017)	The diagnostic accuracy of high b-value diffusion- and T2-weighted imaging for the detection of prostate cancer: a meta-analysis	Does not contain a population with low risk or intermediate cancer
Taira (2013)	Transperineal template-guided mapping biopsy as a staging procedure to select patients best suited for active surveillance	Study does not contain any relevant index tests
Tan (2015)	Characteristics of detected and missed prostate cancer foci on 3-T multiparametric MRI using an endorectal coil correlated with whole-mount thin-section histopathology	Does not contain a population with low risk or intermediate cancer Mixed cancer populations
Thestrup (2016)	Biparametric versus multiparametric MRI in the diagnosis of prostate cancer	Reference standard in study does not match that specified in protocol
Thoeny (2014)	Metastases in normal-sized pelvic lymph nodes: detection with diffusion-weighted MR imaging	Not a relevant study design (cross-sectional study) Non randomised control trial
Thompson (2015)	Medium-term oncological outcomes for extended vs saturation biopsy and transrectal vs transperineal biopsy in active surveillance for prostate cancer	Not possible to calculate a 2x2 table from data presented in the study
Toner (2015)	Magnetic resonance imaging for prostate cancer: Comparative studies including radical prostatectomy specimens and template transperineal biopsy	Systematic review- no additional articles identified for inclusion in this review

Short Title	Title	Reason for Exclusion
Toner (2017)	Multiparametric magnetic resonance imaging for prostate cancer-a comparative study including radical prostatectomy specimens	Not a relevant study design (crosssectional study) Comparative study
Tosoian (2016)	Active Surveillance of Prostate Cancer: Use, Outcomes, Imaging, and Diagnostic Tools	Review article but not a systematic review
Tran (2017)	Magnetic Resonance Imaging-Ultrasound Fusion Biopsy During Prostate Cancer Active Surveillance	Reference standard in study does not match that specified in protocol
Tsivian (2017)	Assessing clinically significant prostate cancer: Diagnostic properties of multiparametric magnetic resonance imaging compared to three-dimensional transperineal template mapping histopathology	Does not contain a population of people with suspected/low risk/intermediate prostate cancer
Turkbey (2010)	Prostate cancer: Value of multiparametric MR imaging at 3 T for detection - Histopathologic correlation	MRI protocol does not satisfy the following criteria - diffusion weighted, contrast enhanced, at least 1.5T and b value of at least 800s/mm ²
van As (2009)	A Study of Diffusion-Weighted Magnetic Resonance Imaging in Men with Untreated Localised Prostate Cancer on Active Surveillance	Not possible to calculate a 2x2 table from data presented in the study
Vargas (2011)	Diffusion-weighted endorectal MR imaging at 3 T for prostate cancer: Tumor detection and assessment of aggressiveness	Not possible to calculate a 2x2 table from data presented in the study Comparison was between 2 readers and did not provide values for 2x2 calculations
Vargas (2012)	Magnetic resonance imaging for predicting prostate biopsy findings in patients considered for active surveillance of clinically low risk prostate cancer	Does not contain a population with low risk or intermediate cancer
Vargas (2012)	Performance characteristics of MR imaging in the evaluation of clinically low-risk prostate cancer: A prospective study	Not possible to calculate a 2x2 table from data presented in the study
Viana (2017)	The accuracy and validation of multiparametric magnetic resonance imaging (MPMRI) using PI-RADS V2 in	Conference abstract

Short Title	Title	Reason for Exclusion
	disease upgrading on re-biopsy among patients with low-risk prostate cancer on active surveillance (AS)-a Brazilian perspective	
von Below (2017)	Additional value of magnetic resonance-targeted biopsies to standard transrectal ultrasound-guided biopsies for detection of clinically significant prostate cancer	MRI protocol does not satisfy the following criteria - diffusion weighted, contrast enhanced, at least 1.5T and b value of at least 800s/mm ² Does not give details of the b values
Vos (2016)	Role of serial multiparametric magnetic resonance imaging in prostate cancer active surveillance	MRI protocol does not satisfy the following criteria - diffusion weighted, contrast enhanced, at least 1.5T and b value of at least 800s/mm ²
Wang (2017)	Determination of the Role of Negative Magnetic Resonance Imaging of the Prostate in Clinical Practice: Is Biopsy Still Necessary?	Does not contain a population with low risk or intermediate cancer
Washington (2012)	Transrectal ultrasonography-guided biopsy does not reliably identify dominant cancer location in men with low-risk prostate cancer	Restrospective study looking at participants before their follow up MRI or Biopsy
Woo (2018)	Diagnostic Performance of Magnetic Resonance Imaging for the Detection of Bone Metastasis in Prostate Cancer: A Systematic Review and Meta-analysis	Study populaton have high risk prostate cancer
Yoo (2018)	A novel biopsy-related parameter derived from location and relationship of positive cores on standard 12-core trans-rectal ultrasound-guided prostate biopsy: a useful parameter for predicting tumor volume compared to number of positive cores	Study not investigating progression or restaging of participants
Yoshida (2015)	Information of prostate biopsy positive core: does it affect MR detection of prostate cancer on using 3T-MRI?	Not possible to calculate a 2x2 table from data presented in the study
Zakian (2016)	Prostate MRSI predicts outcome in radical prostatectomy patients	Study population unclear
Zhang (2007)	Role of Endorectal Coil Magnetic Resonance Imaging in Treatment of Patients with Prostate Cancer and in Determining Radical Prostatectomy Surgical	Study does not contain any relevant index tests

Short Title	Title	Reason for Exclusion
	Margin Status: Report of a Single Surgeon's Practice	

1

2

Economic studies

Short Title	Title	Reason for exclusion
Venderink et al. 2017	Cost-Effectiveness Comparison of Imaging-Guided Prostate Biopsy Techniques: Systematic Transrectal Ultrasound, Direct In-Bore MRI, and Image Fusion	Not using the trans-perineal mapping biopsy as a reference
Willis et al 2015	A review of economic evaluations of diagnostic strategies using imaging in men at risk of prostate cancer	Review reporting already identified studies
Pahwa et al 2017	Cost-effectiveness of MR Imaging-guided Strategies for Detection of Prostate Cancer in Biopsy-Naive Men	Not using the trans-perineal mapping biopsy as a reference
Loeb et al 2017	Active Surveillance Versus Watchful Waiting for Localized Prostate Cancer: A Model to Inform Decisions	Men diagnosed with localised PC. Not using the trans-perineal mapping biopsy as a reference
Gordon et al 2017	Cost-effectiveness analysis of multiparametric MRI with increased active surveillance for low-risk prostate cancer in Australia	Men diagnosed with localised PC. Not using the trans-perineal mapping biopsy as a reference
Do Rooij et al 2014	Cost-effectiveness of magnetic resonance (MR) imaging and MR-guided targeted biopsy versus systematic transrectal ultrasound-guided biopsy in diagnosing prostate cancer: a modelling study from a health care perspective	Not using the trans-perineal mapping biopsy as a reference
Cerantola et al 2016	Cost-effectiveness of multiparametric magnetic resonance imaging and targeted biopsy in diagnosing prostate cancer	Not using the trans-perineal mapping biopsy as a reference
Mowatt et al 2013	The diagnostic accuracy and cost-effectiveness of magnetic resonance spectroscopy and enhanced magnetic resonance imaging techniques in aiding the localisation of prostate abnormalities for biopsy: a systematic review and economic evaluation	Different population (patients with previous negative biopsy)
Hovels et al 2009	Cost-effectiveness of MR lymphography for the detection of lymph node metastases in patients with prostate cancer	population and comparator out of the scope (MR Lymphography for the Detection of Lymph Node Metastases in Patients with Prostate Cancer)
Roth et al 2015	Cost-Effectiveness of a Biopsy-Based 8-Protein Prostate Cancer Prognostic Assay to Optimize Treatment Decision	Comparators out of the scope (PCA3)

Short Title	Title	Reason for exclusion
	Making in Gleason 3 + 3 and 3 + 4 Early Stage Prostate Cancer	
Faria et al 2018	Optimising the diagnosis of prostate cancer in the era of multiparametric magnetic resonance imaging: a cost-effectiveness analysis based on the Prostate MR Imaging Study (PROMIS)	different population: People suspected to be having prostate cancer
Nicholson et al 2015	The clinical effectiveness and cost-effectiveness of the PROGENSA prostate cancer antigen 3 assay and the Prostate Health Index in the diagnosis of prostate cancer: a systematic review and economic evaluation	Comparators out of the scope (PCA3)

1

1
2

Appendix H – References

Clinical studies - included

- 3 Barzell W E, Melamed M R, Cathcart P, Moore C M, Ahmed H U, and Emberton M (2012)
4 Identifying candidates for active surveillance: An evaluation of the repeat biopsy strategy for
5 men with favorable risk prostate cancer. *Journal of Urology* 188(3), 762-767
- 6 Chen K, Tay K J, Law Y M, Aydin H, Ho H, Cheng C, and Yuen J S. P (2017) Outcomes of
7 combination MRI-targeted and transperineal template biopsy in restaging low-risk prostate
8 cancer for active surveillance. *Asian Journal of Urology* ,
- 9 Da Rosa , M R, Milot L, Sugar L, Vesprini D, Chung H, Loblaw A, Pond G R, Klotz L, and
10 Haider M A (2015) A prospective comparison of MRI-US fused targeted biopsy versus
11 systematic ultrasound-guided biopsy for detecting clinically significant prostate cancer in
12 patients on active surveillance. *Journal of Magnetic Resonance Imaging* 41(1), 220-225
- 13 Feng T S, Sharif-Afshar A R, Smith S C, Miller J, Nguyen C, Li Q, Luthringer D, Li D, Saouaf
14 R, and Kim H L (2015) Multiparametric magnetic resonance imaging localizes established
15 extracapsular extension of prostate cancer. *Urologic Oncology: Seminars and Original*
16 *Investigations* 33(3), 109
- 17 Pessoa R R, Viana P C, Mattedi R L, Guglielmetti G B, Cordeiro M D, Coelho R F, Nahas W
18 C, and Srougi M (2017) Value of 3-Tesla multiparametric magnetic resonance imaging and
19 targeted biopsy for improved risk stratification in patients considered for active surveillance.
20 *BJU International* 119(4), 535-542

Clinical studies – excluded

- 22 A'Amar O M, Liou L, Rodriguez-Diaz E, De Las Morenas, A , and Bigio I J (2013)
23 Comparison of elastic scattering spectroscopy with histology in ex vivo prostate glands:
24 Potential application for optically guided biopsy and directed treatment. *Lasers in Medical*
25 *Science* 28(5), 1323-1329
- 26 Abd-Alazeez Mohamed, Ahmed Hashim U, Arya Manit, Allen Clare, Dikaios Nikolaos,
27 Freeman Alex, Emberton Mark, and Kirkham Alex (2014) Can multiparametric magnetic
28 resonance imaging predict upgrading of transrectal ultrasound biopsy results at more
29 definitive histology?. *Urologic oncology* 32(6), 741-7
- 30 Abd-Alazeez M, Kirkham A, Ahmed H U, Arya M, Anastasiadis E, Charman S C, Freeman A,
31 and Emberton M (2014) Performance of multiparametric MRI in men at risk of prostate
32 cancer before the first biopsy: A paired validating cohort study using template prostate
33 mapping biopsies as the reference standard. *Prostate Cancer and Prostatic Diseases* 17(1),
34 40-46
- 35 Abd-Alazeez M, Ramachandran N, Dikaios N, Ahmed H U, Emberton M, Kirkham A, Arya M,
36 Taylor S, Halligan S, and Punwani S (2015) Multiparametric MRI for detection of
37 radiorecurrent prostate cancer: Added value of apparent diffusion coefficient maps and
38 dynamic contrast-enhanced images. *Prostate Cancer and Prostatic Diseases* 18(2), 128-136
- 39 Abdi H, Pourmalek F, Zargar H, Walshe T, Harris A C, Chang S D, Eddy C, So A I, Gleave M
40 E, Machan L, Goldenberg S L, and Black P C (2015) Multiparametric magnetic resonance

- 1 imaging enhances detection of significant tumor in patients on active surveillance for prostate
2 cancer. *Urology* 85(2), 423-428
- 3 Abdollah F, Novara G, Briganti A, Scattoni V, Raber M, Roscigno M, Suardi N, Gallina A,
4 Artibani W, Ficarra V, Cestari A, Guazzoni G, Rigatti P, and Montorsi F (2011) Trans-rectal
5 versus trans-perineal saturation rebiopsy of the prostate: Is there a difference in cancer
6 detection rate?. *Urology* 77(4), 921-925
- 7 Abedi I, Tavakkoli M B, Rabbani M, Jabbari K, Sirous M, and Far G Y (2017) Multiparametric
8 magnetic resonance imaging of prostate cancer: Association of quantitative magnetic
9 resonance parameters with histopathologic findings. *Iranian Journal of Radiology* 14(3),
10 e37844
- 11 Abouassaly R, Lane B R, and Jones J S (2008) Staging Saturation Biopsy in Patients with
12 Prostate Cancer on Active Surveillance Protocol. *Urology* 71(4), 573-577
- 13 Abu V K (2011) The use of MRI scanning to triage patients. *British Journal of Nursing* 20(20),
14 1310-1314
- 15 Acar O, Esen T, Colakoglu B, Vural M, Onay A, Saglican Y, Turkbey B, and Rozanes I
16 (2015) Multiparametric MRI guidance in first-time prostate biopsies: What is the real benefit?.
17 *Diagnostic and Interventional Radiology* 21(4), 271-276
- 18 An J Y, Sidana A, Holzman S A, Baiocco J A, Mehralivand S, Choyke P L, Wood B J,
19 Turkbey B, and Pinto P A (2018) Ruling out clinically significant prostate cancer with negative
20 multi-parametric MRI. *International Urology and Nephrology* 50(1), 7-12
- 21 Anastasiadis E, Charman S C, Arumainayagam N, Sohaib A S, Allen C, Freeman A,
22 Emberton M, and Ahmed H U (2015) What Burden of Prostate Cancer Can Radiologists Rule
23 Out on Multiparametric Magnetic Resonance Imaging? A Sensitivity Analysis Based on
24 Varying the Target Condition in Template Prostate Mapping Biopsies. *Urology* 86(3), 544-
25 551
- 26 Arumainayagam N, Kumar S, Ahmed H U, Moore C M, Payne H, Freeman A, Allen C,
27 Kirkham A, and Emberton M (2010) Accuracy of multiparametric magnetic resonance
28 imaging in detecting recurrent prostate cancer after radiotherapy. *BJU International* 106(7),
29 991-997
- 30 Arumainayagam N, Ahmed H U, Moore C M, Freeman A, Allen C, Sohaib S A, Kirkham A,
31 Van Der Meulen , J , and Emberton M (2013) Multiparametric MR imaging for detection of
32 clinically significant prostate cancer: A validation cohort study with transperineal template
33 prostate mapping as the reference standard. *Radiology* 268(3), 761-769
- 34 Barnett C L, Aufferberg G B, Cheng Z, Yang F, Wang J, Wei J T, Miller D C, Montie J E,
35 Mamawala M, and Denton B T (2017) Optimizing active surveillance strategies to balance
36 the competing goals of early detection of grade progression and minimizing harm from
37 biopsies. *Cancer* ,
- 38 Barrett Tristan, Patterson Andrew J, Koo Brendan C, Wadhwa Karan, Warren Anne Y, Doble
39 Andrew, Gnanapragasam Vincent J, Kastner Christof, and Gallagher Ferdia A (2016)
40 Targeted transperineal biopsy of the prostate has limited additional benefit over background
41 cores for larger MRI-identified tumors. *World journal of urology* 34(4), 501-8
- 42 Barrett T, and Haider M A (2017) The emerging role of MRI in prostate cancer active
43 surveillance and ongoing challenges. *American Journal of Roentgenology* 208(1), 131-139

- 1 Barzell W E, and Melamed M R (2007) Appropriate Patient Selection in the Focal Treatment
2 of Prostate Cancer: The Role of Transperineal 3-Dimensional Pathologic Mapping of the
3 Prostate-A 4-Year Experience. *Urology* 70(6 SUPPL. 1), S27-S35
- 4 Becker A S, Cornelius A, Reiner C S, Stocker D, Ulbrich E J, Barth B K, Mortezavi A, Eberli
5 D, and Donati O F (2017) Direct comparison of PI-RADS version 2 and version 1 regarding
6 interreader agreement and diagnostic accuracy for the detection of clinically significant
7 prostate cancer. *European Journal of Radiology* 94, 58-63
- 8 Bittner N, Merrick G S, Butler W M, Bennett A, and Galbreath R W (2013) Incidence and
9 pathological features of prostate cancer detected on transperineal template guided mapping
10 biopsy after negative transrectal ultrasound guided biopsy. *Journal of Urology* 190(2), 509-
11 514
- 12 Bjurlin M A, Mendhiratta N, Wysock J S, and Taneja S S (2016) Multiparametric MRI and
13 targeted prostate biopsy: Improvements in cancer detection, localization, and risk
14 assessment. *Central European Journal of Urology* 69(1), 9-18
- 15 Bladou F, Fogaing C, Levental M, Aronson S, Alameldin M, and Anidjar M (2017) Transrectal
16 ultrasound-guided biopsy for prostate cancer detection: Systematic and/or magnetic-
17 resonance imaging-targeted. *Canadian Urological Association Journal* 11(9), E330-E337
- 18 Boesen L, Noergaard N, Chabanova E, Logager V, Balslev I, Mikines K, and Thomsen H S
19 (2015) Early experience with multiparametric magnetic resonance imaging-targeted biopsies
20 under visual transrectal ultrasound guidance in patients suspicious for prostate cancer
21 undergoing repeated biopsy. *Scandinavian Journal of Urology* 49(1), 25-34
- 22 Borkowetz A, Platzek I, Toma M, Laniado M, Baretton G, Froehner M, Koch R, Wirth M, and
23 Zastrow S (2015) Comparison of systematic transrectal biopsy to transperineal magnetic
24 resonance imaging/ultrasound-fusion biopsy for the diagnosis of prostate cancer. *BJU*
25 *International* 116(6), 873-879
- 26 Borkowetz A, Zastrow S, Platzek I, Toma M, Froehner M, Koch R, and Wirth M (2015)
27 Assessment of tumour aggressiveness in tranperineal mri/ultrasound-fusion biopsy in
28 comparison to transrectal systematic prostate biopsy. *Journal of urology*. 193(4 suppl. 1),
29 e596
- 30 Bosco C, Cozzi G, Kinsella J, Bianchi R, Acher P, Challacombe B, Popert R, Brown C,
31 George G, Van Hemelrijck , M , and Cahill D (2016) Confirmatory biopsy for the assessment
32 of prostate cancer in men considering active surveillance: Reference centre experience.
33 *ecancermedicalscience* 10, 633
- 34 Brock Marko, von Bodman , Christian , Palisaar Juri, Becker Wolfgang, Martin-Seidel Philipp,
35 and Noldus Joachim (2015) Detecting Prostate Cancer. *Deutsches Arzteblatt international*
36 112(37), 605-11
- 37 Brown L C, Gabe R, Hindley R G, Ahmed H U, Bosaily A E. S, Parker C, Cooper C, Oldroyd
38 R, Kaplan R, Brown L, Rhian Gabe, Collaco-Moraes Y, Adusei , Ward , Stewart S, Mulrenan
39 K T. C, Gardner H, Diaz-Montana C, Coyle C, Sculpher M, Faria R, David Guthrie, Chester J,
40 Cowan R, Jewitt M, Ahmed H, Coe J, El-Shater Bosaily, A , Emberton M, Freeman A, Hung
41 M, Jameson C, Kirkham A, Punwani S, Scott R, Hindley R, Edwards A, El-Mahallawi H,
42 Peppercorn D, Smith J, Thrower A, Winkler M, Ansu K, Barwick T, Edwards S, Honeyfield L,
43 Qazi N, Statton B, Stewart V, Temple E, Burns-Cox N, Burn P, Gordon K, Routley H,
44 McCormick A, Paterson D, Henderson A, Bernsten E, Casey R, Day D, Ghosh S, James J,
45 McMillan P J, Russell G, Persad R, Ash-Miles J, Elmahdy M, Pandian S, Shiridzinomwa C,

- 1 Sohail M, Treasure A, Ghei M, Conteh V, Harbin L, Katz R, Kumaradevan J, Trinidad A,
2 Verjee A, Dudderidge T, Smart J, Rosario D, Catto J, Selem F, Shergill I, and Agarwal S
3 (2015) PROMIS - Prostate MR imaging study: A paired validating cohort study evaluating the
4 role of multi-parametric MRI in men with clinical suspicion of prostate cancer. *Contemporary*
5 *Clinical Trials* 42, 26-40
- 6 Castellucci R, Altieri V M, Marchioni M, Castellan P, Pellegrini M, Alvarez-Maestro M,
7 Sanchez-Gomez J, De Francesco P, Ingrosso M, Tartaro A, and Tenaglia R L (2015)
8 Magnetic resonance spectroscopic imaging 3T and prostate cancer: correlation with
9 transperineal ultrasound guided prostate biopsy. *Archivos espanoles de urologia* 68(5), 493-
10 501
- 11 Chen J, Yi X L, Jiang L X, Wang R, Zhao J G, Li Y H, and Hu B (2015) 3-tesla magnetic
12 resonance imaging improves the prostate cancer detection rate in transrectal ultrasound-
13 guided biopsy. *Experimental and Therapeutic Medicine* 9(1), 207-212
- 14 Chen K, Tay K J, Law Y M, Aydin H, Ho H, Cheng C, and Yuen J S. P (2017) Outcomes of
15 combination MRI-targeted and transperineal template biopsy in restaging low-risk prostate
16 cancer for active surveillance. *Asian Journal of Urology* ,
- 17 Cool Dw, Romagnoli C, Izawa Ji, Chin J, Gardi L, Tessier D, Mercado A, Mandel J, Ward Ad,
18 and Fenster A (2016) Comparison of prostate MRI-3D transrectal ultrasound fusion biopsy
19 for first-time and repeat biopsy patients with previous atypical small acinar proliferation.
20 *Canadian urological association journal* 10(9-10), 342-348
- 21 Di Franco C A, Jallous H, Porru D, Giliberto G L, Cebrelli T, Tinelli C, and Rovereto B
22 (2017) A retrospective comparison between transrectal and transperineal prostate biopsy in
23 the detection of prostate cancer. *Archivio Italiano di Urologia e Andrologia* 89(1), 55-59
- 24 Dieffenbacher S C, Popeneciu I V, Radtke J P, Teber D, Hohenfellner M, Hadaschik B A,
25 and Hatiboglu G (2017) Diagnostic accuracy of transperineal MRI fusion biopsy in
26 comparison to transrectal biopsy with regard to incidental histopathological findings in
27 transurethral resection of the prostate. *Urologia Internationalis* 99(2), 162-167
- 28 Dikaios N, Alkalbani J, Sidhu H S, Fujiwara T, Abd-Alazeez M, Kirkham A, Allen C, Ahmed
29 H, Emberton M, Freeman A, Halligan S, Taylor S, Atkinson D, and Punwani S (2014) Logistic
30 regression model for diagnosis of transition zone prostate cancer on multi-parametric MRI.
31 *European Radiology* 25(2), 523-532
- 32 Dikaios N, Alkalbani J, Abd-Alazeez M, Sidhu H S, Kirkham A, Ahmed H U, Emberton M,
33 Freeman A, Halligan S, Taylor S, Atkinson D, and Punwani S (2015) Zone-specific logistic
34 regression models improve classification of prostate cancer on multi-parametric MRI.
35 *European Radiology* 25(9), 2727-2737
- 36 Donaldson I, Hamid S, Barratt D, Hu Y, Rodell R, Villarini B, Bonmati E, Martin P, Hawkes D,
37 McCartan N, Potyka I, Williams N, Brew-Graves C, Moore C, Emberton M, and Ahmed H
38 (2017) The smarttarget biopsy trial: a prospective paired blinded trial with randomisation to
39 compare visual-estimation and image-fusion targeted prostate biopsies. *Journal of urology*.
40 Conference: 112th annual meeting of the american urological association, and AUA 2017.
41 United states 197(4 Supplement 1), e425
- 42 Durand M, Jain M, Robinson B, Aronowitz E, El Douahy Y, Leung R, Scherr D S, Ng A,
43 Donzeau D, Amiel J, Spincemaille P, Villers A, and Ballon D J (2017) Magnetic resonance
44 microscopy may enable distinction between normal histomorphological features and prostate
45 cancer in the resected prostate gland. *BJU International* 119(3), 414-423

- 1 Elkhoury F F, Simopoulos D N, and Marks L S (2017) Targeted Prostate Biopsy in the Era of
2 Active Surveillance. *Urology* ,
- 3 Elkjaer M, Pedersen Bg, Andersen Mh, Hoyer S, and Borre M (2017) Multi-parametric
4 magnetic resonance imaging and magnetic resonance guided biopsies at active surveillance
5 inclusion selects prostate cancer patients for active treatment. *Scandinavian journal of*
6 *urology*. Conference: 31st NUF meeting. Denmark 51(220), 18-19
- 7 El-Shater Bosaily, A , Parker C, Brown L C, Gabe R, Hindley R G, Kaplan R, Emberton M,
8 Ahmed H U, and Group Promis (2015) PROMIS--Prostate MR imaging study: A paired
9 validating cohort study evaluating the role of multi-parametric MRI in men with clinical
10 suspicion of prostate cancer. *Contemporary clinical trials* 42, 26-40
- 11 Faiella Eliodoro, Santucci Domiziana, Greco Federico, Frauenfelder Giulia, Giacobbe Viola,
12 Muto Giovanni, Zobel Bruno Beomonte, and Grasso Rosario Francesco (2018) Analysis of
13 histological findings obtained combining US/mp-MRI fusion-guided biopsies with systematic
14 US biopsies: mp-MRI role in prostate cancer detection and false negative. *La Radiologia*
15 *medica* 123(2), 143-152
- 16 Felker E R, Lee-Felker S A, Feller J, Margolis D J, Lu D S, Princenthal R, May S, Cohen M,
17 Huang J, Yoshida J, Greenwood B, Kim H J, and Raman S S (2016) In-bore magnetic
18 resonance-guided transrectal biopsy for the detection of clinically significant prostate cancer.
19 *Abdominal Radiology* 41(5), 954-962
- 20 Ferrari F S, Scorzelli A, Megliola A, Drudi F M, Trovarelli S, and Ponchietti R (2009) Real-
21 time elastography in the diagnosis of prostate tumor. *Journal of Ultrasound* 12(1), 22-31
- 22 Ferriero M, Giacobbe A, Collura D, Papalia R, Guaglianone S, Muto G, Gallucci M, and
23 Simone G (2016) Diagnostic performance of multiparametric MRI in prostate cancer: per
24 core analysis of two prospective ultrasound/MRI fusion biopsy datasets. *Journal of*
25 *endourology*. Conference: 34th world congress of endourology, and WCE 2016. South africa.
26 Conference start: 20161108. Conference end: 20161112 30, A29-a30
- 27 Fusco R, Sansone M, Granata V, Setola S V, and Petrillo A (2017) A systematic review on
28 multiparametric MR imaging in prostate cancer detection. *Infectious Agents and Cancer*
29 12(1), 57
- 30 Futterer J J, Briganti A, De Visschere , P , Emberton M, Giannarini G, Kirkham A, Taneja S
31 S, Thoeny H, Villeirs G, and Villers A (2015) Can Clinically Significant Prostate Cancer Be
32 Detected with Multiparametric Magnetic Resonance Imaging? A Systematic Review of the
33 Literature. *European Urology* 68(6), 1045-1053
- 34 Garcia C, Winter M, Bergersen P, Woo H, and Chalasani V (2016) Transperineal versus
35 transrectal prostate biopsy in prostate cancer detection: a systematic review with meta-
36 analysis. *BJU international*. 117, 38
- 37 Garcia C, Winter M, Bergersen P, Woo H, and Chalasani V (2016) Does transperineal
38 prostate biopsy reduce complications compared with transrectal biopsy? A systematic review
39 and metaanalysis of randomised controlled trials. *BJU international*. 117, 68-69
- 40 Garcia Bennett, J , Vilanova J C, Guma Padro, J , Parada D, and Conejero A (2017)
41 Evaluation of MR imaging-targeted biopsies of the prostate in biopsy-naive patients. A single
42 centre study. *Diagnostic and Interventional Imaging* 98(10), 677-684

- 1 Gayet M, Van Der Aa , A , Beerlage H P, Schrier B P, Mulders P F. A, and Wijkstra H (2016)
2 The value of magnetic resonance imaging and ultrasonography (MRI/US)-fusion biopsy
3 platforms in prostate cancer detection: A systematic review. *BJU International* 117(3), 392-
4 400
- 5 Gaziev G, Wadhwa K, Barrett T, Koo B C, Gallagher F A, Serrao E, Frey J, Seidenader J,
6 Carmona L, Warren A, Gnanapragasam V, Doble A, and Kastner C (2016) Defining the
7 learning curve for multiparametric magnetic resonance imaging (MRI) of the prostate using
8 MRI-transrectal ultrasonography (TRUS) fusion-guided transperineal prostate biopsies as a
9 validation tool. *BJU International* 117(1), 80-86
- 10 Gnanapragasam V J, Burling K, George A, Stearn S, Warren A, Barrett T, Koo B, Gallagher
11 F A, Doble A, Kastner C, and Parker R A (2016) The Prostate Health Index adds predictive
12 value to multi-parametric MRI in detecting significant prostate cancers in a repeat biopsy
13 population. *Scientific reports* 6, 35364
- 14 Gomez-Iturriaga A, Casquero F, Lopez J I, Urresola A, Ezquerro A, Buscher D, Bilbao P, and
15 Crook J (2017) Transperineal biopsies of MRI-detected aggressive index lesions in low- and
16 intermediate-risk prostate cancer patients: Implications for treatment decision. *Brachytherapy*
17 16(1), 201-206
- 18 Gordetsky J B, Nix J W, and Rais-Bahrami S (2016) Perineural Invasion in Prostate Cancer
19 Is More Frequently Detected by Multiparametric MRI Targeted Biopsy Compared With
20 Standard Biopsy. *The American journal of surgical pathology* 40(4), 490-494
- 21 Grey A D. R, Chana M S, Popert R, Wolfe K, Liyanage S H, and Acher P L (2015) Diagnostic
22 accuracy of magnetic resonance imaging (MRI) prostate imaging reporting and data system
23 (PI-RADS) scoring in a transperineal prostate biopsy setting. *BJU International* 115(5), 728-
24 735
- 25 Grummet J (2017) How to Biopsy: Transperineal Versus Transrectal, Saturation Versus
26 Targeted, What's the Evidence?. *Urologic Clinics of North America* 44(4), 525-534
- 27 Habchi H, Bratan F, Paye A, Pagnoux G, Sanzalone T, Mege-Lechevallier F, Crouzet S,
28 Colombel M, Rabilloud M, and Rouviere O (2014) Value of prostate multiparametric magnetic
29 resonance imaging for predicting biopsy results in first or repeat biopsy. *Clinical Radiology*
30 69(3), e120-e128
- 31 Habibian David J, Liu Corinne C, Dao Alex, Kosinski Kaitlin E, and Katz Aaron E (2017)
32 Imaging Characteristics of Prostate Cancer Patients Who Discontinued Active Surveillance
33 on 3-T Multiparametric Prostate MRI. *AJR. American journal of roentgenology* 208(3), 564-
34 569
- 35 Hakozaiki Y, Matsushima H, Kumagai J, Murata T, Masuda T, Hirai Y, Oda M, Kawauchi N,
36 Yokoyama M, and Homma Y (2017) A prospective study of magnetic resonance imaging and
37 ultrasonography (MRI/US)-fusion targeted biopsy and concurrent systematic transperineal
38 biopsy with the average of 18-cores to detect clinically significant prostate cancer. *BMC*
39 *Urology* 17(1), 117
- 40 Hamoen E H. J, Hoeks C M. A, Somford D M, van Oort , I M, Vergunst H, Oddens J R, Smits
41 G A, Bokhorst L P, Witjes J A, Rovers M M, Hulsbergen-van de Kaa, C A, and Barentsz J O
42 (2018) Value of Serial Multiparametric Magnetic Resonance Imaging and Magnetic
43 Resonance Imaging-guided Biopsies in Men with Low-risk Prostate Cancer on Active
44 Surveillance After 1 Yr Follow-up. *European Urology Focus* ,

- 1 Hansen N, Patruno G, Wadhwa K, Gaziev G, Miano R, Barrett T, Gnanapragasam V, Doble
2 A, Warren A, Bratt O, and Kastner C (2016) Magnetic Resonance and Ultrasound Image
3 Fusion Supported Transperineal Prostate Biopsy Using the Ginsburg Protocol: Technique,
4 Learning Points, and Biopsy Results. *European Urology* 70(2), 332-340
- 5 Hansen N L, Caglic I, Berman L H, Kastner C, Doble A, and Barrett T (2016) Multiparametric
6 Prostate Magnetic Resonance Imaging and Cognitively Targeted Transperineal Biopsy in
7 Patients With Previous Abdominoperineal Resection and Suspicion of Prostate Cancer.
8 *Urology* 96, 8-14
- 9 Hansen N L, Kesch C, Barrett T, Koo B, Radtke J P, Bonekamp D, Schlemmer H P, Warren
10 A Y, Wieczorek K, Hohenfellner M, Kastner C, and Hadaschik B (2017) Multicentre
11 evaluation of targeted and systematic biopsies using magnetic resonance and ultrasound
12 image-fusion guided transperineal prostate biopsy in patients with a previous negative
13 biopsy. *BJU International* 120(5), 631-638
- 14 Hansen N L, Koo B C, Warren A Y, Kastner C, and Barrett T (2017) Sub-differentiating
15 equivocal PI-RADS-3 lesions in multiparametric magnetic resonance imaging of the prostate
16 to improve cancer detection. *European Journal of Radiology* 95, 307-313
- 17 Hansford B G, Karademir I, Peng Y, Jiang Y, Karczmar G, Thomas S, Yousuf A, Antic T,
18 Eggener S, and Oto A (2014) Dynamic contrast-enhanced MR imaging features of the
19 normal central zone of the prostate. *Academic Radiology* 21(5), 569-577
- 20 Hausmann D, Aksoz N, von Hardenberg , J , Martini T, Westhoff N, Buettner S, Schoenberg
21 S O, and Riffel P (2018) Prostate cancer detection among readers with different degree of
22 experience using ultra-high b-value diffusion-weighted Imaging: Is a non-contrast protocol
23 sufficient to detect significant cancer?. *European Radiology* 28(2), 869-876
- 24 Hauth E, Hohmuth H, Cozub-Poetica C, Bernand S, Beer M, and Jaeger H (2015)
25 Multiparametric MRI of the prostate with three functional techniques in patients with PSA
26 elevation before initial TRUS-guided biopsy. *British Journal of Radiology* 88(1054), 20150422
- 27 Hu Y, Ahmed H U, Carter T, Arumainayagam N, Lecornet E, Barzell W, Freeman A, Nevoux
28 P, Hawkes D J, Villers A, Emberton M, and Barratt D C (2012) A biopsy simulation study to
29 assess the accuracy of several transrectal ultrasonography (TRUS)-biopsy strategies
30 compared with template prostate mapping biopsies in patients who have undergone radical
31 prostatectomy. *BJU International* 110(6), 812-820
- 32 Isbarn H, Briganti A, De Visschere , P J, Futterer J J, Ghadjar P, Giannarini G, Ost P,
33 Ploussard G, Sooriakumaran P, Surcel C I, van Oort , I M, Yossepowitch O, van den Bergh ,
34 and R C (2015) Systematic ultrasound-guided saturation and template biopsy of the prostate:
35 indications and advantages of extended sampling. *Archivos espanoles de urologia* 68(3),
36 296-306
- 37 Ishioka J, Matsuoka Y, Itoh M, Inoue M, Kijima T, Yoshida S, Yokoyama M, Saito K, Kihara
38 K, Fujii Y, Tanaka H, and Kimura T (2017) Computer-aided diagnosis of prostate cancer
39 using a deep neural networks algorithm in prebiopsy multiparametric magnetic resonance
40 imaging. *Journal of urology*. Conference: 112th annual meeting of the american urological
41 association, and AUA 2017. United states 197(4 Supplement 1), e209
- 42 Jambor I, Kahkonen E, Taimen P, Merisaari H, Saunavaara J, Alanen K, Obsitnik B, Minn H,
43 Lehotska V, and Aronen H J (2015) Prebiopsy multiparametric 3T prostate MRI in patients
44 with elevated PSA, normal digital rectal examination, and no previous biopsy. *Journal of*
45 *Magnetic Resonance Imaging* 41(5), 1394-1404

- 1 Javed S, Chadwick E, Edwards Aa, Beveridge S, Laing R, Bott S, Eden C, and Langley S
2 (2014) Does prostate HistoScanning? play a role in detecting prostate cancer in routine
3 clinical practice? Results from three independent studies. *BJU international* 114(4), 541-548
- 4 Jiang X, Zhang J, Tang J, Xu Z, Zhang W, Zhang Q, Guo H, and Zhou W (2016) Magnetic
5 resonance imaging - Ultrasound fusion targeted biopsy outperforms standard approaches in
6 detecting prostate cancer: A meta-analysis. *Molecular and Clinical Oncology* 5(2), 301-309
- 7 Jones T A, Radtke J P, Hadaschik B, and Marks L S (2016) Optimizing safety and accuracy
8 of prostate biopsy. *Current Opinion in Urology* 26(5), 472-480
- 9 Jue J S, Barboza M P, Prakash N S, Venkatramani V, Sinha V R, Pavan N, Nahar B,
10 Kanabur P, Ahdoot M, Dong Y, Satyanarayana R, Parekh D J, and Punnen S (2017) Re-
11 examining Prostate-specific Antigen (PSA) Density: Defining the Optimal PSA Range and
12 Patients for Using PSA Density to Predict Prostate Cancer Using Extended Template Biopsy.
13 *Urology* 105, 123-128
- 14 Kamoi K, Okihara K, Ochiai A, Ukimura O, Mizutani Y, Kawauchi A, and Miki T (2008) The
15 Utility of Transrectal Real-Time Elastography in the Diagnosis of Prostate Cancer.
16 *Ultrasound in Medicine and Biology* 34(7), 1025-1032
- 17 Kanoun S, Walker P, Vrigneaud J-M, Depardon E, Barbier V, Humbert O, Moulin M,
18 Crehange G, Cormier L, Loffroy R, Brunotte F, and Cochet A (2017) 18F-Choline Positron
19 Emission Tomography/Computed Tomography and Multiparametric Magnetic Resonance
20 Imaging for the Detection of Early Local Recurrence of Prostate Cancer Initially Treated by
21 Radiation Therapy: comparison With Systematic 3-Dimensional Transperineal Mapping
22 Biopsy. *International journal of radiation oncology biology physics* 97(5), 986-994
- 23 Kanthabalan A, Emberton M, and Ahmed H U (2014) Biopsy strategies for selecting patients
24 for focal therapy for prostate cancer. *Current Opinion in Urology* 24(3), 209-217
- 25 Kanthabalan A, Abd-Alazeez M, Arya M, Allen C, Freeman A, Jameson C, Kirkham A, Mitra
26 A V, Payne H, Punwani S, Ramachandran N, Walkden M, Emberton M, and Ahmed H U
27 (2016) Transperineal Magnetic Resonance Imaging-targeted Biopsy versus Transperineal
28 Template Prostate Mapping Biopsy in the Detection of Localised Radio-recurrent Prostate
29 Cancer. *Clinical Oncology* 28(9), 568-576
- 30 Kapoor J, Lamb A D, and Murphy D G (2017) Re: Diagnostic Accuracy of Multi-parametric
31 MRI and TRUS Biopsy in Prostate Cancer (PROMIS): A Paired Validating Confirmatory
32 Study. *European Urology* 72(1), 151
- 33 Kasivisvanathan V, Dufour R, Moore C M, Ahmed H U, Abd-Alazeez M, Charman S C,
34 Freeman A, Allen C, Kirkham A, Van Der Meulen , J , and Emberton M (2013) Transperineal
35 magnetic resonance image targeted prostate biopsy versus transperineal template prostate
36 biopsy in the detection of clinically significant prostate cancer. *Journal of Urology* 189(3),
37 860-866
- 38 Kawakami S, Okuno T, Yonese J, Igari T, Arai G, Fujii Y, Kageyama Y, Fukui I, and Kihara K
39 (2007) Optimal Sampling Sites for Repeat Prostate Biopsy: A Recursive Partitioning Analysis
40 of Three-Dimensional 26-Core Systematic Biopsy. *European Urology* 51(3), 675-683
- 41 Kravchick S, Lobik L, Cytron S, Kravchenko Y, Dor D B, and Peled R (2015) Patients with
42 Persistently Elevated PSA and Negative Results of TRUS-Biopsy: Does 6-Month Treatment
43 with Dutasteride can Indicate Candidates for Re-Biopsy. What is the Best of Saturation

- 1 Schemes: Transrectal or Transperineal Approach?. Pathology and Oncology Research
2 21(4), 985-989
- 3 Kroenig M, Schaal K, Benndorf M, Soschynski M, Lenz P, Krauss T, Drendel V, Kayser G,
4 Kurz P, Werner M, Wetterauer U, Schultze-Seemann W, Langer M, and Jilg C A (2016)
5 Diagnostic Accuracy of Robot-Guided, Software Based Transperineal MRI/TRUS Fusion
6 Biopsy of the Prostate in a High Risk Population of Previously Biopsy Negative Men. BioMed
7 Research International 2016, 2384894
- 8 Lai W S, Zarzour J G, Gordetsky J B, and Rais-Bahrami S (2017) Co-registration of MRI and
9 ultrasound: Accuracy of targeting based on radiology-pathology correlation. Translational
10 Andrology and Urology 6(3), 406-412
- 11 Lane B R, Zippe C D, Abouassaly R, Schoenfield L, Magi-Galluzzi C, and Jones J S (2008)
12 Saturation Technique Does Not Decrease Cancer Detection During Followup After Initial
13 Prostate Biopsy. Journal of Urology 179(5), 1746-1750
- 14 Le J D, Huang J, and Marks L S (2014) Targeted prostate biopsy: Value of multiparametric
15 magnetic resonance imaging in detection of localized cancer. Asian Journal of Andrology
16 16(4), 522-529
- 17 Lebovici A, Sfrangeu S A, Caraiani C, Lucan C, Suci M, Elec F, Iacob G, and Buruian M
18 (2015) Value of Endorectal MRI in Romanian Men for High Risk of Prostate Cancer: MRI
19 Findings Compared with Saturation Biopsy. Chirurgia (Bucharest, and Romania : 1990)
20 110(3), 262-267
- 21 Lee D H, Nam J K, Park S W, Lee S S, Han J Y, Lee S D, Lee J W, and Chung M K (2016)
22 Visually estimated MRI targeted prostate biopsy could improve the detection of significant
23 prostate cancer in patients with a PSA level <10 ng/mL. Yonsei Medical Journal 57(3), 565-
24 571
- 25 Lee Hakmin, Kim Chan Kyo, Park Byung Kwan, Sung Hyun Hwan, Han Deok Hyun, Jeon
26 Hwang Gyun, Jeong Byong Chang, Seo Seong Il, Jeon Seong Soo, Choi Han Yong, and Lee
27 Hyun Moo (2017) Accuracy of preoperative multiparametric magnetic resonance imaging for
28 prediction of unfavorable pathology in patients with localized prostate cancer undergoing
29 radical prostatectomy. World journal of urology 35(6), 929-934
- 30 Lee D H, Nam J K, Lee S S, Han J Y, Lee J W, Chung M K, and Park S W (2017)
31 Comparison of multiparametric and biparametric MRI in first round cognitive targeted
32 prostate biopsy in patients with PSA levels under 10 ng/mL. Yonsei Medical Journal 58(5),
33 994-999
- 34 Li Y H, Elshafei A, Li J, Gong M, Susan L, Fareed K, and Jones J S (2014) Transrectal
35 saturation technique may improve cancer detection as an initial prostate biopsy strategy in
36 men with prostate-specific antigen <10 ng/ml. European Urology 65(6), 1178-1183
- 37 Linder B J, Frank I, Umbreit E C, Shimko M S, Fernandez N, Rangel L J, and Karnes R J
38 (2013) Standard and saturation transrectal prostate biopsy techniques are equally accurate
39 among prostate cancer active surveillance candidates. International Journal of Urology 20(9),
40 860-864
- 41 Lu A J, Syed J S, Nguyen K A, Nawaf C B, Rosoff J, Spektor M, Levi A, Humphrey P A,
42 Weinreb J C, Schulam P G, and Sprenkle P C (2017) Negative Multiparametric Magnetic
43 Resonance Imaging of the Prostate Predicts Absence of Clinically Significant Prostate
44 Cancer on 12-Core Template Prostate Biopsy. Urology 105, 118-122

- 1 Ma T M, Tosoian J J, Schaeffer E M, Landis P, Wolf S, Macura K J, Epstein J I, Mamawala
2 M, and Carter H B (2017) The Role of Multiparametric Magnetic Resonance
3 Imaging/Ultrasound Fusion Biopsy in Active Surveillance. *European Urology* 71(2), 174-180
- 4 Mabweesh N J, Lidawi G, Chen J, German L, and Matzkin H (2012) High detection rate of
5 significant prostate tumours in anterior zones using transperineal ultrasound-guided template
6 saturation biopsy. *BJU International* 110(7), 993-997
- 7 Mariotti G C, Falsarella P M, Garcia R G, Queiroz M R. G, Lemos G C, and Baroni R H
8 (2018) Incremental diagnostic value of targeted biopsy using MP-MRI-TRUS fusion versus
9 14-fragments prostatic biopsy: a prospective controlled study. *European Radiology* 28(1), 11-
10 16
- 11 Marra G, Eldred-Evans D, Challacombe B, Van Hemelrijck , M , Polson A, Pomplun S, Foster
12 C S, Brown C, Cahill D, Gontero P, Popert R, and Muir G (2017) Pathological concordance
13 between prostate biopsies and radical prostatectomy using transperineal sector mapping
14 biopsies: Validation and comparison with transrectal biopsies. *Urologia Internationalis* 99(2),
15 168-176
- 16 Martorana E, Pirola G M, Scialpi M, Micali S, Iseppi A, Bonetti L R, Kaleci S, Torricelli P, and
17 Bianchi G (2017) Lesion volume predicts prostate cancer risk and aggressiveness: validation
18 of its value alone and matched with prostate imaging reporting and data system score. *BJU*
19 *International* 120(1), 92-103
- 20 McCammack K C, Schenker-Ahmed N M, White N S, Best S R, Marks R M, Heimbigner J,
21 Kane C J, Parsons J K, Kuperman J M, Bartsch H, Desikan R S, Rakow-Penner R A, Liss M
22 A, Margolis D J. A, Raman S S, Shabaik A, Dale A M, and Karow D S (2016) Restriction
23 spectrum imaging improves MRI-based prostate cancer detection. *Abdominal Radiology*
24 41(5), 946-953
- 25 Merrick G S, Delatore A, Butler W M, Bennett A, Fiano R, Anderson R, and Adamovich E
26 (2017) Transperineal template-guided mapping biopsy identifies pathologic differences
27 between very-low-risk and low-risk prostate cancer: Implications for active surveillance.
28 *American Journal of Clinical Oncology: Cancer Clinical Trials* 40(1), 53-59
- 29 Merrick Gregory S, Galbreath Robert W, Bennett Abbey, Butler Wayne M, and Amamovich
30 Edward (2017) Incidence, grade and distribution of prostate cancer following transperineal
31 template-guided mapping biopsy in patients with atypical small acinar proliferation. *World*
32 *journal of urology* 35(7), 1009-1013
- 33 Miakhil I, Macneal P, Sadien I, Yeong Tt, Larner T, Kommu S, Lockett C, Garnett S, and
34 Rimington P (2017) Predictive value of multiparametric MRI (MP-MRI) for the detection of
35 prostate cancer using 12-core trus-guided prostate biopsy-a United Kingdom multicenter
36 study. *Journal of urology*. Conference: 112th annual meeting of the american urological
37 association, and AUA 2017. United states 197(4 Supplement 1), e484-e485
- 38 Miano R, De Nunzio , C , Kim F J, Rocco B, Gontero P, Vicentini C, Micali S, Oderda M,
39 Masciovecchio S, and Asimakopoulos A D (2014) Transperineal versus transrectal prostate
40 biopsy for predicting the final laterality of prostate cancer: Are they reliable enough to select
41 patients for focal therapy? Results from a multicenter international study. *International Braz J*
42 *Urol* 40(1), 16-22
- 43 Moldovan P C, Van den Broeck , T , Sylvester R, Marconi L, Bellmunt J, van den Bergh , R C
44 N, Bolla M, Briers E, Cumberbatch M G, Fossati N, Gross T, Henry A M, Joniau S, van der
45 Kwast , T H, Matveev V B, van der Poel , H G, De Santis , M , Schoots I G, Wiegel T, Yuan C

- 1 Y, Cornford P, Mottet N, Lam T B, and Rouviere O (2017) What Is the Negative Predictive
2 Value of Multiparametric Magnetic Resonance Imaging in Excluding Prostate Cancer at
3 Biopsy? A Systematic Review and Meta-analysis from the European Association of Urology
4 Prostate Cancer Guidelines Panel. *European Urology* 72(2), 250-266
- 5 Monni F, Fontanella P, Grasso A, Wiklund P, Ou Y C, Randazzo M, Rocco B, Montanari E,
6 and Bianchi G (2017) Magnetic resonance imaging in prostate cancer detection and
7 management: A systematic review. *Minerva Urologica e Nefrologica* 69(6), 567-578
- 8 Moore C M, Robertson N L, Arsanious N, Middleton T, Villers A, Klotz L, Taneja S S, and
9 Emberton M (2013) Image-guided prostate biopsy using magnetic resonance imaging-
10 derived targets: A systematic review. *European Urology* 63(1), 125-140
- 11 Mukherjee A, Morton S, Fraser S, Salmond J, Baxter G, and Leung H Y (2014) Magnetic
12 resonance imaging-directed transperineal limited-mapping prostatic biopsies to diagnose
13 prostate cancer: A scottish experience. *Scottish Medical Journal* 59(4), 204-208
- 14 Muthigi A, George Ak, Sidana A, Kongnyuy M, Simon R, Moreno V, Merino Mj, Choyke Pl,
15 Turkbey B, Wood Bj, and Pinto Pa (2017) Missing the Mark: prostate Cancer Upgrading by
16 Systematic Biopsy over Magnetic Resonance Imaging/Transrectal Ultrasound Fusion Biopsy.
17 *Journal of urology* 197(2), 327-334
- 18 Nakai Y, Tanaka N, Anai S, Miyake M, Hori S, Tatsumi Y, Morizawa Y, Fujii T, Konishi N,
19 and Fujimoto K (2017) Transperineal template-guided saturation biopsy aimed at sampling
20 one core for each milliliter of prostate volume: 103 cases requiring repeat prostate biopsy.
21 *BMC Urology* 17(1), 1-6
- 22 Numao N, Kawakami S, Yokoyama M, Yonese J, Arisawa C, Ishikawa Y, Ando M, Fukui I,
23 and Kihara K (2007) Improved Accuracy in Predicting the Presence of Gleason Pattern 4/5
24 Prostate Cancer by Three-Dimensional 26-Core Systematic Biopsy. *European Urology* 52(6),
25 1663-1669
- 26 Oberlin D T, Casalino D D, Miller F H, Matulewicz R S, Perry K T, Nadler R B, Kundu S,
27 Catalona W J, and Meeks J J (2016) Diagnostic Value of Guided Biopsies: Fusion and
28 Cognitive-registration Magnetic Resonance Imaging Versus Conventional Ultrasound Biopsy
29 of the Prostate. *Urology* 92, 75-79
- 30 Ong W L, Weerakoon M, Huang S, Paul E, Lawrentschuk N, Frydenberg M, Moon D, Murphy
31 D, and Grummet J (2015) Transperineal biopsy prostate cancer detection in first biopsy and
32 repeat biopsy after negative transrectal ultrasound-guided biopsy: The Victorian
33 Transperineal Biopsy Collaboration experience. *BJU International* 116(4), 568-576
- 34 Orczyk C, Peng Hu Y, Gibson E, El-Shater Bosaily A, Kirkham A, Punwani S, Brown L,
35 Bonmati E, Coraco-Moraes Y, Ward K, Kaplan R, Barratt D, Emberton M, and Ahmed Hu
36 (2017) Should we aim for the centre of an MRI prostate lesion? Correlation between MP-MRI
37 and 3-dimensional 5mm transperineal prostate mapping biopsies from the promis trial.
38 *Journal of urology*. Conference: 112th annual meeting of the american urological association,
39 and AUA 2017. United states 197(4 Supplement 1), e486
- 40 Pal R P, Elmussareh M, Chanawani M, and Khan M A (2012) The role of a standardized 36
41 core template-assisted transperineal prostate biopsy technique in patients with previously
42 negative transrectal ultrasonography-guided prostate biopsies. *BJU International* 109(3),
43 367-371

- 1 Pepe P, and Aragona F (2011) Does an inflammatory pattern at primary biopsy suggest a
2 lower risk for prostate cancer at repeated saturation prostate biopsy?. *Urologia*
3 *Internationalis* 87(2), 171-174
- 4 Pepe P, Pennisi M, and Fraggetta F (2015) Anterior prostate biopsy at initial and repeat
5 evaluation: is it useful to detect significant prostate cancer?. *International braz j urol : official*
6 *journal of the Brazilian Society of Urology* 41(5), 844-848
- 7 Pepe P, Garufi A, Priolo G, and Pennisi M (2015) Can 3-tesla pelvic phased-array
8 multiparametric MRI avoid unnecessary repeat prostate biopsy in patients with PSA < 10
9 ng/mL?. *Clinical Genitourinary Cancer* 13(1), e27-e30
- 10 Pepe P, Garufi A, Priolo G, and Pennisi M (2016) Can MRI/TRUS fusion targeted biopsy
11 replace saturation prostate biopsy in the re-evaluation of men in active surveillance?. *World*
12 *journal of urology* 34(9), 1249-1253
- 13 Pepe Pietro, Cimino Sebastiano, Garufi Antonio, Priolo Giandomenico, Russo Giorgio Ivan,
14 Giardina Raimondo, Reale Giulio, Barbera Michele, Panella Paolo, Pennisi Michele, and
15 Morgia Giuseppe (2016) Detection rate for significant cancer at confirmatory biopsy in men
16 enrolled in Active Surveillance protocol: 20 cores vs 30 cores vs MRI/TRUS fusion prostate
17 biopsy. *Archivio italiano di urologia, and andrologia : organo ufficiale [di] Societa italiana di*
18 *ecografia urologica e nefrologica* 88(4), 300-303
- 19 Pepe P, Cimino S, Garufi A, Priolo G, Russo G I, Giardina R, Reale G, Pennisi M, and
20 Morgia G (2017) Confirmatory biopsy of men under active surveillance: extended versus
21 saturation versus multiparametric magnetic resonance imaging/transrectal ultrasound fusion
22 prostate biopsy. *Scandinavian Journal of Urology* 51(4), 260-263
- 23 Pepe P, Garufi A, Priolo G, and Pennisi M (2017) Transperineal Versus Transrectal
24 MRI/TRUS Fusion Targeted Biopsy: Detection Rate of Clinically Significant Prostate Cancer.
25 *Clinical Genitourinary Cancer* 15(1), e33-e36
- 26 Pepe P, Garufi A, Priolo G D, and Pennisi M (2017) Multiparametric MRI/TRUS fusion
27 prostate biopsy: Advantages of a transperineal approach. *Anticancer Research* 37(6), 3291-
28 3294
- 29 Pessoa R R, Viana P C, Mattedi R L, Guglielmetti G B, Cordeiro M D, Coelho R F, Nahas W
30 C, and Srougi M (2017) Value of 3-Tesla multiparametric magnetic resonance imaging and
31 targeted biopsy for improved risk stratification in patients considered for active surveillance.
32 *BJU International* 119(4), 535-542
- 33 Pokharel S S, Patel N U, Garg K, La Rosa , F G, Arangua P, Jones C, and Crawford E D
34 (2014) Multi-parametric MRI findings of transitional zone prostate cancers: correlation with 3-
35 dimensional transperineal mapping biopsy. *Abdominal Imaging* ,
- 36 Raber M, Scattoni V, Gallina A, Freschi M, De Almeyda , E P, Girolamo V D, Montorsi F, and
37 Rigatti P (2012) Does the transrectal ultrasound probe influence prostate cancer detection in
38 patients undergoing an extended prostate biopsy scheme? Results of a large retrospective
39 study. *BJU International* 109(5), 672-677
- 40 Radtke J P, Kuru T H, Boxler S, Alt C D, Popeneciu I V, Huettenbrink C, Klein T, Steinemann
41 S, Bergstraesser C, Roethke M, Roth W, Schlemmer H P, Hohenfellner M, and Hadaschik B
42 A (2015) Comparative Analysis of Transperineal Template Saturation Prostate Biopsy
43 Versus Magnetic Resonance Imaging Targeted Biopsy with Magnetic Resonance Imaging-
44 Ultrasound Fusion Guidance. *Journal of Urology* 193(1), 87-94

- 1 Radtke Jan P, Kuru Timur H, Boxler Silvan, Alt Celine D, Popeneciu Ionel V, Huettenbrink
2 Clemens, Klein Tilman, Steinemann Sarah, Bergstraesser Claudia, Roethke Matthias, Roth
3 Wilfried, Schlemmer Heinz-Peter, Hohenfellner Markus, and Hadaschik Boris A (2015)
4 Comparative analysis of transperineal template saturation prostate biopsy versus magnetic
5 resonance imaging targeted biopsy with magnetic resonance imaging-ultrasound fusion
6 guidance. *The Journal of urology* 193(1), 87-94
- 7 Reis Leonardo O, Sanches Brunno C. F, de Mendonca , Gustavo Borges, Silva Daniel M,
8 Aguiar Tiago, Menezes Ocivaldo P, and Billis Athanase (2015) Gleason underestimation is
9 predicted by prostate biopsy core length. *World journal of urology* 33(6), 821-6
- 10 Robertson N L, Hu Y, Ahmed H U, Freeman A, Barratt D, and Emberton M (2014) Prostate
11 cancer risk inflation as a consequence of image-targeted biopsy of the prostate: A computer
12 simulation study. *European Urology* 65(3), 628-634
- 13 Russo F, Regge D, Armando E, Giannini V, Vignati A, Mazzetti S, Manfredi M, Bollito E,
14 Correale L, and Porpiglia F (2015) Detection of prostate cancer index lesions with
15 multiparametric magnetic resonance imaging (mp-MRI) using whole-mount histological
16 sections as the reference standard. *BJU International* ,
- 17 Salami S S, Vira M A, Turkbey B, Fakhoury M, Yaskiv O, Villani R, Ben-Levi E, and
18 Rastinehad A R (2014) Multiparametric magnetic resonance imaging outperforms the
19 prostate cancer prevention trial risk calculator in predicting clinically significant prostate
20 cancer. *Cancer* 120(18), 2876-2882
- 21 Scheltema M J, Chang J I, van den Bos , W , Bohm M, Delprado W, Gielchinsky I, de Reijke
22 , T M, de la Rosette , J J, Siriwardana A R, Shnier R, and Stricker P D (2017) Preliminary
23 Diagnostic Accuracy of Multiparametric Magnetic Resonance Imaging to Detect Residual
24 Prostate Cancer Following Focal Therapy with Irreversible Electroporation. *European*
25 *Urology Focus* ,
- 26 Schimmoller L, Blondin D, Arsov C, Rabenalt R, Albers P, Antoch G, and Quentin M (2016)
27 MRI-guided in-bore biopsy: Differences between prostate cancer detection and localization in
28 primary and secondary biopsy settings. *American Journal of Roentgenology* 206(1), 92-99
- 29 Schimmoller L, Quentin M, Blondin D, Dietzel F, Hiester A, Schleich C, Thomas C, Rabenalt
30 R, Gabbert H E, Albers P, Antoch G, and Arsov C (2016) Targeted MRI-guided prostate
31 biopsy: are two biopsy cores per MRI-lesion required?. *European Radiology* 26(11), 3858-
32 3864
- 33 Schoots I G, Roobol M J, Nieboer D, Bangma C H, Steyerberg E W, and Hunink M G. M
34 (2015) Magnetic Resonance Imaging-targeted Biopsy May Enhance the Diagnostic Accuracy
35 of Significant Prostate Cancer Detection Compared to Standard Transrectal Ultrasound-
36 guided Biopsy: A Systematic Review and Meta-analysis. *European Urology* 68(3), 438-450
- 37 Scott S, Samaratunga H, Chabert C, Breckenridge M, and Gianduzzo T (2015) Is
38 transperineal prostate biopsy more accurate than transrectal biopsy in determining final
39 Gleason score and clinical risk category? A comparative analysis. *BJU International*
40 116(Supplement 3), 26-30
- 41 Sheikh N, Wei C, Szewczyk-Bieda M, Campbell A, Memon S, Lang S, and Nabi G (2017)
42 Combined T2 and diffusion-weighted MR imaging with template prostate biopsies in men
43 suspected with prostate cancer but negative transrectal ultrasound-guided biopsies. *World*
44 *journal of urology* 35(2), 213-220

- 1 Shen P F, Zhu Y C, Wei W R, Li Y Z, Yang J, Li Y T, Li D M, Wang J, and Zeng H (2012)
2 The results of transperineal versus transrectal prostate biopsy: A systematic review and
3 meta-analysis. *Asian Journal of Andrology* 14(2), 310-315
- 4 Shin T, Smyth T B, Ukimura O, Ahmadi N, de Castro Abreu, A L, Ohe C, Oishi M, Mimata H,
5 and Gill I S (2018) Diagnostic accuracy of a five-point Likert scoring system for magnetic
6 resonance imaging (MRI) evaluated according to results of MRI/ultrasonography image-
7 fusion targeted biopsy of the prostate. *BJU International* 121(1), 77-83
- 8 Shoji S, Hiraiwa S, Endo J, Hashida K, Tomonaga T, Nakano M, Sugiyama T, Tajiri T,
9 Terachi T, and Uchida T (2015) Manually controlled targeted prostate biopsy with real-time
10 fusion imaging of multiparametric magnetic resonance imaging and transrectal ultrasound:
11 An early experience. *International Journal of Urology* 22(2), 173-178
- 12 Shoji S, Hiraiwa S, Ogawa T, Kawakami M, Nakano M, Hashida K, Sato Y, Hasebe T,
13 Uchida T, and Tajiri T (2017) Accuracy of real-time magnetic resonance imaging-transrectal
14 ultrasound fusion image-guided transperineal target biopsy with needle tracking with a
15 mechanical position-encoded stepper in detecting significant prostate cancer in biopsy-naive
16 men. *International Journal of Urology* 24(4), 288-294
- 17 Shukla-Dave A, and Hricak H (2014) Role of MRI in prostate cancer detection. *NMR in*
18 *Biomedicine* 27(1), 16-24
- 19 Sim J, Schieda N, Robertson Sj, Breau Rh, Morash C, Belanger Ec, and Flood Ta (2017)
20 Evaluation of tumor morphologies at radical prostatectomy in high risk gleason score >9
21 prostate cancer diagnosed at trus-guided biopsy. Laboratory investigation. Conference:
22 106th annual meeting of the united states and canadian academy of pathology, and USCAP
23 2017. United states 97, 260a
- 24 Sivaraman A, Sanchez-Salas R, Ahmed H U, Barret E, Cathala N, Mombet A, Uriburu
25 Pizarro, F , Carneiro A, Doizi S, Galiano M, Rozet F, Prapotnich D, and Cathelineau X (2015)
26 Clinical utility of transperineal template-guided mapping biopsy of the prostate after negative
27 magnetic resonance imaging-guided transrectal biopsy. *Urologic Oncology: Seminars and*
28 *Original Investigations* 33(7), 329
- 29 Taira A V, Merrick G S, Bennett A, Andreini H, Taubenslag W, Galbreath R W, Butler W M,
30 Bittner N, and Adamovich E (2013) Transperineal template-guided mapping biopsy as a
31 staging procedure to select patients best suited for active surveillance. *American Journal of*
32 *Clinical Oncology: Cancer Clinical Trials* 36(2), 116-120
- 33 Takuma K, Mikio S, Masashi I, Nobufumi U, Hiromi H, Yushi H, and Yoshiyuki K (2012)
34 Transperineal ultrasound-guided multiple core biopsy using template for patients with one or
35 more previous negative biopsies: comparison with systematic 10-core biopsy. *Urology* 80(3
36 suppl. 1), S306-s307
- 37 Taneja Samir S (2017) Re: Diagnostic Accuracy of Multi-Parametric MRI and TRUS Biopsy
38 in Prostate Cancer (PROMIS): A Paired Validating Confirmatory Study. *The Journal of*
39 *urology* 198(1), 101-102
- 40 Tay Kae Jack, Cheng Christopher W. S, Lau Weber K. O, Khoo James, Thng Choon Hua,
41 and Kwek Jin Wei (2017) Focal Therapy for Prostate Cancer with In-Bore MR-guided
42 Focused Ultrasound: Two-Year Follow-up of a Phase I Trial-Complications and Functional
43 Outcomes. *Radiology* 285(2), 620-628

- 1 Taymoorian K, Thomas A, Slowinski T, Khiabanchian M, Stephan C, Lein M, Deger S, Lenk
2 S, Loening S A, and Fischer T (2007) Transrectal broadband-Doppler sonography with
3 intravenous contrast medium administration for prostate imaging and biopsy in men with an
4 elevated PSA value and previous negative biopsies. *Anticancer Research* 27(6 C), 4315-
5 4320
- 6 Tewes Susanne, Peters Inga, Tiemeyer Ansgar, Peperhove Matti, Hartung Dagmar,
7 Pertschy Stefanie, Kuczyk Markus A, Wacker Frank, and Hueper Katja (2017) Evaluation of
8 MRI/Ultrasound Fusion-Guided Prostate Biopsy Using Transrectal and Transperineal
9 Approaches. *BioMed research international* 2017, 2176471
- 10 Thestrup Karen Cecilie Duus, Logager Vibeke, Baslev Ingerd, Moller Jakob M, Hansen
11 Rasmus Hvass, and Thomsen Henrik S (2016) Biparametric versus multiparametric MRI in
12 the diagnosis of prostate cancer. *Acta radiologica open* 5(8), 2058460116663046
- 13 Thompson J E, Moses D, Shnier R, Brenner P, Delprado W, Ponsky L, Pulbrook M, Bohm M,
14 Haynes A M, Hayen A, and Stricker P D (2014) Multiparametric magnetic resonance imaging
15 guided diagnostic biopsy detects significant prostate cancer and could reduce unnecessary
16 biopsies and over detection: A prospective study. *Journal of Urology* 192(1), 67-74
- 17 Thompson J, Shnier R, Moses D, Brenner P, Delprado W, Tran M, Ponsky L, Boehm M,
18 Hayen A, and Stricker P (2015) Prospective study of pre-biopsy multiparametric magnetic
19 resonance imaging (MP-MRI) compared to transperineal template mapping biopsy (TTMB)
20 for detection of clinically significant prostate cancer: is it accurate enough to guide selection
21 of men for biopsy?. *Journal of urology*. 193(4 suppl. 1), e959
- 22 Thompson J E, Hayen A, Landau A, Haynes A M, Kalapara A, Ischia J, Matthews J,
23 Frydenberg M, and Stricker P D (2015) Medium-term oncological outcomes for extended vs
24 saturation biopsy and transrectal vs transperineal biopsy in active surveillance for prostate
25 cancer. *BJU International* 115(6), 884-891
- 26 Thompson J E, Van Leeuwen , P J, Moses D, Shnier R, Brenner P, Delprado W, Pulbrook M,
27 Bohm M, Haynes A M, Hayen A, and Stricker P D (2016) The diagnostic performance of
28 multiparametric magnetic resonance imaging to detect significant prostate cancer. *Journal of*
29 *Urology* 195(5), 1428-1435
- 30 Thompson J E, and Stricker P D (2017) Diagnostic accuracy of multi-parametric MRI and
31 transrectal ultrasound-guided biopsy in prostate cancer. *The Lancet* 389(10071), 767-768
- 32 Ting F, Van Leeuwen , P J, Thompson J, Shnier R, Moses D, Delprado W, and Stricker P D
33 (2016) Assessment of the Performance of Magnetic Resonance Imaging/Ultrasound Fusion
34 Guided Prostate Biopsy against a Combined Targeted Plus Systematic Biopsy Approach
35 Using 24-Core Transperineal Template Saturation Mapping Prostate Biopsy. *Prostate*
36 *Cancer* 2016, 3794738
- 37 Toner L, Weerakoon M, Bolton D M, Ryan A, Katelaris N, and Lawrentschuk N (2015)
38 Magnetic resonance imaging for prostate cancer: Comparative studies including radical
39 prostatectomy specimens and template transperineal biopsy. *Prostate International* 3(4),
40 107-114
- 41 Tonttila Pp, Lantto J, Pääkkö E, Piippo U, Kauppila S, Lammentausta E, Ohtonen P, and
42 Vaarala Mh (2016) Prebiopsy Multiparametric Magnetic Resonance Imaging for Prostate
43 Cancer Diagnosis in Biopsy-naive Men with Suspected Prostate Cancer Based on Elevated
44 Prostate-specific Antigen Values: results from a Randomized Prospective Blinded Controlled
45 Trial. *European urology* 69(3), 419-425

- 1 Tran G N, Leapman M S, Nguyen H G, Cowan J E, Shinohara K, Westphalen A C, and
2 Carroll P R (2017) Magnetic Resonance Imaging-Ultrasound Fusion Biopsy During Prostate
3 Cancer Active Surveillance. *European Urology* 72(2), 275-281
- 4 Valerio M, McCartan N, Freeman A, Punwani S, Emberton M, and Ahmed H U (2015)
5 Visually directed vs. software-based targeted biopsy compared to transperineal template
6 mapping biopsy in the detection of clinically significant prostate cancer. *Urologic Oncology:
7 Seminars and Original Investigations* 33(10), 424
- 8 Van Vugt , H A, Kranse R, Steyerberg E W, Van Der Poel , H G, Busstra M, Kil P, Oomens E
9 H, De Jong , I J, Bangma C H, and Roobol M J (2012) Prospective validation of a risk
10 calculator which calculates the probability of a positive prostate biopsy in a contemporary
11 clinical cohort. *European Journal of Cancer* 48(12), 1809-1815
- 12 Volkin D, Turkbey B, Hoang A N, Rais-Bahrami S, Yerram N, Walton-Diaz A, Nix J W, Wood
13 B J, Choyke P L, and Pinto P A (2014) Multiparametric magnetic resonance imaging (MRI)
14 and subsequent MRI/ultrasonography fusion-guided biopsy increase the detection of
15 anteriorly located prostate cancers. *BJU International* 114(6), E43-E49
- 16 Walton Diaz, A , Shakir N A, George A K, Rais-Bahrami S, Turkbey B, Rothwax J T,
17 Stamatakis L, Hong C W, Siddiqui M M, Okoro C, Raskolnikov D, Su D, Shih J, Han H,
18 Parnes H L, Merino M J, Simon R M, Wood B J, Choyke P L, and Pinto P A (2015) Use of
19 serial multiparametric magnetic resonance imaging in the management of patients with
20 prostate cancer on active surveillance. *Urologic Oncology: Seminars and Original
21 Investigations* 33(5), 202e1-202e7
- 22 Wang R, Wang H, Zhao C, Hu J, Jiang Y, Tong Y, Liu T, Huang R, and Wang X (2015)
23 Evaluation of multiparametric magnetic resonance imaging in detection and prediction of
24 prostate cancer. *PLoS ONE* 10(6), e0130207
- 25 Wang Z, Schaefferkoetter J, Kok T, Stephenson M, Schneider E, Niaf E, Totman J,
26 Townsend D, Thamboo T, and Chiong E (2017) Primary prostate cancer imaging with MP-
27 MRI, PET/CT and PET/MRI with focus on localisation and grading. *BJU international.
28 Conference: individualised urological treatment, and UROFAIR 2017. Singapore* 119, 4
- 29 Weaver J K, Kim E H, Vetter J M, Fowler K J, Siegel C L, and Andriole G L (2016) Presence
30 of magnetic resonance imaging suspicious lesion predicts gleason 7 or greater prostate
31 cancer in biopsy-naive patients. *Urology* 88, 119-124
- 32 Wegelin Olivier, Henken Kirsten R, Somford Diederik M, Breuking Frans A. M, Bosch Ruud
33 J, van Swol , Christiaan F P, van Melick , and Harm H E (2016) An Ex Vivo Phantom
34 Validation Study of an MRI-Transrectal Ultrasound Fusion Device for Targeted Prostate
35 Biopsy. *Journal of endourology* 30(6), 685-91
- 36 Westhoff N, Siegel F P, Hausmann D, Polednik M, von Hardenberg , J , Michel M S, and
37 Ritter M (2017) Precision of MRI/ultrasound-fusion biopsy in prostate cancer diagnosis: an ex
38 vivo comparison of alternative biopsy techniques on prostate phantoms. *World journal of
39 urology* 35(7), 1015-1022
- 40 Winter M, Garcia C, Bergersen P, Woo H, and Chalasani V (2013) A systematic review with
41 metaanalysis of transrectal prostate biopsy versus transperineal prostate biopsy for detecting
42 prostate cancer. *BJU international.* 112, 22

- 1 Wu L M, Yao Q Y, Zhu J, Lu Q, Suo S T, Liu Q, Xu J R, Chen X X, Haacke E M, and Hu J
2 (2017) T2* mapping combined with conventional T2-weighted image for prostate cancer
3 detection at 3.0T MRI: A multi-observer study. *Acta Radiologica* 58(1), 114-120
- 4 Wysock Js, Rosenkrantz Ab, Huang Wc, Stifelman Md, Lepor H, Deng Fm, Melamed J, and
5 Taneja Ss (2014) A prospective, blinded comparison of magnetic resonance (MR) imaging-
6 ultrasound fusion and visual estimation in the performance of MR-targeted prostate biopsy:
7 the PROFUS trial. *European urology* 66(2), 343-351
- 8 Yaxley A J, Yaxley J W, Thangasamy I A, Ballard E, and Pokorny M R (2017) Comparison
9 between target magnetic resonance imaging (MRI) in-gantry and cognitively directed
10 transperineal or transrectal-guided prostate biopsies for Prostate Imaging-Reporting and
11 Data System (PI-RADS) 3-5 MRI lesions. *BJU International* 120(Supplement 3), 43-50
- 12 Yoo Sangjun, Hong Jun Hyuk, Byun Seok-Soo, Lee Ji Youl, Chung Byung Ha, and Kim
13 Choung-Soo (2017) Is suspicious upstaging on multiparametric magnetic resonance imaging
14 useful in improving the reliability of Prostate Cancer Research International Active
15 Surveillance (PRIAS) criteria? Use of the K-CaP registry. *Urologic oncology* 35(7), 459.e7-
16 459.e13
- 17 Zhang Q, Wang W, Yang R, Zhang G, Zhang B, Li W, Huang H, and Guo H (2015) Free-
18 hand transperineal targeted prostate biopsy with real-time fusion imaging of multiparametric
19 magnetic resonance imaging and transrectal ultrasound: single-center experience in China.
20 *International Urology and Nephrology* ,
- 21 Zhang Q, Wang W, Zhang B, Shi J, Fu Y, Li D, Guo S, Zhang S, Huang H, Jiang X, Zhou W,
22 and Guo H (2017) Comparison of free-hand transperineal MP-MRI/TRUS fusion-guided
23 biopsy with transperineal 12-core systematic biopsy for the diagnosis of prostate cancer: a
24 single-center prospective study in China. *International Urology and Nephrology* 49(3), 439-
25 448
- 26
- 27 **Economic studies – excluded**
- 28
- 29 Venderink W, Govers TM, de Rooij M, Fütterer JJ, Sedelaar JM. Cost-effectiveness
30 comparison of imaging-guided prostate biopsy techniques: systematic transrectal ultrasound,
31 direct in-bore MRI, and image fusion. *American Journal of Roentgenology*. 2017
32 May;208(5):1058-63.
- 33 Willis SR, van der Meulen J, Valerio M, Miners A, Ahmed HU, Emberton M. A review of
34 economic evaluations of diagnostic strategies using imaging in men at risk of prostate
35 cancer. *Current opinion in urology*. 2015 Nov 1;25(6):483-9.
- 36 Pahwa S, Schiltz NK, Ponsky LE, Lu Z, Griswold MA, Gulani V. Cost-effectiveness of MR
37 imaging-guided strategies for detection of prostate cancer in biopsy-naive men. *Radiology*.
38 2017 May 17;285(1):157-66.
- 39 Loeb S, Zhou Q, Siebert U, Rochau U, Jahn B, Mühlberger N, Carter HB, Lepor H,
40 Braithwaite RS. Active surveillance versus watchful waiting for localized prostate cancer: a
41 model to inform decisions. *European urology*. 2017 Dec 1;72(6):899-907.

- 1 Gordon LG, James R, Tuffaha HW, Lowe A, Yaxley J. Cost-effectiveness analysis of
2 multiparametric MRI with increased active surveillance for low-risk prostate cancer in
3 Australia. *Journal of Magnetic Resonance Imaging*. 2017 May 1;45(5):1304-15.
- 4 de Rooij M, Crienen S, Witjes JA, Barentsz JO, Rovers MM, Grutters JP. Cost-effectiveness
5 of magnetic resonance (MR) imaging and MR-guided targeted biopsy versus systematic
6 transrectal ultrasound-guided biopsy in diagnosing prostate cancer: a modelling study from a
7 health care perspective. *European urology*. 2014 Sep 1;66(3):430-6.
- 8 Cerantola Y, Dragomir A, Tanguay S, Bladou F, Aprikian A, Kassouf W. Cost-effectiveness
9 of multiparametric magnetic resonance imaging and targeted biopsy in diagnosing prostate
10 cancer. In *Urologic Oncology: Seminars and Original Investigations* 2016 Mar 1 (Vol. 34, No.
11 3, pp. 119-e1). Elsevier.
- 12 Mowatt G, Scotland G, Boachie C, Cruickshank M, Ford JA, Fraser C, Kurban L, Lam TB,
13 Padhani AR, Royle J, Scheenen TW. The diagnostic accuracy and cost-effectiveness of
14 magnetic resonance spectroscopy and enhanced magnetic resonance imaging techniques in
15 aiding the localisation of prostate abnormalities for biopsy: a systematic review and economic
16 evaluation. *Health technology assessment*. 2013.
- 17 Hövels AM, Heesakkers RA, Adang EM, Barentsz JO, Jager GJ, Severens JL. Cost-
18 effectiveness of MR lymphography for the detection of lymph node metastases in patients
19 with prostate cancer. *Radiology*. 2009 Sep;252(3):729-36.
- 20 Roth JA, Ramsey SD, Carlson JJ. Cost-effectiveness of a biopsy-based 8-protein prostate
21 cancer prognostic assay to optimize treatment decision making in gleason 3+ 3 and 3+ 4
22 early stage prostate cancer. *The oncologist*. 2015 Dec 1;20(12):1355-64.
- 23 Faria R, Soares MO, Spackman E, Ahmed HU, Brown LC, Kaplan R, Emberton M, Sculpher
24 MJ. Optimising the diagnosis of prostate cancer in the era of multiparametric magnetic
25 resonance imaging: a cost-effectiveness analysis based on the Prostate MR Imaging Study
26 (PROMIS). *European urology*. 2018 Jan 1;73(1):23-30.
- 27 Nicholson A, Mahon J, Boland A, Beale S, Dwan K, Fleeman N, Hockenhull J, Dundar Y.
28 The clinical effectiveness and cost-effectiveness of the PROGENSA (R) prostate cancer
29 antigen 3 assay and the Prostate Health Index in the diagnosis of prostate cancer: a
30 systematic review and economic evaluation. *Health Technol Assess*. 2015 Oct 1;19(87):1-92.
31

Economic study - included

- 2 Patel S, Rongen JJ, Fütterer JJ, Boltyenkov A, Rovers MM. The Role of Multiparametric
- 3 Magnetic Resonance Imaging in Active Surveillance for Men with Low-risk Prostate Cancer:
- 4 A Cost-effectiveness Modeling Study. European Urology Oncology. 2018.

Economic studies - excluded

Appendix I– Research recommendations

Question	What is the most clinically and cost effective pathway for excluding the clinically significant progression of prostate cancer in people with low to intermediate risk
Population	People with low-to-intermediate risk prostate cancer
Intervention	mpMRI, TRUS biopsy, transperineal biopsy
Comparator	Transperineal template (mapping) biopsy
Outcomes	Sensitivity Specificity Positive and negative likelihood ratios Adverse events QoL measures
Study design	Diagnostic cross sectional
Potential criterion	Explanation
Importance to patients, service users or the population	The committee agreed that active surveillance is an important option for people with low to intermediate risk prostate cancer, but that it was vital as part of that process to monitor people for clinically significant progression so that they can be offered timely radical treatment. It also commented that managing peoples anxieties and the impact that monitoring has on their quality of life are also key factors in monitoring for progression.
Relevance to NICE guidance	Evidence in this area will enable future committees to make more concrete recommendations about frequency and type of monitoring that should be used.
Current evidence base	The evidence used in the current guideline is reasonably poor. Few studies used a gold standard comparator (since this would not occur in a normal clinical pathway).
Equality	No additional equality issues are envisaged relating to this study over and above those applying generally to vulnerable groups of people.
Feasibility	There is a large enough population of people on surveillance and monitoring regimes, carrying out a trial in this areas should be feasible

1