

Abdominal aortic aneurysm: diagnosis and management

**Evidence review W: Accuracy of imaging
techniques in identifying complications after
surgery**

NICE guideline NG156

Methods, evidence and recommendations

March 2020

Final

*This evidence review was developed by
the NICE Guideline Updates Team*

Disclaimer

The recommendations in this guideline represent the view of NICE, arrived at after careful consideration of the evidence available. When exercising their judgement, professionals are expected to take this guideline fully into account, alongside the individual needs, preferences and values of their patients or service users. The recommendations in this guideline are not mandatory and the guideline does not override the responsibility of healthcare professionals to make decisions appropriate to the circumstances of the individual patient, in consultation with the patient and/or their carer or guardian.

Local commissioners and/or providers have a responsibility to enable the guideline to be applied when individual health professionals and their patients or service users wish to use it. They should do so in the context of local and national priorities for funding and developing services, and in light of their duties to have due regard to the need to eliminate unlawful discrimination, to advance equality of opportunity and to reduce health inequalities. Nothing in this guideline should be interpreted in a way that would be inconsistent with compliance with those duties.

NICE guidelines cover health and care in England. Decisions on how they apply in other UK countries are made by ministers in the [Welsh Government](#), [Scottish Government](#), and [Northern Ireland Executive](#). All NICE guidance is subject to regular review and may be updated or withdrawn.

Copyright

© NICE 2020. All rights reserved. Subject to [Notice of rights](#).

ISBN: 978-1-4731-3452-2

Contents

Accuracy of imaging techniques in identifying complications after surgery	7
Review question	7
Introduction	7
PICO table.....	7
Methods and process	7
Clinical evidence	8
Summary of clinical studies included in the evidence review	9
Economic evidence	24
Evidence statements	24
Accuracy of imaging techniques in identifying complications after surgery	6
Review question	6
Introduction	6
PICO table.....	6
Methods and process	6
Clinical evidence	7
Summary of clinical studies included in the evidence review	8
Economic evidence	23
Evidence statements	22
The committee’s discussion of the evidence.....	27
Appendices	31
Appendix A – Review protocols	31
Review protocol for the effectiveness of tests in predicting poor and good surgical outcomes	33
Appendix B – Literature search strategies	34
Clinical search literature search strategy	36
Health Economics literature search strategy.....	36
Appendix C – Clinical evidence study selection.....	39
Appendix D – Clinical evidence tables.....	40
Appendix E – Forest plots	114
CDUS compared with angiography in the identification of endoleak	114
Sensitivity Analysis: CDUS compared to angiography in detection of change in aneurysm size.....	126
CDUS compared to angiography in detection of change in aneurysm size	130
CEUS compared with angiography in the identification of endoleak	134
3D Contrast Enhanced Colour Duplex ultrasound compared to angiography	146
Appendix F – GRADE tables	150
Complications.....	150
Change in aneurysm size	156

Appendix G – Economic evidence study selection.....	159
Appendix H – Excluded studies	160
Clinical studies	160
Economic studies	171
Appendix I – Glossary	173

Accuracy of imaging techniques in identifying complications after surgery

Review question

When monitoring people after they have had EVAR or open repair of an abdominal aortic aneurysm, which imaging techniques are most useful for detecting postoperative complications, further aneurysm expansion and aneurysm rupture?

Introduction

Endovascular aneurysm repair (EVAR) and open repair of abdominal aortic aneurysms (AAAs) are associated with a number of postoperative complications such as endoleak and graft occlusion, as well as further aneurysm expansion and aneurysm rupture. Due to these complications, surveillance is required. This review question aims to determine which imaging technique is most accurate in identifying postoperative complications. This review also aims to determine which imaging techniques are most acceptable to people with AAA and clinicians, taking into account the safety profiles of the approaches.

PICO table

Table 1: Inclusion criteria

Review Question 8	When monitoring people after they have had EVAR or open repair of an AAA, which imaging techniques are most useful for detecting postoperative complications, further aneurysm expansion and aneurysm rupture?
Population	People who have undergone surgical repair of an AAA
Index test / factors of interest	Ultrasound, including colour duplex ultrasound (CDUS), contrast-enhanced CDUS Plain film radiography, aortography/angiography CT Helical CT technology MRI Intrasac pressure monitoring
Reference Standard	CTA
Outcome/endpoint	Diagnostic accuracy (sensitivity and specificity for endoleak, graft migration, graft kinking, graft occlusion, aortic neck expansion) Adverse events Acceptability of approach to people with AAA and clinicians

Methods and process

This evidence review was developed using the methods and process described in [Developing NICE guidelines: the manual](#). Methods specific to this review question are described in the review protocol in Table 1.

Declarations of interest were recorded according to NICE's 2014 conflicts of interest policy.

A broad search strategy was used to pull in all studies that examine the diagnosis, surveillance or monitoring of AAAs. This was a 'bulk' search that covered multiple review questions. The reviewer sifted the database to identify all studies that assessed the accuracy, safety and acceptability of imaging techniques in the diagnosis of AAAs, including asymptomatic aneurysms, symptomatic unruptured aneurysms, and ruptured aneurysms. An available Cochrane review (Abraha 2017) was used as an additional source of studies which examined the diagnostic accuracy of CDUS in the identification of endoleaks.

Cross sectional studies and systematic reviews of this study design, examining diagnostic accuracy using sensitivity, specificity and likelihood ratios were considered for inclusion. Studies examining adverse events after surgery and acceptability of approach to people with AAA and clinicians were also considered.

Ideally, studies using imaging techniques such as colour duplex ultrasound (CDUS) and computed tomography angiography (CTA) as the reference standard were included. If studies did not report diagnostic test accuracy measures, 2x2 tables of true positives, false positives, true negatives and false negatives were derived from raw data or calculated from the set of test accuracy statistics. These measures were presented as calculated test accuracy measures within the evidence review. Studies from which 2x2 tables could not be calculated were excluded.

Studies were also excluded if they were:

- Not in English
- Abstracts or non-published data
- Published before 2000.

Clinical evidence

Included studies

From a database of 12,786 studies, 188 studies were identified as being potentially relevant. An update search was conducted in December 2017, during which 8 further studies were included for consideration. Following full text review of the 196 studies, 37 studies of cross-sectional study design were included.

Overall, included studies explored the diagnostic accuracy of colour duplex ultrasound (CDUS), contrast enhanced duplex ultrasound (CEUS), 3D contrast enhanced duplex ultrasound (3D CEUS), 4D contrast enhanced duplex ultrasound (4D CEUS) and magnetic resonance imaging (MRI). Data was identified for complications such as endoleaks, graft occlusion and change in aneurysm size. All included studies compared the index tests to computed tomography angiography (CTA). Where possible, the diagnostic accuracy of the tools in the identification of Type I and III endoleaks as well as Type II endoleak was explored.

No studies were included which examined which imaging techniques were most acceptable to people with AAA and clinicians, taking into account the safety profiles of the approaches.

Excluded studies

The list of papers excluded at full text review, with reasons, is given in Appendix H.

Summary of clinical studies included in the evidence review

A summary of the included studies is provided in the table below. See Appendix D for full evidence tables.

Table 2: Summary of included studies

Study ID	Study	Population	Index Test(s) (positive criterion)	Reference Test
Abbas (2014)	Abbas A, Hansrani V, Sedgwick N, Ghosh J, and McCollum C N (2014) 3D contrast enhanced ultrasound for detecting endoleak following endovascular aneurysm repair (EVAR). European Journal of Vascular and Endovascular Surgery 47, 487-492	Number of patients: 23 Study Location: UK Setting: Tertiary referral vascular centre Inclusion Criteria: Consecutive subjects attending for CTA and 3D CEUS imaging Exclusion Criteria: Subjects who did not have paired CTA imaging.	2D CEUS 3D CEUS	CTA
AbuRahma (2005)	AbuRahma Ali F, Welch Christine A, Mullins Bandy B, and Dyer Benjamin (2005) Computed tomography versus color duplex ultrasound for surveillance of abdominal aortic stent-grafts. Journal of endovascular therapy : an official journal of the International Society of Endovascular Specialists 12, 568-73	Number of patients: 178 Study Location: USA Setting: Department of Surgery Inclusion Criteria: Patients undergoing endovascular AAA repair using 3 commercially available devices Exclusion Criteria: Not specified.	CDUS (An endoleak was indicated by flow and spectral signals outside the prosthesis)	CTA
Badri (2010)	Badri Hassan, El Haddad , Mohammed , Ashour Hamdy, Nice Colin, Timmons Grace, and Bhattacharya Vish (2010) Duplex ultrasound scanning (DUS) versus computed tomography angiography (CTA) in the follow-up after EVAR. Angiology 61, 131-6	Number of patients: 59 Study Location: UK Setting: Department of Vascular Surgery Inclusion Criteria: Patients undergoing EVAR Exclusion Criteria: Not specified	CDUS (any colour Doppler signals exterior to the graft)	CTA

Study ID	Study	Population	Index Test(s) (positive criterion)	Reference Test
Bargellini (2009)	Bargellini Irene, Cioni Roberto, Napoli Vinicio, Petruzzi Pasquale, Vignali Claudio, Cicorelli Antonio, Sardella Savino, Ferrari Mauro, and Bartolozzi Carlo (2009) Ultrasonographic surveillance with selective CTA after endovascular repair of abdominal aortic aneurysm. Journal of endovascular therapy : an official journal of the International Society of Endovascular Specialists 16, 93-104	Number of patients: 198 Study Location: Italy Setting: Department of Diagnostic and Interventional Radiology Inclusion Criteria: Patients who underwent EVAR for elective treatment of infrarenal AAAs with a mean maximum transverse diameter of 52.4±9.7mm. Exclusion Criteria: Not specified	CDUS (A change (≥10%) in the maximum transverse sac diameter at follow up compared to the pre-procedural value was considered significant)	CTA
Bendick (2003)	Bendick Phillip J, Bove Paul G, Long Graham W, Zelenock Gerald B, Brown O William, and Shanley Charles J (2003) Efficacy of ultrasound scan contrast agents in the noninvasive follow-up of aortic stent grafts. Journal of vascular surgery 37, 381-5	Number of patients: 20 Study Location: USA Setting: Department of Surgery Inclusion Criteria: Patients who had a percutaneously placed aortoiliac stent graft for infrarenal aortic aneurysmal disease. 10 patients selected because of the technical difficulty of the conventional duplex ultrasound scan from patient body habitus or presence of bowel gas. Exclusion Criteria: Not reported	CDUS (Any endoleaks that were seen with CDUS were classified as being related to stent graft itself, at either the proximal or distal attachment sites or at any graft module junctions or secondary to patent aortic branch vessels, such as the inferior mesenteric artery or lumbar arteries, which showed collateral filled and back bleeding into the aneurysm sac)	CTA
Cantador (2016)	Cantador, A. A, Siqueira, D. E. D, Jacobsen, O. B., Baracat, J., Pereira, I. M. R., Menezes, F. H., Guillaumon, A. T (2016)	Number of patients: 30 Study Location: Brazil Setting: Not specified Inclusion Criteria: Patients undergoing EVAR	CDUS (any flow between the stent and aneurysm sac)	CTA

Study ID	Study	Population	Index Test(s) (positive criterion)	Reference Test
	Duplex ultrasound and computed tomography angiography in the follow-up of endovascular abdominal aortic aneurysm repair: a comparative study. <i>Radiol Bras.</i> 2016 Jul-Aug; 49(4): 229–233.	Exclusion Criteria: Patients allergic to iodinated contrast Patients with creatinine level >2.0 mg/dL		
Clevert (2008)	Clevert D A, Minaifar N, Weckbach S, Kopp R, Meimarakis G, Clevert D A, and Reiser M (2008) Color duplex ultrasound and contrast-enhanced ultrasound in comparison to MS-CT in the detection of endoleak following endovascular aneurysm repair. <i>Clinical hemorheology and microcirculation</i> 39, 121-32	Number of patients: 43 Study Location: Germany Setting: Department of Clinical Radiology Inclusion Criteria: Consecutive patients who had undergone EVAR. Exclusion Criteria: not specified	CDUS and CEUS (persistence of blood flow outside the lumen of the endoluminal graft but within an aneurysm sac or adjacent vascular segment being treated by the graft)	CTA
Clevert (2011)	Clevert D A, Helck A, D'Anastasi M, Gurtler V, Sommer W H, Meimarakis G, Weidenhagen R, and Reiser M (2011) Improving the follow up after EVAR by using ultrasound image fusion of CEUS and MS-CT. <i>Clinical hemorheology and microcirculation</i> 49, 91-104	Number of patients: 35 Study Location: Germany Setting: Interdisciplinary Ultrasound Centre Inclusion Criteria: Only patients undergoing follow-up after EVAR Exclusion Criteria: <ul style="list-style-type: none"> • Patients with heart pacemaker or neurostimulator • Patients with acute heart failure, myocardial infarction, known allergy to Sonovue, extensive subcutaneous emphysema • Patient non-compliance 	CDUS and CEUS	CTA

Study ID	Study	Population	Index Test(s) (positive criterion)	Reference Test
D'Audiffret (2001)	D'Audiffret A, Desgranges P, Kobeiter D H, and Becquemin J P (2001) Follow-up evaluation of endoluminally treated abdominal aortic aneurysms with duplex ultrasonography: validation with computed tomography. Journal of vascular surgery 33, 42-50	Number of patients: 89 Study Location: France Setting: Department of Vascular surgery Inclusion Criteria: Patients who underwent AAA exclusion with commercially available endoprosthesis Exclusion Criteria: Patients who did not have a minimum follow-up of 6 months	CDUS (Colour flow sampling within the aneurysm sac, outside the endoprosthesis)	CTA
Demirpolat (2011)	Demirpolat Gulgun, Ozturk Nur, Parildar Mustafa, Posacioglu Hakan, and Tamsel Sadik (2011) Duplex ultrasound evaluation of endoluminally treated aortic aneurysms with emphasis on diameter measurement: A comparison with computed tomography. Journal of clinical ultrasound : JCU 39, 263-9	Number of patients: 29 Study Location: France Setting: Department of Radiology Inclusion Criteria: Patients treated with endovascular stent grafts for AAA Exclusion Criteria: Not specified	CDUS (when reproducible, pulsatile colour flow images could be seen outside the graft)	CTA
Franca (2013)	Franca G J, Baroncini L A. V, de Oliveira , A , Vidal E A, Miyamoto M, Toregeani J F, Coelho L O. M, and Timi J R. R (2013) Evaluation with Doppler vascular ultrasound in postoperative endovascular treatment of abdominal aortic aneurysm: A prospective comparative study with angiotomography. Jornal Vascular Brasileiro 12, 102-109	Number of patients: 33 Study Location: Brazil Setting: Vascular Ultrasonography units Inclusion Criteria: Not specified Exclusion Criteria: Not specified	CDUS (transmission of flow and pressure into the aneurysm sac)	CTA
Gargiulo (2014)	Gargiulo M, Gallitto E, Serra C, Freyrie A, Mascoli C, Bianchini Massoni, C , De Matteis , M , De Molo	Number of patients: 22 Study Location: Italy Setting: Ultrasound Unit	4D CEUS (White and May classification)	CTA

Study ID	Study	Population	Index Test(s) (positive criterion)	Reference Test
	, C , and Stella A (2014) Could four-dimensional contrast-enhanced ultrasound replace computed tomography angiography during follow up of fenestrated endografts? Results of a preliminary experience. European journal of vascular and endovascular surgery : the official journal of the European Society for Vascular Surgery 48, 536-42	Inclusion Criteria: All consecutive patients who underwent FEVAR follow-up for juxta- and para- AAA Exclusion Criteria: Not specified		
Giannoni (2007)	Giannoni Maria Fabrizia, Fanelli Fabrizio, Citone Michele, Cristina Acconcia, Maria , Speziale Francesco, and Gossetti Bruno (2007) Contrast ultrasound imaging: the best method to detect type II endoleak during endovascular aneurysm repair follow-up. Interactive cardiovascular and thoracic surgery 6, 359-62	Number of patients: 30 Study Location: Italy Setting: Division of Vascular Surgery Inclusion Criteria: Consecutive patients with endovascular grafts for infrarenal aortic aneurysms. Exclusion Criteria: Not specified	CEUS (as persisting flow from patent lumbar or mesenteric arteries within aneurysm sac and outside the endograft)	CTA
Gilabert (2012)	Gilabert Rosa, Bunesch Laura, Real Maria Isabel, Garcia-Criado Angeles, Burrel Marta, Ayuso Juan Ramon, Barrufet Marta, Montana Xavier, and Rimbau Vicenc (2012) Evaluation of abdominal aortic aneurysm after endovascular repair: prospective validation of contrast-enhanced US with a second-generation US contrast agent. Radiology 264, 269-77	Number of patients: 35 Study Location: Spain Setting: Diagnostic imaging centre Inclusion Criteria: Patients undergoing EVAR at institution Exclusion Criteria: • Patients with inadequate renal function (calculated creatinine clearance <30 mL/<50mL/min in patients with diabetes)	CEUS (hyperchogenic flowing region (localised or diffuse) that was absent on the baseline unenhanced images obtained outside the endograft lumen but within the aneurysm sac)	CTA

Study ID	Study	Population	Index Test(s) (positive criterion)	Reference Test
		<ul style="list-style-type: none"> Patients with contraindications to US contrast agent administration, such as heart failure, a right-to-left shunt, severe chronic bronchopulmonary disorder, severe pulmonary hypertension, or uncontrolled hypertension. 		
Golzarian (2002)	Golzarian Jafar, Murgo Salvatore, Dussaussois Luc, Guyot Sophie, Said Kamel Ait, Wautrecht Jean Claude, and Struyven Julien (2002) Evaluation of abdominal aortic aneurysm after endoluminal treatment: comparison of color Doppler sonography with biphasic helical CT. AJR. American journal of roentgenology 178, 623-8	<p>Number of patients: 55 Study Location: Belgium Setting: Department of Radiology Inclusion Criteria: Patients who underwent transfemoral insertion of stent-grafts for abdominal aortic aneurysm Exclusion Criteria: Only the examinations obtained within 7 days after implantation were compared.</p>	CDUS (a signal associated with a spectral Doppler signal was observed outside the aorta)	CTA
Gray (2012)	Gray C, Goodman P, Herron C C, Lawler L P, O'Malley M K, O'Donohoe M K, and McDonnell C O (2012) Use of colour duplex ultrasound as a first line surveillance tool following EVAR is associated with a reduction in cost without compromising accuracy. European Journal of Vascular and Endovascular Surgery 44, 145-150	<p>Number of patients: 145 Study Location: Ireland Setting: Department of Vascular Radiology Inclusion Criteria: All patients who underwent EVAR at the Mater Hospital from 1st June 2003 to 1st July 2010 Exclusion Criteria: Not specified</p>	CDUS (of high jet flow indicating type I endoleak or low velocity flow within the old aneurysm sac demonstrating forward and reversed flow indicating the presence of Type II endoleak)	CTA
Gürtler (2013)	Gurtler Verena M, Sommer Wieland H, Meimarakis Georgios, Kopp Reinhard, Weidenhagen Rolf, Reiser Maximilian F, and Clevert Dirk-Andre (2013) A comparison between contrast-enhanced ultrasound imaging and multislice computed	<p>Number of patients: 171 Study Location: Germany Setting: Department of Clinical Radiology and Department of Surgery Inclusion Criteria:</p>	CEUS (an extravasation of contrast between the aneurysm well and the prosthesis)	CTA

Study ID	Study	Population	Index Test(s) (positive criterion)	Reference Test
	tomography in detecting and classifying endoleaks in the follow-up after endovascular aneurysm repair. Journal of vascular surgery 58, 340-5	<ul style="list-style-type: none"> Only patients undergoing follow-up after EVAR who had received at least one CEUS examination after the stent implantation Examinations that were performed on the same day or ≤ 30 days. Exclusion Criteria: <ul style="list-style-type: none"> Patients with an abdominal tube stent Patients with acute heart failure and acute myocardial infarction Allergy to contrast agent Patient noncompliance 		
Henao (2006)	Henao Esteban A, Hodge Megan D, Felkai Deborah D, McCollum Charles H, Noon George P, Lin Peter H, Lumsden Alan B, and Bush Ruth L (2006) Contrast-enhanced Duplex surveillance after endovascular abdominal aortic aneurysm repair: improved efficacy using a continuous infusion technique. Journal of vascular surgery 43, 259-264	Number of patients: 20 Study Location: USA Setting: Not specified Inclusion Criteria: All men and postmenopausal women seen at follow-up intervals were asked to participate Exclusion Criteria: <ul style="list-style-type: none"> Patients with a known endoleak from previous examinations Severe iodinated contrast allergy Evidence of renal insufficiency marked by a serum creatinine level >1.5 mg/dL Evidence of a right-to-left cardiac shunt or severe pulmonary or hepatic disease 	CDUS and CEUS (presence of persistent intrasac flow outside the stent-graft)	CTA

Study ID	Study	Population	Index Test(s) (positive criterion)	Reference Test
Iezzi (2009)	Iezzi Roberto, Basilico Raffaella, Giancristofaro Daniela, Pascali Danilo, Cotroneo Antonio Raffaele, and Storto Maria Luigia (2009) Contrast-enhanced ultrasound versus color duplex ultrasound imaging in the follow-up of patients after endovascular abdominal aortic aneurysm repair. Journal of vascular surgery 49, 552-60	<p>Number of patients: 84 Study Location: Italy Setting: Department of Radiology Inclusion Criteria:</p> <ul style="list-style-type: none"> All patients treated with EVAR who underwent CTA as part of a routine surveillance program at 1, 6, and 12 months after the procedure and annually thereafter. To avoid selection bias in favour of patients who were 'easy to scan' patients were recruited before undergoing a baseline US scan. No patient was excluded on the basis of poor technical quality of the baseline US study. <p>Exclusion Criteria:</p> <ul style="list-style-type: none"> Patients with unstable general conditions such as heart failure, severe chronic bronchopulmonary disorders, severe pulmonary hypertension, or uncontrolled hypertension 	<p>CDUS (a colour duplex signal was present beyond the graft)</p> <p>CEUS (high attenuation area, absent on the baseline unenhanced-phase images, due to the presence of contrast enhancement, was present beyond the graft but within the aneurysm sac)</p>	CTA
Kamal (2008)	Kamal D M, Steinmetz O K, and Obrand D I (2008) The value of duplex ultrasound versus contrast enhanced CT scan in the follow-up of endoluminally repaired abdominal aortic aneurysm: A blinded comparison. Bahrain Medical Bulletin 30, 101-107	<p>Number of patients: 63 Study Location: Bahrain Setting: Two McGill University Teaching Hospitals Inclusion Criteria: Patients evaluated by contrast enhanced computed tomography scan and duplex ultrasound examinations in their postoperative follow-up. Exclusion Criteria:</p>	CDUS (colour and spectral signal outside the limits of the prosthesis)	CTA

Study ID	Study	Population	Index Test(s) (positive criterion)	Reference Test
		<ul style="list-style-type: none"> • Patients who were followed-up elsewhere • Patients who were followed-up by CT scan only (no Duplex performed) • If the concurrent (paired) study was done more than one month apart • If the CT scan was done without contrast, it was excluded from endoleak detection comparison. 		
Lowe 2017	Lowe C, Abbas A, Rogers S, Smith L, Ghosh J, McCollum C Three-dimensional contrast-enhanced ultrasound improves endoleak detection and classification after endovascular aneurysm repair. J Vasc Surg. 2017 May;65(5):1453-1459	Number of patients: 100 Study Location: UK Setting: Two Not specified Inclusion Criteria: Consecutive patients undergoing CTA for EVAR surveillance Exclusion Criteria: Studies with poor image quality due to bowel gas or obesity	CEUS and 3D CEUS	CTA
McWilliams (2002)	McWilliams Richard G, Martin Janis, White Donagh, Gould Derek A, Rowlands Peter C, Haycox Alan, Brennan John, Gilling-Smith Geoffrey L, and Harris Peter L (2002) Detection of endoleak with enhanced ultrasound imaging: comparison with biphasic computed tomography. Journal of endovascular therapy : an official journal of the International Society of Endovascular Specialists 9, 170-9	Number of patients: 53 Study Location: UK Setting: Departments of Radiology and Vascular Surgery Inclusion Criteria: Patients who underwent EVAR. Exclusion Criteria: All patients seen at follow-up intervals were asked to participate unless there was documented contraindication to the use of Levovist.	CDUS and CEUS (colour flow within the aneurysm sac outside the stent graft)	CTA

Study ID	Study	Population	Index Test(s) (positive criterion)	Reference Test
Mauro (2010)	Mauro R, Maioli F, Freyrie A, Testi G, Palumbo N, Serra C, and Stella A (2010) Is CEUS a valid alternative to CTA in endoleak's detection?. Italian Journal of Vascular and Endovascular Surgery 17, 253-258	Number of patients: 122 Study Location: Italy Setting: Department of Vascular Surgery Inclusion Criteria: Patients undergoing EVAR Exclusion Criteria: <ul style="list-style-type: none"> Renal insufficiency One patient who died seven days after procedure Patients who refused the follow-up program 	CEUS (as contrast enhancement into the residual aneurysm sac)	CTA
Mori (2016)	Mori K, Saida T, Sato F, Uchikawa Y, Konishi T, Ishiguro T, Hiyama T, Hoshiai S, Okamoto Y, Nasu K, Minami M. Endoleak detection after endovascular aneurysm repair using unenhanced MRI with flow suppression technique: Feasibility study in comparison with contrast-enhanced CT. Eur Radiol. 2017 Jan;27(1):336-344	Number of patients: 46 Study Location: Japan Setting: Department of Radiology Inclusion Criteria: Consecutive patients who underwent EVAR for aortic and/or iliac aneurysms aged between 46 and 90 years Written informed consent obtained Exclusion Criteria: Contraindication to contrast enhanced CT Predialysis renal failure Severe bronchial asthma Contraindication to unenhanced MR imaging: MR-incompatible stent graft Patient with pacemaker	MRI (detection of hyperintense areas)	CTA

Study ID	Study	Population	Index Test(s) (positive criterion)	Reference Test
Motta (2012)	Motta R, Rubaltelli L, Vezzano R, Vida V, Marchesi P, Stramare R, Zanon A, Battistel M, Somavilla M, and Miotto D (2012) Role of multidetector CT angiography and contrast-enhanced ultrasound in redefining follow-up protocols after endovascular abdominal aortic aneurysm repair. <i>La Radiologia medica</i> 117, 1079-92	Number of patients: 88 Study Location: Italy Setting: Department of Radiology Inclusion Criteria: Consecutive patients who underwent CTA Exclusion Criteria: <ul style="list-style-type: none"> Severe allergy to iodinated contrast Severe renal failure 	CEUS (presence of blood flow outside the lumen of the endoluminal graft but within the aneurysm sac)	CTA
Nagre (2011)	Nagre Shardul B, Taylor Steven M, Passman Marc A, Patterson Mark A, Combs Bart R, Lowman Bruce G, Jordan William D, and Jr (2011) Evaluating outcomes of endoleak discrepancies between computed tomography scan and ultrasound imaging after endovascular abdominal aneurysm repair. <i>Annals of vascular surgery</i> 25, 94-100	Number of patients: 455 Study Location: USA Setting: University of Alabama Inclusion Criteria: Patients who had undergone both CTA and CDUS at the same visit or within 7 days of each other Exclusion Criteria: Not specified	CDUS	CTA
Nerlekar (2006)	Nerlekar R, Warriar R, De Ryke R, Miller R, Hewitt P M, and Scott A (2006) A comparative study of ultrasound and computed tomography scan for the follow-up of abdominal aortic aneurysms after endovascular repair. <i>Journal for Vascular Ultrasound</i> 30, 81-85	Number of patients: 121 Study Location: Australia Setting: Department of Surgery Inclusion Criteria: All patients who underwent EVAR for an AAA and had CDUS and CT on the same day or within 1 month Exclusion Criteria: <ul style="list-style-type: none"> Patients with modified device configuration Pre-existing grafts 	CDUS	CTA

Study ID	Study	Population	Index Test(s) (positive criterion)	Reference Test
		<ul style="list-style-type: none"> Graft deployment failure Patients who died before 1 month follow up from the study US and CT scans performed in isolation 		
Oikonomou (2012)	Oikonomou K, Ventin F C, Paraskevas K I, Geisselsoder P, Ritter W, and Verhoeven E L (2012) Early follow-up after endovascular aneurysm repair: Is the first postoperative computed tomographic angiography scan necessary? Journal of Endovascular Therapy 19, 151-156	<p>Number of patients: 100 Study Location: Germany Setting: Department of Radiology Inclusion Criteria: Consecutive patients who underwent EVAR for infrarenal AAA Exclusion Criteria: Patients unsuitable for a postoperative CTA due to severely impaired renal function</p>	CDUS (presence of persistent blood flow and spectral signal outside the graft wall)	CTA
Pages (2001)	Pages S, Favre J P, Cerisier A, Pyneeandee S, Boissier C, and Veyret C (2001) Comparison of color duplex ultrasound and computed tomography scan for surveillance after aortic endografting. Annals of vascular surgery 15, 155-62	<p>Number of patients: 41 Study Location: France Setting: University Hospital Centre Inclusion Criteria: Patients referred for elective treatment. Exclusion Criteria: Not specified</p>	CDUS (detection of a colour and spectral signal outside the limits of the prosthesis)	CTA
Parent (2002)	Parent F Noel, 3rd, Godziachvili Vasso, Meier George H, 3rd, Parker Frank M, Carter Kathleen, Gayle Robert G, Demasi Richard J, and Gregory Roger T (2002) Endograft limb occlusion and stenosis after ANCURE endovascular abdominal aneurysm repair. Journal of vascular surgery 35, 686-90	<p>Number of patients: 83 Study Location: USA Setting: Department of Surgery Inclusion Criteria: Patients who underwent treatment before September 1999 Exclusion Criteria: Not specified</p>	CDUS (perigraft Doppler scan signals with colour flow and was confirmed with spectral analysis and mapping of the blood flow pattern)	CTA
Perini (2011)	Perini P, Sediri I, Midulla M, Delsart P, Mouton S, Gautier C, Pruvo J P,	Number of patients: 395	CEUS	CTA

Study ID	Study	Population	Index Test(s) (positive criterion)	Reference Test
	and Haulon S (2011) Single-centre prospective comparison between contrast-enhanced ultrasound and computed tomography angiography after EVAR. European journal of vascular and endovascular surgery : the official journal of the European Society for Vascular Surgery 42, 797-802	<p>Study Location: France Setting: Not specified Inclusion Criteria: All patients who underwent EVAR for AAA and for whom a follow-up with CTA and CEUS was undertaken. Exclusion Criteria: Patients who underwent thoracic endografting Patients with severe contrast media allergy Patients with severe renal insufficiency</p>	(persistent blood flow outside the lumen of the endoluminal graft but within the aneurysm sac)	
Perini (2012)	Perini P, Sediri I, Midulla M, Delsart P, Gautier C, and Haulon S (2012) Contrast-Enhanced ultrasound vs. CT angiography in fenestrated EVAR surveillance: A single-Center comparison. Journal of Endovascular Therapy 19, 648-655	<p>Number of patients: 62 Study Location: France Setting: University Hospital Inclusion Criteria: <ul style="list-style-type: none"> All patients who received a fenestrated stent-graft for juxtarenal abdominal aortic who had both CTA and CEUS imaging studies. Only fenestrated endografts with up to 3 fenestrations with or without a scallop for the celiac trunk or the superior mesenteric artery (SMA) were eligible so that entire implant could be visualised with standard abdominal ultrasound Exclusion Criteria: <ul style="list-style-type: none"> Patients who received endografts with >3 fenestrations </p>	CEUS (persistent blood flow outside the lumen of the endoluminal graft but within the aneurysm sac)	CTA

Study ID	Study	Population	Index Test(s) (positive criterion)	Reference Test
		<ul style="list-style-type: none"> • Patients who died in the early postoperative period • Patients who underwent a CT without contrast because of severe renal insufficiency • Inadequate CEUS due to intervening bowel gas or ascites 		
Raman (2003)	Raman Kathleen G, Missig-Carroll Nita, Richardson Tracey, Muluk Satish C, and Makaroun Michel S (2003) Color-flow duplex ultrasound scan versus computed tomographic scan in the surveillance of endovascular aneurysm repair. Journal of vascular surgery 38, 645-51	<p>Number of patients: 281 Study Location: USA Setting: University of Pittsburgh Medical Centre Inclusion Criteria: Patients who underwent EVAR with Ancure or AneuRX at the University of Pittsburgh Medical Centre. Exclusion Criteria: Not specified</p>	CDUS (visualisation and spectral confirmation of perigraft flow into aneurysm sac)	CTA
Schmieder (2009)	Schmieder Greg C, Stout Christopher L, Stokes Gordon K, Parent F Noel, and Panneton Jean M (2009) Endoleak after endovascular aneurysm repair: duplex ultrasound imaging is better than computed tomography at determining the need for intervention. Journal of vascular surgery 50, 1012-8	<p>Number of patients: 236 Study Location: USA Setting: Not specified Inclusion Criteria: Only patients with paired imaging studies \leq 3 months of each other were included. Exclusion Criteria: Patients with symptomatic or ruptured AAA and isolated iliac aneurysms.</p>	CDUS (presence of flow outside the graft)	CTA
Ten Bosch (2010)	Ten Bosch, Jan A, Rouwet Ellen V, Peters Cecile T. H, Jansen Linda, Verhagen Hence J. M, Prins Martin H, and Teijink Joep A. W (2010) Contrast-enhanced ultrasound versus computed tomographic angiography	<p>Number of patients: 236 Study Location: Netherlands Setting: Department of Vascular Surgery Inclusion Criteria: All patients who underwent EVAR for infrarenal AAA</p>	CEUS (flow and spectral signals within the aneurysm sac)	CTA

Study ID	Study	Population	Index Test(s) (positive criterion)	Reference Test
	for surveillance of endovascular abdominal aortic aneurysm repair. Journal of vascular and interventional radiology : JVIR 21, 638-43	Exclusion Criteria: Patients who could not undergo CT angiography as a result of severe iodinated contrast allergy or severe renal insufficiency		
Wolf (2000)	Wolf Y G, Johnson B L, Hill B B, Rubin G D, Fogarty T J, and Zarins C K (2000) Duplex ultrasound scanning versus computed tomographic angiography for postoperative evaluation of endovascular abdominal aortic aneurysm repair. Journal of vascular surgery 32, 1142-8	Number of patients: 100 Study Location: USA Setting: Stanford University Hospital Inclusion Criteria: Patients who underwent endovascular repair of AAA with the AneuRx (Medtronic) bifurcated endograft. Exclusion Criteria: Not specified	CDUS	CTA
Zannetti (2000)	Zannetti S, De Rango , P , Parente B, Parlani G, Verzini F, Maselli A, Nardelli L, and Cao P (2000) Role of duplex scan in endoleak detection after endoluminal abdominal aortic aneurysm repair. European journal of vascular and endovascular surgery : the official journal of the European Society for Vascular Surgery 19, 531-5	Number of patients: 103 Study Location: Italy Setting: Unit of Vascular Surgery Inclusion Criteria: Patients undergoing EVAR Exclusion Criteria: <ul style="list-style-type: none"> • Conversion to open repair • Duplex scan performed in a different centre in patients from out of town • Patient refusal • Patients with renal insufficiency • Patients in need of a different imaging technique (I.e. angiography in patients subjected to adjunctive peripheral revascularisation) • Inadequate duplex visualisation of the AAA sac due to obesity or intestinal gas. 	CDUS (reproducible colour signal outside the endograft and within the aneurysmal sac was visualised)	CTA

Quality assessment of clinical studies included in the evidence review

See Appendix F for full GRADE tables, highlighting the quality of evidence from the included studies

Economic evidence

A systematic review of economic literature was conducted jointly for all review questions in this guideline by applying standard health economic filters to a clinical search for AAA (see Appendix B). A total of 5,173 studies was identified. The studies were reviewed to identify economic evaluations in the form of cost–utility analyses evaluating imaging techniques for detecting postoperative complications, further aneurysm expansion and aneurysm rupture. Studies that met the eligibility criteria were assessed using the quality appraisal criteria as outlined in the Guidelines Manual (2014).

Included studies

Following an initial review of titles and abstracts, the full texts of 4 studies were retrieved for detailed consideration. Following full-text review, none of the 4 studies were judged to be potentially applicable cost–utility analyses.

An update search was conducted in December 2017, to identify any relevant cost–utility analyses that had been published during guideline development. This search returned 814 studies. Following review of titles and abstracts, no studies were ordered for detailed consideration.

No studies were therefore included as economic evidence for this review question.

Excluded studies

Studies that were excluded after full-text review, and reasons for exclusion, are provided in Appendix H – Excluded studies.

Evidence statements

Diagnostic test accuracy

Thirty-seven studies were identified which examined the diagnostic accuracy of different diagnostic tools (CDUS, CEUS and MRI) after EVAR. Two of these studies examined 3D and 1 study examined 4D CEUS. Diagnostic accuracy of the tools was evaluated using positive and negative likelihood ratios. The following schema, adapted from the suggestions of Jaeschke et al. (1994), was used to interpret the likelihood ratio findings from diagnostic test accuracy reviews.

Likelihood ratio	Value of likelihood ratio	Interpretation
Negative likelihood ratio	$LR \leq 0.1$	Very large decrease in probability of disease
	$0.1 < LR \leq 0.2$	Large decrease in probability of disease
	$0.2 < LR \leq 0.5$	Moderate decrease in probability of disease
	$0.5 < LR \leq 1.0$	Slight decrease in probability of disease
Positive likelihood ratio	$1.0 < LR < 2.0$	Slight increase in probability of disease
	$2.0 \leq LR < 5.0$	Moderate increase in probability of disease
	$5.0 \leq LR < 10.0$	Large increase in probability of disease
	$LR \geq 10.0$	Very large increase in probability of disease

The schema above has the effect of setting a minimal important difference for positive likelihoods ratio at 2, and a corresponding minimal important difference for negative likelihood ratios at 0.5. Likelihood ratios (whether positive or negative) falling between these thresholds were judged to indicate no meaningful change in the probability of disease.

Evidence statements were formed to reflect the different complications associated with AAA repair as well as people undergoing infrarenal and complex EVAR.

No studies were identified which assessed the diagnostic accuracy of different diagnostic tools after open surgical repair of AAA.

Identification of an any type of endoleak

Interpretation of positive test results

A positive finding on the following tools increases the probability that an endoleak is present to a degree that is likely to be **very large**:

- CEUS after complex EVAR (high-quality evidence from 1 study with 62 participants; 95% CI ranged from large to very large increase)
- 4D CEUS after complex EVAR (low-quality evidence from 1 study with 22 participants; 95% CI ranged from slight to very large increase)
- 3D CEUS after EVAR (Moderate-quality evidence from 2 studies with 130 measurements; 95% CI ranged from moderate to very large increase)
- MRI after EVAR (very low-quality evidence from 1 study with 46 participants; 95% CI ranged from moderate to very large increase).

A positive finding on the following tools increases the probability that an endoleak is present (based on positive likelihood ratio) to a degree that is likely to be **large**:

- CDUS after EVAR (very low-quality evidence from 24 studies including 4,198 measurements; 95% CI ranged from large to very large increase)
- CEUS after EVAR (very low-quality evidence from 15 studies including 1,667 measurements; 95% CI ranged from moderate to very large increase).

A negative finding on the following tools decreases the probability that an endoleak is present (based on negative likelihood ratio) to a degree that is likely to be **very large**:

- 3D CEUS after EVAR (Moderate-quality evidence from 2 studies including 130 people; 95% CI ranged from large to very large decrease)
- MRI after EVAR (very low-quality evidence from 1 study including 46 people; 95% CI ranged from moderate to very large decrease).

Interpretation of negative test results

Very low-quality evidence from 15 studies, including 1,667 measurements, indicated a negative finding on CEUS after EVAR decreases the probability that an endoleak is present to a degree that is likely to be large (95% CI ranged from large to very large decrease).

Very low-quality evidence from 24 studies, including 4,198 measurements, indicated a negative finding on CDUS after EVAR decreases the probability that an endoleak is present to a degree that is likely to be moderate.

The following tools could not demonstrate whether a negative finding altered the probability that an endoleak is present:

- CEUS after complex EVAR (moderate-quality evidence from 1 study including 62 people; 95% CI ranged from very large decrease to slight increase)
- 4D CEUS after complex EVAR (low-quality evidence from 1 study including 22 people; 95% CI ranged from large decrease to slight increase).

Identification of Type I and III endoleaks

Interpretation of positive test results

A positive finding on the following tools increases the probability that Type I and III endoleaks are present (based on positive likelihood ratio) to a degree that is likely to be **very large**:

- CDUS after EVAR (low-quality evidence from 7 studies including 1,346 measurements)
- CEUS after EVAR (high-quality evidence from 6 studies including 791 measurements)
- CEUS after complex EVAR (high-quality evidence from 1 study including 62 people; 95% CI ranged from large to very large increase).

Interpretation of negative test results

High-quality evidence from 6 studies, including 791 measurements, indicated a negative finding on CEUS after EVAR decreases the probability that a Type I or III endoleak is present to a degree that is likely to be large (95% CI ranged from moderate to very large decrease).

High-quality evidence from 7 studies, including 1,346 measurements, indicated a negative finding on CDUS after EVAR decreases the probability that a Type I or III endoleak is present to a degree that is likely to be moderate (95% CI ranged from slight to large decrease).

Low-quality evidence from 1 study, including 62 people, could not demonstrate whether a negative finding on CEUS after complex EVAR alters the probability that a Type I endoleak is present (95% CI ranged from very large decrease to moderate increase).

Identification of Type II endoleak

Interpretation of positive test results

A positive finding on the following tools increases the probability that a Type II endoleak is present (based on positive likelihood ratio) to a degree that is likely to be **very large**:

- CDUS after EVAR (very low-quality evidence from 5 studies including 1,242 measurements; 95% CI ranged from large to very large)
- CEUS after EVAR (low-quality evidence from 4 studies including 678 measurements)
- CEUS after complex EVAR (high-quality evidence from 1 study including 62 people; 95% CI ranged from moderate to very large increase).

Interpretation of negative test results

High-quality evidence from 4 studies, including 678 measurements, indicated a negative finding on CEUS after EVAR decreases the probability that a Type II endoleak is present to a degree that is likely to be very large (95% CI ranged from large to very large decrease).

High-quality evidence from 5 studies, including 1,242 measurements, indicated a negative finding on CDUS after EVAR decreases the probability that a Type II endoleak is present to a degree that is likely to be moderate (95% CI ranged from slight to very large decrease).

Moderate-quality evidence from 1 study, including 62 people, could not demonstrate whether a negative finding on CEUS after complex EVAR alters the probability that a Type II endoleak is present (95% CI ranged from very large decrease to slight increase).

Identification of overall change in aneurysm size

Low-quality evidence from 2 studies, including 773 measurements, could not demonstrate whether a positive finding on CDUS after alters the probability of a change in aneurysm size (95% CI ranged from slight decrease to very large increase).

Low-quality evidence from 2 studies, including 773 measurements, indicated a negative finding on CDUS after EVAR decreases the probability of a change in aneurysm size to a degree that is likely to be large (95% CI ranged from large to very large decrease).

Identification of aneurysm expansion

Moderate-quality evidence from 1 study, including 180 measurements, indicated a positive finding on CDUS after EVAR increases the probability that an aneurysm has grown to a degree that is likely to be very large (95% CI ranged from large to very large decrease).

Low-quality evidence from 1 study, including 180 measurements, indicated a negative finding on CDUS after EVAR decreases the probability that an aneurysm has grown to a degree that is likely to be slight (95% CI ranged from slight to moderate decrease).

Identification of aneurysm reduction

Moderate-quality evidence from 1 study, including 657 measurements, indicated a positive finding on CDUS after EVAR increases the probability that an aneurysm has become smaller to a degree that is likely to be moderate.

Moderate-quality evidence from 1 study, including 657 measurements, indicated a negative finding on CDUS after EVAR decreases the probability that an aneurysm has become smaller to a degree that is likely to be very large.

Identification of graft occlusion

Moderate-quality evidence from 1 study, including 134 measurements, indicated a positive finding on CEUS after EVAR increases the probability that graft occlusion is present to a degree that is likely to be very large (95% CI ranged from large to very large increase).

Low-quality evidence from 1 study, including 134 measurements, indicated a negative finding on CEUS after EVAR decreases the probability that that graft occlusion is present to a degree that is likely to be moderate (95% CI ranged from slight to moderate decrease).

The committee's discussion of the evidence

Interpreting the evidence

The outcomes that matter most

In the evidence review, sensitivity, specificity and likelihood ratios were calculated for each index test. The committee took into consideration the likelihood ratios but also examined the sensitivity of index tests in the identification of different complications.

While no evidence on patient and clinician acceptability was identified, the committee took these outcomes into consideration when making recommendations.

The quality of the evidence

Overall, the evidence ranged from very low to moderate quality. The studies had varying follow-up periods and were conducted in a number of different settings. Only 4 studies were conducted in the UK.

In a number of studies, methodological limitations were identified. Firstly, a number of studies did not specify if the results from the reference standard were blinded from the results of the index test. Due to this uncertainty in blinding, these studies were downgraded for risk of bias. A number of studies were downgraded for risk of bias because the time interval between the reference standard and index test was not specified. Studies in which the time interval between the 2 tests spanned more than 1 month were also downgraded for serious risk of bias, as disease progression during this time interval could have had an impact on the results.

A number of studies did not adequately provide a definition for a positive identification of the complication of interest. Studies in which definition of a positive test was not provided or unclear were downgraded for risk of bias. The committee also further discussed the studies in which a definition was provided. In relation to the identification of endoleak with CDUS, a number of studies defined the complication as the persistent blood flow outside the lumen of the graft. The committee agreed that this imaging sign is insufficiently sensitive to detect all endoleaks.

In relation to aneurysm expansion, 2 studies (Bargellini et al., 2009 and Pages et al., 2001) defined sac expansion on CDUS as an increase in the maximum anteroposterior or transverse sac diameter. The committee noted that measuring transverse diameter using CDUS was challenging. Similarly, 1 study (Motta et al., 2012) was identified which examined accuracy of CEUS in the identification of graft occlusion. The study defined graft occlusion as the presence of endograft partial thrombosis. The committee did not find this to be an adequate indicator of the risk of graft occlusion.

A number of studies were downgraded for indirectness. One study was identified which examined the diagnostic accuracy of unenhanced MRI. This study specifically examined unenhanced 2D motion sensitised-driven equilibrium (MSDE)-prepared balanced turbo filled echo (BTFE) sequences. The committee noted that this is not a sequence commonly used in practice. Due to this, the study was downgraded for indirectness, as it was not viewed as being representative of conventional MRI. Due to the quality of the study, the committee did not make recommendations for the use of MRI.

The review protocol specified studies published since 2000. All studies included in the review met this criterion, though 4 studies (Golzarian et al., 2002; Pages et al.,

2001; Wolf et al., 2000 and Zannetti et al., 2000), whilst published after 2000, were undertaken before this date. A sensitivity analysis was conducted in which these studies were removed from the assessment of the diagnostic accuracy of CDUS. This resulted in a slight decrease in the overall estimate of CDUS diagnostic accuracy. These 4 studies were downgraded for partial indirectness. The committee were mindful that ultrasound technology has advanced considerably over the past decade. Furthermore, they noted that in some of the included studies the identification of endoleaks was based on ultrasound images acquired by technicians and retrospectively reviewed by radiologists. In light of this, a second sensitivity analysis was performed to consider only studies published from 2008 onwards in which the presence of endoleaks was determined in real-time by the person who was performing the scan. This sensitivity analysis indicated a slight increase in the diagnostic accuracy of CDUS, however the increase was not significant enough to change the committee's conclusions.

Benefits and harms

The committee agreed on the importance of early identification of complications, particularly aneurysm expansion and endoleaks. Based on their experience, the committee agreed that there is considerable variation in monitoring strategies adopted across the NHS. Some centres use CTA as the primary imaging tool to detect sac expansion and endoleaks - CT is widely accepted as a reference standard due to its high diagnostic accuracy. In other centres, ultrasound is used as the main imaging modality to observe changes in sac size and detect large high flow endoleaks. Where changes in sac size are found on ultrasound further imaging with imaging tools that have higher discriminatory power is then undertaken. Since the evidence demonstrated that CDUS had a satisfactory sensitivity and specificity in identifying changes in sac size, the committee considered that this was a reasonable approach, so long as any abnormalities are subsequently explored with contrast-enhanced CTA or CEUS to exclude the presence of endoleaks.

The committee believed that CEUS was appropriate for exclusion of endoleaks because the addition of contrast agent improves the performance of ultrasound considerably when compared with CDUS alone.

While CDUS is used in the surveillance of post-operative complications following EVAR in some settings, the committee recommended against its use as a definitive imaging tool. The committee formed these conclusions based on the evidence which showed CDUS to have insufficient sensitivity for certain kinds of endoleak. This led the committee to agree that the use of CDUS as the sole imaging tool would not allow some complications, in particular type I and III endoleaks, to be adequately excluded.

Two studies of low quality were identified that demonstrated 3D CEUS to increase the probability of identifying endoleaks in people who have undergone fenestrated EVAR. One study was also identified which demonstrated 4D CEUS increases the probability of identifying endoleaks in people who have undergone EVAR. It was discussed that 3D imaging allows clinicians to form a complete picture of the complication and 4D imaging allows movement over time to be captured. However, the committee noted that, while these imaging techniques showed promise, additional software is required compared with standard 2D CEUS. Taking into consideration the quality of the evidence and cost and training implications, the committee did not make any recommendations on 3D and 4D CEUS.

Cost effectiveness and resource use

The committee advised that current practice in this area varies extensively, with some centres using only ultrasound, others using only CTA, and some using a mixture of techniques. It is the committee's experience that CEUS has not been widely adopted in practice as a replacement for duplex ultrasound; it is mainly used only in large, specialist centres. The primary reason for this is that CEUS requires important new skills for sonographers – requiring cannulation of the patient and administration of contrast. These are skills that, in many cases, would require additional training and, potentially, medical staff to deal with any complications that may occur. In addition, the committee cited a perceived patient preference for not being cannulated, and a perception that CEUS does not materially influence subsequent decision-making compared with duplex ultrasound.

The committee discussed the resource implications of using CEUS over duplex ultrasound, and of using CTA over either ultrasound technique. CEUS requires administering contrast agent (approximately £40–60 per vial), a one-off software cost, as well as cannulation and contrast delivery, with the associated training and staff needs described above. CTA has a higher unit cost than both ultrasound techniques.

The committee discussed the cost implications of a hypothetical situation in which CTA was used as the main imaging modality for detecting postoperative complications. Using conservative assumptions, the resource impact of using CTA alone as a first-line post-EVAR surveillance technique was estimated to have an upper limit of £860,000 per year, based on NHS reference costs data (3,875 EVARs in England, 2016–17). This assumes that current practice is 100% duplex ultrasound, to be replaced by CTA in 100% of cases, using NHS tariff costs of £85 for CTA and £48 for ultrasound. It assumes that newly-repaired aneurysms require 2 scans during their first year after AAA repair, and that in any given year there will be the same number of aneurysms receiving a single scan in years 2, 3, 4 and 5 after EVAR, giving a total of 23,250 scans per year. The resulting figure of £860,000 represents the maximum possible resource impact of using CTA in all cases.

In reality the resource impact of the recommendation is likely to be small, primarily because complimentary imaging regimens based on US assessment of sac size as an initial surveillance modality are widely adopted.

Furthermore, elsewhere in this guideline the committee have recommended against the use of EVAR for the repair of unruptured infrarenal AAA for patients who are suitable for OSR, and outside of a clinical trial for those who are not. EVAR for unruptured complex AAA should also only be undertaken in the context of an RCT. The alternative surgical procedure, open surgical repair, requires less follow-up surveillance, typically a single 1 consultation. Given that these elective procedures make up the large majority of AAA repair procedures performed in the UK, a shift in practice from EVAR towards open surgery will reduce the number of EVARs per year significantly from the 3,875 figure identified above, removing most elective EVARs and leaving mainly emergency cases. This would reduce the overall resource required for post EVAR surveillance.

Other factors the committee took into account

It was identified that studies included in this review predominantly enrolled men, which raised questions about the generalisability of the results to women. In the absence of evidence, it was agreed that the accuracy of the diagnostic tools would not be expected vary between these 2 groups.

Along with assessing diagnostic test accuracy, this question aimed to determine which imaging techniques are most acceptable to people with AAAs and clinicians, taking into account the safety profiles. While no studies which examined the acceptability of diagnostic tools were identified, the committee did take this into consideration when making recommendations.

The committee noted that CEUS involves intravenous administration of microbubble contrast material, but this is generally well tolerated by people. The need for cannulation and administration of contrast could have an impact on clinician acceptability. However, the committee noted that CEUS is a sensitive tool and would allow clearer visualisation of complications, particularly endoleaks.

For CTA, there is a small but non-zero risk of contrast-induced nephropathy associated with administering iodinated contrast agents, especially in people with established renovascular disease (which is common in the population undergoing AAA repair). Some people are also allergic to the contrast agent used. The committee also discussed that CTA is associated with exposure to ionising radiation. Since CTA was not recommended as the sole imaging tool for detecting complications, the committee agreed that it was unlikely to be used often enough in individual patients to result in a meaningful increase in the occurrence of malignancies. They were in agreement that the average life expectancy following EVAR is too short for radiation-induced cancer to develop in most people undergoing endoleak surveillance. Taking the safety profile of CTA into consideration, the committee recommended the use of CEUS in people with contraindications to contrast-enhanced CTA.

No studies were identified that examined the diagnostic accuracy of imaging tools in the follow-up of people undergoing open surgical repair. The committee noted that complications do occur following open surgical repair; however these tend to be clinically manifested earlier, which means that a comprehensive follow-up programme is not required. Therefore, recommendations were confined to imaging follow-up after EVAR.

Appendices

Appendix A – Review protocols

Review protocol for the effectiveness of tests in predicting poor and good surgical outcomes

Review Question 28	When monitoring people after they have had EVAR or open repair of an abdominal aortic aneurysm, which imaging techniques are most useful for detecting postoperative complications, further aneurysm expansion and aneurysm rupture?
Objectives	To determine which imaging technique is most accurate in identifying complications (endoleak, graft migration, graft kinking, graft occlusion and aortic neck expansion), further aneurysm expansion and aneurysm rupture in people who have undergone surgical repair of an AAA To determine which imaging techniques are most acceptable to patients and clinicians, taking into account the safety profiles of the approaches
Type of review	Diagnostic
Language	English only
Study design	Systematic reviews of study designs listed below Cross-sectional studies
Status	Published papers only (full text) No date restrictions
Population	People who have undergone surgical repair of an abdominal aortic aneurysm Subgroup: position of aneurysm
Index test	Ultrasound, including colour duplex ultrasound (CDUS), contrast-enhanced CDUS Plain film radiography, aortography/angiography CT Helical CT technology MRI Intrasac pressure monitoring
Reference standard	Computed tomographic angiography, preferably with post-processing techniques/workstations – dual or triple or venous phase
Endpoints	Diagnostic accuracy (sensitivity and specificity for endoleak, graft migration, graft kinking, graft occlusion, aortic neck expansion) Adverse events Acceptability of approach to patients and clinicians
Other criteria for inclusion / exclusion of studies	Exclusion: Non-English language Abstract/non-published Diagnostic accuracy measures for which both sensitivity and specificity are not available/ cannot be calculated Publication before the year 2000
Baseline characteristics to be	Age Sex

Review Question 28	When monitoring people after they have had EVAR or open repair of an abdominal aortic aneurysm, which imaging techniques are most useful for detecting postoperative complications, further aneurysm expansion and aneurysm rupture?
extracted in evidence tables	Size of aneurysm Comorbidities Date of first investigation
Search strategies	See Appendix B
Review strategies	Appropriate NICE Methodology Checklists, depending on study designs, will be used as a guide to appraise the quality of individual studies. Available Cochrane review (Abraha, 2013) will be used as a 'seed review' for the identification of endoleak. Abraha's Cochrane review (ongoing at the time of protocol development) will be used as the evidence base for ultrasound for endoleak in people who have undergone EVAR for AAA Data on all included studies will be extracted into evidence tables. Where statistically possible, a meta-analytic approach will be used to give an overall summary effect. All key findings from evidence will be presented in GRADE profiles and further summarised in evidence statements.
Key papers	Endoleak: Armerding MD, Rubin GD, Beaulieu CF, Slonim SM, Olcott EW, Samuels SL, Jorgensen MJ, Semba CP, Jeffrey RB Jr, Dake MD. Aortic aneurysmal disease: assessment of stent-graft treatment-CT versus conventional angiography. <i>Radiology</i> . 2000 Apr;215(1):138-46 Ayuso JR, de Caralt TM, Pages M, Riambau V, Ayuso C, Sanchez M, Real MI, Montaña X. MRA is useful as a follow-up technique after endovascular repair of aortic aneurysms with nitinol endoprostheses. <i>J Magn Reson Imaging</i> . 2004 Nov;20(5):803-10 Bendick PJ, Bove PG, Long GW, Zelenock GB, Brown OW, Shanley CJ. Efficacy of ultrasound scan contrast agents in the noninvasive follow-up of aortic stent grafts. <i>J Vasc Surg</i> . 2003 Feb;37(2):381-5 Elkouri S, Panneton JM, Andrews JC, Lewis BD, McKusick MA, Noel AA, Rowland CM, Bower TC, Cherry KJ Jr, Gloviczki P. Computed tomography and ultrasound in follow-up of patients after endovascular repair of abdominal aortic aneurysm. <i>Ann Vasc Surg</i> . 2004 May;18(3):271-9 Gargiulo, M., Gallitto, E., Serra, C., Freyrie, A., Mascoli, C., Bianchini Massoni, C., et al. Could four-dimensional contrast-enhanced ultrasound replace computed tomography angiography during follow up of fenestrated endografts? Results of a preliminary experience. <i>Eur J Vasc Endovasc Surg</i> 2014;48(5):536-42 Giannoni MF, Palombo G, Sbarigia E, Speciale F, Zaccaria A, Fiorani P. Contrast-enhanced ultrasound imaging for aortic stent-graft surveillance. <i>J Endovasc Ther</i> . 2003 Apr;10(2):208-17. Henao EA, Hodge MD, Felkai DD, McCollum CH, Noon GP, Lin PH, Lumsden AB, Bush RL. Contrast-enhanced Duplex surveillance after endovascular abdominal aortic aneurysm repair: improved efficacy using a continuous infusion technique. <i>J Vasc Surg</i> . 2006 Feb;43(2):259-64 Iezzi R, Cotroneo AR, Filippone A, Di Fabio F, Quinto F, Colosimo C, Bonomo L. Multidetector CT in abdominal aortic aneurysm

Review Question 28	When monitoring people after they have had EVAR or open repair of an abdominal aortic aneurysm, which imaging techniques are most useful for detecting postoperative complications, further aneurysm expansion and aneurysm rupture?
	<p>treated with endovascular repair: are unenhanced and delayed phase enhanced images effective for endoleak detection? Radiology. 2006 Dec;241(3):915-21</p> <p>Sandford RM, Bown MJ, Fishwick G, Murphy F, Naylor M, Sensier Y, Sharpe R, Walker J, Hartshorn T, London NJ, Sayers RD. Duplex ultrasound scanning is reliable in the detection of endoleak following endovascular aneurysm repair. Eur J Vasc Endovasc Surg. 2006 Nov;32(5):537-41</p> <p>van der Laan MJ, Bartels LW, Viergever MA, Blankensteijn JD. Computed tomography versus magnetic resonance imaging of endoleaks after EVAR. Eur J Vasc Endovasc Surg. 2006 Oct;32(4):361-5</p> <p>Wolf YG, Johnson BL, Hill BB, Rubin GD, Fogarty TJ, Zarins CK. Duplex ultrasound scanning versus computed tomographic angiography for postoperative evaluation of endovascular abdominal aortic aneurysm repair. J Vasc Surg. 2000 Dec;32(6):1142-8</p>

Appendix B – Literature search strategies

Clinical search literature search strategy

Main searches

Bibliographic databases searched for the guideline

- Cumulative Index to Nursing and Allied Health Literature - CINAHL (EBSCO)
- Cochrane Database of Systematic Reviews – CDSR (Wiley)
- Cochrane Central Register of Controlled Trials – CENTRAL (Wiley)
- Database of Abstracts of Reviews of Effects – DARE (Wiley)
- Health Technology Assessment Database – HTA (Wiley)
- EMBASE (Ovid)
- MEDLINE (Ovid)
- MEDLINE Epub Ahead of Print (Ovid)
- MEDLINE In-Process (Ovid)

Identification of evidence for review questions

The searches were conducted between November 2015 and October 2017 for 31 review questions (RQ). In collaboration with Cochrane, the evidence for several review questions was identified by an update of an existing Cochrane review. Review questions in this category are indicated below. Where review questions had a broader scope, supplement searches were undertaken by NICE.

Searches were re-run in December 2017.

Where appropriate, study design filters (either designed in-house or by McMaster) were used to limit the retrieval to, for example, randomised controlled trials. Details of the study design filters used can be found in section 4.

Search strategy review question 28

Abraha Iosief, Luchetta Maria Laura, De Florio , Rita , Cozzolino Francesco, Casazza Giovanni, Duca Piergiorgio, Parente Basso, Orso Massimiliano, Germani Antonella, Eusebi Paolo, and Montedori Alessandro (2017) Ultrasonography for endoleak detection after endoluminal abdominal aortic aneurysm repair. The Cochrane database of systematic reviews 6, CD010296

Medline Strategy, searched 13th April 2016

Database: Ovid MEDLINE(R) 1946 to March Week 5 2016

Search Strategy:

- 1 Aortic Aneurysm, Abdominal/
- 2 (aneurysm* adj4 (abdom* or thoracoabdom* or thoraco-abdom* or aort* or spontan* or juxtarenal* or juxta-renal* or juxta renal* or paraarenal* or para-renal* or para renal* or suprarenal* or supra renal* or supra-renal* or short neck* or short-neck* or shortneck* or visceral aortic segment*)).tw.
- 3 Aortic Rupture/
- 4 (AAA or RAAA).tw.

Medline Strategy, searched 13th April 2016**Database: Ovid MEDLINE(R) 1946 to March Week 5 2016****Search Strategy:**

- 5 (endovascular* adj4 aneurysm* adj4 repair*).tw.
- 6 (endovascular* adj4 aort* adj4 repair*).tw.
- 7 (EVAR or EVRAR or FEVAR or F-EAVAR or BEVAR or B-EVAR).tw.
- 8 (Anaconda or Zenith Dynalink or Hemobahn or Luminex* or Memoth-erm or Wallstent).tw.
- 9 (Viabahn or Nitinol or Hemobahn or Intracoil or Tantalum).tw.
- 10 or/1-9
- 11 X-Rays/
- 12 (x-ray* or x ray* or xray* or x-radiation* or x radiation* or roentgen ray* or grenz ray* or radiograph*).tw.
- 13 Aortography/
- 14 aortograph*.tw.
- 15 Tomography, X-Ray Computed/ (
- 16 (cat scan* or ct scan* or cine ct or cine-ct or tomodensitomet*).tw.
- 17 ((computed or computer assisted or computeriz* or computeris* or electron beam* or axial*) adj4 tomograph*).tw.
- 18 Four-Dimensional Computed Tomography/
- 19 (4d ct or 4dct or 4-dimensional CT or four dimensional CT).tw.
- 20 exp Tomography, Spiral Computed/
- 21 ((helical or spiral) adj4 ct*).tw.
- 22 exp Magnetic Resonance Imaging/
- 23 (nmr tomograph* or mr tomograph* or nmr imag* or mri scan* or functional mri* or fmri* or zeugmatograph* or cine-mri* or cinemri*).tw.
- 24 (proton spin adj4 tomograph*).tw.
- 25 ((chemical shift or magnetic resonance or magneti* transfer) adj4 imag*).tw.
- 26 exp Angiography/
- 27 (angiograph* or arteriograph*).tw.
- 28 exp Ultrasonography/
- 29 (ultrasound* or ultrason* or sonograph* or echograph* or echotomograph*).tw.
- 30 exp Echocardiography/
- 31 echocardiograph*.tw.
- 32 Finite element analysis/
- 33 (finite adj4 element* adj4 analys*).tw.
- 34 (finite adj4 element* adj4 comput*).tw.
- 35 FEA.tw.
- 36 ((wall adj4 stress adj4 analys*) or (wall adj4 stress adj4 comput*).tw.
- 37 exp Computer simulation/
- 38 Software/
- 39 Image interpretation, computer-assisted/ or Radiographic image interpretation, computer-assisted/
- 40 Imaging Three-Dimensional/
- 41 exp Image enhancement/
- 42 Stress, mechanical/
- 43 (stress* adj4 mechanical*).tw.
- 44 (scan* or imag*).tw.
- 45 Watchful waiting/
- 46 (watchful adj4 waiting*).tw.
- 47 Mass screening/
- 48 screen*.tw.

Medline Strategy, searched 13th April 2016**Database: Ovid MEDLINE(R) 1946 to March Week 5 2016****Search Strategy:**

49 Population surveillance/
 50 surveillan*.tw.
 51 ((period* or test* or frequen* or regular* or routine* or rate or optimal* or optimis* or optimiz* or repeat* or interval*) adj4 (test* or monitor* or observ* or measur* or assess* or screen* or re-screen* or rescreen* or exam* or evaluat*)).tw.
 52 ((aneursym* or sign* or diameter or risk*) adj4 (grow* or siz* or measur* or expan* or ruptur* or tear* or progress* or enlarg* or dilat* or bulg* or evaluat*)).tw.
 53 Patient Selection/
 54 ((patient or subject or criteria or treatment*) adj4 select*).tw.
 55 ((follow-up or follow up) adj4 (visit* or repeat* or monitor* or assess* or care*)).tw.
 56 Aftercare/
 57 (aftercare or after-care).tw.
 58 Disease progression/
 59 ((disease or illness or condition) adj4 (progress* or worsen* or exacerbat* or deterior* or course or duration or trajector* or improv* or recur* or relaps* or remission)).tw.
 60 or/11-59
 61 10 and 60
 62 animals/ not humans/
 63 61 not 62
 64 limit 63 to english language

Note: RCT, Systematic Review and Observational study filters appended to strategy.

Health Economics literature search strategy**Sources searched to identify economic evaluations**

- NHS Economic Evaluation Database – NHS EED (Wiley) last updated Dec 2014
- Health Technology Assessment Database – HTA (Wiley) last updated Oct 2016
- Embase (Ovid)
- MEDLINE (Ovid)
- MEDLINE In-Process (Ovid)

Search filters to retrieve economic evaluations and quality of life papers were appended to the population and intervention terms to identify relevant evidence. Searches were not undertaken for qualitative RQs. For social care topic questions additional terms were added. Searches were re-run in September 2017 where the filters were added to the population terms.

Health economics search strategy**Medline Strategy**

Economic evaluations

- 1 Economics/
- 2 exp "Costs and Cost Analysis"/
- 3 Economics, Dental/
- 4 exp Economics, Hospital/
- 5 exp Economics, Medical/
- 6 Economics, Nursing/

Medline Strategy

7 Economics, Pharmaceutical/
8 Budgets/
9 exp Models, Economic/
10 Markov Chains/
11 Monte Carlo Method/
12 Decision Trees/
13 econom*.tw.
14 cba.tw.
15 cea.tw.
16 cua.tw.
17 markov*.tw.
18 (monte adj carlo).tw.
19 (decision adj3 (tree* or analys*)).tw.
20 (cost or costs or costing* or costly or costed).tw.
21 (price* or pricing*).tw.
22 budget*.tw.
23 expenditure*.tw.
24 (value adj3 (money or monetary)).tw.
25 (pharmacoeconomic* or (pharmaco adj economic*)).tw.
26 or/1-25

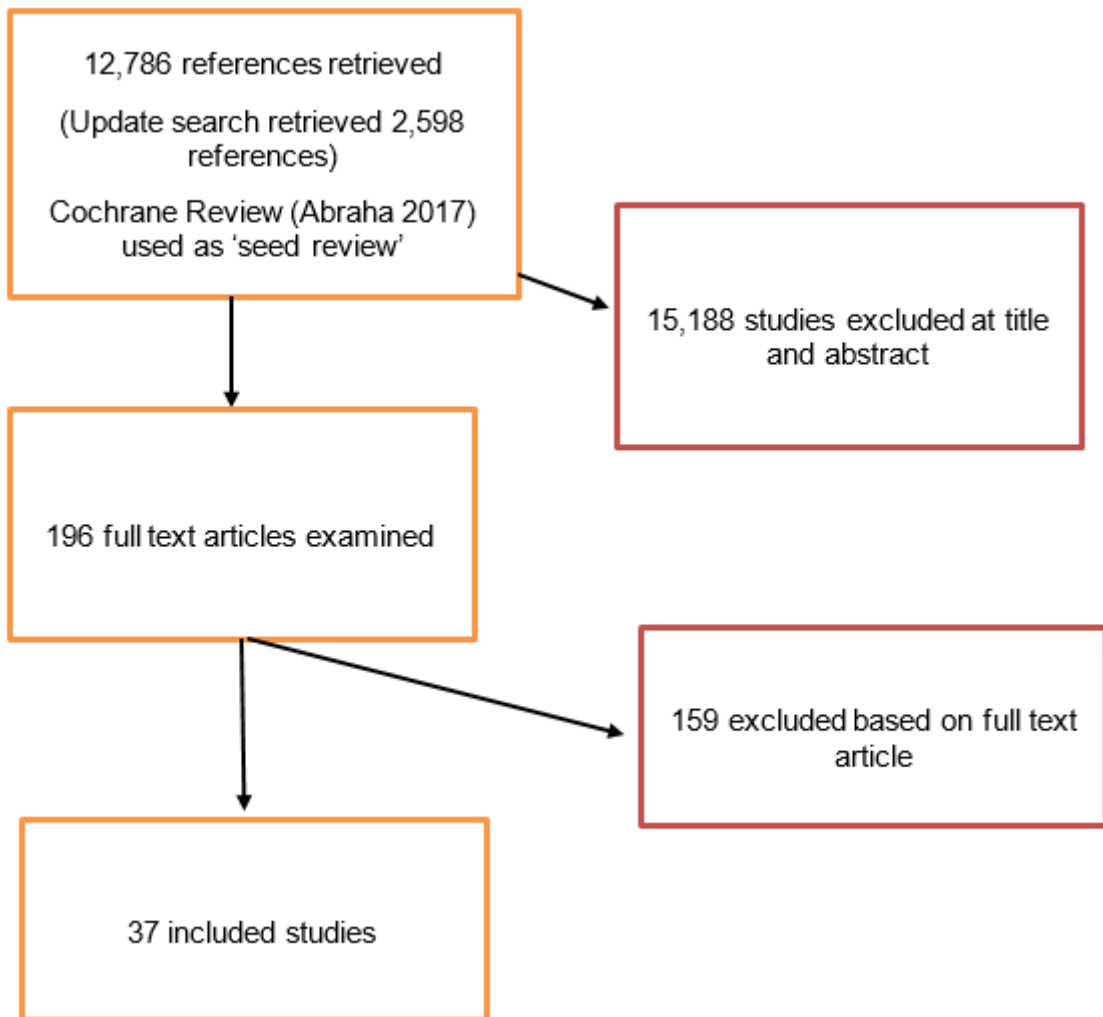
Quality of life

1 "Quality of Life"/
2 quality of life.tw.
3 "Value of Life"/
4 Quality-Adjusted Life Years/
5 quality adjusted life.tw.
6 (qaly* or qald* or qale* or qtime*).tw.
7 disability adjusted life.tw.
8 daly*.tw.
9 Health Status Indicators/
10 (sf36 or sf 36 or short form 36 or shortform 36 or sf thirtysix or sf thirty six or shortform thirtysix or shortform thirty six or short form thirtysix or short form thirty six).tw.
11 (sf6 or sf 6 or short form 6 or shortform 6 or sf six or sfsix or shortform six or short form six).tw.
12 (sf12 or sf 12 or short form 12 or shortform 12 or sf twelve or sftwelve or shortform twelve or short form twelve).tw.
13 (sf16 or sf 16 or short form 16 or shortform 16 or sf sixteen or sfsixteen or shortform sixteen or short form sixteen).tw.
14 (sf20 or sf 20 or short form 20 or shortform 20 or sf twenty or sftwenty or shortform twenty or short form twenty).tw.
15 (euroqol or euro qol or eq5d or eq 5d).tw.
16 (qol or hql or hqol or hrqol).tw.
17 (hye or hyes).tw.
18 health* year* equivalent*.tw.
19 utilit*.tw.
20 (hui or hui1 or hui2 or hui3).tw.
21 disutili*.tw.
22 rosser.tw.
23 quality of wellbeing.tw.
24 quality of well-being.tw.

Medline Strategy

- 25 qwb.tw.
- 26 willingness to pay.tw.
- 27 standard gamble*.tw.
- 28 time trade off.tw.
- 29 time tradeoff.tw.
- 30 tto.tw.
- 31 or/1-30

Appendix C – Clinical evidence study selection



Appendix D – Clinical evidence tables

Full citation	Abbas A, Hansrani V, Sedgwick N, Ghosh J, and McCollum C N (2014) 3D contrast enhanced ultrasound for detecting endoleak following endovascular aneurysm repair (EVAR). European Journal of Vascular and Endovascular Surgery 47, 487-492																															
Study type	Cross sectional study																															
Aim	Compare 3D CEUS with CTA for the detection of endoleak and aneurysm expansion following EVAR.																															
Patient Characteristics	<p>Inclusion criteria: Consecutive subjects attending for CTA and 3D CEUS imaging who were thought to possibly have an endoleak following an EVAR</p> <p>Exclusion criteria: Subjects who did not have paired CTA imaging.</p> <table border="1"> <thead> <tr> <th colspan="3">Study Characteristics</th> </tr> </thead> <tbody> <tr> <td>Age (years; mean \pm SD)</td> <td></td> <td>77.4 \pm 6</td> </tr> <tr> <td>Males (%)</td> <td></td> <td>88%</td> </tr> <tr> <td>BMI (kg/m²; mean \pm SD)</td> <td></td> <td>29 \pm 4</td> </tr> <tr> <td>Creatinine (mmol/L; mean \pm SD)</td> <td></td> <td>101 \pm 35</td> </tr> <tr> <td>Stent-graft: bifurcated</td> <td></td> <td>80%</td> </tr> <tr> <td>Stent-graft: Uniliac</td> <td></td> <td>20%</td> </tr> <tr> <td>Elective EVAR</td> <td></td> <td>96%</td> </tr> <tr> <td>Emergency EVAR</td> <td></td> <td>4%</td> </tr> <tr> <td>Aneurysm Size</td> <td></td> <td>Not reported</td> </tr> </tbody> </table>		Study Characteristics			Age (years; mean \pm SD)		77.4 \pm 6	Males (%)		88%	BMI (kg/m ² ; mean \pm SD)		29 \pm 4	Creatinine (mmol/L; mean \pm SD)		101 \pm 35	Stent-graft: bifurcated		80%	Stent-graft: Uniliac		20%	Elective EVAR		96%	Emergency EVAR		4%	Aneurysm Size		Not reported
Study Characteristics																																
Age (years; mean \pm SD)		77.4 \pm 6																														
Males (%)		88%																														
BMI (kg/m ² ; mean \pm SD)		29 \pm 4																														
Creatinine (mmol/L; mean \pm SD)		101 \pm 35																														
Stent-graft: bifurcated		80%																														
Stent-graft: Uniliac		20%																														
Elective EVAR		96%																														
Emergency EVAR		4%																														
Aneurysm Size		Not reported																														
Sample Size	23 patients																															
Index test(s)	<p>2D CEUS and 3D CEUS</p> <p>With patients supine, the AAA and stent-graft were visualised and traced to the proximal neck, with was measured in cross-section and interrogated for potential endoleak using low colour flow velocity or power Doppler colour flow settings. After administration of SonoVue (contrast agent) into a peripheral vein (2-5mL), the aorta was scanned methodically in transverse section from the neck of the graft to the distal stent-graft in the iliac arteries. The image acquisition for 2D and 3D CEUS is simultaneous and takes 10-15 minutes, with subsequent analysis of the 3D images taking a further 5-10 minutes. The images were analysed independently by two fully trained vascular laboratory technologist.</p>																															

Full citation	Abbas A, Hansrani V, Sedgwick N, Ghosh J, and McCollum C N (2014) 3D contrast enhanced ultrasound for detecting endoleak following endovascular aneurysm repair (EVAR). European Journal of Vascular and Endovascular Surgery 47, 487-492
Reference standard(s)	CTA All patients had paired CTA images as part of their routine EVAR surveillance
Study Details	Study location: Manchester, UK Study setting: Tertiary referral vascular centre Study dates: May 2012 to May 2013 Loss to follow-up: Not specified. Time between testing & Treatment: The interval between paired images was an average of 3.9 weeks (range: same day to 8 weeks) Source of funding: Manchester Surgical Research Trust (MSRT)
Quality Assessment (QUADAS 2)	Patient selection: Low risk of bias Index test: Unclear risk of bias. Unclear if index results were interpreted without knowledge of the reference standard. Definition of endoleak not provided Reference standard: Unclear risk of bias. Unclear if reference standard results were interpreted without knowledge of the index test. Flow and timing: High risk of bias. Inadequate time interval between index test and reference standard. Overall risk of bias: High risk of bias Directness: Directly applicable

Full citation	AbuRahma Ali F, Welch Christine A, Mullins Bandy B, and Dyer Benjamin (2005) Computed tomography versus color duplex ultrasound for surveillance of abdominal aortic stent-grafts. Journal of endovascular therapy: an official journal of the International Society of Endovascular Specialists 12, 568-73																					
Study type	Cross sectional																					
Aim	Compare the ability of computed tomography (CT) and colour duplex ultrasound (CDUS) to detect endoleak and accurately measure aortic aneurysm diameters after endovascular repair.																					
Patient Characteristics	<p>Inclusion criteria: Patients undergoing endovascular AAA repair using 3 commercially available devices Exclusion criteria: Not specified. Patient characteristics:</p> <table border="1"> <thead> <tr> <th colspan="2">Study Characteristics</th> </tr> </thead> <tbody> <tr> <td>Age (years; range)</td> <td>74 years (49-89)</td> </tr> <tr> <td>Males (%)</td> <td>88%</td> </tr> <tr> <td>BMI (kg/m²; mean± SD)</td> <td>29± 4</td> </tr> <tr> <td>Creatinine (mmol/L; mean± SD)</td> <td>101±35</td> </tr> <tr> <td>Stent-graft: bifurcated</td> <td>80%</td> </tr> <tr> <td>Stent-graft: Uniliac</td> <td>20%</td> </tr> <tr> <td>Elective EVAR</td> <td>96%</td> </tr> <tr> <td>Emergency EVAR</td> <td>4%</td> </tr> <tr> <td>Aneurysm Size</td> <td>Not reported</td> </tr> </tbody> </table>		Study Characteristics		Age (years; range)	74 years (49-89)	Males (%)	88%	BMI (kg/m ² ; mean± SD)	29± 4	Creatinine (mmol/L; mean± SD)	101±35	Stent-graft: bifurcated	80%	Stent-graft: Uniliac	20%	Elective EVAR	96%	Emergency EVAR	4%	Aneurysm Size	Not reported
Study Characteristics																						
Age (years; range)	74 years (49-89)																					
Males (%)	88%																					
BMI (kg/m ² ; mean± SD)	29± 4																					
Creatinine (mmol/L; mean± SD)	101±35																					
Stent-graft: bifurcated	80%																					
Stent-graft: Uniliac	20%																					
Elective EVAR	96%																					
Emergency EVAR	4%																					
Aneurysm Size	Not reported																					
Sample Size	178 patients																					
Index test(s)	CDUS The follow-up protocol called for serial CT and CDUS scans at 1 month and every 6 months thereafter. Transverse and anteroposterior (AP) images were obtained from the level of the suprarenal aorta above the graft to the distal iliac or femoral arteries. These studies were reviewed by a board certified vascular surgeon and registered vascular technologist. Neither the registered vascular technologist nor the reviewing surgeon was aware of the CT results during any portion of the CDUS examination. An endoleak was indicated by flow and spectral signals outside the prosthesis.																					
Reference standard(s)	CTA																					

Full citation	AbuRahma Ali F, Welch Christine A, Mullins Bandy B, and Dyer Benjamin (2005) Computed tomography versus color duplex ultrasound for surveillance of abdominal aortic stent-grafts. Journal of endovascular therapy: an official journal of the International Society of Endovascular Specialists 12, 568-73
	Helical CT imaging was performed to acquire non-contrasted and contrasted axial images of the abdominal aorta. All CT scans were reviewed by one vascular surgeon. An endoleak was determined using CT scans based on extravasation of contrast between the prosthesis and the aneurysm wall
Study Details	Study location: East Virginia, USA Study setting: Department of Surgery Study dates: February 2000 and October 2004 Loss to follow-up: Not specified Time between testing & Treatment: 7 days Source of funding: Not specified
Quality Assessment (QUADAS 2)	Patient selection: Unclear risk of bias. Exclusion criteria not specified. Index test: Low risk of bias Reference standard: Low risk of bias Flow and timing: Low risk of bias Overall risk of bias: Low risk of bias Directness: Directly applicable

Full citation	Badri Hassan, El Haddad, Mohammed, Ashour Hamdy, Nice Colin, Timmons Grace, and Bhattacharya Vish (2010) Duplex ultrasound scanning (DUS) versus computed tomography angiography (CTA) in the follow-up after EVAR. Angiology 61, 131-6									
Study type	Cross sectional study (retrospective)									
Aim	Assess the reliability of DUS compared with CTA for surveillance following EVAR.									
Patient Characteristics	Inclusion criteria: Patients undergoing EVAR. Exclusion criteria: Not reported									
	<table border="1"> <thead> <tr> <th colspan="2">Study Characteristics</th> </tr> </thead> <tbody> <tr> <td>Mean Age (range)</td> <td>79 years (56-94 years)</td> </tr> <tr> <td>Males (%)</td> <td>85%</td> </tr> <tr> <td>Aneurysm Size</td> <td>Not reported</td> </tr> </tbody> </table>		Study Characteristics		Mean Age (range)	79 years (56-94 years)	Males (%)	85%	Aneurysm Size	Not reported
Study Characteristics										
Mean Age (range)	79 years (56-94 years)									
Males (%)	85%									
Aneurysm Size	Not reported									
Sample Size	59 patients									
Index test(s)	CDUS Follow-up protocol for patients undergoing EVAR was to perform both CDUS and CTA at 1 month, 3 months, 6 months, 12 months, 18 months, and then yearly thereafter. All patients were scanned with a 2- to 5-MHz transducer. Pulsed Doppler was used to evaluate any colour Doppler signals exterior to the graft. This was to help differentiate between genuine higher velocity endoleak and 'pseudo-endoleak' reflecting the movement of liquefied thrombus within the aneurysm sac. Reporting radiologists and ultrasonographers referred to previous scans to assess significant change in maximum sac diameter. 3 specialist vascular ultrasonographers performed and reported the CDUS.									
Reference standard(s)	CTA All patients underwent dual phase Multi-Detector CT on a Philips MX80000 IDT or GE Prospeed SX. Two consultant interventional radiologists reported the CTA.									
Study Details	Study location: Gateshead, UK Study setting: Department of Vascular Surgery Study dates: April 1998 and December 2007 Loss to follow-up: Not reported Time between testing & Treatment: Paired scans conducted within 2 weeks of each other, and almost all scans took place on the same day Source of funding: Not specified									

Full citation	Badri Hassan, El Haddad, Mohammed, Ashour Hamdy, Nice Colin, Timmons Grace, and Bhattacharya Vish (2010) Duplex ultrasound scanning (DUS) versus computed tomography angiography (CTA) in the follow-up after EVAR. <i>Angiology</i> 61, 131-6
Quality Assessment (QUADAS 2)	Patient selection: Low risk of bias Index test: Unclear risk of bias. Unclear if index test results were interpreted without knowledge of reference standard results. Reference standard: Unclear risk of bias. Unclear if reference standard results were interpreted without knowledge of index test. Flow and timing: Low risk of bias Overall risk of bias: High risk of bias Directness: Directly applicable

Full citation	Bargellini Irene, Cioni Roberto, Napoli Vinicio, Petruzzi Pasquale, Vignali Claudio, Cicorelli Antonio, Sardella Savino, Ferrari Mauro, and Bartolozzi Carlo (2009) Ultrasonographic surveillance with selective CTA after endovascular repair of abdominal aortic aneurysm. Journal of endovascular therapy: an official journal of the International Society of Endovascular Specialists 16, 93-104									
Study type	Cross sectional study									
Aim	Evaluate the agreement between CDUS and CTA in monitoring aneurysm diameter and detecting endoleaks after EVAR.									
Patient Characteristics	<p>Inclusion criteria: Patients who underwent EVAR for elective treatment of infrarenal AAAs with a mean maximum transverse diameter of 52.4±9.7mm.</p> <p>Exclusion criteria: Not specified</p> <table border="1"> <thead> <tr> <th colspan="2">Study Characteristics</th> </tr> </thead> <tbody> <tr> <td>Mean Age (range)</td> <td>72.4 years (52-88)</td> </tr> <tr> <td>Males (%)</td> <td>97%</td> </tr> <tr> <td>Aneurysm Size (±SD)</td> <td>52.4 ± 9.7 mm</td> </tr> </tbody> </table>		Study Characteristics		Mean Age (range)	72.4 years (52-88)	Males (%)	97%	Aneurysm Size (±SD)	52.4 ± 9.7 mm
Study Characteristics										
Mean Age (range)	72.4 years (52-88)									
Males (%)	97%									
Aneurysm Size (±SD)	52.4 ± 9.7 mm									
Sample Size	198 patients									
Index test(s)	<p>CDUS</p> <p>All patients underwent strict clinical and imaging follow-up by CDUS at 1 month and every 6 months. When complications were suspected (such as endoleak, stent-graft migration, or increased AAA diameter), closer surveillance was performed. A single radiologist masked to the CTA findings performed CDUS. A change (≥10%) in the maximum transverse sac diameter at follow up compared to the pre-procedural value was considered significant.</p>									
Reference standard(s)	<p>CTA</p> <p>CTA was performed at 1 and 6 months and annually thereafter. Surveillance CTA included an unenhanced scan, followed by acquisitions in the arterial phase and delayed phases.</p>									
Study Details	<p>Study location: Italy</p> <p>Study setting: Department of Diagnostic and Interventional Radiology</p> <p>Study dates: November 1998 to January 2007</p> <p>Loss to follow-up:</p> <p>5 cases of surgical conversion due to severe kinking of the stent-graft, rupture and stent-graft occlusion</p> <p>2 deaths due to myocardial infarction</p> <p>Aneurysm- related death due to rupture</p>									

Full citation	Bargellini Irene, Cioni Roberto, Napoli Vinicio, Petruzzi Pasquale, Vignali Claudio, Cicorelli Antonio, Sardella Savino, Ferrari Mauro, and Bartolozzi Carlo (2009) Ultrasonographic surveillance with selective CTA after endovascular repair of abdominal aortic aneurysm. Journal of endovascular therapy: an official journal of the International Society of Endovascular Specialists 16, 93-104
	Time between testing & Treatment: CDUS and CTA conducted within 30 days of each other Source of funding: Not reported
Quality Assessment (QUADAS 2)	Patient selection: Low risk of bias Index test: Low risk of bias Reference standard: Unclear risk of bias- unclear blinding between reference standard results and index test results Flow and timing: Low risk of bias Overall risk of bias: Moderate risk of bias Directness: Directly applicable

Full citation	Bendick Phillip J, Bove Paul G, Long Graham W, Zelenock Gerald B, Brown O William, and Shanley Charles J (2003) Efficacy of ultrasound scan contrast agents in the noninvasive follow-up of aortic stent grafts. Journal of vascular surgery 37, 381-5									
Study type	Cross sectional study									
Aim	Evaluate the efficacy of duplex ultrasound scan with the addition of an ultrasound scan contrast agent in documenting endoleaks and compare results with CTA									
Patient Characteristics	<p>Inclusion criteria: Patients who had a percutaneously placed aortoiliac stent graft for infrarenal aortic aneurysmal disease. 10 patients selected because of the technical difficulty of the conventional duplex ultrasound scan from patient body habitus or presence of bowel gas.</p> <p>Exclusion criteria: Not reported</p> <table border="1"> <thead> <tr> <th colspan="2">Study Characteristics</th> </tr> </thead> <tbody> <tr> <td>Mean Age</td> <td>74.5 ±7.6 years</td> </tr> <tr> <td>Males (%)</td> <td>95%</td> </tr> <tr> <td>Aneurysm Size (±SD)</td> <td>5.6 ± 0.9 cm</td> </tr> </tbody> </table>		Study Characteristics		Mean Age	74.5 ±7.6 years	Males (%)	95%	Aneurysm Size (±SD)	5.6 ± 0.9 cm
Study Characteristics										
Mean Age	74.5 ±7.6 years									
Males (%)	95%									
Aneurysm Size (±SD)	5.6 ± 0.9 cm									
Sample Size	20 patients									
Index test(s)	<p>CDUS and CEUS</p> <p>As part of routine postoperative surveillance at 1, 3, 6 and 12 months, a standard aortic duplex ultrasound scan examination, with CDI and spectral Doppler velocity measurements. The operator was blinded to the results of any previous ultrasound scans and of any prior angiographic or CTA studies. After completion of the standard aortic postoperative scanning protocol, a 1-mL bolus of ultrasound scan contrast agent was given. The contrast was allowed to circulate in the blood pool for approximately 1 minute, and then the aortic stent graft and aneurysm sac were again scanned.</p> <p>Any endoleaks that were seen with CDUS were classified as being related to stent graft itself (group I), at either the proximal or distal attachment sites or at any graft module junctions or secondary to patent aortic branch vessels (group II), such as the inferior mesenteric artery or lumbar arteries, which showed collateral filled and back bleeding into the aneurysm sac.</p>									
Reference standard(s)	<p>CTA</p> <p>CTA was conducted after a standard stent graft protocol. All CTA studies were done within a 2 week period of duplex ultrasound scan.</p>									
Study Details	<p>Study location: USA</p> <p>Study setting: Department of Surgery</p> <p>Study dates: January to December 2001</p>									

Full citation	Bendick Phillip J, Bove Paul G, Long Graham W, Zelenock Gerald B, Brown O William, and Shanley Charles J (2003) Efficacy of ultrasound scan contrast agents in the noninvasive follow-up of aortic stent grafts. Journal of vascular surgery 37, 381-5
	Loss to follow-up: Not specified Time between testing & Treatment: within 2 weeks Source of funding: Not specified
Quality Assessment (QUADAS 2)	Patient selection: High risk of bias. Consecutive patients not selected. Index test: Low risk of bias Reference standard: Low risk of bias Flow and timing: Low risk of bias Overall risk of bias: Moderate risk of bias Directness: Directly applicable

Full citation	Cantador Alex Aparecido, Siqueira Daniel Emilio Dalledone, Jacobsen Octavio Barcellos, Baracat Jamal, Pereira Ines Minniti Rodrigues, Menezes Fabio Husemann, and Guillaumon Ana Terezinha (2016) Duplex ultrasound and computed tomography angiography in the follow-up of endovascular abdominal aortic aneurysm repair: a comparative study. Radiologia brasileira 49(4), 229-233																			
Study type	Cross sectional study																			
Aim	Compare duplex ultrasound and CTA in terms of their performance in detecting endoleaks, as well as in determining the diameter of the aneurysm sac, in the post-operative follow-up of EVAR																			
Patient Characteristics	<p>Inclusion criteria: Patients undergoing EVAR</p> <p>Exclusion criteria:</p> <p>Patients allergic to iodinated contrast</p> <p>Patients with creatinine level >2.0 mg/dL</p> <table border="1"> <thead> <tr> <th colspan="2">Study Characteristics</th> </tr> </thead> <tbody> <tr> <td>Age (range)</td> <td>75 years (58-85 years)</td> </tr> <tr> <td>Males (%)</td> <td>83%</td> </tr> <tr> <td>Smoking (%)</td> <td>80%</td> </tr> <tr> <td>Arterial hypertension (%)</td> <td>73%</td> </tr> <tr> <td>Diabetes mellitus (%)</td> <td>30%</td> </tr> <tr> <td>Dyslipidemia (%)</td> <td>23%</td> </tr> <tr> <td>Myocardial infarction (%)</td> <td>16%</td> </tr> <tr> <td>Aneurysm Size (range)</td> <td>6.5 cm (3.5-8.8 cm)</td> </tr> </tbody> </table>		Study Characteristics		Age (range)	75 years (58-85 years)	Males (%)	83%	Smoking (%)	80%	Arterial hypertension (%)	73%	Diabetes mellitus (%)	30%	Dyslipidemia (%)	23%	Myocardial infarction (%)	16%	Aneurysm Size (range)	6.5 cm (3.5-8.8 cm)
Study Characteristics																				
Age (range)	75 years (58-85 years)																			
Males (%)	83%																			
Smoking (%)	80%																			
Arterial hypertension (%)	73%																			
Diabetes mellitus (%)	30%																			
Dyslipidemia (%)	23%																			
Myocardial infarction (%)	16%																			
Aneurysm Size (range)	6.5 cm (3.5-8.8 cm)																			
Sample Size	30 patients																			
Index test(s)	<p>CDUS</p> <p>One ultrasound and one CT angiography per patient, with a maximum interval of two weeks between examinations were evaluated. Endoleaks were initially evaluated through the acquisition of good-quality B-mode ultrasound images, the aneurysm sac and stent being inspected in cross-sectional and longitudinal views. Thereafter, Doppler was used to identify any flow between the stent and aneurysm sac. Endoleaks were evaluated in spectral Doppler, in order to confirm the findings of the colour Doppler ultrasound examinations. One radiologist performed all ultrasounds.</p>																			

Full citation	Cantador Alex Aparecido, Siqueira Daniel Emilio Dalledone, Jacobsen Octavio Barcellos, Baracat Jamal, Pereira Ines Minniti Rodrigues, Menezes Fabio Husemann, and Guillaumon Ana Terezinha (2016) Duplex ultrasound and computed tomography angiography in the follow-up of endovascular abdominal aortic aneurysm repair: a comparative study. Radiologia brasileira 49(4), 229-233
Reference standard(s)	CTA One radiologist performed all CT angiographies. Reports were generated independently, without data sharing between the examiners.
Study Details	Study location: Brazil Study setting: Not specified Study dates: Not specified Loss to follow-up: Not specified Time between testing & Treatment: Maximum of 14 days Source of funding: Not specified
Quality Assessment (QUADAS 2)	Patient selection: Low risk of bias Index test: Low risk of bias Reference standard: Low risk of bias Flow and timing: low risk of bias Overall risk of bias: Low risk of bias Directness: Directly applicable

Full citation	Clevert D A, Minaifar N, Weckbach S, Kopp R, Meimarakis G, Clevert D A, and Reiser M (2008) Color duplex ultrasound and contrast-enhanced ultrasound in comparison to MS-CT in the detection of endoleak following endovascular aneurysm repair. <i>Clinical hemorheology and microcirculation</i> 39, 121-32							
Study type	Cross sectional study							
Aim	Compare colour duplex ultrasound (CDU), contrast enhanced ultrasound (CEUS) and multislice computed tomography (MS-CT) angiography in the routine follow-up of patients following EVAR.							
Patient Characteristics	Inclusion criteria: consecutive patients who had undergone EVAR. Exclusion criteria: Not specified							
	<table border="1"> <tr> <td colspan="2">Study Characteristics</td> </tr> <tr> <td>Mean Age</td> <td>63 years</td> </tr> <tr> <td>Aneurysm Size (\pmSD)</td> <td>Not reported</td> </tr> </table>		Study Characteristics		Mean Age	63 years	Aneurysm Size (\pm SD)	Not reported
Study Characteristics								
Mean Age	63 years							
Aneurysm Size (\pm SD)	Not reported							
Sample Size	43 patients							
Index test(s)	<p>CDUS and CEUS</p> <p>Two experienced sonographers performed ultrasound examinations of the abdominal aorta. An internally standardised duplex scanning protocol was used for assessing the abdominal aorta followed by CUES. In CDUS, the colour gain was selected just as high as it is necessary to avoid overwriting artefacts. The sonographer was not aware of the CT scan results during the examination and reading of CDUS and CEUS examination. Endoleaks were defined as the persistence of blood flow outside the lumen of the endoluminal graft but within an aneurysm sac or adjacent vascular segment being treated by the graft. Type I endoleak were defined as flow into aneurysm sac originating from around a stent graft attachment site. Type II endoleak were defined as retrograde blood flow through aortic branch vessels into the aneurysm sac. Type III endoleak was defined as structural failure within the stent graft such as stent-graft fractures or holes that develop in the fabric of the device.</p>							
Reference standard(s)	<p>CTA</p> <p>The patients were examined using a standard protocol for an arterial and venous phase exam with a 16 or 64 detector CT scanner. CT examinations were performed within 1 day before CEUS. CT examinations were performed and read by experienced radiologists who were blinded to the results of both sonography and contrast-enhanced sonography.</p>							
Study Details	<p>Study location: Munich, Germany</p> <p>Study setting: Department of Clinical Radiology</p> <p>Study dates: September 2006 to December 2006</p> <p>Loss to follow-up: No loss to follow-up</p>							

Full citation	Clevert D A, Minaifar N, Weckbach S, Kopp R, Meimarakis G, Clevert D A, and Reiser M (2008) Color duplex ultrasound and contrast-enhanced ultrasound in comparison to MS-CT in the detection of endoleak following endovascular aneurysm repair. <i>Clinical hemorheology and microcirculation</i> 39, 121-32
	Time between testing & Treatment: CTA examinations conducted within 1 day before CEUS. Source of funding: Not specified
Quality Assessment (QUADAS 2)	Patient selection: Low risk of bias Index test: Low risk of bias Reference standard: Low risk of bias Flow and timing: Low risk of bias Overall risk of bias: Low risk of bias Directness: Directly applicable

Full citation	Clevert D A, Helck A, D'Anastasi M, Gurtler V, Sommer W H, Meimarakis G, Weidenhagen R, and Reiser M (2011) Improving the follow up after EVAR by using ultrasound image fusion of CEUS and MS-CT. Clinical hemorheology and microcirculation 49, 91-104									
Study type	Cross sectional study (retrospective)									
Aim	To evaluate whether the image fusion with CEUS and CT affects the diagnosis of endoleaks in unclear cases.									
Patient Characteristics	<p>Inclusion criteria: Only patients undergoing follow-up after EVAR</p> <p>Exclusion criteria:</p> <p>Patients with heart pacemaker or neurostimulator</p> <p>Patients with acute heart failure, myocardial infarction, known allergy to Sonovue, extensive subcutaneous emphysema</p> <p>Patient non-compliance</p> <table border="1"> <thead> <tr> <th colspan="2">Study Characteristics</th> </tr> </thead> <tbody> <tr> <td>Mean Age</td> <td>73 years</td> </tr> <tr> <td>Males (%)</td> <td>94%</td> </tr> <tr> <td>Aneurysm Size (\pmSD)</td> <td>Not reported</td> </tr> </tbody> </table>		Study Characteristics		Mean Age	73 years	Males (%)	94%	Aneurysm Size (\pm SD)	Not reported
Study Characteristics										
Mean Age	73 years									
Males (%)	94%									
Aneurysm Size (\pm SD)	Not reported									
Sample Size	35 patients									
Index test(s)	<p>CDUS and CEUS</p> <p>Ultrasound examinations were performed by an experienced sonographer and were later read by two blinded unbiased investigators. Both conventional ultrasound including CDUS and CEUS were performed. For CEUS, an intravenous bolus injection of 1.0 ml of a second generation blood pool contrast agent consisting of stabilised microbubbles of sulphur hexafluoride was administered.</p>									
Reference standard(s)	<p>CTA</p> <p>All special ultrasound techniques like CDUS, power-Doppler or CEUS were integrated in the image fusion examination. Standard DICOM data sets of all cross-sectional CT examinations were used for image fusion.</p>									
Study Details	<p>Study location: Germany</p> <p>Study setting: Interdisciplinary Ultrasound Centre</p> <p>Study dates: Not reported</p> <p>Loss to follow-up: No adverse reactions to the ultrasound contrast medium were observed</p> <p>Time between testing & Treatment: Not reported</p> <p>Source of funding: Not reported</p>									

Full citation	Clevert D A, Helck A, D'Anastasi M, Gurtler V, Sommer W H, Meimarakis G, Weidenhagen R, and Reiser M (2011) Improving the follow up after EVAR by using ultrasound image fusion of CEUS and MS-CT. Clinical hemorheology and microcirculation 49, 91-104
Quality Assessment (QUADAS 2)	Patient selection: Low risk of bias Index test: Unclear- definition of endoleak not provided Reference standard: Unclear risk of bias- Inadequate information on reference standard and unclear blinding between reference standard results and index test Flow and timing: Unclear risk of bias- interval between reference standard and index test not reported. Overall risk of bias: High risk of bias Directness: Directly applicable

Full citation	D'Audiffret A, Desgranges P, Kobeiter D H, and Becquemin J P (2001) Follow-up evaluation of endoluminally treated abdominal aortic aneurysms with duplex ultrasonography: validation with computed tomography. Journal of vascular surgery 33, 42-50																											
Study type	Cross sectional study																											
Aim	Compare CDUS and CTA for the follow-up of endoluminally treated aortic aneurysms.																											
Patient Characteristics	Inclusion criteria: Patients who underwent AAA exclusion with commercially available endoprosthesis Exclusion criteria: Patients who did not have a minimum follow-up of 6 months																											
	<table border="1"> <thead> <tr> <th colspan="2">Study Characteristics</th> </tr> </thead> <tbody> <tr> <td>Mean Age</td> <td>70 ± 5</td> </tr> <tr> <td>Males (%)</td> <td>93%</td> </tr> <tr> <td>Ischemic Heart disease</td> <td>56.2%</td> </tr> <tr> <td>Previous myocardial infraction</td> <td>19.2%</td> </tr> <tr> <td>Obesity</td> <td>31.3%</td> </tr> <tr> <td>Smoking</td> <td>49%</td> </tr> <tr> <td>Hypertension</td> <td>59.4%</td> </tr> <tr> <td>Pulmonary disease</td> <td>29%</td> </tr> <tr> <td>Diabetes mellitus</td> <td>9%</td> </tr> <tr> <td>Renal impairment</td> <td>11%</td> </tr> <tr> <td>Hyperlipidemia</td> <td>30.3%</td> </tr> <tr> <td>Aneurysm Size (range)</td> <td>53.2 mm (48-80 mm)</td> </tr> </tbody> </table>		Study Characteristics		Mean Age	70 ± 5	Males (%)	93%	Ischemic Heart disease	56.2%	Previous myocardial infraction	19.2%	Obesity	31.3%	Smoking	49%	Hypertension	59.4%	Pulmonary disease	29%	Diabetes mellitus	9%	Renal impairment	11%	Hyperlipidemia	30.3%	Aneurysm Size (range)	53.2 mm (48-80 mm)
Study Characteristics																												
Mean Age	70 ± 5																											
Males (%)	93%																											
Ischemic Heart disease	56.2%																											
Previous myocardial infraction	19.2%																											
Obesity	31.3%																											
Smoking	49%																											
Hypertension	59.4%																											
Pulmonary disease	29%																											
Diabetes mellitus	9%																											
Renal impairment	11%																											
Hyperlipidemia	30.3%																											
Aneurysm Size (range)	53.2 mm (48-80 mm)																											
Sample Size	89 patients																											
Index test(s)	CDUS CDUS examinations were performed by 1 or 4 physicians. No contrast agent was used. Colour flow sampling within the aneurysm sac, outside the endoprosthesis, was used to detect endoleaks. When flow was detected, a Doppler waveform analysis completed the investigation.																											
Reference standard(s)	CTA																											

Full citation	D'Audiffret A, Desgranges P, Kobeiter D H, and Becquemin J P (2001) Follow-up evaluation of endoluminally treated abdominal aortic aneurysms with duplex ultrasonography: validation with computed tomography. Journal of vascular surgery 33, 42-50
	Helical CTA performed. Endoleaks were defined by the presence of contrast between the graft the arterial wall of the aneurysm. Comparison with non-enhanced CT images enabled the differentiation of small type II endoleak from calcification. All images were reviewed by an experienced radiologist and vascular surgeon.
Study Details	Study location: France Study setting: Department of Vascular surgery Study dates: January 1995 to March 2000 Loss to follow-up: Not specified Time between testing & Treatment: Between a one month interval Source of funding: Not specified
Quality Assessment (QUADAS 2)	Patient selection: Low risk of bias Index test: High risk of bias. Inadequate blinding between index and reference standard Reference standard: High risk of bias. Inadequate blinding between reference standard and index test. Flow and timing: Low risk of bias Overall risk of bias: High risk of bias Directness: Directly applicable

Full citation	Demirpolat Gulgun, Ozturk Nur, Parildar Mustafa, Posacioglu Hakan, and Tamsel Sadik (2011) Duplex ultrasound evaluation of endoluminally treated aortic aneurysms with emphasis on diameter measurement: A comparison with computed tomography. Journal of clinical ultrasound: JCU 39, 263-9									
Study type	Cross sectional study (retrospective)									
Aim	Determine accuracy of CDUS for endoleak detection and measurement of the aneurysm diameter after EVAR.									
Patient Characteristics	Inclusion criteria: Patients treated with endovascular stent grafts for AAA Exclusion criteria: Not specified									
	<table border="1"> <thead> <tr> <th colspan="2">Study Characteristics</th> </tr> </thead> <tbody> <tr> <td>Mean Age (range)</td> <td>72.2 years (47 to 90 years)</td> </tr> <tr> <td>Males (%)</td> <td>89%</td> </tr> <tr> <td>Aneurysm Size (\pmSD)</td> <td>64 \pm18.4 mm</td> </tr> </tbody> </table>		Study Characteristics		Mean Age (range)	72.2 years (47 to 90 years)	Males (%)	89%	Aneurysm Size (\pm SD)	64 \pm 18.4 mm
Study Characteristics										
Mean Age (range)	72.2 years (47 to 90 years)									
Males (%)	89%									
Aneurysm Size (\pm SD)	64 \pm 18.4 mm									
Sample Size	29 patients									
Index test(s)	CDUS CDUS was performed by a radiologist experience in Doppler ultrasonography. Endoleaks were suspected when reproducible, pulsatile colour flow images could be seen outside the graft. If present, spectral analysis of pulsed Doppler signal was performed and the relation of this flow with the graft lumen or with branches of the aorta was evaluated.									
Reference standard(s)	CTA Routine follow-up were performed first, sixth and twelfth months, and yearly thereafter. No pre-contrast or delayed images were obtained.									
Study Details	Study location: Turkey Study setting: Department of Radiology Study dates: September 2007 and May 2009 Loss to follow-up: Not specified Time between testing & Treatment: Same day Source of funding: Not specified.									
Quality Assessment (QUADAS 2)	Patient selection: Low risk of bias Index test: Low risk of bias									

Full citation	Demirpolat Gulgun, Ozturk Nur, Parildar Mustafa, Posacioglu Hakan, and Tamsel Sadik (2011) Duplex ultrasound evaluation of endoluminally treated aortic aneurysms with emphasis on diameter measurement: A comparison with computed tomography. Journal of clinical ultrasound: JCU 39, 263-9
	Reference standard: Low risk of bias Flow and timing: Low risk Overall risk of bias: Low risk of bias Directness: Directly applicable

Full citation	Franca G J, Baroncini L A. V, de Oliveira , A , Vidal E A, Miyamoto M, Toregeani J F, Coelho L O. M, and Timi J R. R (2013) Evaluation with Doppler vascular ultrasound in postoperative endovascular treatment of abdominal aortic aneurysm: A prospective comparative study with angiotomography. Jornal Vascular Brasileiro 12, 102-109	
Study type	Cross sectional	
Aim	Determine validity indices of Doppler vascular ultrasound and to correlate findings with CTA results in postoperative evaluation of patients who had undergone elective endovascular treatment of AAAs.	
Patient Characteristics	Inclusion criteria: Not specified	
	Exclusion criteria: Not specified	
	Study Characteristics	
	Mean Age	73±6.9 years
	Males (%)	90%
	Aneurysm Size (±SD)	54.5 ±12.6 mm
Sample Size	33 patients	
Index test(s)	CDUS Doppler vascular exams were performed by 3 experienced vascular ultrasonographers. Exam interpretation was blinded for test information, even in patients with more than one test pair. Endoleak was defined as the transmission of flow and pressure into the aneurysm sac.	
Reference standard(s)	CTA 3 radiologists performed CTA examinations	
Study Details	Study location: Brazil Study setting: Vascular Ultrasonography units Study dates: not specified Loss to follow-up: Not specified Time between testing & Treatment: interval between two examinations could not exceed 90 days Source of funding: Not specified	
Quality Assessment (QUADAS 2)	Patient selection: Unclear risk of bias. Inclusion and exclusion criteria not specified. Index test: Low risk of bias	

Full citation	Franca G J, Baroncini L A. V, de Oliveira , A , Vidal E A, Miyamoto M, Toregeani J F, Coelho L O. M, and Timi J R. R (2013) Evaluation with Doppler vascular ultrasound in postoperative endovascular treatment of abdominal aortic aneurysm: A prospective comparative study with angiotomography. Jornal Vascular Brasileiro 12, 102-109
	Reference standard: Low risk of bias Flow and timing: High risk of bias. Inadequate interval between index test and reference test. Overall risk of bias: High risk of bias Directness: Directly applicable

Full citation	Gargiulo M, Gallitto E, Serra C, Freyrie A, Mascoli C, Bianchini Massoni, C , De Matteis , M , De Molo , C , and Stella A (2014) Could four-dimensional contrast-enhanced ultrasound replace computed tomography angiography during follow up of fenestrated endografts? Results of a preliminary experience. European journal of vascular and endovascular surgery : the official journal of the European Society for Vascular Surgery 48, 536-42									
Study type	Cross sectional study									
Aim	Evaluate 4D CEUS as an alternative imaging method to CTA during follow-up of fenestrated EVAR for juxta- and para-renal AAA.									
Patient Characteristics	Inclusion criteria: All consecutive patients who underwent FEVAR follow-up for juxta- and para- AAA Exclusion criteria: Not specified									
	<table border="1"> <thead> <tr> <th colspan="2">Study Characteristics</th> </tr> </thead> <tbody> <tr> <td>Mean Age</td> <td>74±7 years</td> </tr> <tr> <td>Males (%)</td> <td>96%</td> </tr> <tr> <td>Aneurysm Size (±SD)</td> <td>55 ± 7 mm</td> </tr> </tbody> </table>		Study Characteristics		Mean Age	74±7 years	Males (%)	96%	Aneurysm Size (±SD)	55 ± 7 mm
Study Characteristics										
Mean Age	74±7 years									
Males (%)	96%									
Aneurysm Size (±SD)	55 ± 7 mm									
Sample Size	22 patients									
Index test(s)	4DCEUS All US examinations, including baseline US, CEUS, and 4D CEUS, were performed with the same machine. A sulphur hexafluoride-filled microbubble contrast agent (SonoVue) was used for contrast examinations. To avoid inter-observer variability, all US scanning was performed by one investigator who was blinded to the CTA. Endoleaks were detected and classified according the White and May classification									
Reference standard(s)	CTA CTA was performed by a radiologist with experience in vascular CTA evaluations. Triple phase CTA was acquired on a 64-slice CT scanner. Endoleaks were detected and classified according to the White and May classification.									
Study Details	Study location: Italy Study setting: Ultrasound Unit Study dates: October 2011 to March 2012 Loss to follow-up: No loss to follow-up Time between testing & Treatment: ≤30 days Source of funding: Not specified									

Full citation	Gargiulo M, Gallitto E, Serra C, Freyrie A, Mascoli C, Bianchini Massoni, C , De Matteis , M , De Molo , C , and Stella A (2014) Could four-dimensional contrast-enhanced ultrasound replace computed tomography angiography during follow up of fenestrated endografts? Results of a preliminary experience. European journal of vascular and endovascular surgery : the official journal of the European Society for Vascular Surgery 48, 536-42
Quality Assessment (QUADAS 2)	Patient selection: Low risk of bias Index test: Low risk of bias Reference standard: Unclear risk of bias- unclear blinding between reference standard and index test Flow and timing: Low risk of bias Overall risk of bias: Moderate risk of bias Directness: Directly applicable

Full citation	Giannoni Maria Fabrizia, Fanelli Fabrizio, Citone Michele, Cristina Acconcia, Maria , Speziale Francesco, and Gossetti Bruno (2007) Contrast ultrasound imaging: the best method to detect type II endoleak during endovascular aneurysm repair follow-up. Interactive cardiovascular and thoracic surgery 6, 359-62						
Study type	Cross sectional study						
Aim	Evaluate if ultrasound investigation with Cadence Contrast Pulse Sequencing technique and Sonovue is a possible alternative method to CTA in detecting endoleaks.						
Patient Characteristics	Inclusion criteria: Consecutive patients with endovascular grafts for infrarenal aortic aneurysms.						
	Exclusion criteria: Not specified						
	<table border="1"> <tr> <td colspan="2">Study Characteristics</td> </tr> <tr> <td>Mean Age</td> <td>74.4±5.4 years</td> </tr> <tr> <td>Aneurysm Size (±SD)</td> <td>Not reported</td> </tr> </table>		Study Characteristics		Mean Age	74.4±5.4 years	Aneurysm Size (±SD)
Study Characteristics							
Mean Age	74.4±5.4 years						
Aneurysm Size (±SD)	Not reported						
Sample Size	30 patients						
Index test(s)	<p>CEUS</p> <p>Ultrasound investigation (Sequoia Acuson Siemens) was performed with convex probe, equipped for Cadence CPS software. The echo-contrast solution was injected in bolus. The US examination were performed by vascular doctors, blinded to the results of CTA. Particular attention was reserved in order to detect type II endoleak, defined as persisting flow from patent lumbar or mesenteric arteries within aneurysm sac and outside the endograft.</p>						
Reference standard(s)	<p>CTA</p> <p>CTA was performed with delayed triphasic sequences (Siemens Somatom Sensation Cardia 64).</p>						
Study Details	<p>Study location: Rome, Italy</p> <p>Study setting: Division of Vascular Surgery</p> <p>Study dates: Not specified</p> <p>Loss to follow-up: One patient dropped out because a stroke occurred in the time interval between the two investigations</p> <p>Time between testing & Treatment: No more than 15 days between the two examinations.</p> <p>Source of funding: Not specified</p>						
Quality Assessment (QUADAS 2)	<p>Patient selection: Low risk of bias</p> <p>Index test: Low risk of bias</p>						

Full citation	Giannoni Maria Fabrizia, Fanelli Fabrizio, Citone Michele, Cristina Acconcia, Maria , Speziale Francesco, and Gossetti Bruno (2007) Contrast ultrasound imaging: the best method to detect type II endoleak during endovascular aneurysm repair follow-up. Interactive cardiovascular and thoracic surgery 6, 359-62
	Reference standard: Unclear risk of bias- unclear if reference standard results were interpreted without knowledge of index test results Flow and timing: Low risk of bias Overall risk of bias: Moderate risk of bias Directness: Directly applicable

Full citation	Gilabert Rosa, Bunesch Laura, Real Maria Isabel, Garcia-Criado Angeles, Burrel Marta, Ayuso Juan Ramon, Barrufet Marta, Montana Xavier, and Riambau Vicenc (2012) Evaluation of abdominal aortic aneurysm after endovascular repair: prospective validation of contrast-enhanced US with a second-generation US contrast agent. Radiology 264, 269-77									
Study type	Cross sectional study									
Aim	Assess the accuracy of contrast agent enhanced ultrasonography with a second generation US contrast agent in the detection and classification of endoleaks after EVAR.									
Patient Characteristics	<p>Inclusion criteria: Patients undergoing EVAR at institution</p> <p>Exclusion criteria:</p> <p>Patients with inadequate renal function (calculated creatinine clearance <30 mL/<50mL/min in patients with diabetes)</p> <p>Patients with contraindications to US contrast agent administration, such as heart failure, a right-to-left shunt, severe chronic bronchopulmonary disorder, severe pulmonary hypertension, or uncontrolled hypertension.</p> <table border="1" data-bbox="450 699 1697 858"> <thead> <tr> <th colspan="2">Study Characteristics</th> </tr> </thead> <tbody> <tr> <td>Mean Age (range)</td> <td>71.6 years (51-83 years)</td> </tr> <tr> <td>Males (%)</td> <td>97%</td> </tr> <tr> <td>Aneurysm Size (\pmSD)</td> <td>Not reported</td> </tr> </tbody> </table>		Study Characteristics		Mean Age (range)	71.6 years (51-83 years)	Males (%)	97%	Aneurysm Size (\pm SD)	Not reported
Study Characteristics										
Mean Age (range)	71.6 years (51-83 years)									
Males (%)	97%									
Aneurysm Size (\pm SD)	Not reported									
Sample Size	35 patients									
Index test(s)	<p>CEUS</p> <p>All US studies were performed by two radiologists. CDUS was performed prior to CEUS. The CEUS study was performed after injection of 2.4 mL of sulphur hexafluoride (SonoVue) followed by a 5 mL saline bolus flush. Endoleaks were diagnosed when the observation consisted of a hyperchogenic flowing region (localised or diffuse) that was absent on the baseline unenhanced images obtained outside the endograft lumen but within the aneurysm sac.</p>									
Reference standard(s)	<p>CTA</p> <p>CTA images were obtained either with a helical CT scanner or multi-detector CT scanner. Triple-phase image acquisitions were performed that included abdominal aorta from the celiac trunk to the external iliac arteries 2-4 cm below the endoprotheses or the common femoral arteries. CTAS were analysed by two radiologists who were not involved in CDUS or CEUS image acquisitions and analysis and who had knowledge of previous CT angiographic findings. Endoleaks were diagnosed when the observation consisted of an increase in the attenuation coefficient at CTA</p>									
Study Details	Study location: Spain									

Full citation	Gilabert Rosa, Bunesch Laura, Real Maria Isabel, Garcia-Criado Angeles, Burrel Marta, Ayuso Juan Ramon, Barrufet Marta, Montana Xavier, and Riambau Vicenc (2012) Evaluation of abdominal aortic aneurysm after endovascular repair: prospective validation of contrast-enhanced US with a second-generation US contrast agent. Radiology 264, 269-77					
	<p>Study setting: Diagnostic imaging centre</p> <p>Study dates: January 2004 and December 2006</p> <p>Loss to follow-up: Not reported</p> <p>Time between testing & Treatment: 52 CTA and CEUS studies performed on the same day, 31 CEUS studies performed before CTA (mean, 10.77 days \pm8.32) and 43 CEUS studies were performed after CTA (mean, 8.6 days \pm4.7)</p> <p>Source of funding: Not reported</p>					
Quality Assessment (QUADAS 2)	<p>Patient selection: Low risk of bias</p> <p>Index test: Low risk of bias</p> <p>Reference standard: Low risk of bias</p> <p>Flow and timing: Low risk of bias</p> <p>Overall risk of bias: Low risk of bias</p> <p>Directness: Directly applicable</p>					
Full citation	Golzarian Jafar, Murgo Salvatore, Dussaussois Luc, Guyot Sophie, Said Kamel Ait, Wautrecht Jean Claude, and Struyven Julien (2002) Evaluation of abdominal aortic aneurysm after endoluminal treatment: comparison of color Doppler sonography with biphasic helical CT. AJR. American journal of roentgenology 178, 623-8					
Study type	Cross sectional study					
Aim	Compare colour Doppler sonography with biphasic helical CT in the evaluation of abdominal aneurysms after endovascular repair.					
Patient Characteristics	<p>Inclusion criteria: Patients who underwent transfemoral insertion of stent-grafts for abdominal aortic aneurysm</p> <p>Exclusion criteria: Only the examinations obtained within 7 days after implantation were compared.</p> <table border="1" data-bbox="448 1209 1697 1289"> <tr> <td colspan="2">Study Characteristics</td> </tr> <tr> <td>Mean Age (range)</td> <td>73 years (61-87 years)</td> </tr> </table>		Study Characteristics		Mean Age (range)	73 years (61-87 years)
Study Characteristics						
Mean Age (range)	73 years (61-87 years)					

Full citation	Golzarian Jafar, Murgo Salvatore, Dussaussois Luc, Guyot Sophie, Said Kamel Ait, Wautrecht Jean Claude, and Struyven Julien (2002) Evaluation of abdominal aortic aneurysm after endoluminal treatment: comparison of color Doppler sonography with biphasic helical CT. AJR. American journal of roentgenology 178, 623-8	
	Males (%)	93%
	Aneurysm Size (range)	5.1-7.8 cm
Sample Size	55 patients	
Index test(s)	<p>CDUS</p> <p>All patients prospectively underwent CDUS and biphasic CTA within 7 days after stent-graft implantation. CDUS and CTA were used as follow-up modalities in patients at 3, 6 and 12 months and every 6 months thereafter. CDUS was performed by 2 experienced operators (one angiologist and one radiologist). Each patient was evaluated by one physician. Patients were studied in the supine and lateral positions after an overnight fast. The aorta was first scanned transversally from the top of the stent-graft to the femoral arteries, and the maximal transversal diameter was measured. A leak was considered present when a signal associated with a spectral Doppler signal was observed outside the aorta. In case of a perigraft leak, an attempt was made to identify the origin and the direction of the flow. Operators were unaware of the helical CT results.</p>	
Reference standard(s)	<p>CTA</p> <p>All helical CT examinations were performed by 2 experience radiologists. A leak was considered present if contrast material was noted outside the stent-graft in either acquisition. All images were reviewed on radiologists and a workstation in conference with 2 radiologists who were unaware of the colour Doppler sonographic results.</p>	
Study Details	<p>Study location: Brussels, Belgium</p> <p>Study setting: Department of Radiology</p> <p>Study dates: April 1996 to April 1997</p> <p>Loss to follow-up: No loss to follow up</p> <p>Time between testing & Treatment: The maximum time interval between helical CT and CDUS was 48 hours, however, 33 patients had both examinations on the same day.</p> <p>Source of funding: Not specified</p>	
Quality Assessment (QUADAS 2)	<p>Patient selection: Low risk of bias</p> <p>Index test: Low risk of bias</p> <p>Reference standard: Low risk of bias</p> <p>Flow and timing: Low risk of bias</p>	

Full citation	Golzarian Jafar, Murgo Salvatore, Dussaussois Luc, Guyot Sophie, Said Kamel Ait, Wautrecht Jean Claude, and Struyven Julien (2002) Evaluation of abdominal aortic aneurysm after endoluminal treatment: comparison of color Doppler sonography with biphasic helical CT. AJR. American journal of roentgenology 178, 623-8
	Overall risk of bias: Low risk of bias Directness: Partially indirect. Although the protocol specifies that studies published after 2000 should be included, the committee were interested in studies in which patients received scans before this cut-off. As this study was conducted between 1996 and 1997, the study was downgraded for partial indirectness.

Full citation	Gray C, Goodman P, Herron C C, Lawler L P, O'Malley M K, O'Donohoe M K, and McDonnell C O (2012) Use of colour duplex ultrasound as a first line surveillance tool following EVAR is associated with a reduction in cost without compromising accuracy. European Journal of Vascular and Endovascular Surgery 44, 145-150									
Study type	Cross sectional study (retrospective)									
Aim	Evaluate the cost saving obtained if CDUS was employed as a first line surveillance tool following EVAR, as well as comparing the two entities in terms of efficacy.									
Patient Characteristics	Inclusion criteria: All patients who underwent EVAR at the Mater Hospital from 1st June 2003 to 1st July 2010 Exclusion criteria: Not specified									
	<table border="1"> <thead> <tr> <th colspan="2">Study Characteristics</th> </tr> </thead> <tbody> <tr> <td>Age</td> <td>77.1 ±7.9 years</td> </tr> <tr> <td>Male (%)</td> <td>84.1 %</td> </tr> <tr> <td>Aneurysm Size (±SD)</td> <td>Not reported</td> </tr> </tbody> </table>		Study Characteristics		Age	77.1 ±7.9 years	Male (%)	84.1 %	Aneurysm Size (±SD)	Not reported
Study Characteristics										
Age	77.1 ±7.9 years									
Male (%)	84.1 %									
Aneurysm Size (±SD)	Not reported									
Sample Size	145									
Index test(s)	<p>CDUS</p> <p>Following graft implantation all patients underwent regular post-operative surveillance, including CDUS and CT scans of the aorta within 7 days of surgery. After discharge, all patients underwent a CDUS scan and abdominal x ray at 1 month, a CDUS and CT scan at 6 months, 12 months, and annually thereafter provided. All scans were performed by the same accredited vascular technologist, blinded to CT results. Any examination that did not achieve complete visualisation of the entire aneurysm sac was considered limited. Contrast was not used in any patient. The stent and residual aneurysm sac were assessed using colour flow and spectral Doppler to rule out the presence of an endoleak. This required the use of very sensitive colour flow scale settings to determine the presence of low velocity leaks which may have been present within the residual aneurysm sac. Proximal and distal sealing zones were assessed to ensure that there was no evidence of high jet flow indicating type I endoleak or low velocity flow within the old aneurysm sac demonstrating forward and reversed flow indicating the presence of Type II endoleak.</p>									
Reference standard(s)	<p>CTA</p> <p>All CT scans were carried out on a Siemens Somatom Definition AS 128 slice scanner. Under the follow-up protocol following EVAR, patients underwent 3 CTs in the initial year post graft implantation (post-surgery, at 6 months and 1 year) and annually thereafter, provided there has been no documented endoleak or residual sac increase on either CDUS or CT.</p>									
Study Details	<p>Study location: Dublin, Ireland</p> <p>Study setting: Department of Vascular Radiology, Mater Misericordiae University Hospital</p>									

Full citation	Gray C, Goodman P, Herron C C, Lawler L P, O'Malley M K, O'Donohoe M K, and McDonnell C O (2012) Use of colour duplex ultrasound as a first line surveillance tool following EVAR is associated with a reduction in cost without compromising accuracy. European Journal of Vascular and Endovascular Surgery 44, 145-150
	Study dates: June 2003 to July 2010 Loss to follow-up: Patients who missed scheduled appointments were contacted directly by phone and asked to re-attend Time between testing & Treatment: Unclear. However scans performed greater than 90 days apart were excluded. Source of funding: Not specified
Quality Assessment (QUADAS 2)	Patient selection: Low risk of bias Index test: Low risk of bias Reference standard: Unclear risk of bias- unclear blinding between reference and index test Flow and timing: Unclear risk of bias – interval between index test and reference standard not specified Overall risk of bias: High risk of bias Directness: Direct

Full citation	Gurtler Verena M, Sommer Wieland H, Meimarakis Georgios, Kopp Reinhard, Weidenhagen Rolf, Reiser Maximilian F, and Clevert Dirk-Andre (2013) A comparison between contrast-enhanced ultrasound imaging and multislice computed tomography in detecting and classifying endoleaks in the follow-up after endovascular aneurysm repair. Journal of vascular surgery 58, 340-5									
Study type	Cross-sectional study (retrospective)									
Aim	Compare contrast-enhanced ultrasound imaging and multislice computed tomography (MS-CT) angiography in detecting and classifying endoleaks in the follow-up of patients after EVAR.									
Patient Characteristics	<p>Inclusion criteria: Only patients undergoing follow-up after EVAR who had received at least one CEUS examination after the stent implantation Examinations that were performed on the same day or ≤ 30 days.</p> <p>Exclusion criteria: Patients with an abdominal tube stent Patients with acute heart failure and acute myocardial infarction Allergy to contrast agent Patient noncompliance</p> <table border="1"> <thead> <tr> <th colspan="2">Study Characteristics</th> </tr> </thead> <tbody> <tr> <td>Age</td> <td>70.4 \pm 8.6 years</td> </tr> <tr> <td>Males (%)</td> <td>84.4 (%)</td> </tr> <tr> <td>Aneurysm Size (\pmSD)</td> <td>Not reported</td> </tr> </tbody> </table>		Study Characteristics		Age	70.4 \pm 8.6 years	Males (%)	84.4 (%)	Aneurysm Size (\pm SD)	Not reported
Study Characteristics										
Age	70.4 \pm 8.6 years									
Males (%)	84.4 (%)									
Aneurysm Size (\pm SD)	Not reported									
Sample Size	171 patients									
Index test(s)	<p>CEUS An experienced sonographer performed the US examinations in the follow-up after EVAR. An internally standardised scanning protocol was used in assessing the abdominal aneurysm. The protocol included transverse and sagittal imaging. An endoleak was defined as an extravasation of contrast between the aneurysm well and the prosthesis. CEUS and MS-CT images were assessed by consensus reading by 2 experienced radiologists. Radiologists reading one test did not have access to the results of the other test. CEUS findings were considered true positive if the MS-CT revealed evidence of an endoleak, if the findings were not confirmed in MS-CT, they were considered false positive.</p>									

Full citation	Gurtler Verena M, Sommer Wieland H, Meimarakis Georgios, Kopp Reinhard, Weidenhagen Rolf, Reiser Maximilian F, and Clevert Dirk-Andre (2013) A comparison between contrast-enhanced ultrasound imaging and multislice computed tomography in detecting and classifying endoleaks in the follow-up after endovascular aneurysm repair. Journal of vascular surgery 58, 340-5
Reference standard(s)	CTA Patients were examined using a standard protocol for an arterial and a venous phase examination with a Somaton Sensation 16-,64-, or 128-slice detector MS-CT scanner. Because of the retrospective nature of the study, the image resolution was performed with the latest state-of-the-art equipment available at that time. All images were stored in the picture archiving and communications system and were examined by two experienced radiologists in a consensus reading.
Study Details	Study location: Munich, Germany Study setting: Department for Clinical Radiology and Department of Surgery Study dates: February 2006 to February 2011 Loss to follow-up: All examinations were performed successfully and without complication or adverse effects Time between testing & Treatment: Same day or ≤ 30 days Source of funding: Not specified
Quality Assessment (QUADAS 2)	Patient selection: Low risk of bias Index test: Low risk of bias Reference standard: Low risk of bias Flow and timing: Low risk of bias Overall risk of bias: Low risk of bias Directness: Directly applicable

Full citation	Henao Esteban A, Hodge Megan D, Felkai Deborah D, McCollum Charles H, Noon George P, Lin Peter H, Lumsden Alan B, and Bush Ruth L (2006) Contrast-enhanced Duplex surveillance after endovascular abdominal aortic aneurysm repair: improved efficacy using a continuous infusion technique. Journal of vascular surgery 43, 259-264							
Study type	Cross sectional study							
Aim	Prospectively evaluate the use of continuous infusion method of ultrasound contrast in the surveillance of abdominal aortic endografts in detecting endoleaks compared with CT.							
Patient Characteristics	<p>Inclusion criteria: All men and postmenopausal women seen at follow-up intervals were asked to participate</p> <p>Exclusion criteria:</p> <p>Patients with a known endoleak from previous examinations</p> <p>Severe iodinated contrast allergy</p> <p>Evidence of renal insufficiency marked by a serum creatinine level >1.5 mg/dL</p> <p>Evidence of a right-to-left cardiac shunt or severe pulmonary or hepatic disease</p> <table border="1" data-bbox="450 703 1695 823"> <tr> <td colspan="2">Study Characteristics</td> </tr> <tr> <td>Mean Age</td> <td>70.4 years</td> </tr> <tr> <td>Aneurysm Size</td> <td>5.27 cm</td> </tr> </table>		Study Characteristics		Mean Age	70.4 years	Aneurysm Size	5.27 cm
Study Characteristics								
Mean Age	70.4 years							
Aneurysm Size	5.27 cm							
Sample Size	20 patients							
Index test(s)	<p>CDUS and CEUS</p> <p>Patient were typically followed after a successful endovascular aneurysm repair at 1,6,12 and 24 months, and annually thereafter. Endoleaks were defined as the presence of persistent intrasac flow outside the stent-raft. The endoleaks were characterised in relation to the endograft, aneurysm wall, and aortic side branches, and recorded in accordance to the White-May classification.</p> <p>Four experienced vascular sonographers performed all the ultrasound studies using a 3.5-MHz probe on a Philips lu22 UNIT. Ultrasonographers were blinded to the results of pervious angiographic or CT angiographic results. Measurements of the aneurysm were recorded, and grey scale, colour Duplex, and CEUS were used to identify leaks.</p>							
Reference standard(s)	<p>CTA</p> <p>CTA were performed on the same day, before CEUS. The protocol called for the intravenous injection of 150 mL of a contrast agent at a rate of 2.5 mL/s.</p>							
Study Details	<p>Study location: USA</p> <p>Study setting: Unclear</p>							

Full citation	Henao Esteban A, Hodge Megan D, Felkai Deborah D, McCollum Charles H, Noon George P, Lin Peter H, Lumsden Alan B, and Bush Ruth L (2006) Contrast-enhanced Duplex surveillance after endovascular abdominal aortic aneurysm repair: improved efficacy using a continuous infusion technique. Journal of vascular surgery 43, 259-264
	<p>Study dates: July 2004 to May 2005</p> <p>Loss to follow-up: None reported</p> <p>Time between testing & Treatment: Both tests performed on the same day</p> <p>Source of funding: Not specified</p>
Quality Assessment (QUADAS 2)	<p>Patient selection: Low risk of bias</p> <p>Index test: Low risk of bias</p> <p>Reference standard: Low risk of bias</p> <p>Flow and timing: Low risk of bias</p> <p>Overall risk of bias: Low risk of bias</p> <p>Directness: Directly applicable</p>
Full citation	Iezzi Roberto, Basilico Raffaella, Giancristofaro Daniela, Pascali Danilo, Cotroneo Antonio Raffaele, and Storto Maria Luigia (2009) Contrast-enhanced ultrasound versus color duplex ultrasound imaging in the follow-up of patients after endovascular abdominal aortic aneurysm repair. Journal of vascular surgery 49, 552-60
Study type	Cross sectional study
Aim	Assess the negative predictive value, sensitivity, specificity, and diagnostic accuracy of real-time contrast enhanced ultrasound (CEUS) in the detection of endoleaks in patients with AAA who underwent EVAR compared with unenhanced ultrasound imaging.
Patient Characteristics	<p>Inclusion criteria:</p> <p>All patients treated with EVAR who underwent CTA as part of a routine surveillance program at 1, 6, and 12 months after the procedure and annually thereafter.</p> <p>To avoid selection bias in favour of patients who were 'easy to scan' patients were recruited before undergoing a baseline US scan. No patient was excluded on the basis of poor technical quality of the baseline US study.</p> <p>Exclusion criteria:</p>

Full citation	Iezzi Roberto, Basilico Raffaella, Giancristofaro Daniela, Pascali Danilo, Cotroneo Antonio Raffaele, and Storto Maria Luigia (2009) Contrast-enhanced ultrasound versus color duplex ultrasound imaging in the follow-up of patients after endovascular abdominal aortic aneurysm repair. Journal of vascular surgery 49, 552-60									
	Patients with unstable general conditions such as heart failure, severe chronic bronchopulmonary disorders, severe pulmonary hypertension, or uncontrolled hypertension									
	<table border="1"> <thead> <tr> <th colspan="2">Study Characteristics</th> </tr> </thead> <tbody> <tr> <td>Mean Age</td> <td>79.6 ±5.2 years</td> </tr> <tr> <td>Males (%)</td> <td>82.1%</td> </tr> <tr> <td>Aneurysm Size</td> <td>Not reported</td> </tr> </tbody> </table>		Study Characteristics		Mean Age	79.6 ±5.2 years	Males (%)	82.1%	Aneurysm Size	Not reported
Study Characteristics										
Mean Age	79.6 ±5.2 years									
Males (%)	82.1%									
Aneurysm Size	Not reported									
Sample Size	84 patients									
Index test(s)	<p>CDUS and CEUS</p> <p>Patients underwent CTA, CDUS and CEUS on the same day. The precontrast and postcontrast US scans were performed by a single radiologist who blinded to all other imaging findings at the time of examinations. All US scans were performed with a Philips HDI 5000 scanner. CEUS was performed after administration of a second-generation contrast agent (SnoVue). Cine loop sweeps from the US examinations were randomly reviewed independently by two radiologists not involved in the imaging, and neither were aware of the CTA outcomes or dose of contrast used for CEUS. The tapes were viewed at an interval of at least 1 week to reduce their memory of previous images. The readers were blinded to image session sequence; furthermore, names, ages, and identifications were hidden during the review. During the reading session that included the baseline unenhanced US images, the presence of endoleak was considered probable if a colour duplex signal was present beyond the graft. During the reading session of CEUS imaging, the presence of endoleak was considered probable or certain if high attenuation area, absent on the baseline unenhanced-phase images, due to the presence of contrast enhancement, was present beyond the graft but within the aneurysm sac.</p>									
Reference standard(s)	<p>CTA</p> <p>Triple-phase acquisition (unenhanced and contrast enhanced transverse imaging, in arterial and delayed phases) was performed using a multidetector row helical scanner at each follow-up CT study. CT acquisition assessed in consensus by two experienced vascular radiologists not involved in US image analysis, who knew previous CT findings. They were asked to classify a detected leak according to its aetiology as described by White et al.</p>									
Study Details	<p>Study location: Italy</p> <p>Study setting: Department of Radiology</p> <p>Study dates: Not reported</p> <p>Loss to follow-up: All patients completed the protocol, and no adverse events were recorded during CEUS or CT examinations</p>									

Full citation	lezzi Roberto, Basilico Raffaella, Giancristofaro Daniela, Pascali Danilo, Cotroneo Antonio Raffaele, and Storto Maria Luigia (2009) Contrast-enhanced ultrasound versus color duplex ultrasound imaging in the follow-up of patients after endovascular abdominal aortic aneurysm repair. Journal of vascular surgery 49, 552-60
	Time between testing & Treatment: All tests conducted on the same day Source of funding: Not reported
Quality Assessment (QUADAS 2)	Patient selection: Low risk of bias Index test: Low risk of bias Reference standard: Low risk of bias Flow and timing: Low risk of bias Overall risk of bias: Low risk of bias Directness: Directly applicable

Full citation	Kamal D M, Steinmetz O K, and Obrand D I (2008) The value of duplex ultrasound versus contrast enhanced CT scan in the follow-up of endoluminally repaired abdominal aortic aneurysm: A blinded comparison. Bahrain Medical Bulletin 30, 101-107																													
Study type	Cross sectional (retrospective)																													
Aim	To compare the accuracy of Duplex ultrasound to contrast- enhanced CT scan with respect to aneurysm sac diameter measurement and endoleak detection in patients with EVAR.																													
Patient Characteristics	<p>Inclusion criteria: Patients evaluated by contrast enhanced computed tomography scan and duplex ultrasound examinations in their postoperative follow-up.</p> <p>Exclusion criteria:</p> <p>Patients who were followed-up elsewhere</p> <p>Patients who were followed-up by CT scan only (no Duplex performed)</p> <p>If the concurrent (paired) study was done more than one month apart</p> <p>If the CT scan was done without contrast, it was excluded from endoleak detection comparison.</p> <table border="1"> <thead> <tr> <th colspan="2">Study Characteristics</th> </tr> </thead> <tbody> <tr> <td>Mean Age</td> <td>76.6 ±7.6 years</td> </tr> <tr> <td>Males (%)</td> <td>88.2%</td> </tr> <tr> <td>Obesity (%)</td> <td>17.6%</td> </tr> <tr> <td>Coronary Artery Disease (%)</td> <td>64.7%</td> </tr> <tr> <td>Congestive Heart Failure (%)</td> <td>7.8%</td> </tr> <tr> <td>Hypertension (%)</td> <td>58.8%</td> </tr> <tr> <td>Diabetes Mellitus (%)</td> <td>7.8%</td> </tr> <tr> <td>Chronic Obstructive Pulmonary Disease (%)</td> <td>27.5%</td> </tr> <tr> <td>Dyslipidemia (%)</td> <td>25.5%</td> </tr> <tr> <td>Remote Cerebro-vascular accident (%)</td> <td>15.7%</td> </tr> <tr> <td>Cigarette smoking (%)</td> <td>33.3%</td> </tr> <tr> <td>Chronic Renal Failure</td> <td>7.8%</td> </tr> <tr> <td>Aneurysm Size (±SD)</td> <td>Not reported</td> </tr> </tbody> </table>		Study Characteristics		Mean Age	76.6 ±7.6 years	Males (%)	88.2%	Obesity (%)	17.6%	Coronary Artery Disease (%)	64.7%	Congestive Heart Failure (%)	7.8%	Hypertension (%)	58.8%	Diabetes Mellitus (%)	7.8%	Chronic Obstructive Pulmonary Disease (%)	27.5%	Dyslipidemia (%)	25.5%	Remote Cerebro-vascular accident (%)	15.7%	Cigarette smoking (%)	33.3%	Chronic Renal Failure	7.8%	Aneurysm Size (±SD)	Not reported
Study Characteristics																														
Mean Age	76.6 ±7.6 years																													
Males (%)	88.2%																													
Obesity (%)	17.6%																													
Coronary Artery Disease (%)	64.7%																													
Congestive Heart Failure (%)	7.8%																													
Hypertension (%)	58.8%																													
Diabetes Mellitus (%)	7.8%																													
Chronic Obstructive Pulmonary Disease (%)	27.5%																													
Dyslipidemia (%)	25.5%																													
Remote Cerebro-vascular accident (%)	15.7%																													
Cigarette smoking (%)	33.3%																													
Chronic Renal Failure	7.8%																													
Aneurysm Size (±SD)	Not reported																													

Full citation	Kamal D M, Steinmetz O K, and Obrand D I (2008) The value of duplex ultrasound versus contrast enhanced CT scan in the follow-up of endoluminally repaired abdominal aortic aneurysm: A blinded comparison. Bahrain Medical Bulletin 30, 101-107
Sample Size	63 patients
Index test(s)	CDUS A colour Doppler (Duplex) was used for detection of endoleaks, characterised by detection of a colour and spectral signal outside the limits of the prosthesis.
Reference standard(s)	CTA There was a slight difference in the CT scan and ultrasound protocol in the two hospitals. At one hospital, the contrast enhanced CT was performed using a Picker CT, Twin Flash Spiral Helical Unit. At second hospital, CT scan was performed using a Siemens Plus4 machine. An endoleak was defined as persistent blow flow between the tenet graft and the wall of the aneurysm. Radiologist performing the CT was blinded to the ultrasound results and vice versa.
Study Details	Study location: Bahrain Study setting: Two McGill University Teaching Hospitals Study dates: February 1998 and December 2000 Loss to follow-up: Not reported Time between testing & Treatment: CT and CDUS conducted within a 1 month period Source of funding: Not specified.
Quality Assessment (QUADAS 2)	Patient selection: Low risk of bias Index test: Low risk of bias Reference standard: Low risk of bias Flow and timing: High risk of bias- Two hospitals followed different protocols for CT scan Overall risk of bias: Moderate risk of bias Directness: Directly applicable

Full citation	Lowe Christopher, Abbas Abeera, Rogers Steven, Smith Lee, Ghosh Jonathan, and McCollum Charles (2017) Three-dimensional contrast-enhanced ultrasound improves endoleak detection and classification after endovascular aneurysm repair. Journal of vascular surgery 65(5), 1453-1459									
Study type	Cross sectional study									
Aim	Comparing standard CEUS, 3D-CEUS and CTA for the detection and classification of endoleaks in EVAR surveillance.									
Patient Characteristics	Inclusion criteria: Consecutive patients undergoing CTA for EVAR surveillance Exclusion criteria: Studies with poor image quality due to bowel gas or obesity									
	<table border="1"> <thead> <tr> <th colspan="2">Study Characteristics</th> </tr> </thead> <tbody> <tr> <td>Mean Age</td> <td>76 years</td> </tr> <tr> <td>Males (%)</td> <td>86%</td> </tr> <tr> <td>Aneurysm Size (\pmSD)</td> <td>Not reported</td> </tr> </tbody> </table>		Study Characteristics		Mean Age	76 years	Males (%)	86%	Aneurysm Size (\pm SD)	Not reported
Study Characteristics										
Mean Age	76 years									
Males (%)	86%									
Aneurysm Size (\pm SD)	Not reported									
Sample Size	100 patients									
Index test(s)	CEUS and 3D CEUS Standard CEUS and 3D-CEUS images were acquired by the same vascular scientist for all patients in the study and reported independently by 2 vascular scientists blinded to each other and CTA result. Standard CEUS was performed using the same Philips iU22 duplex ultrasound machine. A 1-mL of SonoVue contrast agent was given. 3D CEUS system used was a prototype magnetically tracked freehand system attached to the same Philip iU22 ultrasound unit.									
Reference standard(s)	CTA CTA was reported by the consultant vascular interventional radiologists.									
Study Details	Study location: Manchester, UK Study setting: Not specified Study dates: May 2012 and March 2015 Loss to follow-up: 57 patients lost due to patient compliance Patients lost due to instrument failure Time between testing & Treatment: CTA and ultrasound imaging were conducted on the same day in 52 studies and never more than 4 weeks apart in other studies									

Full citation	Lowe Christopher, Abbas Abeera, Rogers Steven, Smith Lee, Ghosh Jonathan, and McCollum Charles (2017) Three-dimensional contrast-enhanced ultrasound improves endoleak detection and classification after endovascular aneurysm repair. Journal of vascular surgery 65(5), 1453-1459
	Source of funding: Not specified
Quality Assessment (QUADAS 2)	Patient selection: Low risk of bias Index test: Unclear risk of bias. Definition of endoleak not provided Reference standard: Low risk of bias Flow and timing: Low risk of bias Overall risk of bias: Moderate risk of bias Directness: Directly applicable

Full citation	McWilliams Richard G, Martin Janis, White Donagh, Gould Derek A, Rowlands Peter C, Haycox Alan, Brennan John, Gilling-Smith Geoffrey L, and Harris Peter L (2002) Detection of endoleak with enhanced ultrasound imaging: comparison with biphasic computed tomography. Journal of endovascular therapy : an official journal of the International Society of Endovascular Specialists 9, 170-9								
Study type	Cross sectional study								
Aim	To compare unenhanced and enhanced ultrasound imaging to biphasic computed tomography (CT) in the detection after EVAR.								
Patient Characteristics	<p>Inclusion criteria: Patients who underwent EVAR. Exclusion criteria: All patients seen at follow-up intervals were asked to participate unless there was documented contraindication to the use of Levovist.</p> <table border="1"> <thead> <tr> <th colspan="2">Study Characteristics</th> </tr> </thead> <tbody> <tr> <td>Mean Age</td> <td>70 years</td> </tr> <tr> <td>Males (%)</td> <td>83%</td> </tr> <tr> <td>Aneurysm Size (\pmSD)</td> <td>Not reported</td> </tr> </tbody> </table>	Study Characteristics		Mean Age	70 years	Males (%)	83%	Aneurysm Size (\pm SD)	Not reported
Study Characteristics									
Mean Age	70 years								
Males (%)	83%								
Aneurysm Size (\pm SD)	Not reported								
Sample Size	53 patients								
Index test(s)	<p>CDUS and CEUS</p> <p>Endograft patients are followed according to the intervals recommended by the EUROSTAR registry at 1,3,6,12, 18 and 24 months and annually thereafter. One experienced vascular sonographer performed all the ultrasound studies. Patients were scanned with colour and power Doppler before and after the intravenous administration of Levovist, an ultrasound contrast. Endoleak was indicated by colour flow within the aneurysm sac outside the stent graft.</p>								
Reference standard(s)	<p>CTA</p> <p>Endoleak was defined as the presence of intrasac flow outside the stent graft. It was defined by its relationship to the endograft, aneurysm wall, and aortic side branches and categorised using the White/May classification. Biphasic enhanced CT was performed on the same day using the same protocol and imager. Either of two radiologists, who were blinded to the ultrasound results, recorded all the CT studies.</p>								
Study Details	<p>Study location: Liverpool, UK</p> <p>Study setting: Departments of Radiology and Vascular Surgery</p> <p>Study dates: March 1999 to May 2000</p> <p>Loss to follow-up: 2 participants excluded because radiology staff failed to follow protocol.</p> <p>Time between testing & Treatment: Same day</p>								

Full citation	McWilliams Richard G, Martin Janis, White Donagh, Gould Derek A, Rowlands Peter C, Haycox Alan, Brennan John, Gilling-Smith Geoffrey L, and Harris Peter L (2002) Detection of endoleak with enhanced ultrasound imaging: comparison with biphasic computed tomography. Journal of endovascular therapy : an official journal of the International Society of Endovascular Specialists 9, 170-9
	Source of funding: Not specified
Quality Assessment (QUADAS 2)	Patient selection: Low risk of bias Index test: Low risk of bias Reference standard: Low risk of bias Flow and timing: Low risk of bias Overall risk of bias: Low risk of bias Directness: Directly applicable

Full citation	Mauro R, Maioli F, Freyrie A, Testi G, Palumbo N, Serra C, and Stella A (2010) Is CEUS a valid alternative to CTA in endoleak's detection? Italian Journal of Vascular and Endovascular Surgery 17, 253-258							
Study type	Cross sectional study							
Aim	Evaluate the diagnostic accuracy of section generation enhancement ultrasound (CEUS) in comparison with CTA to detect endoleaks in patients submitted to EVAR.							
Patient Characteristics	<p>Inclusion criteria: Patients undergoing EVAR Exclusion criteria: Renal insufficiency One patient who died seven days after procedure Patients who refused the follow-up program</p> <table border="1"> <thead> <tr> <th colspan="2">Study Characteristics</th> </tr> </thead> <tbody> <tr> <td>Mean Age (years)</td> <td>74.3 ± 7.2 years</td> </tr> <tr> <td>Aneurysm Size (±SD)</td> <td>Not reported</td> </tr> </tbody> </table>		Study Characteristics		Mean Age (years)	74.3 ± 7.2 years	Aneurysm Size (±SD)	Not reported
Study Characteristics								
Mean Age (years)	74.3 ± 7.2 years							
Aneurysm Size (±SD)	Not reported							
Sample Size	122 patients							
Index test(s)	CEUS Program consisted of CEUS and CTA examinations at 1,6,12 and 24 months after EVAR. All exams were performed within 14 days by different blinded operators. The second generation echo-contrast agent SonoVue was employed. Presence of endoleaks was defined as contrast enhancement into the residual aneurysm sac. The physician who performed CEUS did not know the results of CTA examinations.							
Reference standard(s)	CTA CTA was performed with arterial phase and 3 minutes delayed phase, using a CTA multislice 16 slice GE light Speed scanner. The images were reviewed by a radiologist.							
Study Details	Study location: Bologna, Italy Study setting: Department of Vascular Surgery Study dates: January 2005 to May 2007 Loss to follow-up: No adverse events were noted Time between testing & Treatment: 14 days							

Full citation	Mauro R, Maioli F, Freyrie A, Testi G, Palumbo N, Serra C, and Stella A (2010) Is CEUS a valid alternative to CTA in endoleak's detection? Italian Journal of Vascular and Endovascular Surgery 17, 253-258
	Source of funding: Not specified
Quality Assessment (QUADAS 2)	Patient selection: Low risk of bias Index test: Low risk of bias Reference standard: Low risk of bias Flow and timing: Low risk of bias Overall risk of bias: Low risk of bias Directness: Directly applicable

Full citation	Mori Kensaku, Saida Tsukasa, Sato Fujio, Uchikawa Yoko, Konishi Takahiro, Ishiguro Toshitaka, Hiyama Takashi, Hoshiai Sodai, Okamoto Yoshikazu, Nasu Katsuhiko, and Minami Manabu (2017) Endoleak detection after endovascular aneurysm repair using unenhanced MRI with flow suppression technique: Feasibility study in comparison with contrast-enhanced CT. European radiology 27(1), 336-344									
Study type	Cross sectional study									
Aim	Evaluate the feasibility of unenhanced motion sensitized-driven equilibrium (MSDE) - prepared balanced turbo filed echo (BTFE) sequences for detecting endoleaks after EVAR.									
Patient Characteristics	<p>Inclusion criteria: Consecutive patients who underwent EVAR for aortic and/or iliac aneurysms aged between 46 and 90 years Written informed consent obtained</p> <p>Exclusion criteria: Contraindication to contrast enhanced CT Predialysis renal failure Severe bronchial asthma Contraindication to unenhanced MR imaging: MR-incompatible stent graft Patient with pacemaker</p> <table border="1"> <thead> <tr> <th colspan="2">Study Characteristics</th> </tr> </thead> <tbody> <tr> <td>Mean Age (range)</td> <td>73.2 years (47-87 years)</td> </tr> <tr> <td>Males (%)</td> <td>71.7%</td> </tr> <tr> <td>Aneurysm Size (±SD)</td> <td>Not reported</td> </tr> </tbody> </table>		Study Characteristics		Mean Age (range)	73.2 years (47-87 years)	Males (%)	71.7%	Aneurysm Size (±SD)	Not reported
Study Characteristics										
Mean Age (range)	73.2 years (47-87 years)									
Males (%)	71.7%									
Aneurysm Size (±SD)	Not reported									
Sample Size	46 patients									
Index test(s)	MR imaging All patients underwent unenhanced MR imaging with 1.5 – Tesla MR system. Unenhanced MR imaging was performed just after CTA on the same day in all but two patients, who underwent MR imaging two days after CTA. Unenhanced 2D MSDE- prepared BTFE sequences with and without flow suppression were acquired in the axial, coronal and sagittal planes. Endoleaks were diagnosed as follows: first, the observers detected all hyperintense areas in the aneurysms, other than flow blood in the stent grafts. Endoleaks were distinguished from misregistration artefacts by reviewing adjacent images in the same plan and/ or images in different planes. When									

Full citation	Mori Kensaku, Saida Tsukasa, Sato Fujio, Uchikawa Yoko, Konishi Takahiro, Ishiguro Toshitaka, Hiyama Takashi, Hoshiai Sodai, Okamoto Yoshikazu, Nasu Katsuhiko, and Minami Manabu (2017) Endoleak detection after endovascular aneurysm repair using unenhanced MRI with flow suppression technique: Feasibility study in comparison with contrast-enhanced CT. European radiology 27(1), 336-344
	hyperintense areas were located in compatible positions on adjacent images in the same plane and/ or on images in different planes, they were diagnosed as endoleaks.
Reference standard(s)	CTA In all patients, biphasic contrast enhanced CT was performed within 28 days after EVAR.
Study Details	Study location: Japan Study setting: Department of Radiology Study dates: September 2012 to August 2014 Loss to follow-up: All patients tolerated contrast enhanced CT and unenhanced MR imaging Time between testing & Treatment: Same day for all patients apart from 2 who had MR done 2 days after CTA Source of funding: Grant received from Grant in Aid for Scientific Research from Japan Society for Promotion of Science. Philips Medical Systems provided authors with MSDE preparation pulse before selling on the market as a clinical science key.
Quality Assessment (QUADAS 2)	Patient selection: Low risk of bias Index test: Low risk of bias Reference standard: High risk of bias – Observers involved in interpreting reference standard and index test Flow and timing: Low risk of bias Overall risk of bias: Moderate risk of bias Directness: Indirectly applicable. MSDE-BTFE sequence utilised in study is not routinely used in practice.

Full citation	Motta R, Rubaltelli L, Vezzano R, Vida V, Marchesi P, Stramare R, Zanon A, Battistel M, Somnavilla M, and Miotto D (2012) Role of multidetector CT angiography and contrast-enhanced ultrasound in redefining follow-up protocols after endovascular abdominal aortic aneurysm repair. La Radiologia medica 117, 1079-92
Study type	Cross sectional study
Aim	Evaluate the accuracy of CEUS compared with a particularly tailored protocol of CTA performed with a 64-row multidetector CT.
Patient Characteristics	Inclusion criteria: Consecutive patients who underwent CTA Exclusion criteria: Severe allergy to iodinated contrast Severe renal failure Study Characteristics: Not reported
Sample Size	88 patients
Index test(s)	CEUS CEUS examinations and evaluations were performed by two other senior radiologists in consensus reading, masked to CTA findings, with an Esatune (26 patients) or a MyLab25 (62 patients).
Reference standard(s)	CTA CTA scans were obtained from the coeliac to the femoral arteries before and after the i.v. injection of contrast medium. CTA examinations were performed by two senior radiologists, in consensus reading and blinded to CEUS results. Endoleaks were identified and characterised according to the classification of standard guidelines.
Study Details	Study location: Padua, Italy Study setting: Department of Radiology Study dates: January 2008 and December 2010 Loss to follow-up: No adverse events were recorded during the examinations. Time between testing & Treatment: CTA and CEUS conducted within a few hours Source of funding: Not specified
Quality Assessment (QUADAS 2)	Patient selection: Low risk of bias Index test: Low risk of bias Reference standard: Low risk of bias Flow and timing: Low risk of bias

Full citation	Motta R, Rubaltelli L, Vezzaro R, Vida V, Marchesi P, Stramare R, Zanon A, Battistel M, Sommovilla M, and Miotto D (2012) Role of multidetector CT angiography and contrast-enhanced ultrasound in redefining follow-up protocols after endovascular abdominal aortic aneurysm repair. La Radiologia medica 117, 1079-92
	Overall risk of bias: Low risk of bias
	Directness: Directly applicable

Full citation	Nagre Shardul B, Taylor Steven M, Passman Marc A, Patterson Mark A, Combs Bart R, Lowman Bruce G, Jordan William D, and Jr (2011) Evaluating outcomes of endoleak discrepancies between computed tomography scan and ultrasound imaging after endovascular abdominal aneurysm repair. Annals of vascular surgery 25, 94-100																							
Study type	Cross sectional study (retrospective)																							
Aim	Determine discrepancies in endoleak detection between CTA and CDUS.																							
Patient Characteristics	Inclusion criteria: Patients who had undergone both CTA and CDUS at the same visit or within 7 days of each other Exclusion criteria: Not specified																							
	<table border="1"> <thead> <tr> <th colspan="2">Study Characteristics</th> </tr> </thead> <tbody> <tr> <td>Age (years)</td> <td>71.4±8.5</td> </tr> <tr> <td>Males (%)</td> <td>84.2%</td> </tr> <tr> <td>Smoking (%)</td> <td>90.8%</td> </tr> <tr> <td>Coronary Artery Disease (%)</td> <td>50.8%</td> </tr> <tr> <td>Chronic Obstructive Pulmonary Disease (%)</td> <td>21.3%</td> </tr> <tr> <td>Hypertension (%)</td> <td>63.5%</td> </tr> <tr> <td>Stroke (%)</td> <td>10.1%</td> </tr> <tr> <td>Diabetes Mellitus (%)</td> <td>14.1%</td> </tr> <tr> <td>End stage renal disease on dialysis (%)</td> <td>2.7%</td> </tr> <tr> <td>Aneurysm Size (±SD)</td> <td>Not reported</td> </tr> </tbody> </table>		Study Characteristics		Age (years)	71.4±8.5	Males (%)	84.2%	Smoking (%)	90.8%	Coronary Artery Disease (%)	50.8%	Chronic Obstructive Pulmonary Disease (%)	21.3%	Hypertension (%)	63.5%	Stroke (%)	10.1%	Diabetes Mellitus (%)	14.1%	End stage renal disease on dialysis (%)	2.7%	Aneurysm Size (±SD)	Not reported
Study Characteristics																								
Age (years)	71.4±8.5																							
Males (%)	84.2%																							
Smoking (%)	90.8%																							
Coronary Artery Disease (%)	50.8%																							
Chronic Obstructive Pulmonary Disease (%)	21.3%																							
Hypertension (%)	63.5%																							
Stroke (%)	10.1%																							
Diabetes Mellitus (%)	14.1%																							
End stage renal disease on dialysis (%)	2.7%																							
Aneurysm Size (±SD)	Not reported																							
Sample Size	455 patients																							
Index test(s)	CDUS Patients were evaluated with CTA and CDUS imaging within 30 days after the procedure. Both studies were recorded within 7 days of each other. Abdominal X-ray was performed at the discretion of the physician. After the initial study, patients were followed up at 6-12 months intervals, depending on multiple risk factors, including clinical signs and symptoms, abnormal findings in previous studies, and renal function. All CDUS scans were performed by a registered vascular technician.																							
Reference standard(s)	CTA Both contrast enhanced and non-contrast images were obtained by performing helical scans from the diaphragm to the upper thigh using a thin section of CT angiography protocol. CT without contrast and DUS were obtained in patients with abnormal renal function (creatinine: >1.4mg/dL).																							

Full citation	Nagre Shardul B, Taylor Steven M, Passman Marc A, Patterson Mark A, Combs Bart R, Lowman Bruce G, Jordan William D, and Jr (2011) Evaluating outcomes of endoleak discrepancies between computed tomography scan and ultrasound imaging after endovascular abdominal aneurysm repair. Annals of vascular surgery 25, 94-100
Study Details	Study location: USA Study setting: University of Alabama Study dates: October 1999 and June 2009 Loss to follow-up: National death indices were reviewed of patients lost to follow-up. Time between testing & Treatment: CTA and CDUS conducted on the same day or within 7 days of each other Source of funding: Not specified.
Quality Assessment (QUADAS 2)	Patient selection: Unclear risk of bias- Unclear if consecutive patients were selected Index test: Unclear risk of bias- Unclear binding between index test and reference standard. Definition of endoleak not provided Reference standard: Unclear risk of bias- unclear blinding between reference standard and index test Flow and timing: Low risk of bias Overall risk of bias: High risk of bias Directness: Directly applicable

Full citation	Nerlekar R, Warriar R, De Ryke, R , Miller R, Hewitt P M, and Scott A (2006) A comparative study of ultrasound and computed tomography scan for the follow-up of abdominal aortic aneurysms after endovascular repair. Journal for Vascular Ultrasound 30, 81-85							
Study type	Cross sectional study							
Aim	To compare ultrasound and CT scan in our practice to ascertain whether ultrasound alone would be sufficient for follow-up of AAA after EVAR.							
Patient Characteristics	<p>Inclusion criteria: All patients who underwent EVAR for an AAA and had CDUS and CT on the same day or within 1 month</p> <p>Exclusion criteria:</p> <ul style="list-style-type: none"> Patients with modified device configuration Pre-existing grafts Graft deployment failure Patients who died before 1 month follow up from the study US and CT scans performed in isolation <table border="1" style="width: 100%; border-collapse: collapse;"> <tr> <th colspan="2" style="text-align: left;">Study Characteristics</th> </tr> <tr> <td style="width: 50%;">Mean Age (range)</td> <td>73 years (52-93 years)</td> </tr> <tr> <td>Aneurysm Size (range)</td> <td>52 mm (21-75 mm)</td> </tr> </table>		Study Characteristics		Mean Age (range)	73 years (52-93 years)	Aneurysm Size (range)	52 mm (21-75 mm)
Study Characteristics								
Mean Age (range)	73 years (52-93 years)							
Aneurysm Size (range)	52 mm (21-75 mm)							
Sample Size	121 patients							
Index test(s)	<p>CDUS</p> <p>Patients were followed up with contrast-enhanced spiral CT scanning and duplex ultrasound at 1 and 6 months after EVAR and annually thereafter. All US examinations were performed by a single experienced ultrasonographer using a Sonoline Elegra Ultrasound Imaging System with colour flow Doppler.</p>							
Reference standard(s)	<p>CTA</p> <p>CT scans were obtained using a High Speed Advanced 2X spiral CT scanner with administration of 140 mL of intravenous contrast. All US and CT scan films were reviewed by two blinded reviewers.</p>							
Study Details	<p>Study location: Australia</p> <p>Study setting: Department of Surgery</p> <p>Study dates: 1995 and 2003</p> <p>Loss to follow-up: 3 participants died before the 1 month follow-up from study</p>							

Full citation	Nerlekar R, Warriar R, De Ryke, R , Miller R, Hewitt P M, and Scott A (2006) A comparative study of ultrasound and computed tomography scan for the follow-up of abdominal aortic aneurysms after endovascular repair. Journal for Vascular Ultrasound 30, 81-85
	Time between testing & Treatment: Both tests done of the same day or within 1 month Source of funding: Not reported
Quality Assessment (QUADAS 2)	Patient selection: Low risk of bias Index test: Unclear risk of bias - Definition of endoleak not provided Reference standard: Low risk of bias Flow and timing: Low risk of bias Overall risk of bias: Moderate risk of bias Directness: Directly applicable

Full citation	Oikonomou K, Ventin F C, Paraskevas K I, Geisselsoder P, Ritter W, and Verhoeven E L (2012) Early follow-up after endovascular aneurysm repair: Is the first postoperative computed tomographic angiography scan necessary?. Journal of Endovascular Therapy 19, 151-156									
Study type	Cross sectional study									
Aim	Examine whether initial postoperative computed tomographic angiography (CTA) is needed in all patients undergoing EVAR.									
Patient Characteristics	Inclusion criteria: Consecutive patients who underwent EVAR for infrarenal AAA Exclusion criteria: Patients unsuitable for a postoperative CTA due to severely impaired renal function									
	<table border="1"> <thead> <tr> <th colspan="2">Study Characteristics</th> </tr> </thead> <tbody> <tr> <td>Mean Age (range)</td> <td>73 years (range 46-91)</td> </tr> <tr> <td>Male (%)</td> <td>85%</td> </tr> <tr> <td>Aneurysm Size (range)</td> <td>55 mm (48-110 mm)</td> </tr> </tbody> </table>		Study Characteristics		Mean Age (range)	73 years (range 46-91)	Male (%)	85%	Aneurysm Size (range)	55 mm (48-110 mm)
Study Characteristics										
Mean Age (range)	73 years (range 46-91)									
Male (%)	85%									
Aneurysm Size (range)	55 mm (48-110 mm)									
Sample Size	100 patients									
Index test(s)	CDUS Patients were prospectively enrolled for a triple-modality early follow-up imaging protocol consisting an intraoperative completion angiogram, a DUS, and a plain abdominal radiograph prior to hospital discharge. These data were compared with the results of a CTA performed within 1 month after the procedure. CDUS examinations were performed by experienced vascular surgeons. An endoleak on CDUS was defined as the presence of persistent blood flow and spectral signal outside the graft wall.									
Reference standard(s)	CTA CTAs were performed on a Siemens Somatom scanner. Patients with known history of contrast agent allergy received oral corticosteroids and antihistamines prior to the examinations. Patients with GFR < 60 mL/min and 2 additional risk factors, including age > 75 years, diabetes mellitus, and established cardiac insufficiency, were given 24 hours of intravenous hydration and acetylcysteine before the CTA.									
Study Details	Study location: Germany Study setting: Department of Radiology Study dates: November 2009 to May 2011 Loss to follow-up: Not specified. Time between testing & Treatment: Median interval between CDUS and CTA was 9 days (range from 0-25) Source of funding: Not specified									

Full citation	Oikonomou K, Ventin F C, Paraskevas K I, Geisselsoder P, Ritter W, and Verhoeven E L (2012) Early follow-up after endovascular aneurysm repair: Is the first postoperative computed tomographic angiography scan necessary?. Journal of Endovascular Therapy 19, 151-156
Quality Assessment (QUADAS 2)	Patient selection: Low risk of bias Index test: Unclear risk of bias- unclear if index test results were interpreted without knowledge of the result of the reference standard Reference standard: Unclear risk of bias- unclear if reference standard results were interpreted without knowledge of the result of the index test Flow and timing: Low risk of bias Overall risk of bias: High risk of bias Directness: Directly applicable

Full citation	Pages S, Favre J P, Cerisier A, Pyneeandee S, Boissier C, and Veyret C (2001) Comparison of color duplex ultrasound and computed tomography scan for surveillance after aortic endografting. Annals of vascular surgery 15, 155-62									
Study type	Cross sectional study									
Aim	Compare CDUS and CT scanning for follow-up of patients treated by EVAR.									
Patient Characteristics	Inclusion criteria: Patients referred for elective treatment. Exclusion criteria: Not specified									
	<table border="1"> <thead> <tr> <th colspan="2">Study Characteristics</th> </tr> </thead> <tbody> <tr> <td>Mean Age (Range)</td> <td>71 years (50-83 years)</td> </tr> <tr> <td>Males (%)</td> <td>95%</td> </tr> <tr> <td>Aneurysm Size (\pmSD)</td> <td>55 \pm 9 mm</td> </tr> </tbody> </table>		Study Characteristics		Mean Age (Range)	71 years (50-83 years)	Males (%)	95%	Aneurysm Size (\pm SD)	55 \pm 9 mm
Study Characteristics										
Mean Age (Range)	71 years (50-83 years)									
Males (%)	95%									
Aneurysm Size (\pm SD)	55 \pm 9 mm									
Sample Size	41 participants									
Index test(s)	CDUS Postoperative surveillance included plain abdominal roentgenography, CT scan and CDUS. These procedures were performed prior to discharge, and at 3, 6, 12, 24 and 30 months. CT and CDUS examinations were performed by different operators at different locations. The second operator had no knowledge of the results of the first examination. On CDUS, the characteristic feature was detection of a colour and spectral signal outside the limits of the prosthesis. On CDUS, the largest anteroposterior or transverse diameter was used for the detection of diameter changes.									
Reference standard(s)	CTA Three consecutive spiral CT scan acquisitions were performed. On CT scans, endoleaks were characterised by extravasation of contrast dye between the prosthesis and aneurysmal wall. On CT scan, the maximum diameter of the aneurysm was defined as the largest diameter measured regardless of the position of the aortic axis, including the thickness of the wall.									
Study Details	Study location: France Study setting: University Hospital Centre Study dates: November 1996 to September 1999 Loss to follow-up: No loss to follow-up Time between testing & Treatment: Not specified Source of funding: Not reported									

Full citation	Pages S, Favre J P, Cerisier A, Pyneeandee S, Boissier C, and Veyret C (2001) Comparison of color duplex ultrasound and computed tomography scan for surveillance after aortic endografting. Annals of vascular surgery 15, 155-62
Quality Assessment (QUADAS 2)	<p>Patient selection: Low risk of bias Index test: Low risk of bias Reference standard: Low risk of bias Flow and timing: High risk of bias- interval between index test and reference test not specified</p> <p>Overall risk of bias: Moderate risk of bias</p> <p>Directness: Partially indirect. Although the protocol specifies that studies published after 2000 should be included, the committee were interested in studies in which patients received scans before this cut-off. As this study was conducted between 1996 and 1999, the study was downgraded for partial indirectness.</p>

Full citation	Parent F Noel, 3rd, Godziachvili Vasso, Meier George H, 3rd , Parker Frank M, Carter Kathleen, Gayle Robert G, Demasi Richard J, and Gregory Roger T (2002) Endograft limb occlusion and stenosis after ANCURE endovascular abdominal aneurysm repair. Journal of vascular surgery 35, 686-90
Study type	Cross sectional study (retrospective)
Aim	Demonstration of the value of CDUS in the detection of Type I and Type II endoleak
Patient Characteristics	Inclusion criteria: Patients who underwent treatment before September 1999 Exclusion criteria: Not specified Study Characteristics: Not specified
Sample Size	83 patients
Index test(s)	CDUS CDUS and CTA scans were scheduled within 30 days and at 3,6 and 12 months after surgery and annually thereafter. A Type I endoleak was defined as an incompetent seal at one of the graft attachment sites, and a Type II was defined as continuance of liquefied blood within the AAA sac because of a patent branch vessel. Type I and Type III were not observed. CDUS scan evidence of an endoleak required the identification of perigraft Doppler scan signals with colour flow and was confirmed with spectral analysis and mapping of the blood flow pattern.
Reference standard(s)	CTA CT scan protocol consisted of a 3 mm slice thickness and a pitch of 2 mm, with a single detector helical scanner. CT scan was diagnostic for endoleak in contrast was visualised exterior to the endograft but within the aneurysm sac.
Study Details	Study location: USA Study setting: Department of Surgery Study dates: February 1996 to July 2000 Loss to follow-up: Not specified Time between testing & Treatment: Not specified Source of funding: Not specified
Quality Assessment (QUADAS 2)	Patient selection: Low risk of bias Index test: Unclear risk of bias- unclear blinding between index test and reference standard

Full citation	Parent F Noel, 3rd, Godziachvili Vasso, Meier George H, 3rd , Parker Frank M, Carter Kathleen, Gayle Robert G, Demasi Richard J, and Gregory Roger T (2002) Endograft limb occlusion and stenosis after ANCURE endovascular abdominal aneurysm repair. Journal of vascular surgery 35, 686-90
	Reference standard: Unclear risk of bias- unclear blinding between reference standard and index test Flow and timing: Unclear risk of bias- unclear time interval between index test and reference standard Overall risk of bias: High risk of bias Directness: Directly applicable

Full citation	Perini P, Sediri I, Midulla M, Delsart P, Mouton S, Gautier C, Pruvo J P, and Haulon S (2011) Single-centre prospective comparison between contrast-enhanced ultrasound and computed tomography angiography after EVAR. European journal of vascular and endovascular surgery : the official journal of the European Society for Vascular Surgery 42, 797-802
Study type	Cross-sectional study
Aim	To evaluate contrast enhanced ultrasound (CEUS) as an effective alternative to CT-angiography (CTA) for endoleak detection and aneurismal sac diameter measurement in the follow-up after EVAR.
Patient Characteristics	Inclusion criteria: All patients who underwent EVAR for AAA and for whom a follow-up with CTA and CEUS was undertaken. Exclusion criteria: Patients who underwent thoracic endografting Patients with severe contrast media allergy Patients with severe renal insufficiency Study Characteristics: Not specified
Sample Size	395 patients
Index test(s)	CEUS All US scans were performed by 3 angiologists experienced in vascular ultrasonography and in the use of ultrasound contrast material who were blinded to CTA findings at the time of examination. Endoleak detection was performed at a low mechanical index (0.2-0.3) and with the focus positioned behind the aorta to delay bubble destruction. Endoleaks were classified according to that 'Reporting standards for endovascular aortic aneurysm repair' published in 2002. Paired imaging was performed less than 1 month after procedure (typically before discharge) and during follow up (median 18.55 months)
Reference standard(s)	CTA All CTAs were performed with a 640 slice CT scanner. Triple-phase acquisition with unenhanced and contrast enhanced in arterial (with bolus tracking) and delayed phases (at 70 s) was carried out from the thorax to the femoral bifurcations. CTAs were analysed on an independent dedicated workstation by both vascular surgeons and vascular radiologists (who were blinded to the results of CEUS, if already performed) to determine the maximal aortic diameter by centreline measurements and to depict and characterise endoleaks.
Study Details	Study location: France Study setting: Not specified Study dates: January 2006 to December 2010 Loss to follow-up: All patients completed the follow-up, and no adverse events were recorded during these examinations.

Full citation	Perini P, Sediri I, Midulla M, Delsart P, Mouton S, Gautier C, Pruvo J P, and Haulon S (2011) Single-centre prospective comparison between contrast-enhanced ultrasound and computed tomography angiography after EVAR. European journal of vascular and endovascular surgery : the official journal of the European Society for Vascular Surgery 42, 797-802
	Time between testing & Treatment: <15 days Source of funding: No source of funding
Quality Assessment (QUADAS 2)	Patient selection: Low risk of bias Index test: Low Risk of bias Reference standard: Low Risk of Bias Flow and timing: Low risk of bias Overall risk of bias: Low risk of bias Directness: Directly applicable

Full citation	Perini P, Sediri I, Midulla M, Delsart P, Gautier C, and Haulon S (2012) Contrast-Enhanced ultrasound vs. CT angiography in fenestrated EVAR surveillance: A single-Center comparison. Journal of Endovascular Therapy 19, 648-655							
Study type	Cross sectional study (retrospective)							
Aim	To evaluate CEUS as an effective alternative to CTA during follow-up after fenestrated EVAR of juxtarenal aortic aneurysms.							
Patient Characteristics	<p>Inclusion criteria: All patients who received a fenestrated stent-graft for juxtarenal abdominal aortic who had both CTA and CEUS imaging studies. Only fenestrated endografts with up to 3 fenestrations with or without a scallop for the celiac trunk or the superior mesenteric artery (SMA) were eligible so that entire implant could be visualised with standard abdominal ultrasound</p> <p>Exclusion criteria: Patients who received endografts with >3 fenestrations Patients who died in the early postoperative period Patients who underwent a CT without contrast because of severe renal insufficiency Inadequate CEUS due to intervening bowel gas or ascites</p> <table border="1"> <thead> <tr> <th colspan="2">Study Characteristics</th> </tr> </thead> <tbody> <tr> <td>Mean Age</td> <td>72 years</td> </tr> <tr> <td>Aneurysm Size (\pmSD)</td> <td>57.70 \pm8.59 mm</td> </tr> </tbody> </table>		Study Characteristics		Mean Age	72 years	Aneurysm Size (\pm SD)	57.70 \pm 8.59 mm
Study Characteristics								
Mean Age	72 years							
Aneurysm Size (\pm SD)	57.70 \pm 8.59 mm							
Sample Size	62 patients							
Index test(s)	CEUS The timing of the first postoperative investigation was no more than 30 days after procedure (preferably 1 week), and the interval between the 2 examinations was <7 days. All CEUS scans were performed by 3 angiologists. Ultrasound examinations were performed with any of 3 machines: a Vivid 7 or a Vivid 9 or a Philips iE33 equipped with a convex 3.5- MHz probe. All physicians were blinded to the findings of the other study if already performed. Endoleaks were identified and classified according to established reporting standards.							
Reference standard(s)	CTA CTA analysis were performed by both vascular surgeons and vascular radiologists. Triple-phase CTAs [unenhanced and contrast-enhanced in arterial (with bolus tracking) and delayed (70 seconds) phases] were acquired on a 64 slice CT scanner from the thorax to the femoral bifurcations. Iodinated contrast or Omnipaque 350 was injected intravenously at a flow rate of 4.5mL/s, followed by 40mL of saline solution injected at the same time. The CTAs were processed on an independent dedicated workstation to generate all conventional reconstructions following a standardised pattern.							

Full citation	Perini P, Sediri I, Midulla M, Delsart P, Gautier C, and Haulon S (2012) Contrast-Enhanced ultrasound vs. CT angiography in fenestrated EVAR surveillance: A single-Center comparison. Journal of Endovascular Therapy 19, 648-655
Study Details	Study location: France Study setting: University Hospital Study dates: January 2008 and April 2011 Loss to follow-up: Not reported Time between testing & Treatment: Interval between the 2 examinations was <7 days. Source of funding: Not reported
Quality Assessment (QUADAS 2)	Patient selection: Low risk of bias Index test: Low risk of bias Reference standard: low risk of bias Flow and timing: Low risk of bias Overall risk of bias: Low risk of bias Directness: Directly applicable

Full citation	Raman Kathleen G, Missig-Carroll Nita, Richardson Tracey, Muluk Satish C, and Makaroun Michel S (2003) Color-flow duplex ultrasound scan versus computed tomographic scan in the surveillance of endovascular aneurysm repair. Journal of vascular surgery 38, 645-51								
Study type	Cross sectional study (retrospective)								
Aim	Compare both computed tomography scan (CT) and colour flow duplex ultrasound scanning as surveillance modalities for clinically significant endoleaks and to evaluate concordance in AAA diameter measurements in patients after EVAR in a busy hospital vascular laboratory.								
Patient Characteristics	<p>Inclusion criteria: Patients who underwent EVAR with Ancure or AneuRX at the University of Pittsburgh Medical Centre. Exclusion criteria: Not specified</p> <table border="1"> <thead> <tr> <th colspan="2">Study Characteristics</th> </tr> </thead> <tbody> <tr> <td>Age</td> <td>73 ± 7 years</td> </tr> <tr> <td>Males (%)</td> <td>87.5%</td> </tr> <tr> <td>Aneurysm Size (±SD)</td> <td>Not reported</td> </tr> </tbody> </table>	Study Characteristics		Age	73 ± 7 years	Males (%)	87.5%	Aneurysm Size (±SD)	Not reported
Study Characteristics									
Age	73 ± 7 years								
Males (%)	87.5%								
Aneurysm Size (±SD)	Not reported								
Sample Size	281								
Index test(s)	<p>CDUS</p> <p>Follow-up of these patients included same day ultrasound, CT, and abdominal radiograph in the first postoperative month, then at 6 months, 12 months, and yearly thereafter. Patients who underwent routine endovascular aneurysm repair with commercial endografts under same day studies only 30 days postoperatively. All duplex scans were performed by a registered vascular technologist in a fully accredited hospital vascular laboratory. A protocol standardised for the vascular laboratory was used for assessing the abdominal aorta, aortic bifurcation, and iliac vessels. Colour flow duplex scanning and Doppler interrogation of the sac was used to rule out the presence of perigraft flow. Endoleak detection was based on direct visualisation and spectral confirmation of perigraft flow into an aneurysm sac. All CDUS were reviewed by a vascular surgeon. The ultrasound scanning technologists and the surgeon reviewing the tapes were both unaware of the results of the CT scan during any portion of the ultrasound scan examination or review.</p>								
Reference standard(s)	<p>CTA</p> <p>Contrast CT scans were performed. All CT scans were reviewed by a single vascular surgeon.</p>								
Study Details	<p>Study location: Pittsburgh, USA</p> <p>Study setting: University of Pittsburgh Medical Centre</p> <p>Study dates: February 1996 to November 2002</p>								

Full citation	Raman Kathleen G, Missig-Carroll Nita, Richardson Tracey, Muluk Satish C, and Makaroun Michel S (2003) Color-flow duplex ultrasound scan versus computed tomographic scan in the surveillance of endovascular aneurysm repair. Journal of vascular surgery 38, 645-51
	Loss to follow-up: Not specified Time between testing & Treatment: CDUS and CTA carried out on the same day Source of funding: Not specified
Quality Assessment (QUADAS 2)	Patient selection: Low risk of bias Index test: Low risk of bias Reference standard: Unclear risk of bias - unclear if reference standard results were interpreted without knowledge of index test Flow and timing: Low risk of bias Overall risk of bias: Moderate risk of bias Directness: Direct

Full citation	Schmieder Greg C, Stout Christopher L, Stokes Gordon K, Parent F Noel, and Panneton Jean M (2009) Endoleak after endovascular aneurysm repair: duplex ultrasound imaging is better than computed tomography at determining the need for intervention. Journal of vascular surgery 50, 1012-8									
Study type	Cross sectional study (retrospective)									
Aim	Retrospectively compare CT and CDUS imaging in the detection of endoleaks requiring intervention after EVAR.									
Patient Characteristics	Inclusion criteria: Only patients with paired imaging studies \leq 3 months of each other were included. Exclusion criteria: Patients with symptomatic or ruptured AAA and isolated iliac aneurysms.									
	<table border="1"> <thead> <tr> <th colspan="2">Study Characteristics</th> </tr> </thead> <tbody> <tr> <td>Mean Age (range)</td> <td>72 years (51-90 years)</td> </tr> <tr> <td>Males (%)</td> <td>86%</td> </tr> <tr> <td>Aneurysm Size (\pmSD)</td> <td>Not reported</td> </tr> </tbody> </table>		Study Characteristics		Mean Age (range)	72 years (51-90 years)	Males (%)	86%	Aneurysm Size (\pm SD)	Not reported
Study Characteristics										
Mean Age (range)	72 years (51-90 years)									
Males (%)	86%									
Aneurysm Size (\pm SD)	Not reported									
Sample Size	236 patients									
Index test(s)	CDUS CDUS or CT examinations were scheduled at 1, 3, 6 and 12 months and annually thereafter. The CDUS was performed in sagittal and transverse views to evaluate the AAA sac for the presence of flow outside the graft. CDUS scan evidence of an endoleak required the identification of perigraft Doppler scan signal with colour flow and was confirmed with spectral analysis and mapping of blood flow pattern. All CDUS examinations occurred in a peripheral vascular laboratory and were performed by vascular technicians. Vascular surgeons read the results. The CDUS examination was considered inadequate if the endograft graft was poorly or incompletely seen secondary to patient habitus or obscured by bowel gas.									
Reference standard(s)	CTA CT scan surveillance was performed using a GE Lightspeed plus 16 slice scanner. Interpretation of CT scan was performed by radiology, whereas vascular surgery interpreted CDU results. Vascular surgeons made clinical decisions by reviewing both imaging modalities and the patient's clinical findings.									
Study Details	Study location: USA Study setting: Not specified Study dates: July 1996 to March 2007 Loss to follow-up: Not specified Time between testing & Treatment: Mean interval between CDU and CT was 18 days (range, 0-90 days)									

Full citation	Schmieder Greg C, Stout Christopher L, Stokes Gordon K, Parent F Noel, and Panneton Jean M (2009) Endoleak after endovascular aneurysm repair: duplex ultrasound imaging is better than computed tomography at determining the need for intervention. Journal of vascular surgery 50, 1012-8
	Source of funding: Not specified
Quality Assessment (QUADAS 2)	Patient selection: Low risk of bias Index test: Low risk of bias Reference standard: Low risk of bias Flow and timing: High risk of bias. Inadequate interval between index and reference test. Overall risk of bias: Moderate Directness: Direct

Full citation	Ten Bosch, Jan A, Rouwet Ellen V, Peters Cecile T. H, Jansen Linda, Verhagen Hence J. M, Prins Martin H, and Teijink Joep A. W (2010) Contrast-enhanced ultrasound versus computed tomographic angiography for surveillance of endovascular abdominal aortic aneurysm repair. Journal of vascular and interventional radiology: JVIR 21, 638-43									
Study type	Cross – sectional study									
Aim	Compare diagnostic accuracy between contrast-enhanced ultrasound and computed tomographic angiography to detect changes in AA size and endoleaks during follow-up after EVAR.									
Patient Characteristics	<p>Inclusion criteria: All patients who underwent EVAR for infrarenal AAA Exclusion criteria: Patients who could not undergo CT angiography as a result of severe iodinated contrast allergy or severe renal insufficiency</p> <table border="1"> <thead> <tr> <th colspan="2">Study Characteristics</th> </tr> </thead> <tbody> <tr> <td>Age</td> <td>71 years \pm 9</td> </tr> <tr> <td>Males (%)</td> <td>92%</td> </tr> <tr> <td>Aneurysm Size (\pmSD)</td> <td>Not reported</td> </tr> </tbody> </table>		Study Characteristics		Age	71 years \pm 9	Males (%)	92%	Aneurysm Size (\pm SD)	Not reported
Study Characteristics										
Age	71 years \pm 9									
Males (%)	92%									
Aneurysm Size (\pm SD)	Not reported									
Sample Size	83 patients									
Index test(s)	<p>CUES</p> <p>The routine surveillance regiment consisted of intravenous contrast enhanced CT scans at 3 and 12 months after procedure and yearly thereafter. During the study period, contrast enhanced US examinations were added to this regimen. US investigations were performed with an abdominal 3.5- MHz curved-array transducer. The examinations were performed by 3 well trained vascular technicians dedicated to US imaging, who were blinded to each other's findings and to the findings on CTA. An endoleak was identified on CEUS by flow and spectral signals within the aneurysm sac during infusion of sonographic contrast.</p>									
Reference standard(s)	<p>CTA</p> <p>Triple phase CTA was performed from the diaphragm to the common femoral arteries after continuous intravenous administration of iodinated contrast agent.</p>									
Study Details	<p>Study location: Netherlands Study setting: Department of Vascular Surgery Study dates: May 2006 and December 2008 Loss to follow-up: Not reported Time between testing & Treatment: 30 days</p>									

Full citation	Ten Bosch, Jan A, Rouwet Ellen V, Peters Cecile T. H, Jansen Linda, Verhagen Hence J. M, Prins Martin H, and Teijink Joep A. W (2010) Contrast-enhanced ultrasound versus computed tomographic angiography for surveillance of endovascular abdominal aortic aneurysm repair. Journal of vascular and interventional radiology: JVIR 21, 638-43
	Source of funding: Not specified
Quality Assessment (QUADAS 2)	Patient selection: Low risk of bias Index test: Low risk of bias Reference standard: Unclear risk of bias. – Unclear if CTA results were interpreted without knowledge of CEUS. Flow and timing: Low risk of bias Overall risk of bias: Moderate risk of bias Directness: directly applicable

Full citation	Wolf Y G, Johnson B L, Hill B B, Rubin G D, Fogarty T J, and Zarins C K (2000) Duplex ultrasound scanning versus computed tomographic angiography for postoperative evaluation of endovascular abdominal aortic aneurysm repair. Journal of vascular surgery 32, 1142-8
Study type	Cross-sectional study
Aim	Compare duplex ultrasound scanning and computed tomography (CT) angiography for postoperative imaging and surveillance after endovascular repair of AAA.
Patient Characteristics	Inclusion criteria: Patients who underwent endovascular repair of AAA with the AneuRx (Medtronic) bifurcated endograft. Exclusion criteria: Not reported Patient characteristics: Not reported
Sample Size	100
Index test(s)	CDUS Follow-up protocol included CT angiography before discharge, duplex scan at 1 month, and CT angiography at 6 months, 1 year and yearly thereafter. All duplex scans were obtained after the patients fasted for 6 hours and were performed by a registered vascular technologist proficient in both vascular and abdominal imaging. Vascular technologist was not aware of CT scan results. An internally standardised duplex scanning protocol was used for assessing the abdominal aorta. All duplex scans were reviewed by a vascular surgeon.
Reference standard(s)	CTA Helical CT was performed with either a CTi single detector-row or a Lightspeed QXi multi detector-row CT scanner. In addition to a formal reading by a radiologist who was unaware of the duplex scans result, CT angiograms were reviewed by a panel of radiologists and vascular surgeons to confirm the presence or absence of an endoleak.
Study Details	Study location: Stanford, USA Study setting: Stanford University Hospital Study dates: October 1996 to May 1999 Loss to follow-up: Not reported Time between testing & Treatment: Where possible, CT and duplex scans were conducted within 7 days from each other. Source of funding: Not specified
Quality Assessment (QUADAS 2)	Patient selection: Low risk of bias Index test: Unclear risk of bias – Definition of endoleak not stated

Full citation	Wolf Y G, Johnson B L, Hill B B, Rubin G D, Fogarty T J, and Zarins C K (2000) Duplex ultrasound scanning versus computed tomographic angiography for postoperative evaluation of endovascular abdominal aortic aneurysm repair. Journal of vascular surgery 32, 1142-8
	Reference standard: Low risk of bias Flow and timing: Unclear – CT and CDUS performed within 7 days in only 76 patients. Overall risk of bias: Moderate risk of bias Directness: Partially indirect. Although the protocol specifies that studies published after 2000 should be included, the committee were interested in studies in which patients received scans before this cut-off. As this study was conducted between 1996 and 1999, the study was downgraded for partial indirectness.

Full citation	Zannetti S, De Rango, P , Parente B, Parlani G, Verzini F, Maselli A, Nardelli L, and Cao P (2000) Role of duplex scan in endoleak detection after endoluminal abdominal aortic aneurysm repair. European journal of vascular and endovascular surgery : the official journal of the European Society for Vascular Surgery 19, 531-5									
Study type	Cross sectional study									
Aim	To validate the role of Duplex scan in endoleak detection in postoperative surveillance of endoluminal abdominal aneurysm repair.									
Patient Characteristics	<p>Inclusion criteria: Patients undergoing EVAR Exclusion criteria: Conversion to open repair Duplex scan performed in a different centre in patients from out of town Patient refusal Patients with renal insufficiency Patients in need of a different imaging technique (I.e. angiography in patients subjected to adjunctive peripheral revascularisation) Inadequate duplex visualisation of the AAA sac due to obesity or intestinal gas.</p> <table border="1"> <thead> <tr> <th colspan="2">Study Characteristics</th> </tr> </thead> <tbody> <tr> <td>Mean Age</td> <td>70.1 ±6.7 years</td> </tr> <tr> <td>Males (%)</td> <td>91%</td> </tr> <tr> <td>Aneurysm Size (±SD)</td> <td>50.2 ± 8.3 mm</td> </tr> </tbody> </table>		Study Characteristics		Mean Age	70.1 ±6.7 years	Males (%)	91%	Aneurysm Size (±SD)	50.2 ± 8.3 mm
Study Characteristics										
Mean Age	70.1 ±6.7 years									
Males (%)	91%									
Aneurysm Size (±SD)	50.2 ± 8.3 mm									
Sample Size	103 patients									
Index test(s)	CDUS CDUS was performed with an ATL 3000 HDI system (Advanced Technology Laboratory) with a C4-2 MHz curved array transducer. Low frequencies were used and colour Doppler settings were optimised to avoid excessive overgain (i.e. colour artefacts to may fill the colour box) or undergain (i.e. absence of colour flow within the aortic graft). The entire AAA sac, proximal and distal necks, the aorta, iliac and femoral arteries were systematically imaged and measurements were performed on both sagittal and transverse views. The presence of perigraft endoleaks was suspected when a reproducible colour signal outside the endograft and within the aneurysmal sac was visualised. All suspected endoleaks were further evaluated with the Doppler signal to avoid colour artefacts. When the presence of both the Doppler and colour signal outside the endograft and within the aneurysmal sac were observed, the location, flow direction, and extent of AAA sac involvement were recorded. Two vascular surgeons performed all duplex-scan examinations.									
Reference standard(s)	CTA									

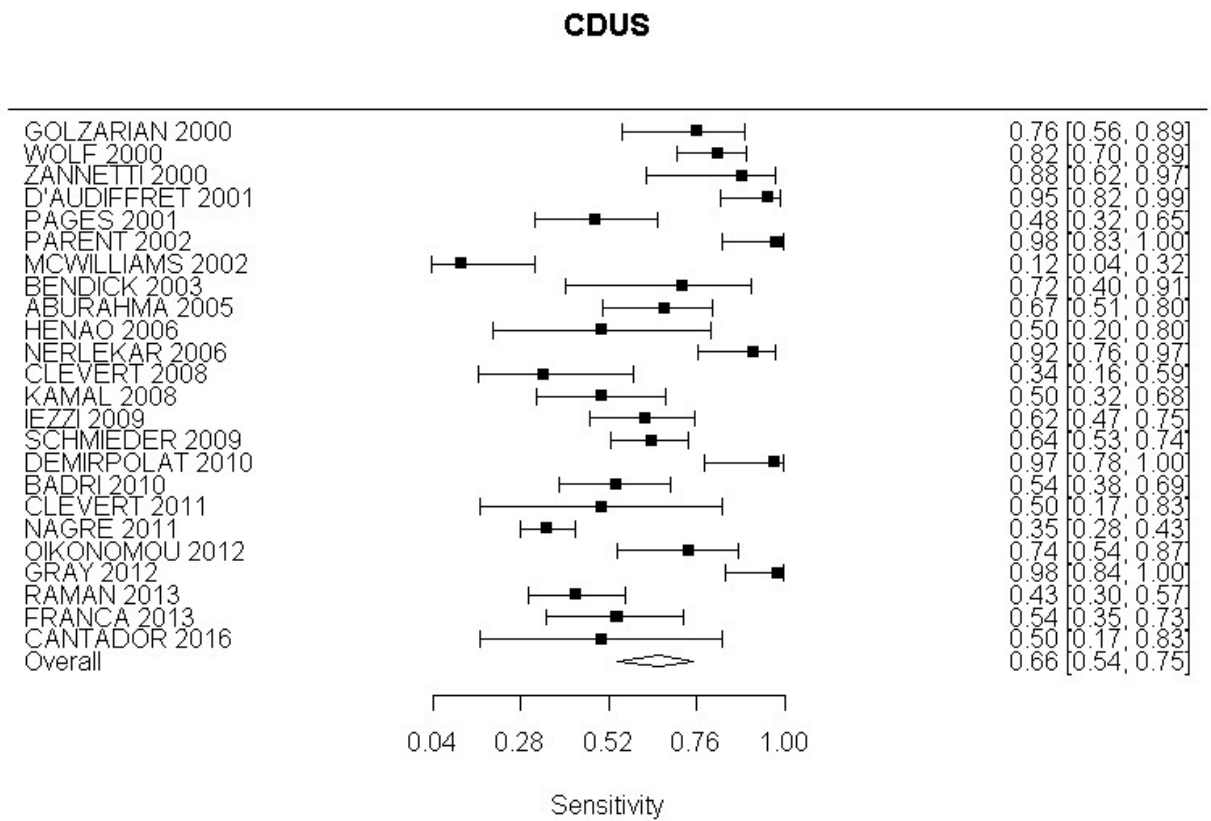
Full citation	Zannetti S, De Rango, P , Parente B, Parlani G, Verzini F, Maselli A, Nardelli L, and Cao P (2000) Role of duplex scan in endoleak detection after endoluminal abdominal aortic aneurysm repair. European journal of vascular and endovascular surgery : the official journal of the European Society for Vascular Surgery 19, 531-5
	Contrast enhanced CT scan was considered the gold standard in endoleak detection and classification. All CT scans were centrally reviewed by the same vascular surgeon who established the presence or absence of endoleak. Endoleak was diagnosed in the presence, in the axial reconstruction, of contrast outside the lumen of the endoluminal graft and within aneurysmal sac. Medium contrast within the aneurysmal sac that appeared in continuity with the proximal or distal implant zones were interpreted as a graft-related endoleak, whereas a small amount of contrast medium near the entry of a patent inferior mesenteric or lumbar artery, implying retrograde flow, was interpreted as a non-graft related endoleak. The interpretation of all colour duplex and CT scans was blinded to all concurrent and prior studies.
Study Details	<p>Study location: Perugia, Italy</p> <p>Study setting: Unit of Vascular Surgery</p> <p>Study dates: April 1997 and March 1999</p> <p>Loss to follow-up: Major complication occurred in six patients and included a non-disabling stroke during a secondary endovascular procedure, occlusion of the endograft limb, renal infarction due to covering of the right renal artery by the endograft treated with nephrectomy, asymptomatic occlusion of a renal artery, and intraoperative rupture of a common iliac artery. Late death occurred in 3 patients and was caused by pulmonary embolism in a patient undergoing hip replacement, by cancer and by myocardial infarction.</p> <p>Time between testing & Treatment: Not specified</p> <p>Source of funding: Not specified</p>
Quality Assessment (QUADAS 2)	<p>Patient selection: Low risk of bias</p> <p>Index test: Low risk of bias</p> <p>Reference standard: Low risk of bias</p> <p>Flow and timing: Unclear risk of bias- interval between index test and reference standard not specified</p> <p>Overall risk of bias: Moderate risk of bias</p> <p>Directness: Partially indirect. Although the protocol specifies that studies published after 2000 should be included, the committee were interested in studies in which patients received scans before this cut-off. As this study was conducted between 1997 and 1999, the study was downgraded for partial indirectness.</p>

Appendix E – Forest plots

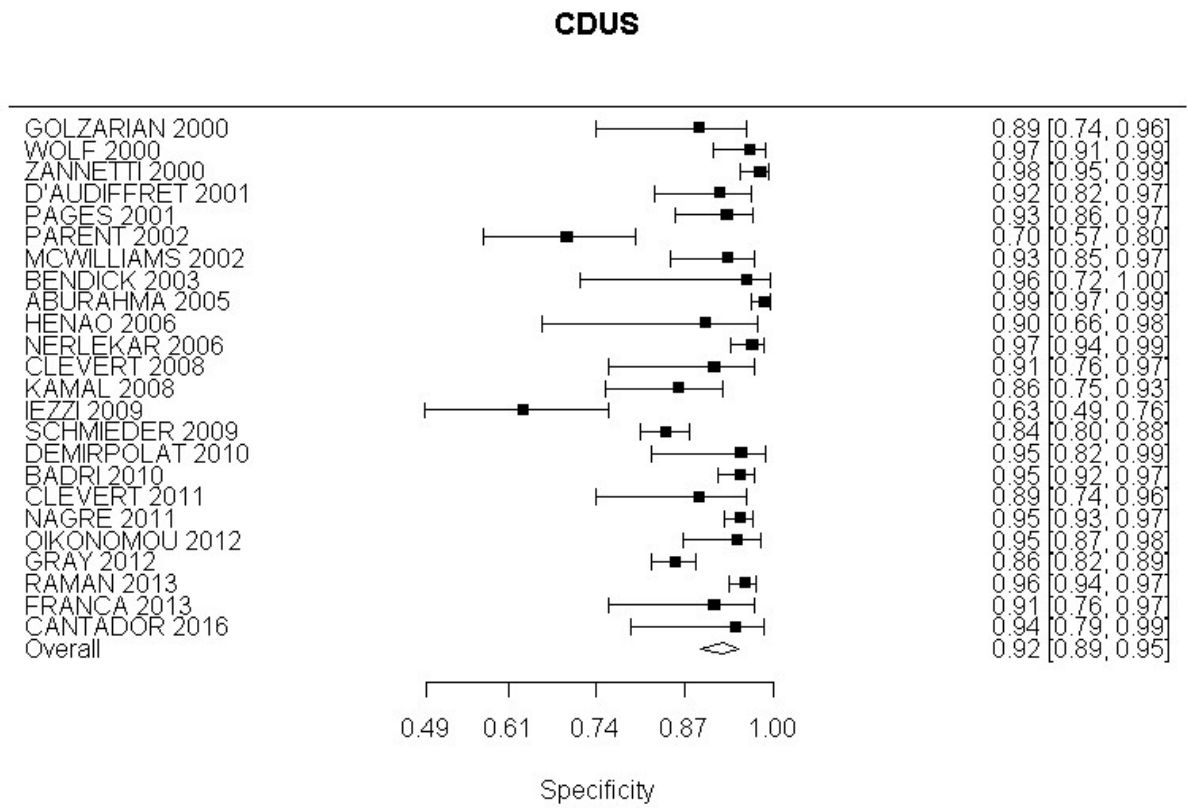
CDUS compared with angiography in the identification of endoleak

All endoleaks

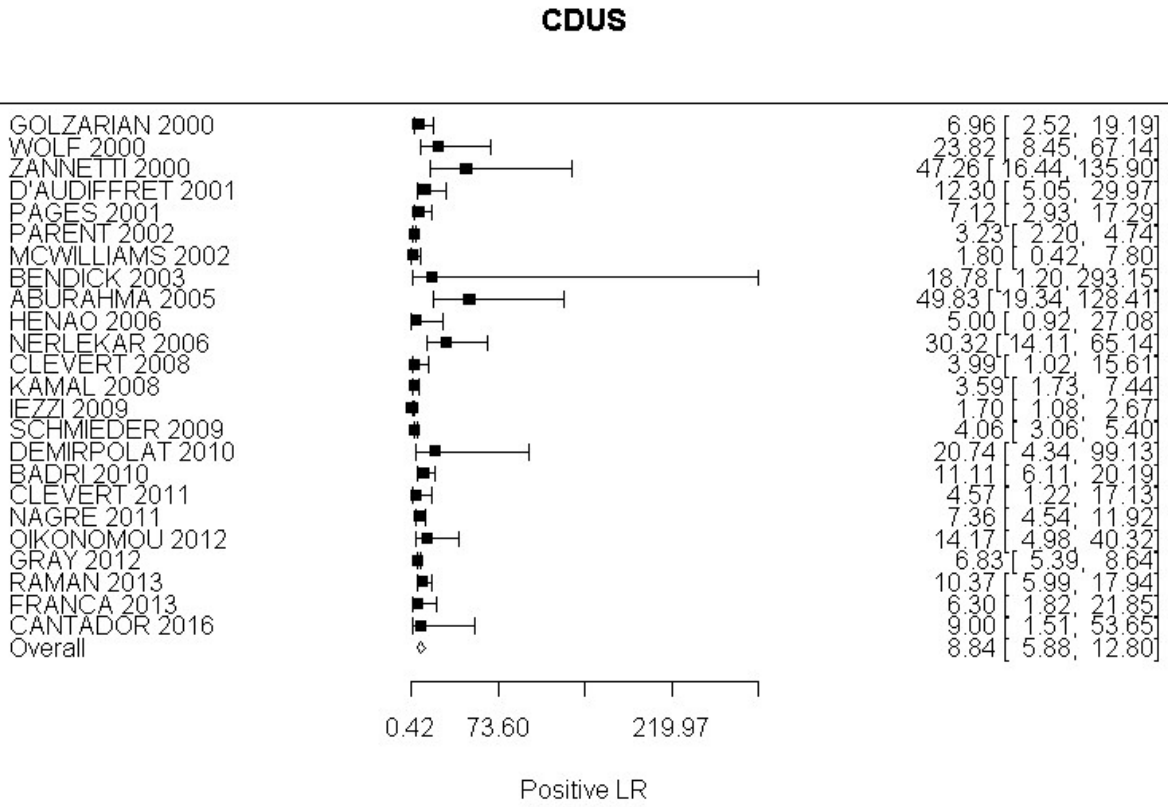
Sensitivity



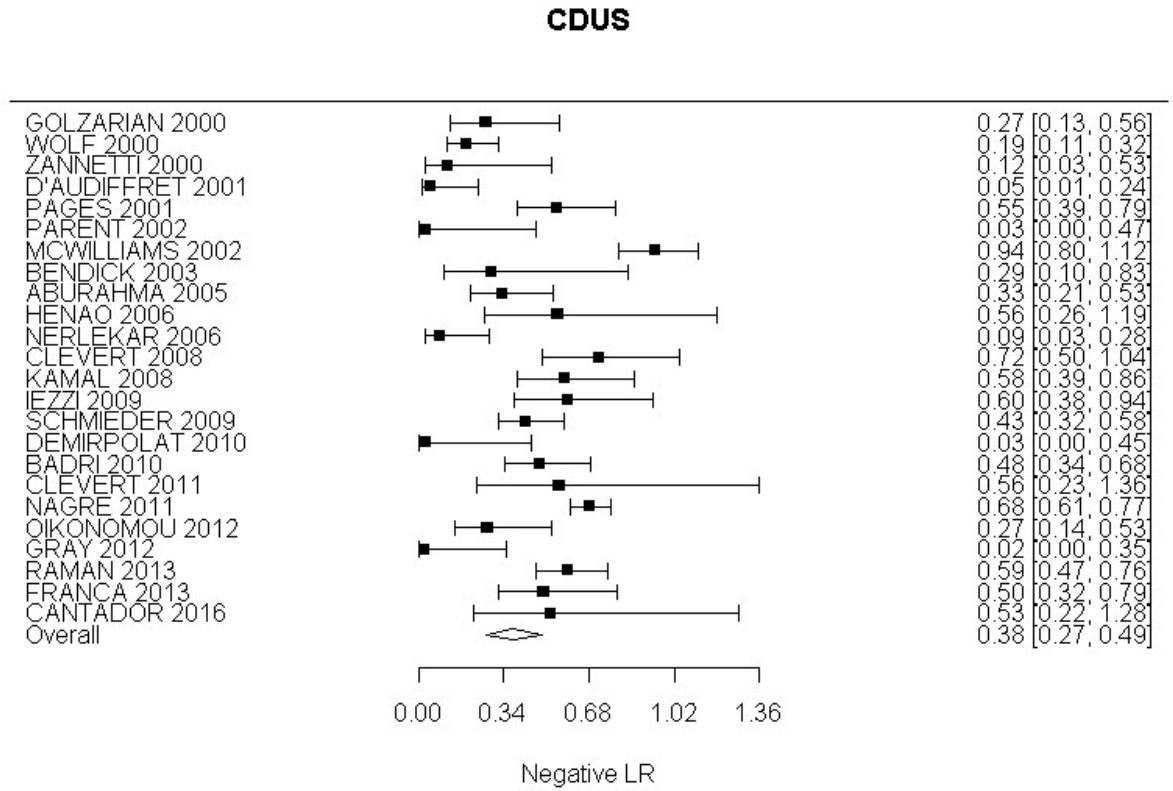
Specificity

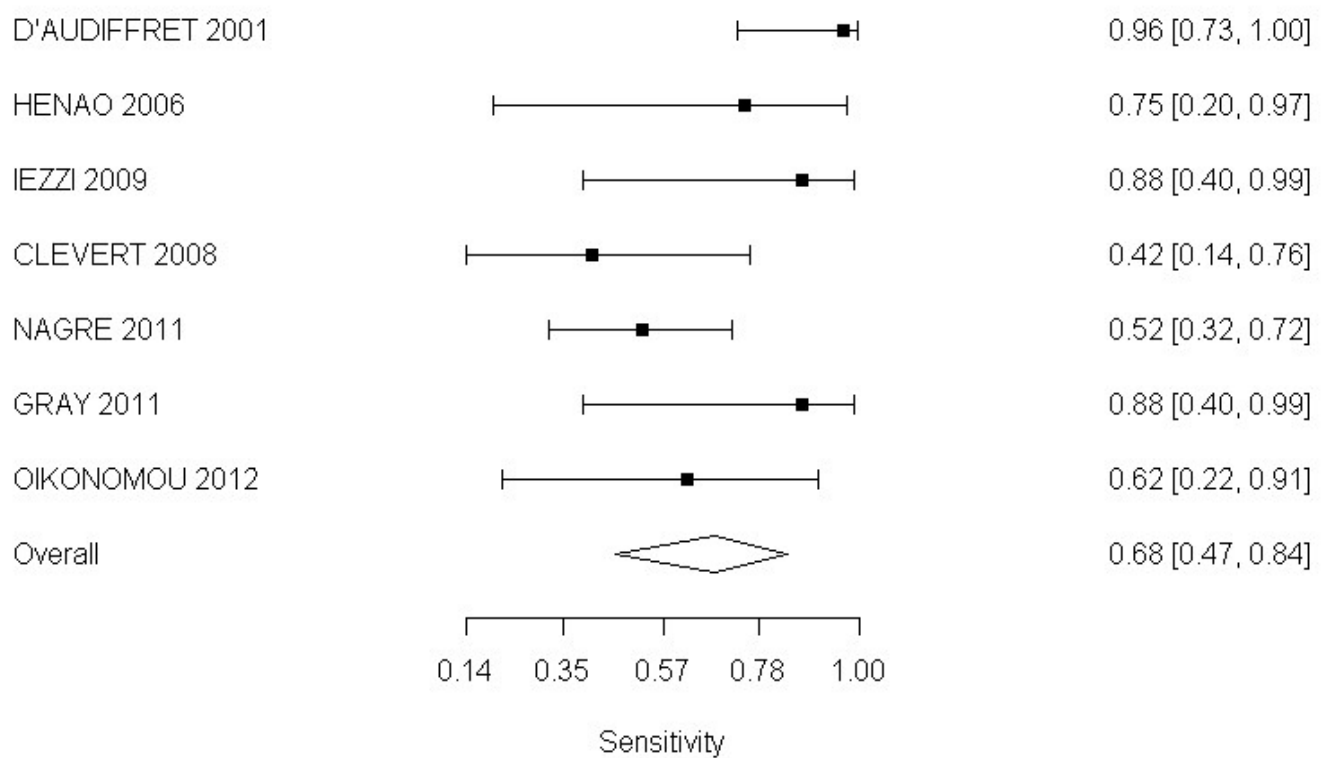


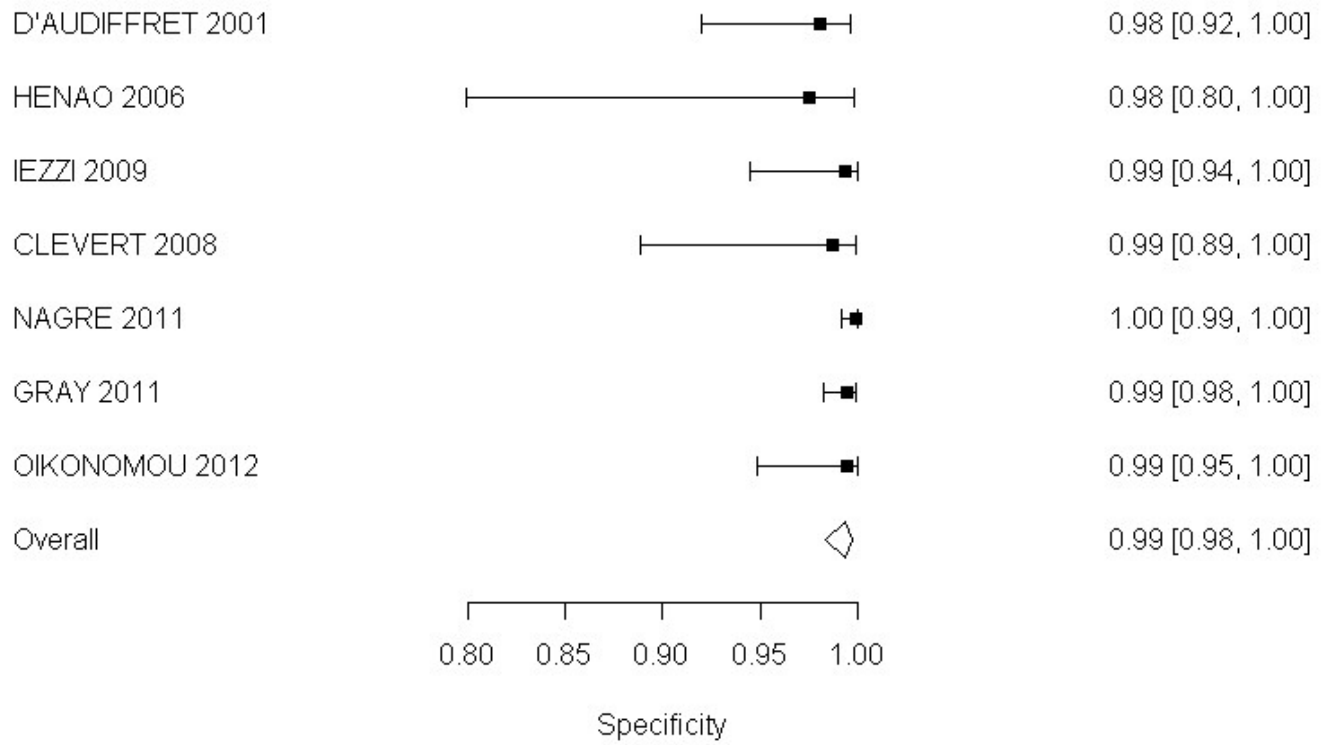
Positive Likelihood Ratio

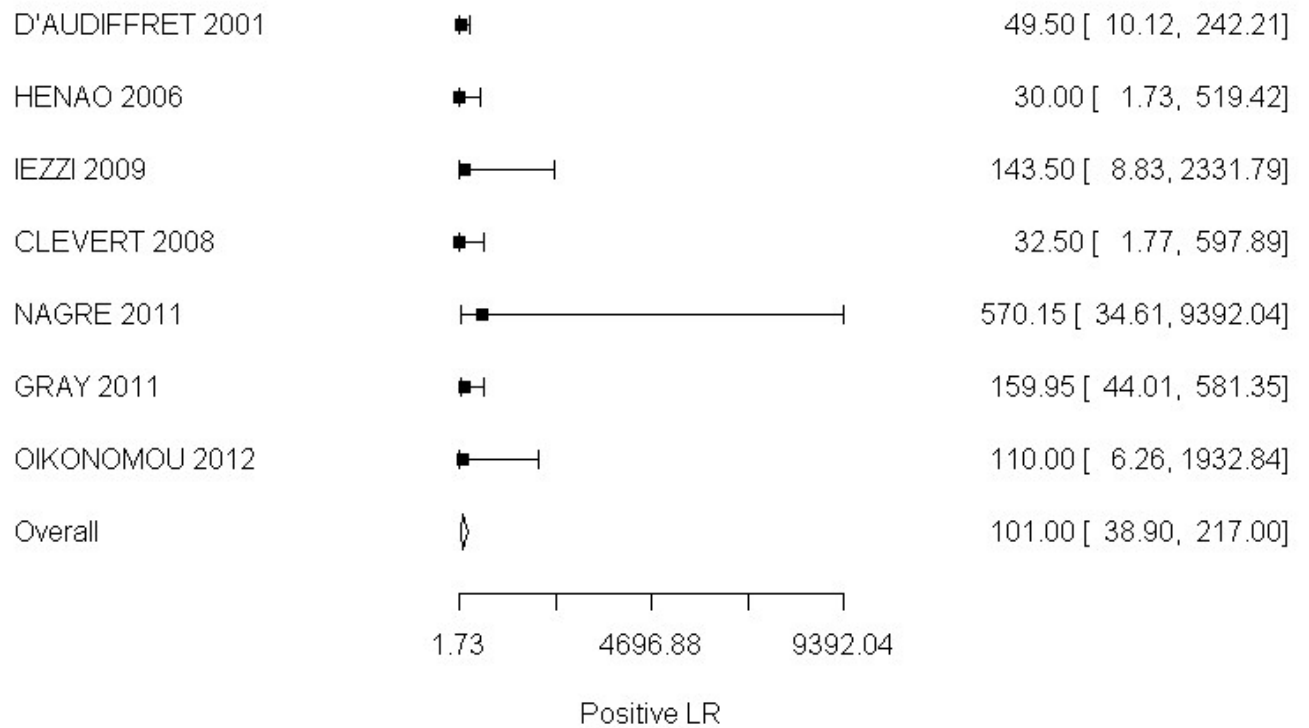


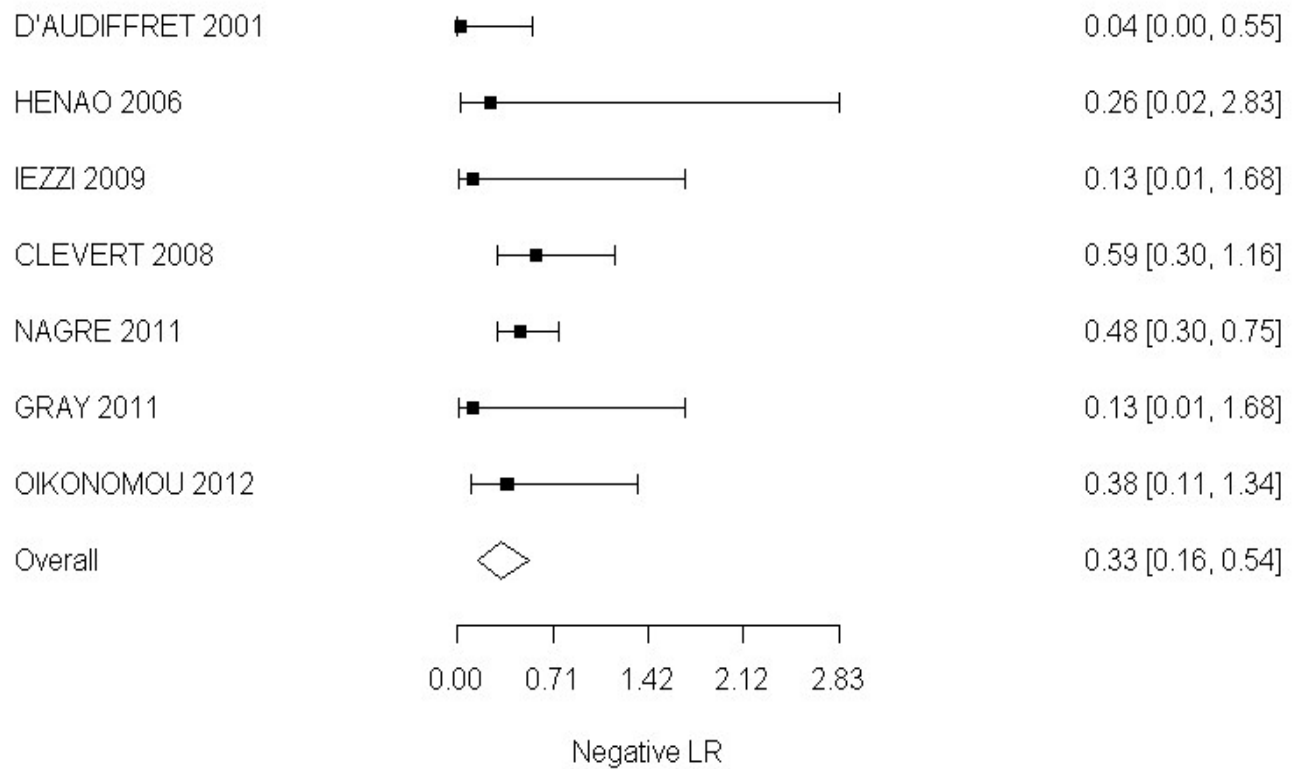
Negative Likelihood Ratio



Type I and III endoleaks**Sensitivity****CDUS**

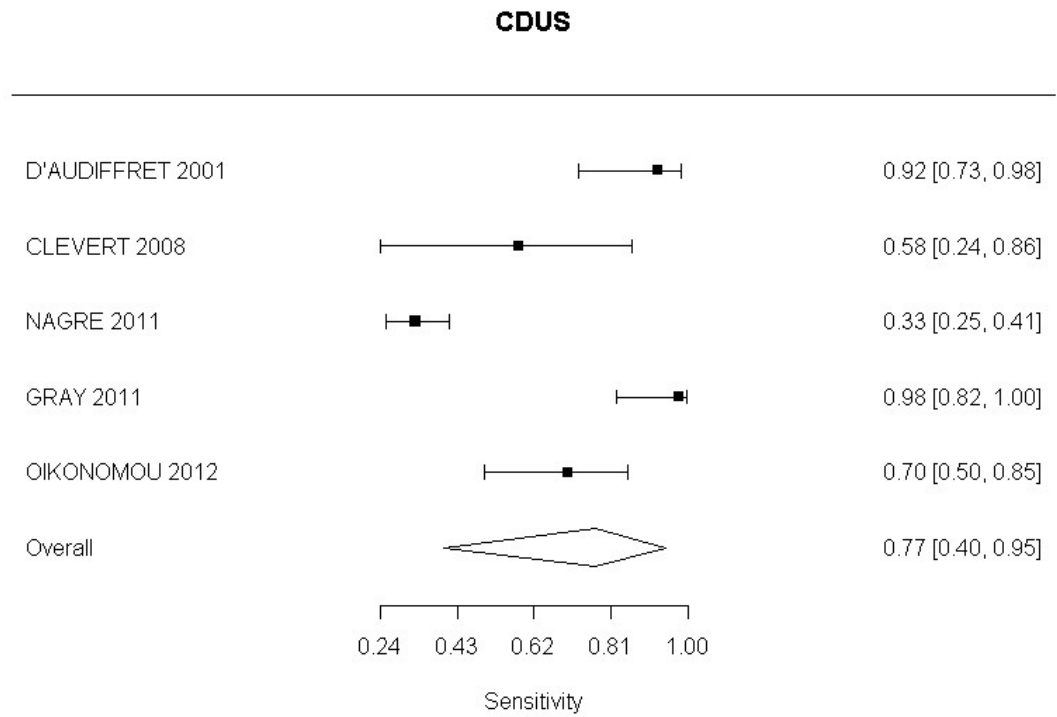
Specificity**CDUS**

Positive Likelihood Ratio**CDUS**

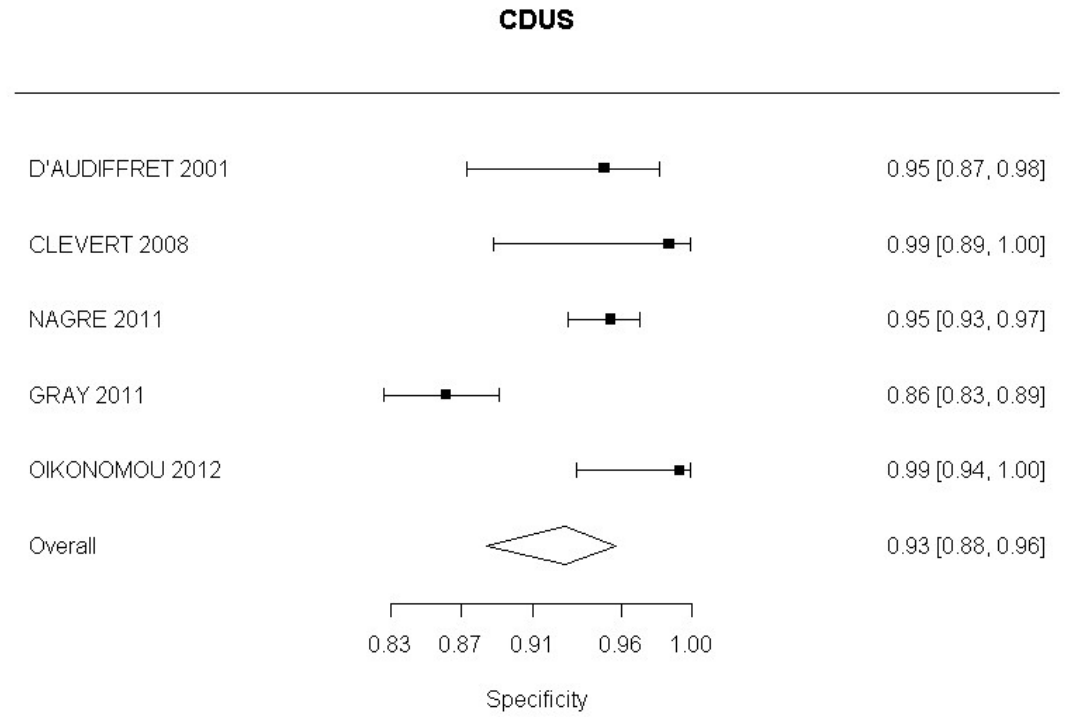
Negative Likelihood Ratio**CDUS**

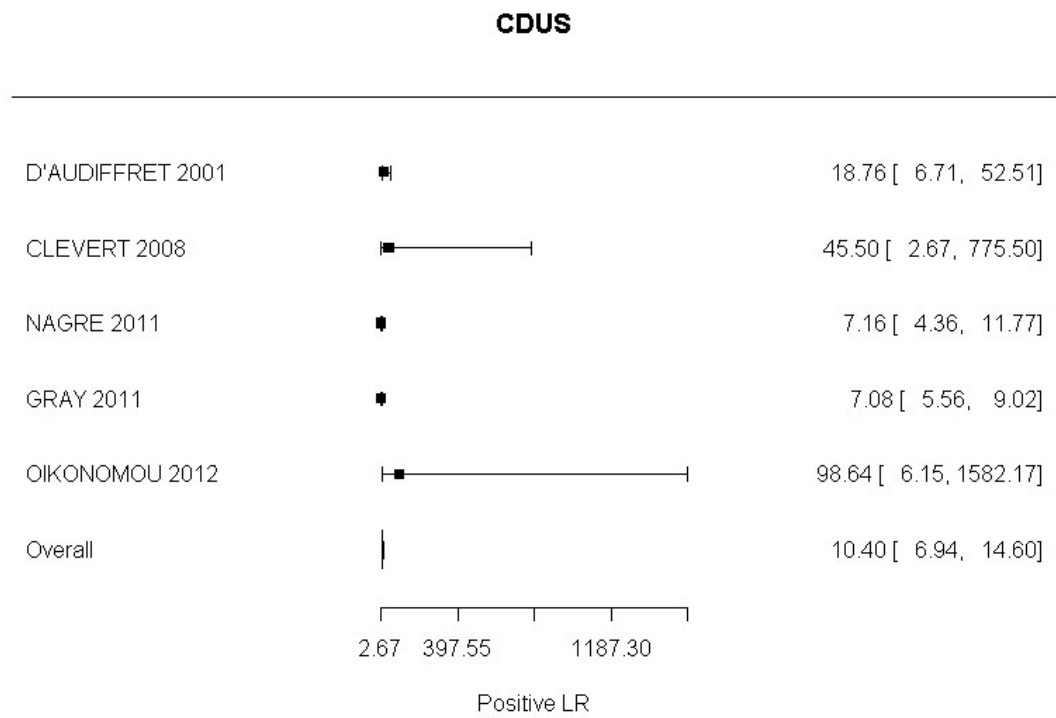
Type II endoleak

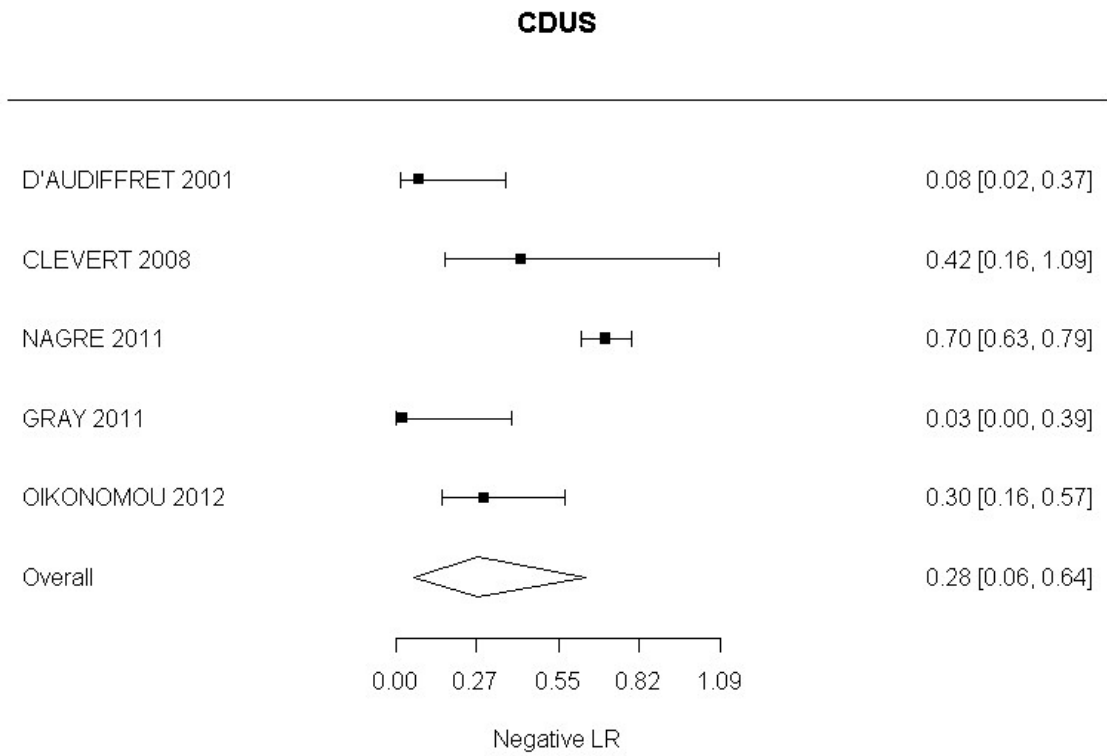
Sensitivity



Specificity

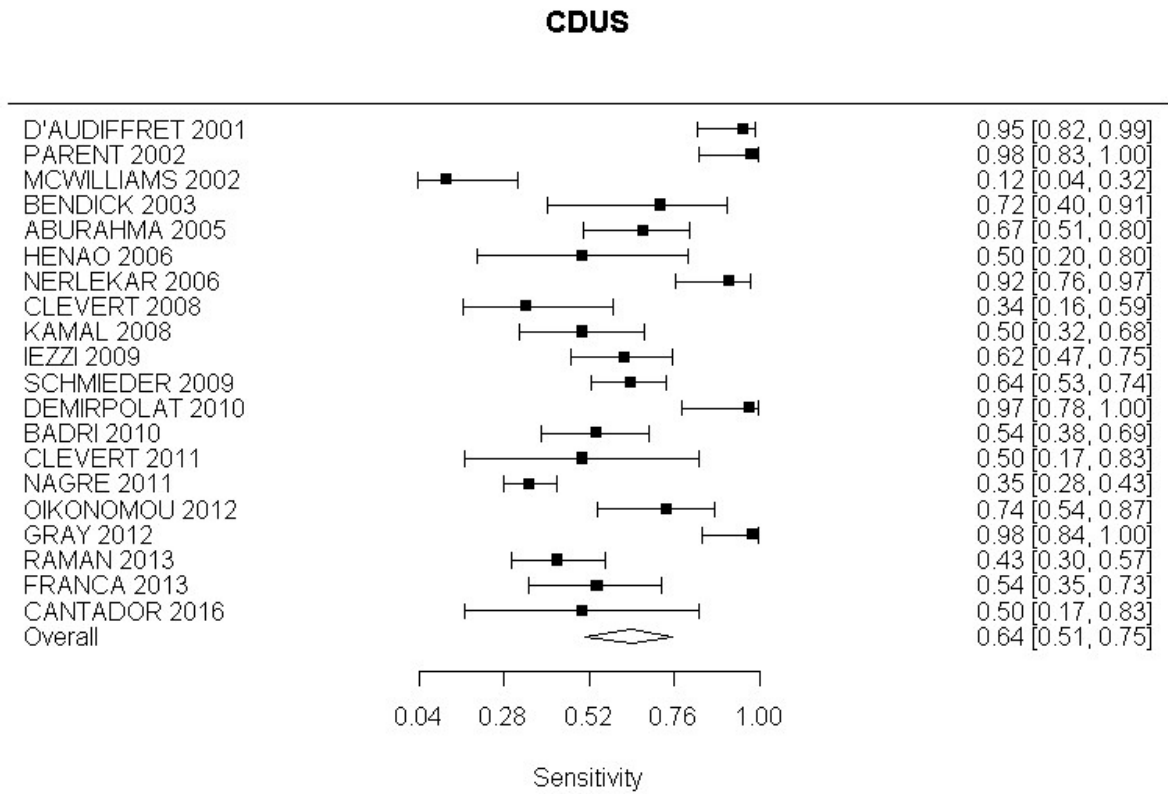


Positive Likelihood Ratio

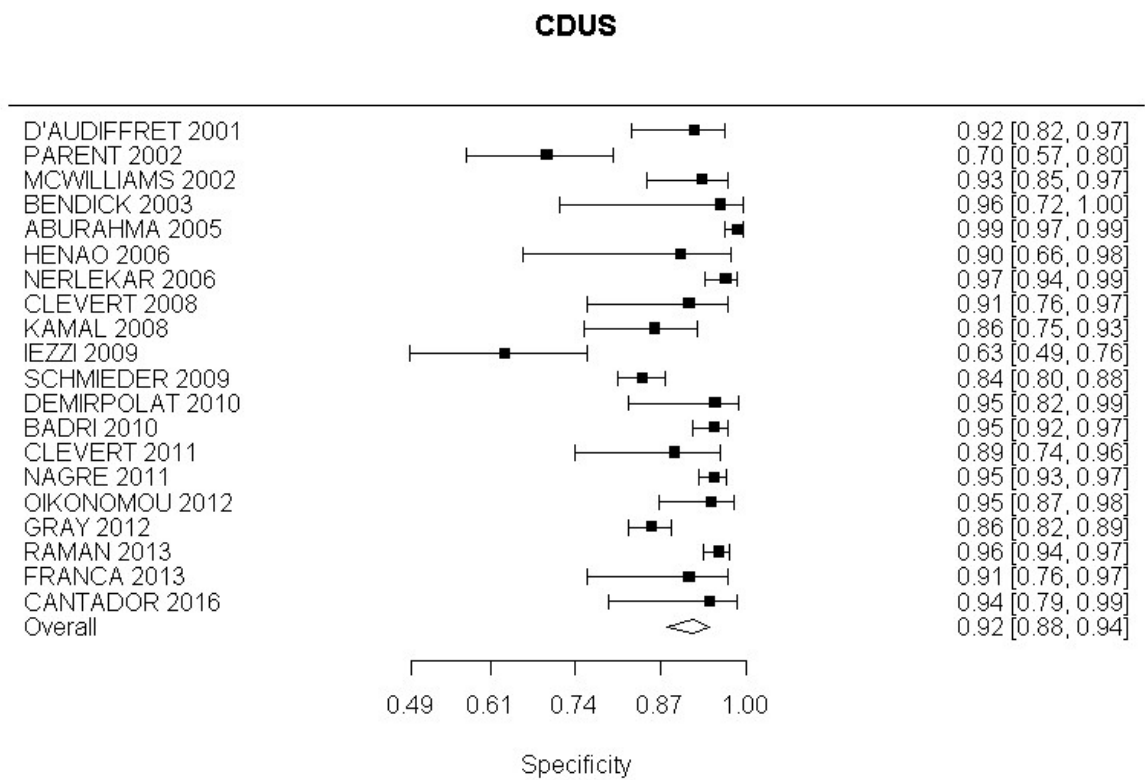
Negative Likelihood Ratio

Sensitivity Analysis: CDUS compared to angiography in detection of change in aneurysm size

Sensitivity

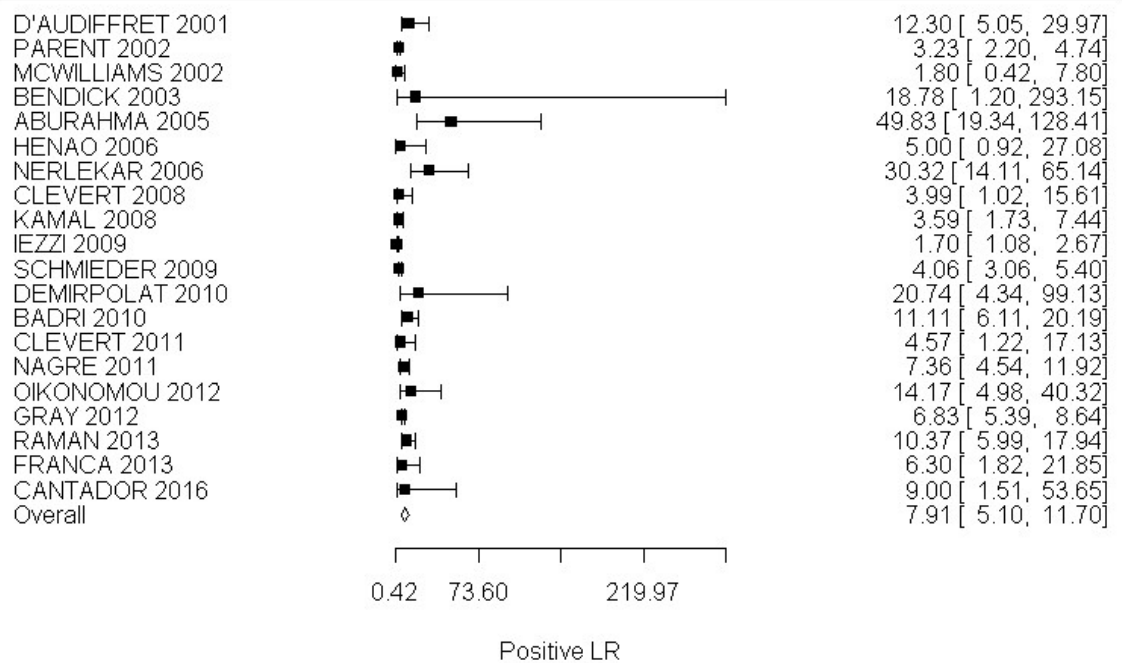


Specificity



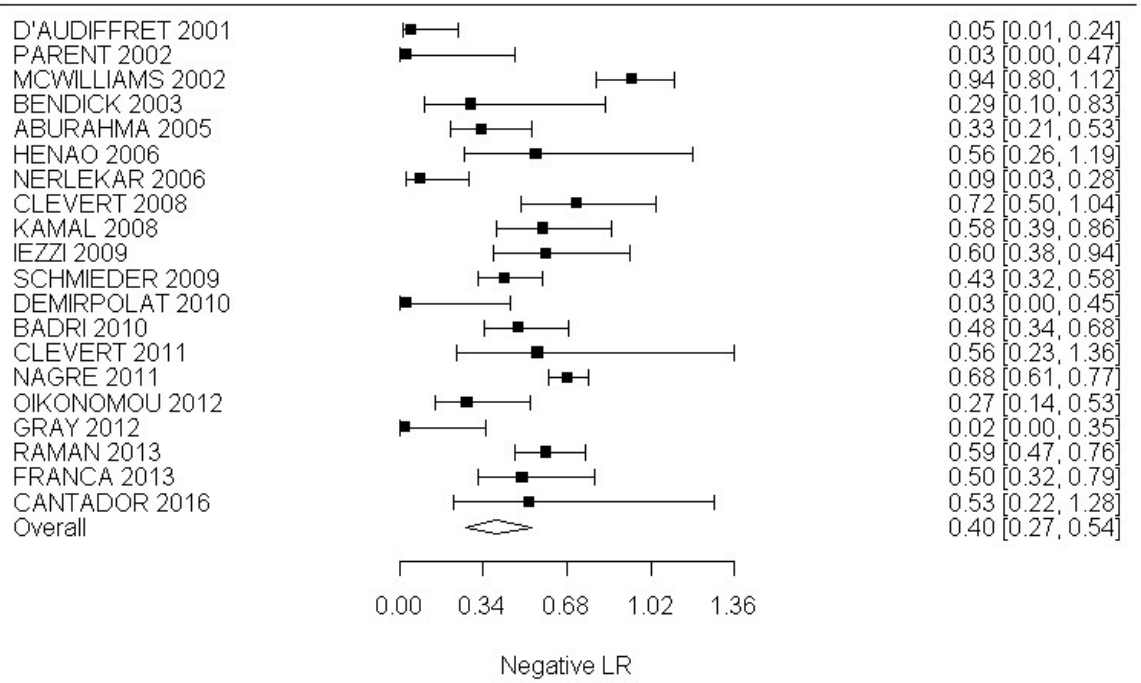
Positive Likelihood Ratio

CDUS



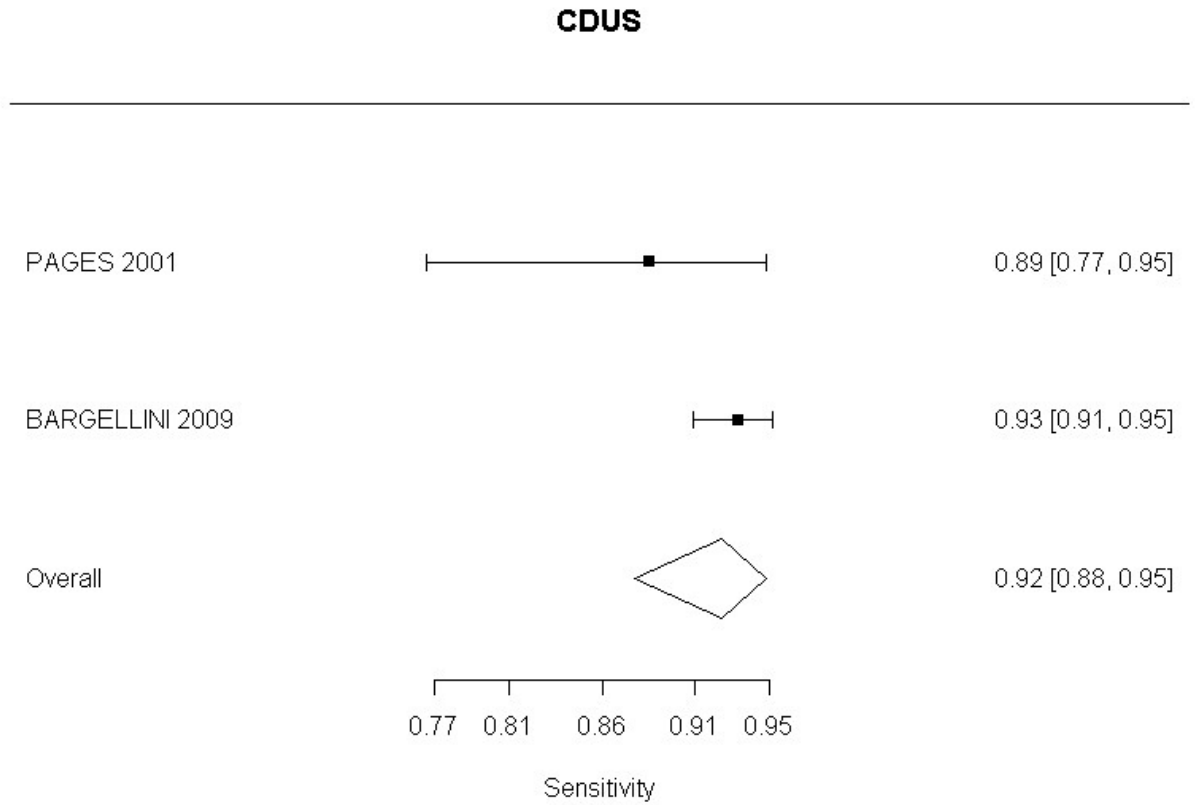
Negative Likelihood Ratio

CDUS



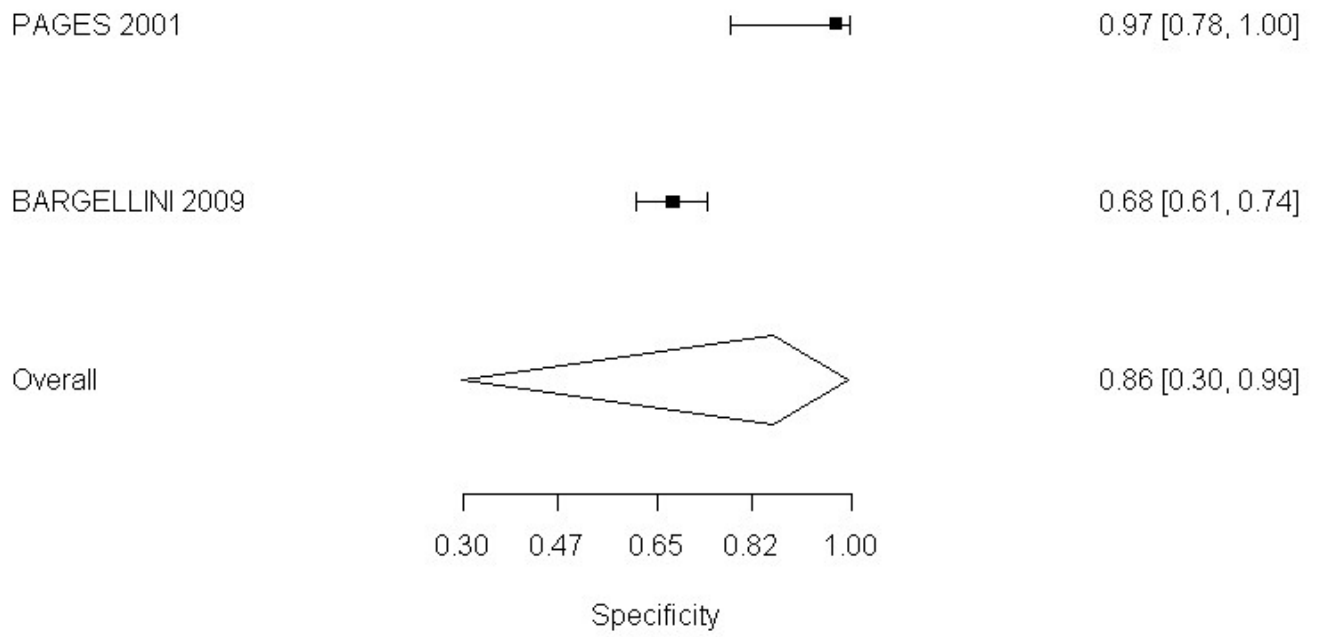
CDUS compared to angiography in detection of change in aneurysm size

Sensitivity



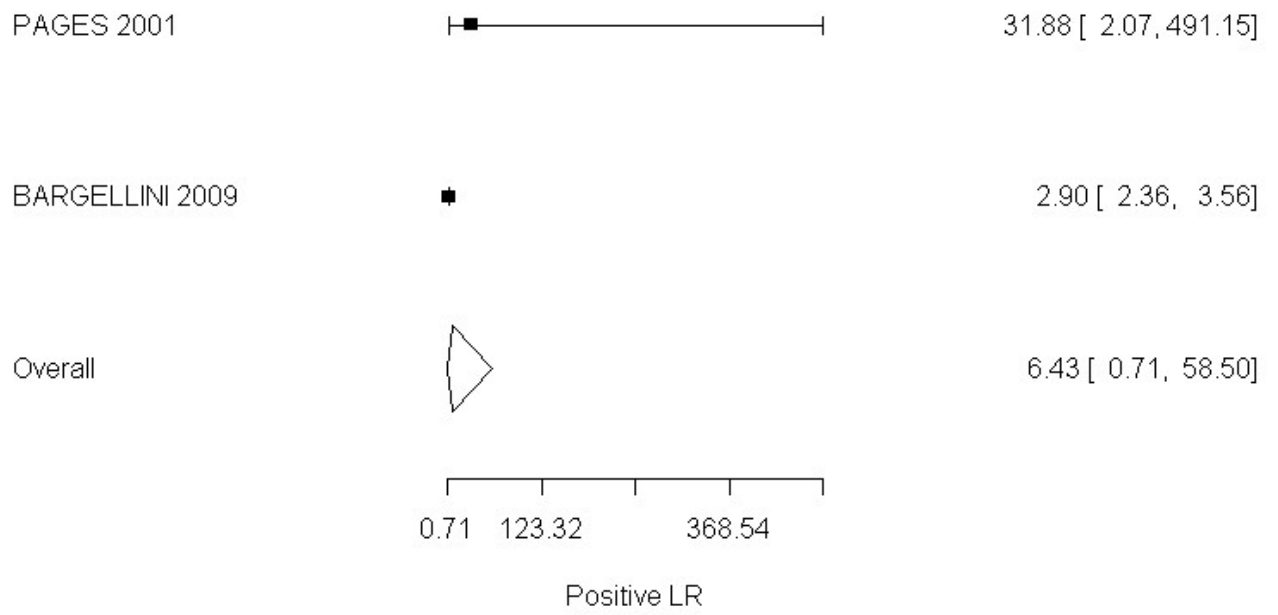
Specificity

CDUS



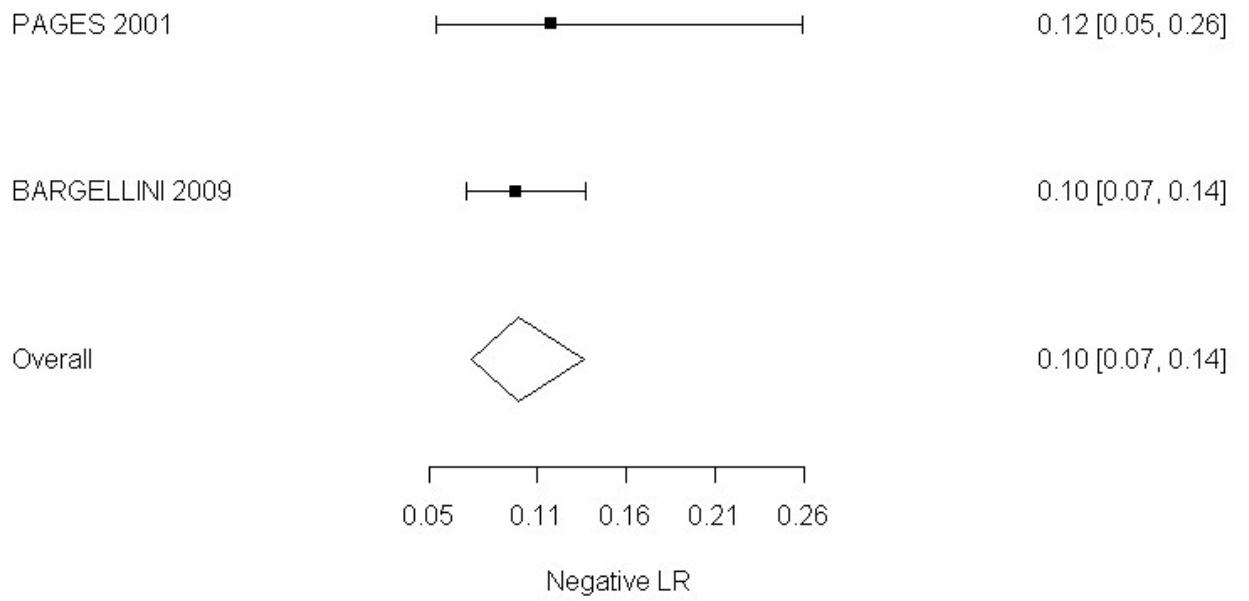
Positive Likelihood Ratio

CDUS



Negative Likelihood Ratio

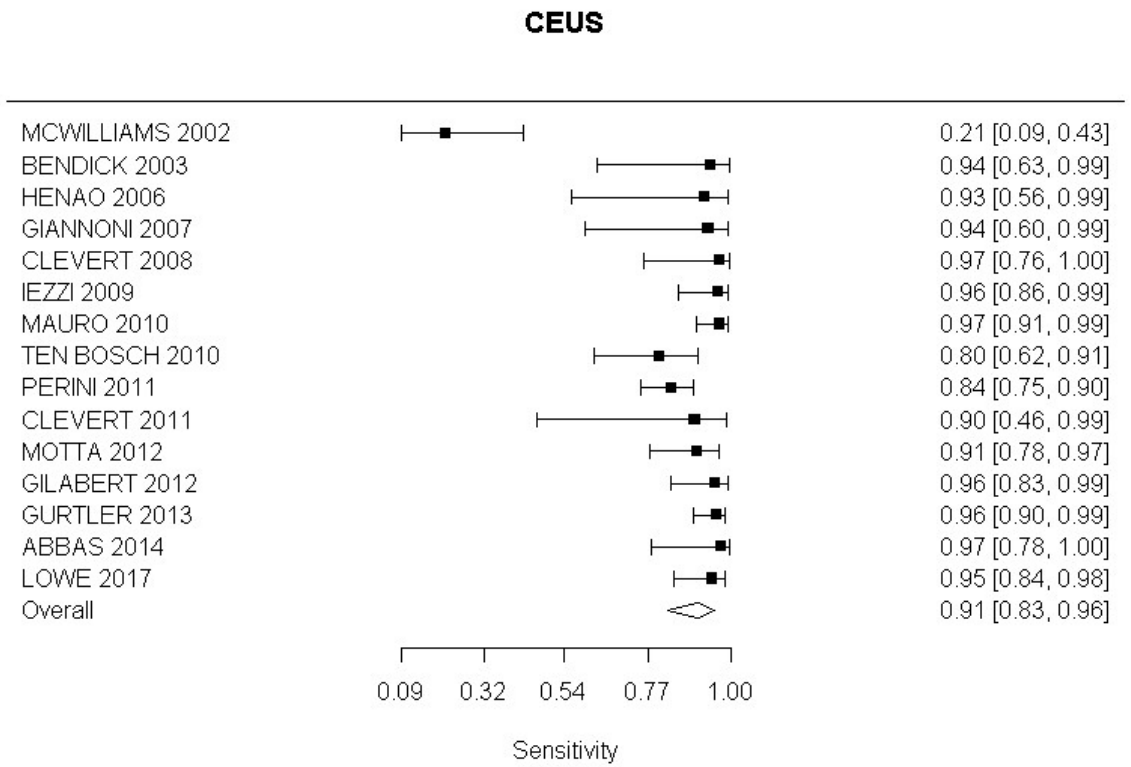
CDUS

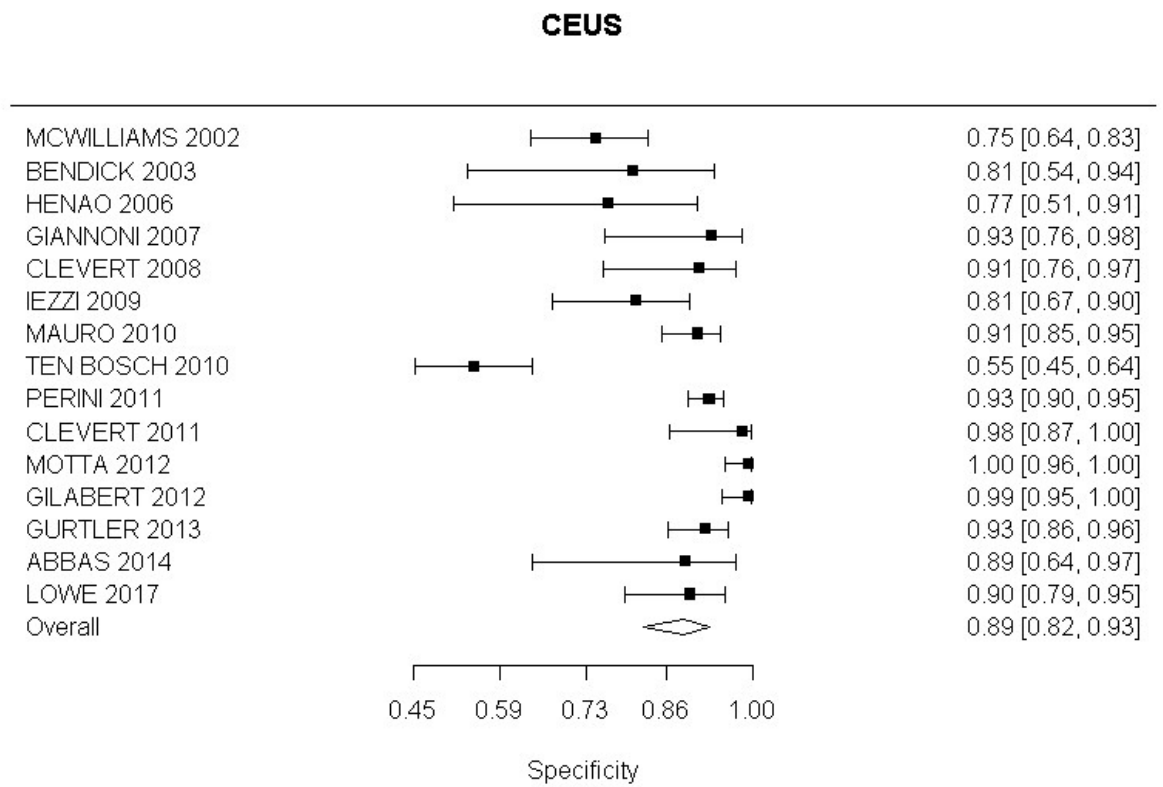


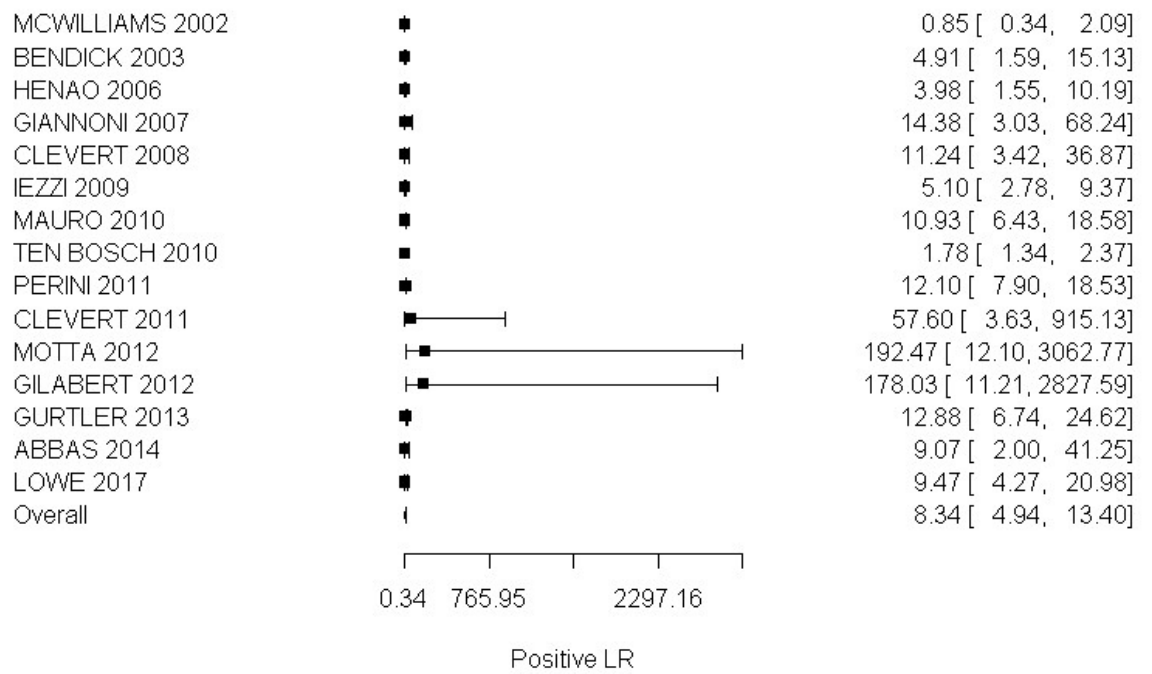
CEUS compared with angiography in the identification of endoleak

All endoleaks

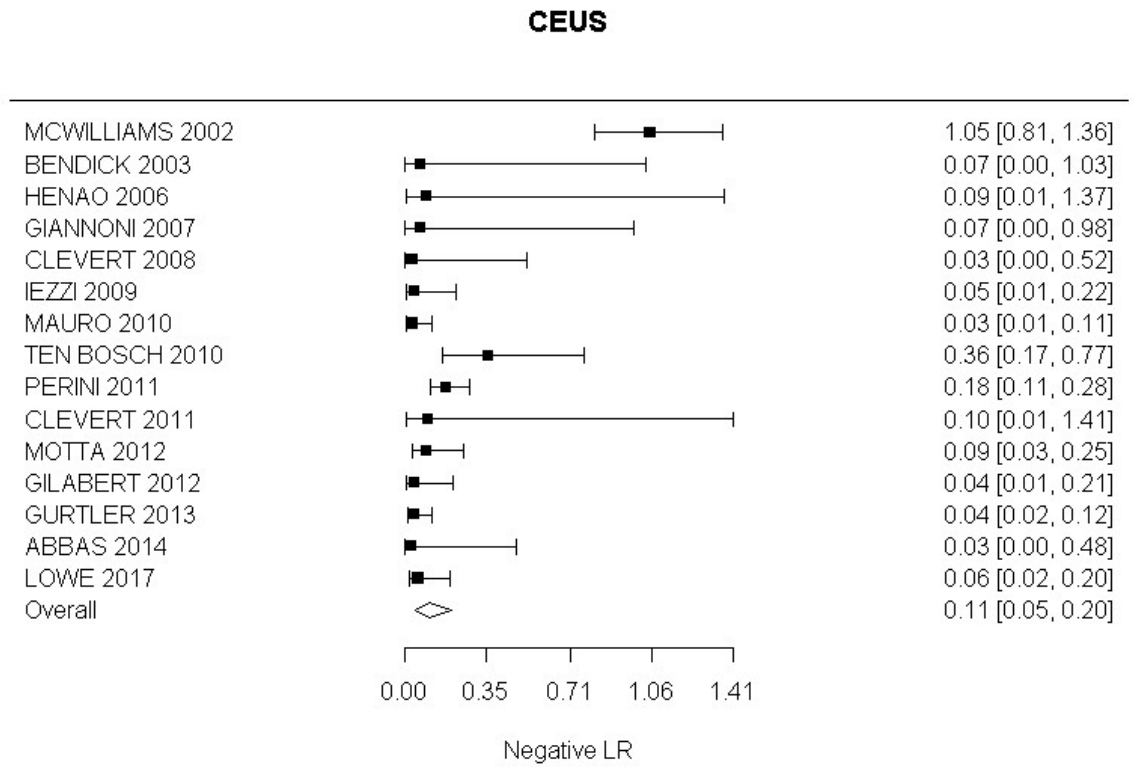
Sensitivity

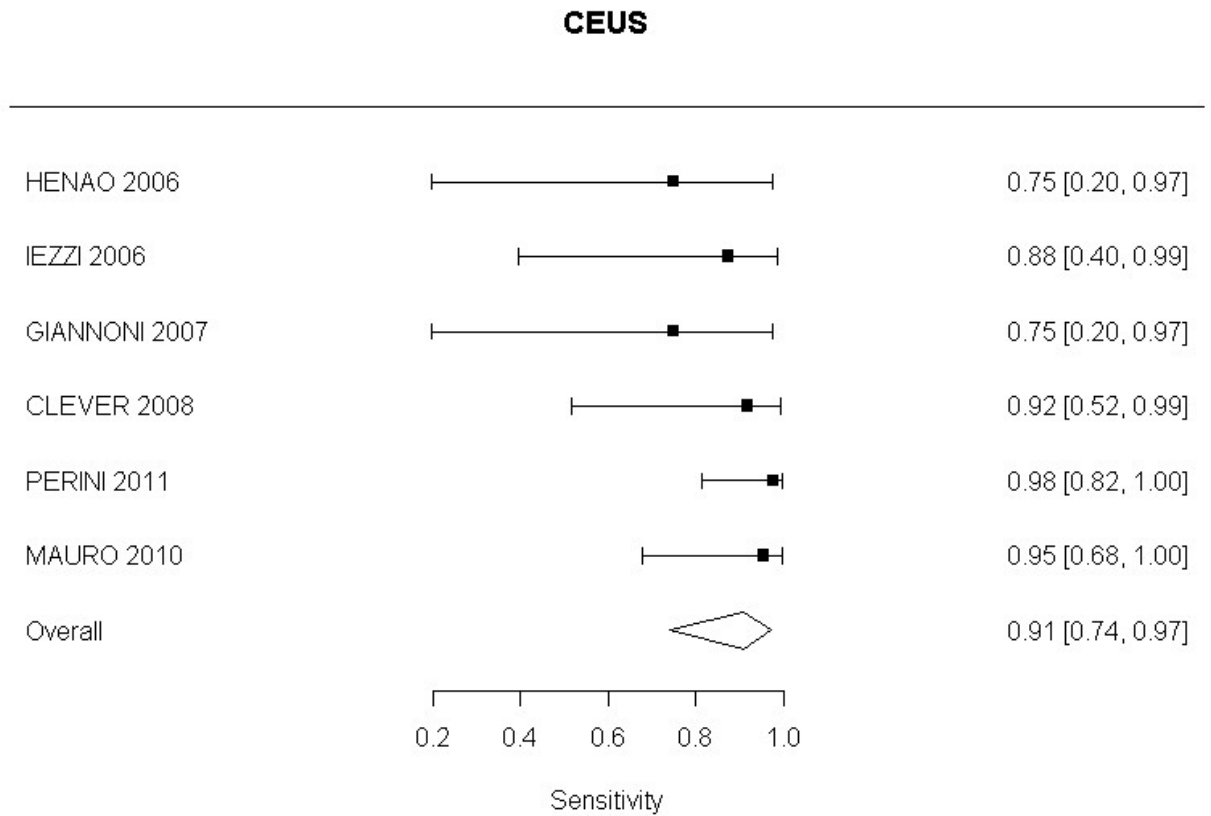


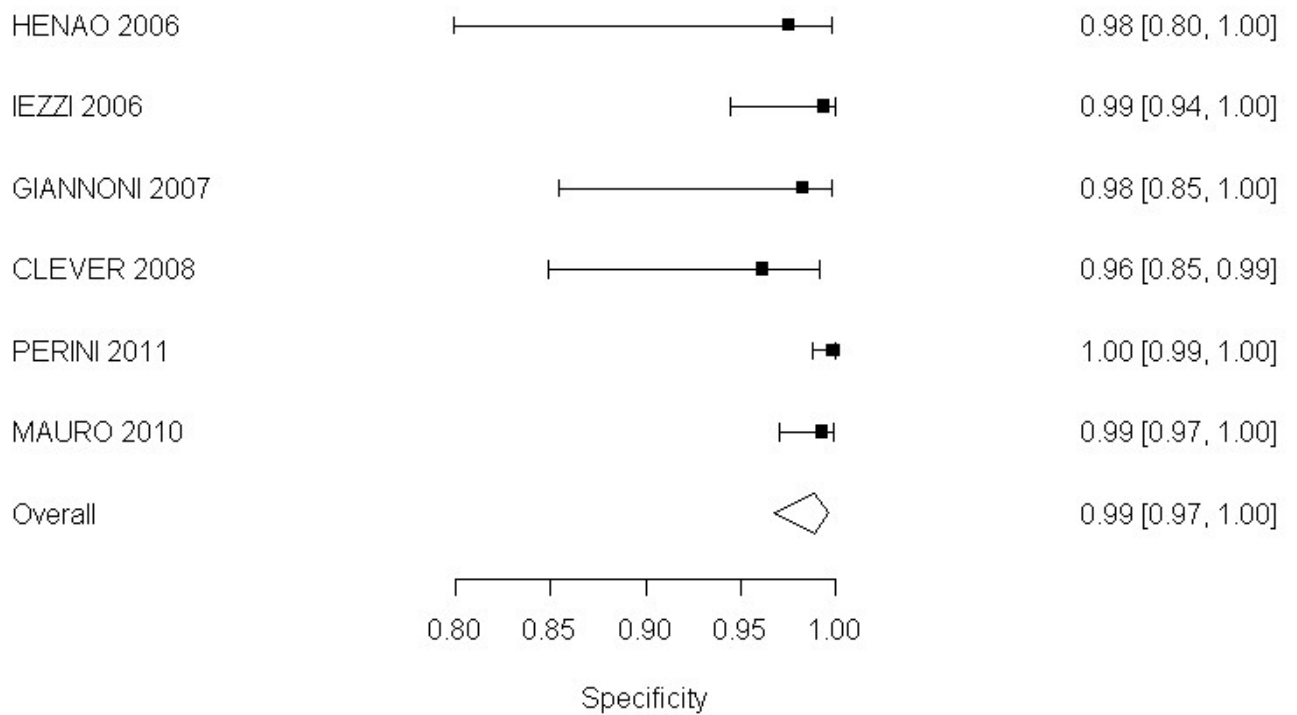
Specificity

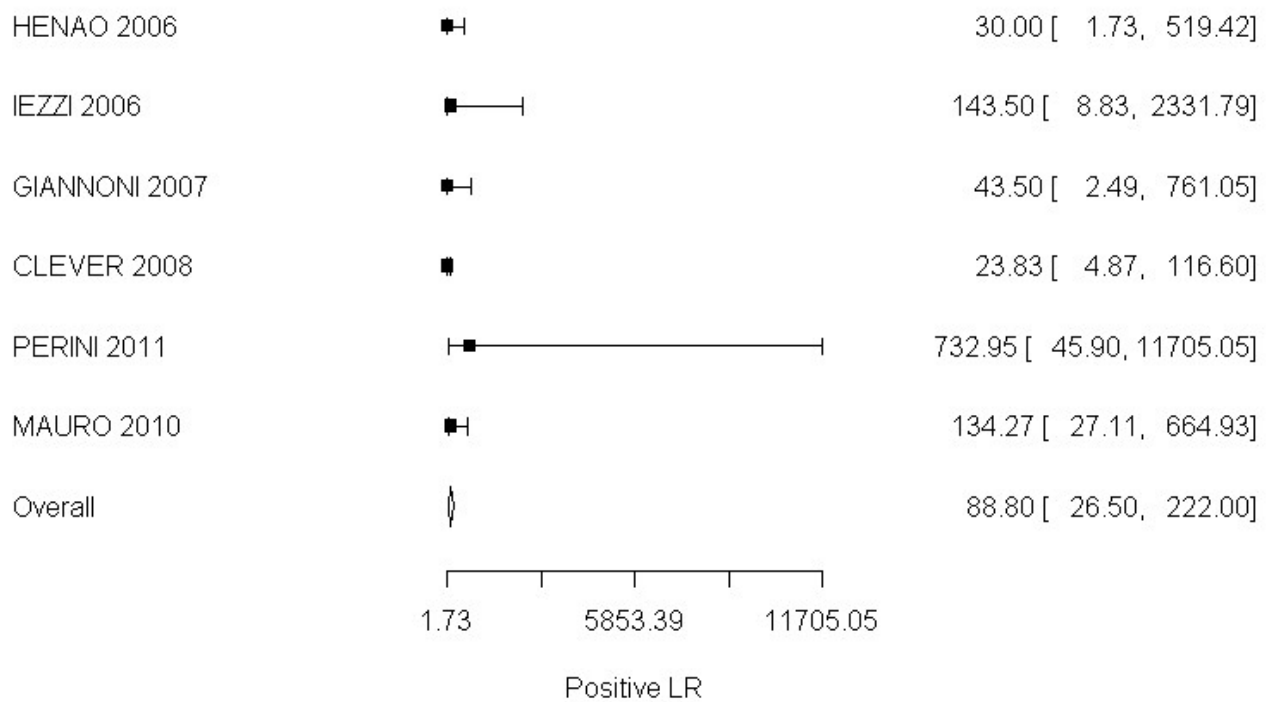
Positive Likelihood Ratio**CEUS**

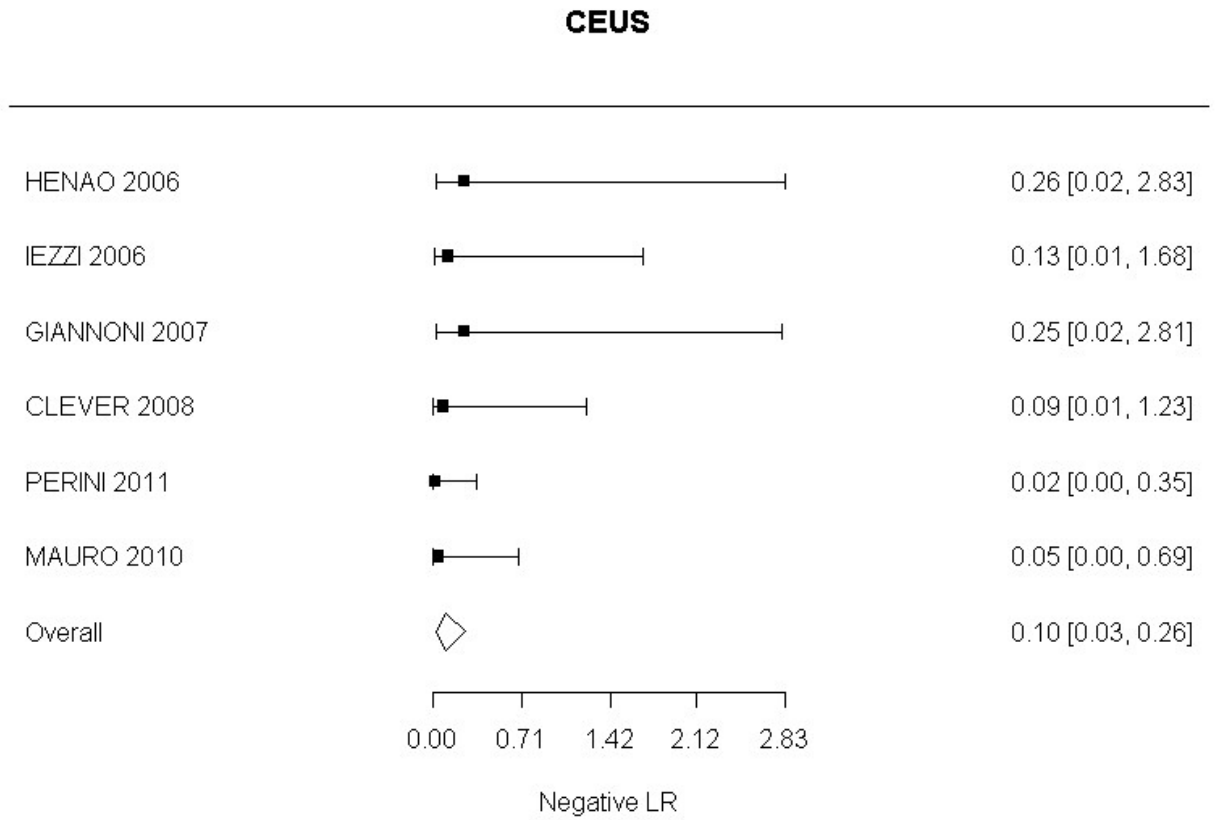
Negative Likelihood Ratio

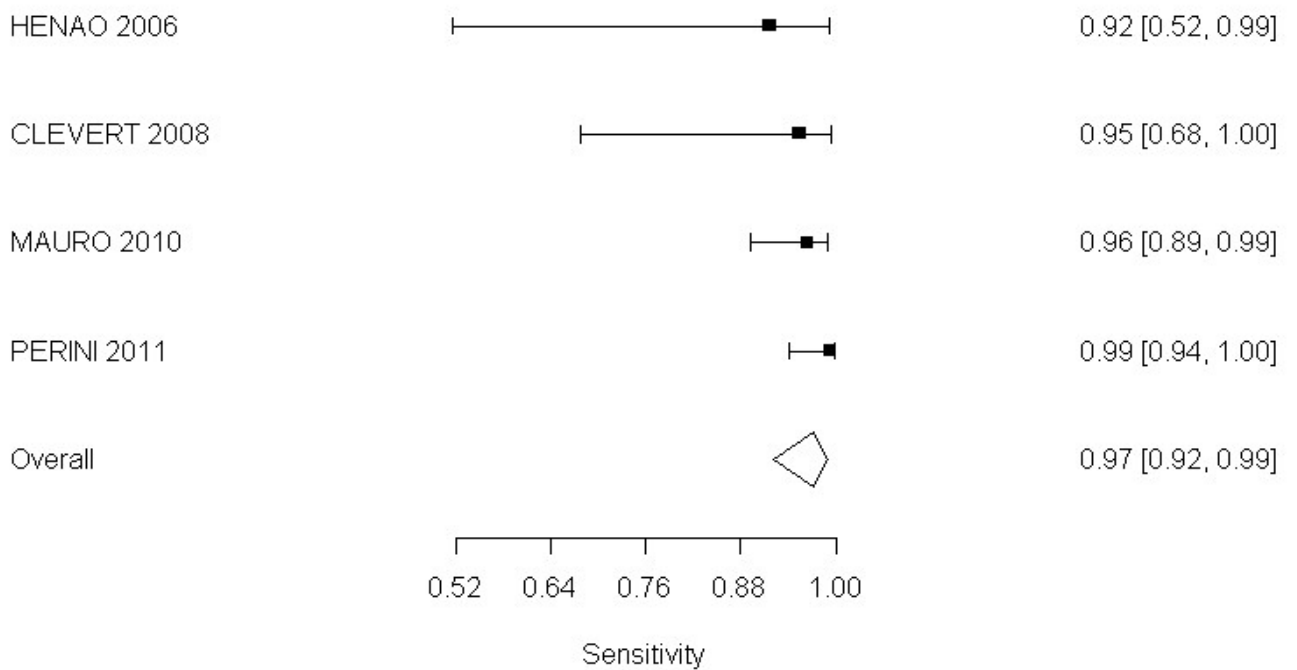


Type I and III endoleaks**Sensitivity**

Specificity**CEUS**

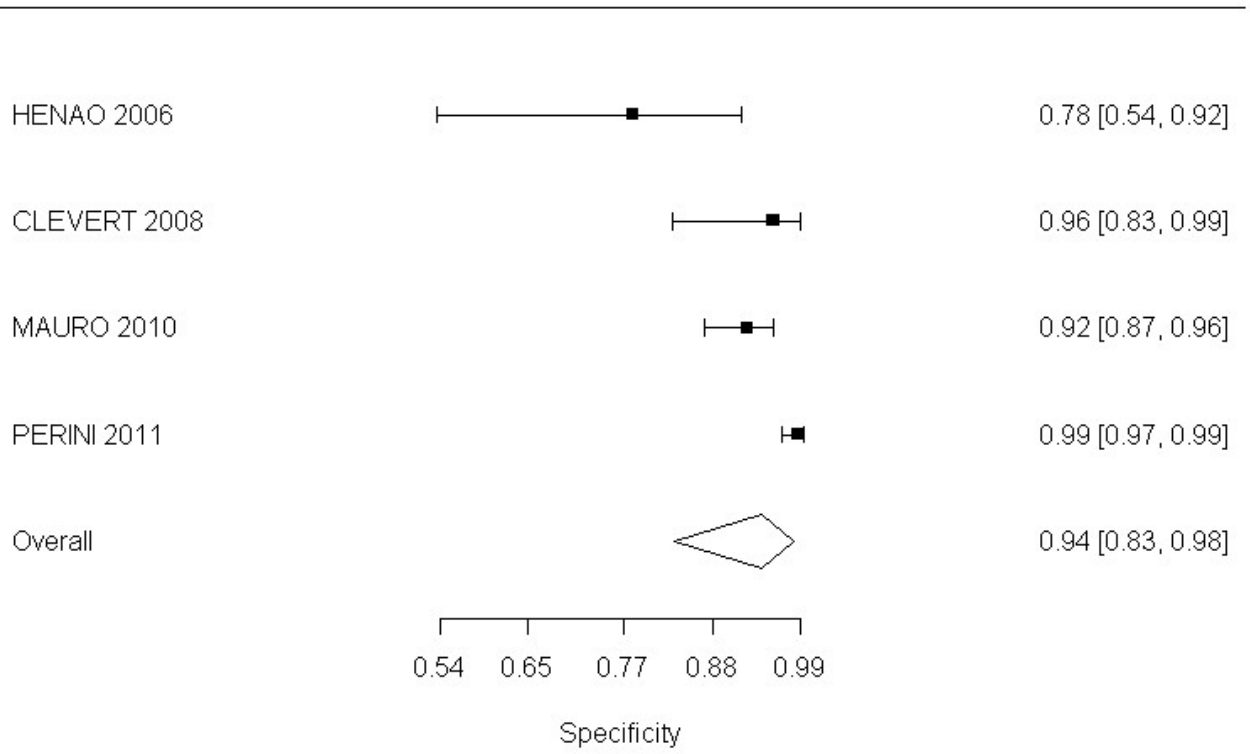
Positive Likelihood Ratio**CEUS**

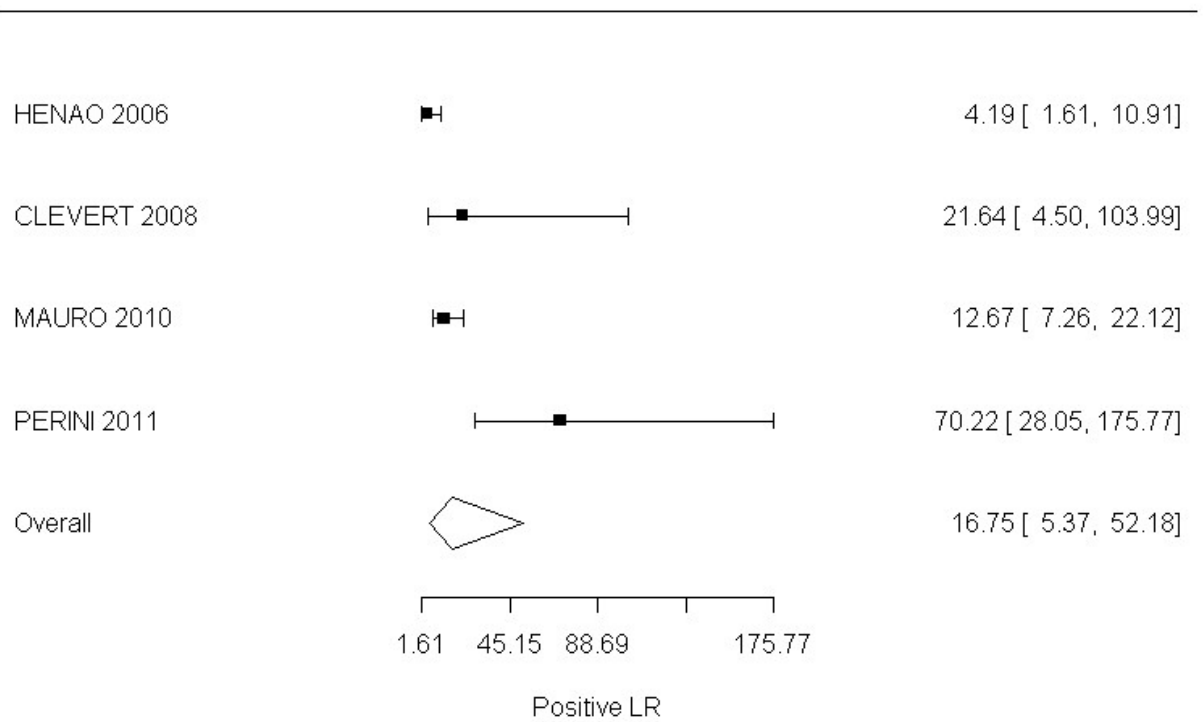
Negative Likelihood Ratio

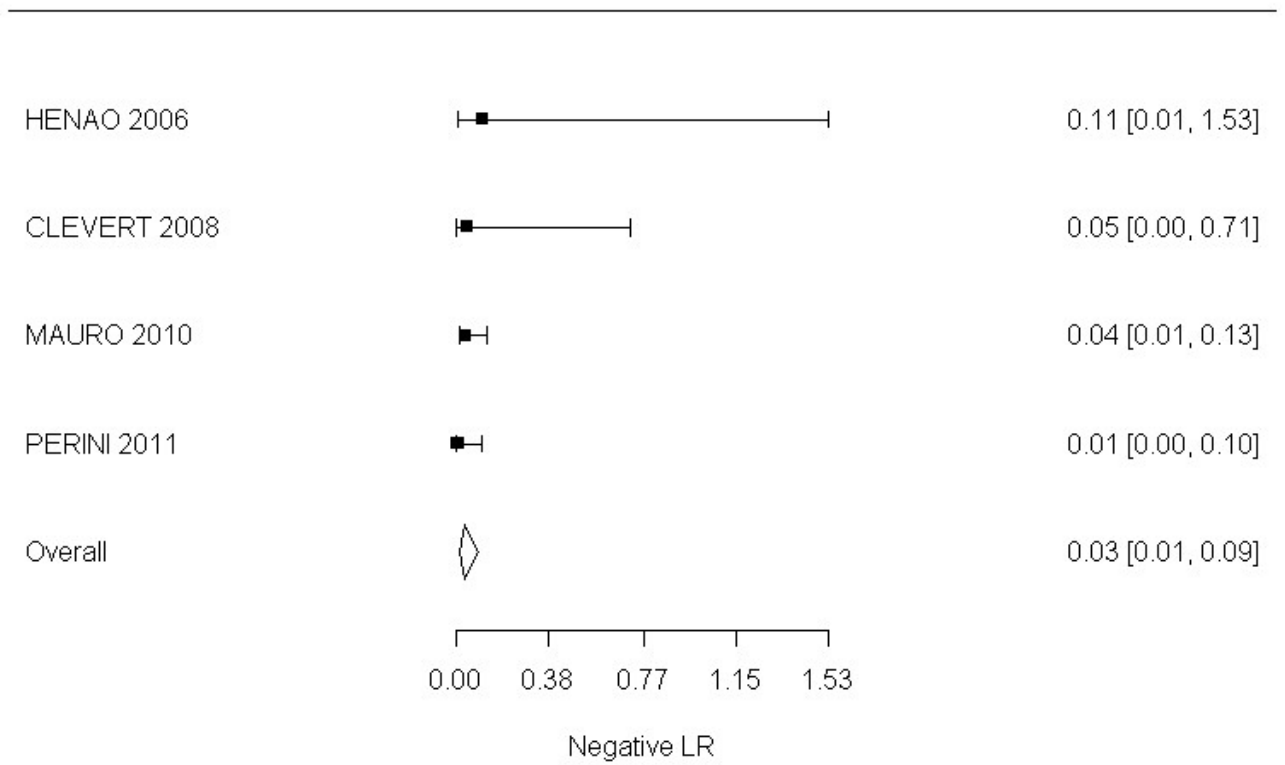
Type II endoleak**Sensitivity****CEUS**

Specificity

CEUS



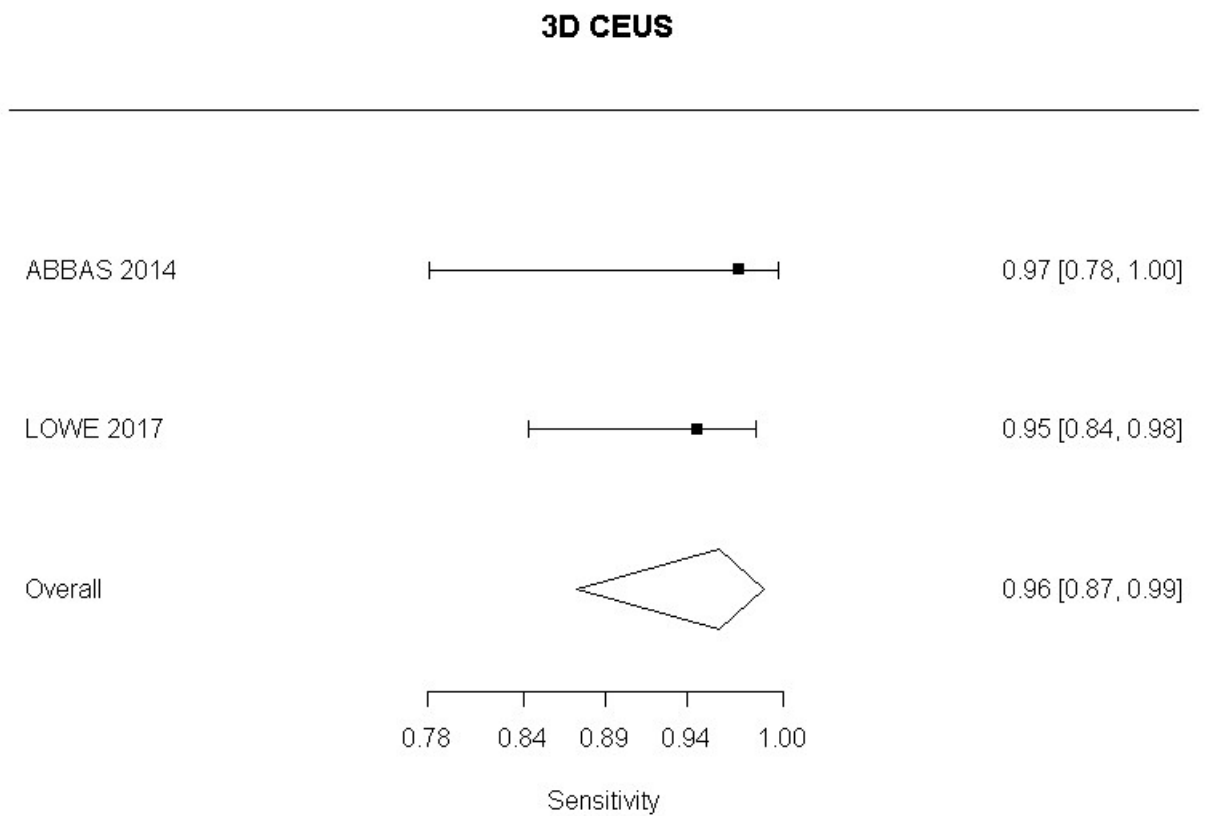
Positive Likelihood Ratio**CEUS**

Negative Likelihood Ratio**CEUS**

3D Contrast Enhanced Colour Duplex ultrasound compared to angiography

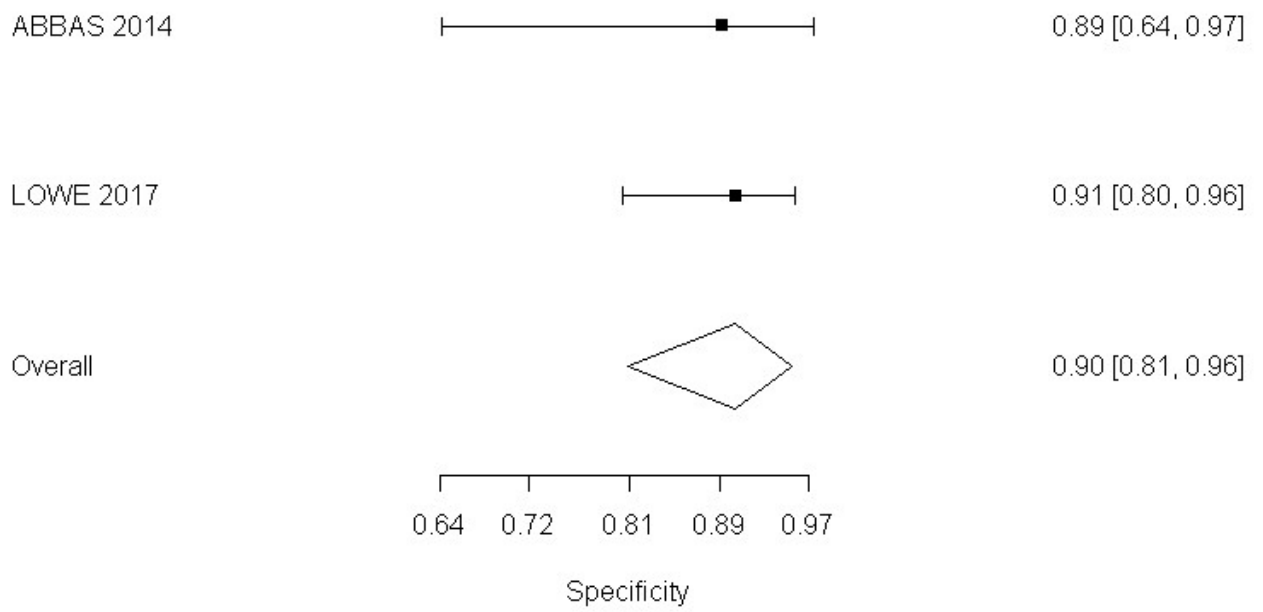
All endoleaks

Sensitivity



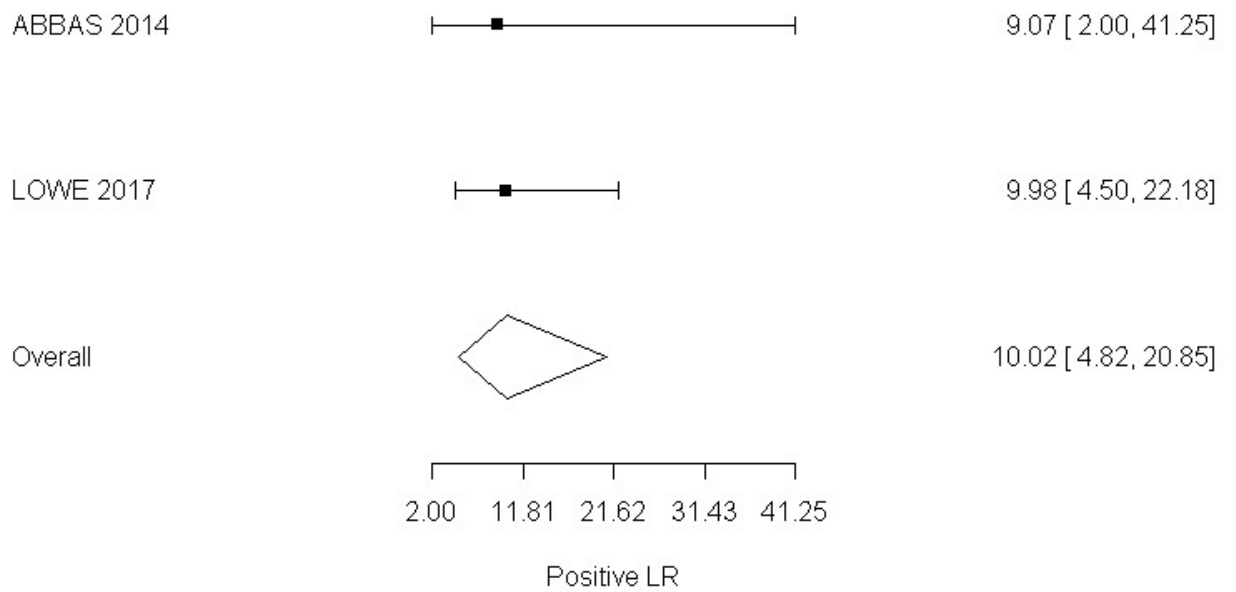
Specificity

3D CEUS



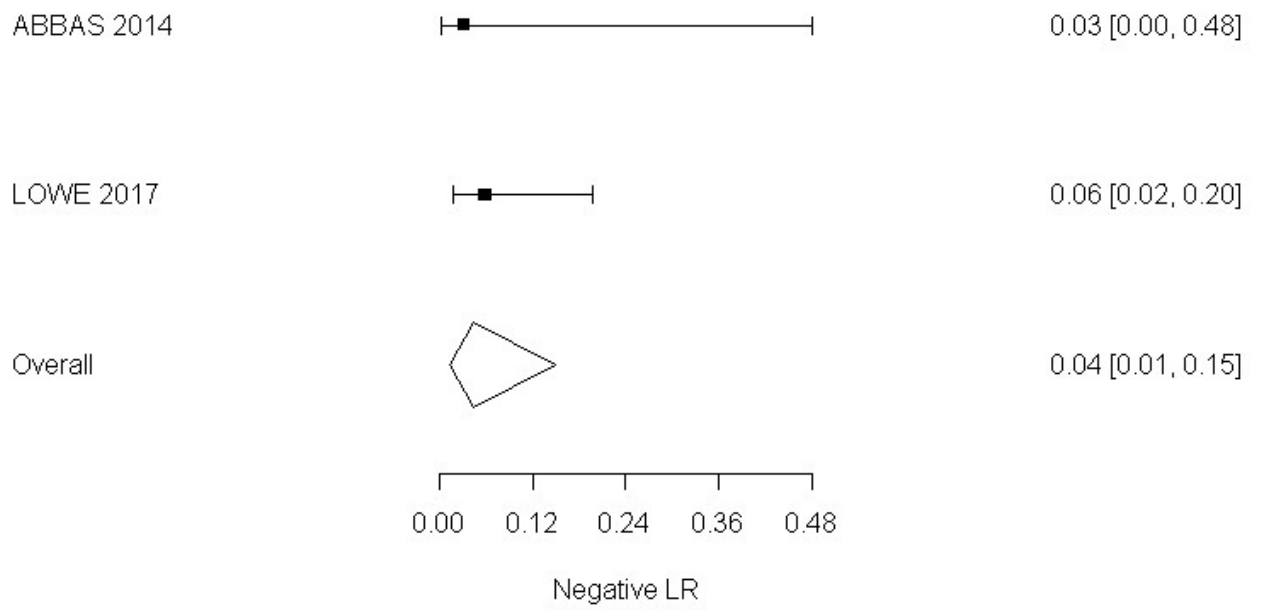
Positive Likelihood Ratio

3D CEUS



Negative Likelihood Ratio

3D CEUS



Appendix F – GRADE tables

Complications

Identification of Endoleak

Colour Duplex ultrasound compared to angiography

No. of studies	Study design	Sample size	Sensitivity (95%CI)	Specificity (95%CI)	Effect size (95%CI)	Risk of bias	Inconsistency	Indirectness	Imprecision	Quality
Reference Standard- CTA; CDUS in the identification of all endoleaks in people undergoing EVAR										
24 ¹	Cross Sectional	4198 (combination of patients and scans)	65.6% (54.5%, 75.2%)	92.5% (89.3%, 94.8%)	LR+ 8.84 (5.870, 12.80)	Serious ⁴	Very Serious ⁵	Not Serious	Not Serious	Very Low
					LR- 0.375 (0.268, 0.493)	Serious ⁴	Very Serious ⁵	Not Serious	Serious ⁶	Very Low
Sensitivity analysis: Removal of studies conducted in 1990s.										
20 ⁹	Cross sectional	3675 (combination of patients and scans)	64.0% (50.8%, 75.4%)	91.8 % (87.9%, 94.5%)	LR+ 7.910 (5.10, 11.80)	Serious ⁴	Very Serious ⁵	Not Serious	Not Serious	Very Low
					LR- 0.395 (0.269, 0.539)	Serious ⁴	Very Serious ⁵	Not Serious	Serious ⁶	Very Low
Sensitivity analysis: Removal of studies published before 2018, and those in which										
5 ¹⁰	Cross sectional	914	77.2%	93.6%	LR+ 9.63 (6.26, 14.82)	Very Serious ⁷	Serious ⁸	Not Serious	Not Serious	Very Low

No. of studies	Study design	Sample size	Sensitivity (95%CI)	Specificity (95%CI)	Effect size (95%CI)	Risk of bias	Inconsistency	Indirectness	Imprecision	Quality
		(combination of patients and scans)	(51.5%, 91.5%)	(86.5%, 97.1%)	LR- 0.29 (0.15, 0.60)	Very Serious ⁷	Serious ⁸	Not Serious	Serious ⁶	Very Low
Reference Standard- CTA; CDUS in the identification of Type I and III endoleak in people undergoing EVAR										
7 ²	Cross Sectional	1346 (combination of patients and scans)	68.2% (46.6%, 84.15)	99.3% (98.3%, 99.7%)	LR+ 101.00 (38.80, 218.00)	Very Serious ⁷	Not Serious	Not Serious	Not Serious	Low
					LR- 0.328 (0.161, 0.538)	Very Serious ⁷	Not Serious	Not Serious	Serious ⁶	Very Low
Reference Standard- CTA; CDUS in the identification Of Type II endoleak in people undergoing EVAR										
5 ³	Cross Sectional	1242 combination of patients and scans)	77.1% (39.6%, 94.5%)	92.9% (88.4%, 95.7%)	LR+ 10.40 (6.94, 14.60)	Very Serious ⁷	Serious ⁸	Not Serious	Not Serious	Very Low
					LR- 0.275 (0.0611, 0.635)	Very Serious ⁷	Very Serious ⁵	Not Serious	Serious ⁶	Very Low
<ol style="list-style-type: none"> Oikonomou (2012), Golzarian (2000), D'Audiffret (2001), Bendick (2003), Clevert (2008), Clevert (2011), Iezzi (2009), Henao (2006), Parent (2002), Cantador (2016), Wolf (2000), Schmieder (2009), Gray (2012), Raman (2013), Aburahma (205), Franca (2013), Demirpolat (2010), Kamal (2008), Badri (2010), McWilliams (2002), Pages (2001), Nagre (2011), Zannetti (2000), Nerlekar (2006) Oikonomou (2012), D'Audiffret (2001), Henao (2006), Iezzi (2009), Clevert (2008), Nagre (2011), Gray (2012) Clevert 2008, D'Audiffret 2001, Oikonomou 2012, Nagre 2011, Gray 2012 >33.3% of weighted data from studies at moderate or high risk of bias, downgrade 1 level. Studies rated moderate or high risk of bias due to unclear blinding between reference standard and index test and unclear time interval between two tests. I2 greater than 66.7%, downgrade 2 levels 95% confidence interval for likelihood ratio crosses one end of a defined MID interval – (0.5, 2), downgrade 1 level 										

No. of studies	Study design	Sample size	Sensitivity (95%CI)	Specificity (95%CI)	Effect size (95%CI)	Risk of bias	Inconsistency	Indirectness	Imprecision	Quality
7.	>33.3% of weighted data from studies at high risk of bias, downgrade 2 levels. Studies rated high risk of bias due to unclear blinding and interval between reference standard and index test.									
8.	I2 between 33.3% and 66.7%, downgrade 1 level									
9.	Oikonomou (2012), D'Audiffret (2001), Bendick (2003), Clevert (2008), Clevert (2011), Iezzi (2009), Henao (2006), Parent (2002), Cantador (2016), Schmieder (2009), Gray (2012), Raman (2013), Aburahma (205), Franca (2013), Demirpolat (2010), Kamal (2008), Badri (2010), McWilliams (2002), Nagre (2011), Nerlekar (2006)									
10.	Badri (2010), Cantador (2016), Demirpolat (2010), Gray (2012), Oikonomou (2012)									

Contrast Enhanced Colour Duplex ultrasound compared to angiography

No. of studies	Study design	Sample size	Sensitivity (95%CI)	Specificity (95%CI)	Effect size (95%CI)	Risk of bias	Inconsistency	Indirectness	Imprecision	Quality
Reference Standard- CTA; CEUS in identification of all endoleaks in people undergoing EVAR										
15 ¹	Cross Sectional	1667 (combination of patients and scans)	91.0% (82.7%, 95.6%)	88.0% (82.3%, 93.1%)	LR+ 8.34 (4.94, 13.4)	Serious ⁴	Very Serious ⁵	Not Serious	Not Serious	Very Low
					LR- 0.107(0.04 91, 0.20)	Serious ⁴	Very Serious ⁵	Not Serious	Not Serious	Very Low
Reference Standard – CTA, CEUS in identification of endoleaks in people undergoing complex EVAR										
Perini 2012	Cross sectional	62 patients	83.3% (36.9%, 97.7%)	96.4% (86.8%, 99.1%)	LR+ 23.33 (5.173, 95.304)	Not Serious	N/A ⁶	Not Serious	Not Serious	High
					LR- 0.173 (0.029, 1.035)	Not Serious	N/A ⁶	Not Serious	Serious ⁷	Moderate
Reference Standard- CTA;CEUS, In identification of Type I and III endoleak in people undergoing EVAR										

No. of studies	Study design	Sample size	Sensitivity (95%CI)	Specificity (95%CI)	Effect size (95%CI)	Risk of bias	Inconsistency	Indirectness	Imprecision	Quality
6 ²	Cross Sectional	791 (combination of patients and scans)	91.0% (74.2%, 97.3%)	98.8% (99.6%, 96.7%)	LR+ 88.80 (26.40, 222.000)	Not Serious	Not Serious	Not Serious	Not Serious	High
					LR- 0.105 (0.027, 0.262)	Not Serious	Not Serious	Not Serious	Not Serious	High
Reference Standard – CTA, CEUS in identification of type I endoleaks in people undergoing complex EVAR										
Perini 2012	Cross sectional	62 patients	75.0% (10.9%, 98.7%)	99.2% (88.4%, 99.9%)	LR+ 93.0 (5.251, 1647.197)	Not Serious	N/A ⁶	Not Serious	Not Serious	High
					LR- 0.252 (0.023, 2.780)	Not Serious	N/A ⁶	Not Serious	Very Serious ⁸	Low
Reference Standard- CTA; CEUS, In identification of Type II endoleak in patients undergoing EVAR										
4 ³	Cross Sectional	678	97.2% (92.2%, 99.0%)	94.2% (83.35, 98.25)	LR+ 16.746 (5.374, 52.180)	Not Serious	Very Serious ⁵	Not Serious	Not Serious	Low
					LR- 0.032 (0.011, 0.089)	Not Serious	Not Serious	Not Serious	Not Serious	High
Reference Standard – CTA, CEUS in identification of type II endoleaks in people undergoing complex EVAR										
Perini 2012	Cross sectional	62 patients	66.7 % (26.8%, 91.65)	98.2% (88.4%, 99.7%)	LR+ 37.33 (4.937, 282.308)	Not Serious	N/A ⁶	Not Serious	Not Serious	High

No. of studies	Study design	Sample size	Sensitivity (95%CI)	Specificity (95%CI)	Effect size (95%CI)	Risk of bias	Inconsistency	Indirectness	Imprecision	Quality
					LR- 0.339 (0.109, 1.053)	Not Serious	N/A ⁶	Not Serious	Not Serious	Moderate
<ol style="list-style-type: none"> Perini (2011), Bendick (2003), Giannoni (2007), Clevert (2008), Henao (2006), Iezzi (2009), Clevert (2011), Ten Bosch (2010), Gurtler (2013), Abbas (2014), McWilliams (2002), Motta (2012), Gilbaert (2012), Mauro (2010), Lowe (2017). Giannoni (2007), Clevert (2008), Henao (2006), Iezzi (2009), Perini (2011), Mauro (2010) Clevert (2008), Henao (2006), Perini (2011), Mauro (2010) >33.3% of weighted data from studies at moderate or high risk of bias, downgrade 1 level. Studies rated moderate or high risk of bias due to unclear blinding between reference standard and index test and unclear time interval between two tests. I² greater than 66.7%, downgrade 2 levels Inconsistency not applicable as evidence from a single study Downgrade 1 level as 95% confidence interval of likelihood ratio crosses one end of a defined MID interval (0.5, 2) Downgrade 2 levels as 95% confidence interval of likelihood ratio crosses both ends of a defined MID interval (0.5, 2) 										

3D Contrast Enhanced Colour Duplex ultrasound compared to angiography

No. of studies	Study design	Sample size	Sensitivity (95%CI)	Specificity (95%CI)	Effect size (95%CI)	Risk of bias	Inconsistency	Indirectness	Imprecision	Quality
Reference Standard- CTA; 3D CEUS in identification of all endoleaks in people undergoing EVAR										
2	Cross sectional	130 scans	96.0 % (87.2%, 98.8%)	90.4% (80.8%, 95.5%)	LR + 10.021 (4.817, 20.851)	Not serious	N/A ¹	Not Serious	Not Serious	Moderate
Abbas (2014) Lowe (2017)					LR- 0.044 (0.013, 0.149)	Not serious	N/A ¹	Not serious	Not serious	Moderate
<ol style="list-style-type: none"> Inconsistency not applicable as evidence from a single study. 										

4D Contrast Enhanced Colour Duplex ultrasound compared to angiography

No. of studies	Study design	Sample size	Sensitivity (95%CI)	Specificity (95%CI)	Effect size (95%CI)	Risk of bias	Inconsistency	Indirectness	Imprecision	Quality
Reference Standard- CTA; 3D CEUS in identification of all endoleaks in people undergoing complex EVAR										
Gargiulo (2014)	Cross sectional	22 patients	62.5% (18%, 92.7%)	97.5% (70.2%, 99.8%)	LR+ 25 (1.460, 428.004)	Serious ¹	N/A ²	Not Serious	Serious ³	Low
					LR- 0.385 (0.108, 1.366)	Serious ¹	N/A ²	Not serious	Serious ³	Low
Downgrade 1 level for serious risk of bias due to unclear blinding between reference standard and index test Inconsistency not applicable as evidence from a single study Downgrade 1 level as 95% confidence interval of likelihood ratio crosses one end of a defined MID interval (0.5, 2)										

Magnetic Resonance Imaging compared to angiography

No. of studies	Study design	Sample size	Sensitivity (95%CI)	Specificity (95%CI)	Effect size (95%CI)	Risk of bias	Inconsistency	Indirectness	Imprecision	Quality
Reference Standard- CTA; MRI in identification of endoleaks in people undergoing EVAR										
1 Mori 2016	Cross Sectional	46 patients	90.9% (56.1%, 98.7%)	91.4% (76.6%, 97.2%)	LR+ 10.606 (3.537, 31.799)	Serious ¹	N/A ²	Very serious	Not serious	Very Low
					LR- 0.099 (0.015, 0.646)	Serious ¹	N/A ²	Very serious	Serious ³	Very Low
Downgrade 1 level for serious risk of bias due to inadequate blinding between index test and reference standard. Inconsistency not applicable as evidence from a single study Downgrade 1 level as 95% confidence interval of likelihood ratio crosses one end of a defined MID interval (0.5, 2)										

No. of studies	Study design	Sample size	Sensitivity (95%CI)	Specificity (95%CI)	Effect size (95%CI)	Risk of bias	Inconsistency	Indirectness	Imprecision	Quality
Downgrade 2 levels for serious indirectness. Unenhanced MRI sequence utilised in the study, is not routinely used in practice.										

Identification of graft occlusion

Contrast Enhanced Colour Duplex ultrasound compared to angiography

No. of studies	Study design	Sample size	Sensitivity (95%CI)	Specificity (95%CI)	Effect size (95%CI)	Risk of bias	Inconsistency	Indirectness	Imprecision	Quality
Reference Standard- CTA; CEUS in the identification of graft occlusion in people undergoing EVAR										
1 Motta 2012	Cross Sectional	134 scans	58.3% (35.4%, 78.1%)	99.6% (93.6%, 100%)	LR+ 137.667 (8.427, 2248.874)	Serious ¹	N/A ²	Not serious	Not serious	Moderate
					LR- 0.418 (0.242, 0.723)					
Downgrade 1 level for serious risk of bias. All paired scans not included in final analysis										
Inconsistency not applicable as evidence from a single study										
Downgrade 1 level as 95% confidence interval of likelihood ratio crosses one end of a defined MID interval (0.5, 2)										

Change in aneurysm size

Overall change in aneurysm size

Colour Duplex Ultrasound compared to angiography

No. of studies	Study design	Sample size	Sensitivity (95%CI)	Specificity (95%CI)	Effect size (95%CI)	Risk of bias	Inconsistency	Indirectness	Imprecision	Quality
Reference Standard- CTA; CDUS In identification of aneurysm change in people undergoing EVAR										
2	Cross Sectional	773 scans	92.4% (87.7%, 95.3%)	85.7% (29.6%, 98.8%)	LR+ 6.426 (0.706, 58.498)	Serious ¹	Serious ²	Serious ³	Serious ⁴	Very low
Pages 2001 Bargellini 2009					LR- 0.100 (0.073, 0.137)	Serious ¹	Not serious	Serious ³	Not serious	Low
Downgrade 1 level for serious risk of bias. Studies rated moderate risk of bias due to unclear blinding and time interval between reference standard and index test.										
I ² between 33.3% and 66.7%, downgrade 1 level										
Downgrade 1 level for indirectness. Pages (2001) presented partially indirect data. While study was published prior to year 2000, study was conducted between 1996 and 1999, which does not match the review protocol.										
Downgrade 1 level as 95% confidence interval of likelihood ratio crosses one end of a defined MID interval (0.5, 2)										

Reduction in aneurysm size

Colour Duplex Ultrasound compared to angiography

No. of studies	Study design	Sample size	Sensitivity (95%CI)	Specificity (95%CI)	Effect size (95%CI)	Risk of bias	Inconsistency	Indirectness	Imprecision	Quality
Reference Standard- CTA; CDUS in identification of reduction in aneurysm size in people undergoing EVAR										

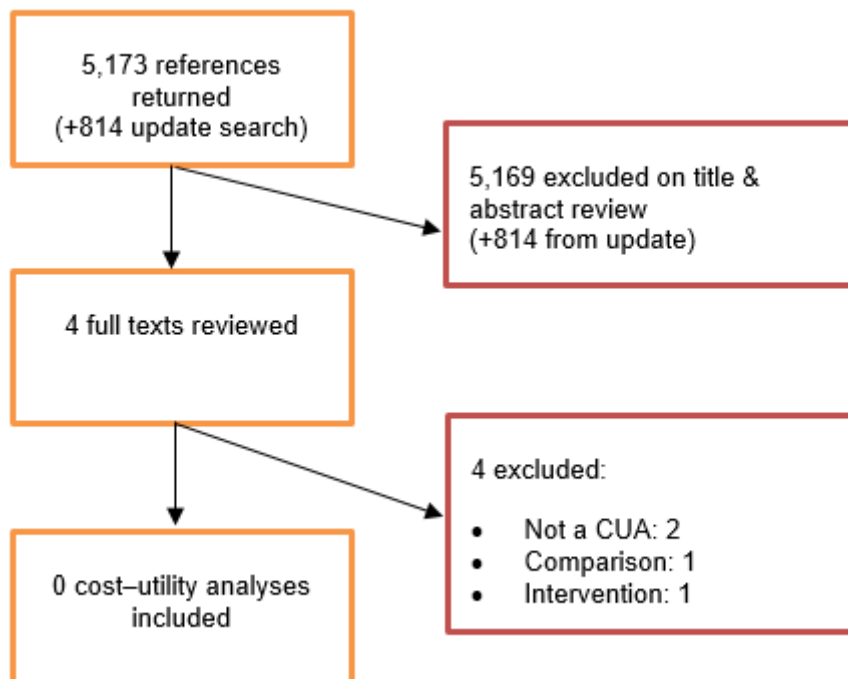
No. of studies	Study design	Sample size	Sensitivity (95%CI)	Specificity (95%CI)	Effect size (95%CI)	Risk of bias	Inconsistency	Indirectness	Imprecision	Quality
1 Bargellini 2009	Cross Sectional	657 scans	98.7 % (97.2%, 99.4%)	68.2% (61.3%, 74.4%)	LR+ 3.107 (2.525, 3.824)	Serious ⁴	N/A ⁵	Not serious	Not serious	Moderate
					LR- 0.019 (0.008, 0.042)	Serious ⁴	N/A ⁵	Not serious	Not serious	Moderate
Downgrade 1 level for serious risk of bias due to unclear blinding between reference standard and index test Inconsistency not applicable as evidence from a single study										

Increase in aneurysm size

Colour Duplex Ultrasound compared to angiography

No. of studies	Study design	Sample size	Sensitivity (95%CI)	Specificity (95%CI)	Effect size (95%CI)	Risk of bias	Inconsistency	Indirectness	Imprecision	Quality
Reference Standard- CTA; CDUS In identification of increase in aneurysm size in people undergoing EVAR										
1 Bargellini 2009	Cross Sectional	180 scans	41.7% (28.7%, 55.9%)	99.2% (94.8%, 99.95)	LR+ 55.00 (7.586, 398.753)	Serious ¹	N/A ²	Not serious	Not serious	Moderate
					LR- 0.588 (0.463, 0.747)	Serious ¹	N/A ²	Not serious	Serious ³	Low
Downgrade 1 level for serious risk of bias due to unclear blinding between reference standard and index test Inconsistency not applicable as evidence from a single study Downgrade 1 level as 95% confidence interval of likelihood ratio crosses one end of a defined MID interval (0.5, 2)										

Appendix G – Economic evidence study selection



Appendix H – Excluded studies

Clinical studies

Study ID	Title	Reason for Exclusion
AbuRahma (2006)	Fate of endoleaks detected by CT angiography and missed by color duplex ultrasound in endovascular grafts for abdominal aortic aneurysms.	Diagnostic accuracy measures were not available and could not be calculated.
Alerci (2009)	Prospective, intraindividual comparison of MRI versus MDCT for endoleak detection after endovascular repair of abdominal aortic aneurysms	Not a relevant intervention and/or comparator
Almaroof (2013)	Comparison of duplex ultrasound and computed tomography surveillance after endovascular aneurysm repair in determining proximal endograft location	No relevant outcomes reported
Antoniou (2013)	Plasma matrix metalloproteinase 9 levels may predict endoleaks after endovascular aortic aneurysm repair	Not a relevant intervention and/or comparator
Arko (2004)	Duplex scanning after endovascular aneurysm repair: an alternative to computed tomography	Not a relevant study design
Armerding (2000)	Aortic aneurysmal disease: assessment of stent-graft treatment-CT versus conventional angiography.	Study did use adequate reference standard. In the study, CTA was compared to screen film or digital subtraction angiography.
Arsicot (2014)	Follow-up of aortic stent grafts: comparison of the volumetric analysis of the aneurysm sac by ultrasound and CT.	Case-control study design.
Ascenti (2011)	Dual-energy CT for detection of endoleaks after endovascular abdominal aneurysm repair: Usefulness of colored iodine overlay	Not a relevant intervention and/or comparator
Ashoke (2005)	Color duplex ultrasonography is insensitive for the detection of endoleak after aortic endografting: a systematic review (Structured abstract).	Systematic review contained unpublished data and studies conducted before year 2000.
Ayuso (2004)	MRA is useful as a follow-up technique after endovascular repair of aortic aneurysms with nitinol endoprostheses.	Study population did not match review protocol. Study included patients after an endoleak was observed on a follow-up CTA.
Bakken (2010)	Long-term follow-up after endovascular aneurysm repair: is ultrasound alone enough?	Not a relevant study design
Balm (1996)	CT-angiography of abdominal aortic aneurysms after transfemoral endovascular aneurysm management	Published before 2000 or systematic review

Study ID	Title	Reason for Exclusion
		containing only papers published before 2000
Balm (1997)	Use of spiral computed tomographic angiography: In monitoring abdominal aortic aneurysms after transfemoral endovascular repair	Published before 2000 or systematic review containing only papers published before 2000
Balm (1997)	Computed tomographic angiographic imaging of abdominal aortic aneurysms: implications for transfemoral endovascular aneurysm management	Published before 2000 or systematic review containing only papers published before 2000
Bastos (2011)	A multidetector tomography protocol for follow-up of endovascular aortic aneurysm repair	Not a relevant intervention and/or comparator
Bastounis (1996)	The validity of current vascular imaging methods in the evaluation of aortic anastomotic aneurysms developing after abdominal aortic aneurysm repair	Published before 2000 or systematic review containing only papers published before 2000
Baum (2000)	Diagnosis and treatment of inferior mesenteric arterial endoleaks after endovascular repair of abdominal aortic aneurysms	Not a relevant study design. No relevant outcomes reported
Baum (2001)	Diagnosis and management of type 2 endoleaks after endovascular aneurysm repair	Not a relevant study design
Baum (2003)	Endoleaks after endovascular repair of abdominal aortic aneurysms	Not a relevant study design
Baumüller (2011)	Maximum diameter measurements of aortic aneurysms on axial CT images after endovascular aneurysm repair: sufficient for follow-up?	Not a relevant intervention and/or comparator
Becker (2002)	Transluminal repair of abdominal aortic aneurysm: a call for selective use, careful surveillance, new device design, and systematic study of transrenal fixation	Not a peer-reviewed publication
Beeman (2009)	Duplex ultrasound imaging alone is sufficient for midterm endovascular aneurysm repair surveillance: a cost analysis study and prospective comparison with computed tomography scan	Not a relevant study design
Beeman (2010)	Duplex ultrasound factors predicting persistent type II endoleak and increasing AAA sac diameter after EVAR	Not a relevant intervention and/or comparator
Berman (1995)	Application of computed tomography for surveillance of aortic grafts	Published before 2000 or systematic review containing only papers published before 2000
Bevis (2012)	Duplex ultrasound for surveillance after endovascular repair of abdominal aortic aneurysm.	No primary studies or no new primary studies extracted from this systematic review
Biasi (2009)	Intra-operative DynaCT improves technical success of endovascular repair of abdominal aortic aneurysms	Not a relevant intervention and/or comparator

Study ID	Title	Reason for Exclusion
Biasi (2009)	Intraoperative DynaCT detection and immediate correction of a type Ia endoleak following endovascular repair of abdominal aortic aneurysm	Not a relevant intervention and/or comparator
Binkert (2006)	Translumbal type II endoleak repair using angiographic CT	Not a relevant study design
Black (2009)	Long-term surveillance with computed tomography after endovascular aneurysm repair may not be justified	Not a relevant study design
Bley (2009)	Endovascular abdominal aortic aneurysm repair: nonenhanced volumetric CT for follow-up	Not a relevant study design
Blom (2012)	Duplex ultrasound imaging to detect limb stenosis or kinking of endovascular device	Not a relevant intervention and/or comparator. Not a relevant study design
Bobadilla (2013)	Clinical implications of non-contrast-enhanced computed tomography for follow-up after endovascular abdominal aortic aneurysm repair	Not a relevant intervention and/or comparator
Bredahl (2013)	Volume estimation of the aortic sac after EVAR using 3-D ultrasound - a novel, accurate and promising technique	No relevant outcomes reported
Bredahl (2013)	Three-dimensional ultrasound improves the accuracy of diameter measurement of the residual sac in EVAR patients	No relevant outcomes reported
Cani (2012)	Volumetric analysis of the aneurysmal sac with computed tomography in the follow-up of abdominal aortic aneurysms after endovascular treatment	Not a relevant intervention and/or comparator. Not a relevant study design
Cantisani (2011)	Prospective comparative analysis of colour-doppler ultrasound, contrast-enhanced ultrasound, computed tomography and magnetic resonance in detecting endoleak after endovascular abdominal aortic aneurysm repair.	Reference standard used in study did not match review protocol. CTA and MRA were used as the reference or angiography when available.
Cantisani (2015)	EVAR: Benefits of CEUS for monitoring stent-graft status	Not a relevant study design
Cantisani (2017)	Color Doppler Ultrasound with Superb Microvascular Imaging Compared to Contrast-enhanced Ultrasound and Computed Tomography Angiography to Identify and Classify Endoleaks in Patients Undergoing EVAR.	Reference standard used in study did not match review protocol. DSA used as reference standard.
Carnero (2006)	Aneurysm sac pressure measurement with a pressure sensor in endovascular aortic aneurysm repair	Not a relevant study design
Carrafiello (2006)	Comparison of contrast-enhanced ultrasound and computed tomography in classifying endoleaks after endovascular treatment of abdominal aorta aneurysms: preliminary experience	Not a relevant study design
Carrafiello (2008)	Endoleak detection and classification after endovascular treatment of abdominal aortic aneurysm: value of CEUS over CTA	Not a relevant study design

Study ID	Title	Reason for Exclusion
Carter (2005)	Color duplex ultrasound for the evaluation of endovascular stent grafts following endovascular repair of abdominal aortic aneurysm	Full text not obtained
Causey (2013)	Three-dimensional ultrasonography measurements after endovascular aneurysm repair	No relevant outcomes reported
Cejna (2002)	MR angiography vs CT angiography in the follow-up of nitinol stent grafts in endoluminally treated aortic aneurysms	Not a relevant intervention and/or comparator
Chandarana (2008)	Abdominal aorta: evaluation with dual-source dual-energy multidetector CT after endovascular repair of aneurysms--initial observations	Not a relevant intervention and/or comparator
Chernyak (2006)	Type II endoleak after endoaortic graft implantation: diagnosis with helical CT arteriography	Not a relevant intervention and/or comparator
Chisci (2012)	Surveillance imaging modality does not affect detection rate of asymptomatic secondary interventions following EVAR	Not a relevant intervention and/or comparator
Chung (2015)	Contrast-enhanced ultrasound (CEUS) versus computed tomography angiography (CTA) in detection of endoleaks in post-EVAR patients. Are delayed type II endoleaks being missed? A systematic review and meta-analysis.	No primary studies or no new primary studies extracted from this systematic review
Clevert (2009)	Imaging of endoleaks after endovascular aneurysm repair (EVAR) with contrast-enhanced ultrasound (CEUS). A pictorial comparison with CTA	Not a relevant study design
Clevert (2013)	Clevert D A, Gurtler V M, Meimarakis G, D'Anastasi M, Weidenhagen R, Reiser M F, and Becker C R (2013) Classification of endoleaks in the follow-up after EVAR using the time-to-peak of the contrast agent in CEUS examinations. Clinical hemorheology and microcirculation 55, 183-91	Study did not match the objectives of this review. Study evaluated if the time-to-peak is a helpful new feature in confirming the type of endoleak in uncertain cases.
Cohen (2008)	Time-resolved MR angiography for the classification of endoleaks after endovascular aneurysm repair	Not a relevant intervention and/or comparator
Collins (2007)	Ultrasound surveillance of endovascular aneurysm repair: a safe modality versus computed tomography.	Reference standard (CTA) was only offered to when ultrasound was positive for endoleaks.
Cornelissen (2010)	Detection of occult endoleaks after endovascular treatment of abdominal aortic aneurysm using magnetic resonance imaging with a blood pool contrast agent: preliminary observations	Not a relevant study design
Cornelissen (2011)	Use of multispectral MRI to monitor aneurysm sac contents after endovascular abdominal aortic aneurysm repair	Not a relevant intervention and/or comparator. Not a relevant study design
Czermak (2001)	Serial CT volume measurements after endovascular aortic aneurysm repair	Not a relevant intervention and/or

Study ID	Title	Reason for Exclusion
		comparator. Not a relevant study design
David (2016)	What is the role of contrast-enhanced ultrasound in the evaluation of the endoleak of aortic endoprostheses? A comparison between CEUS and CT on a widespread scale.	CTA not used as reference standard.
de Bucourt (2011)	Endoleak after endovascular aneurysm repair: evaluation of a single-acquisition CTA protocol using a prebolus	Not a relevant intervention and/or comparator
den (2009)	Comparison of ultrasonography with computed tomography in the diagnosis of incisional hernias	No relevant outcomes reported
Dias (2004)	Intra-aneurysm sac pressure measurements after endovascular aneurysm repair: differences between shrinking, unchanged, and expanding aneurysms with and without endoleaks	Not a relevant intervention and/or comparator
Diehm (2007)	Intraobserver and interobserver variability of 64-row computed tomography abdominal aortic aneurysm neck measurements	Not a relevant intervention and/or comparator. Not a relevant study design
Diehm (2008)	Commentary: Aneurysm Sac diameter measurement versus volume analysis in EVAR surveillance: out with the old and in with the new	Not a relevant study design
Dill-Macky (2006)	Aortic endografts: Detecting endoleaks using contrast-enhanced ultrasound	Not a relevant study design
Dindyal (2012)	Re: Single-centre prospective comparison between contrast-enhanced ultrasound and computed tomography angiography after EVAR	Not a relevant study design
Dingemans (2016)	Aneurysm Sac Enlargement after Endovascular Abdominal Aortic Aneurysm Repair	Not a relevant study design
Donas (2013)	CT angiography at 24 months demonstrates durability of EVAR with the use of chimney grafts for pararenal aortic pathologies	Not a relevant intervention and/or comparator
Dudeck (2015)	Can early computed tomography angiography after endovascular aortic aneurysm repair predict the need for reintervention in patients with type II endoleak?	Not a relevant intervention and/or comparator
Elkouri (2004)	Computed tomography and ultrasound in follow-up of patients after endovascular repair of abdominal aortic aneurysm.	Diagnostic accuracy measures were not available and could not be calculated.
Engellau (1998)	Magnetic resonance imaging and MR angiography of endoluminally treated abdominal aortic aneurysms	Published before 2000 or systematic review containing only papers published before 2000
Engellau (2003)	Patient preferences for follow-up methods after endovascular repair of abdominal aortic aneurysms.	Study examined patient experience of CT with MRI and DSA. These comparators were not listed in review protocol.
Engellau (2003)	Costs in follow-up of endovascularly repaired abdominal aortic aneurysms. Magnetic resonance	Not a relevant study design

Study ID	Title	Reason for Exclusion
	imaging with MR angiography versus EUROSTAR protocols	
Ersoy (2004)	Blood pool MR angiography of aortic stent-graft endoleak	Not the correct population/condition of interest
Faries (2003)	Increased recognition of type II endoleaks using a modified intraoperative angiographic protocol: implications for intermittent endoleak and aneurysm expansion	Not a relevant intervention and/or comparator
Fearn (2003)	Follow-up after endovascular aortic aneurysm repair: the plain radiograph has an essential role in surveillance	Not a relevant study design
Figuroa (2010)	Preliminary 3D computational analysis of the relationship between aortic displacement force and direction of endograft movement	Not a relevant intervention and/or comparator. Not a relevant study design
Fletcher (2000)	Colour Doppler diagnosis of perigraft flow following endovascular repair of abdominal aortic aneurysm.	Diagnostic accuracy measures were not available and could not be calculated.
Franco (2000)	Endovascular repair of the abdominal aortic aneurysm with the ancure endograft: CT follow-up of perigraft flow and aneurysm size at 6 months.	Study did not compare index test (CTA) to a reference standard.
Gardet (2010)	Comparison of detection of F-18 fluorodeoxyglucose positron emission tomography and 99mTc-hexamethylpropylene amine oxime labelled leukocyte scintigraphy for an aortic graft infection	Not a relevant intervention and/or comparator
Georg (2005)	Aortic stentgraft movement detection using digital roentgen stereophotogrammetric analysis on plane film radiographs -- initial results of a phantom study	Not a relevant intervention and/or comparator
Giannoni (2003)	Contrast-enhanced ultrasound imaging for aortic stent-graft surveillance.	Reference standard used in study did not match review protocol. In the study, CTA and MRA were used as reference standards.
Giannoni (2012)	Role of contrast-enhanced ultrasound in the follow-up of endo-vascular aortic aneurysm repair: an effective and safe surveillance method	Not a relevant study design
Go (2008)	What is the clinical utility of a 6-month computed tomography in the follow-up of endovascular aneurysm repair patients?	Not a relevant intervention and/or comparator
Gorich (1999)	Leakages after endovascular repair of aortic aneurysms: classification based on findings at CT, angiography, and radiography	Published before 2000 or systematic review containing only papers published before 2000
Gurtler (2014)	Comparison of contrast-enhanced ultrasound and compression elastography in the follow-up after endovascular aortic aneurysm repair	Not a relevant intervention and/or comparator

Study ID	Title	Reason for Exclusion
Habets (2013)	Magnetic resonance imaging is more sensitive than computed tomography angiography for the detection of endoleaks after endovascular abdominal aortic aneurysm repair: a systematic review (Provisional abstract)	Not a relevant intervention and/or comparator
Habets (2015)	Magnetic Resonance Imaging with a Weak Albumin Binding Contrast Agent can Reveal Additional Endoleaks in Patients with an Enlarging Aneurysm after EVAR	Not a relevant intervention and/or comparator
Han (2010)	Ultrasound-determined diameter measurements are more accurate than axial computed tomography after endovascular aortic aneurysm repair	No relevant outcomes reported
Hansen (2014)	Evaluation of low-dose CT angiography with model-based iterative reconstruction after endovascular aneurysm repair of a thoracic or abdominal aortic aneurysm	Not a relevant intervention and/or comparator
Harrison (2011)	Surveillance after EVAR based on duplex ultrasound and abdominal radiography	Not a relevant study design
Haulon (2001)	Diagnosis and treatment of type II endoleak after stent placement for exclusion of an abdominal aortic aneurysm	Not a relevant intervention and/or comparator
Haulon (2001)	Prospective evaluation of magnetic resonance imaging after endovascular treatment of infrarenal aortic aneurysms	Not a relevant intervention and/or comparator
Haulon (2012)	Response to letter to the editor "Re: Single centre prospective comparison between contrast enhanced ultrasound and computed tomography angiography after EVAR"	Not a relevant study design
Heilberger (1997)	Postoperative color flow duplex scanning in aortic endografting	Published before 2000 or systematic review containing only papers published before 2000
Hiramoto (2007)	The effect of magnetic resonance imaging on stainless-steel Z-stent-based abdominal aortic prosthesis	Not a relevant intervention and/or comparator
Hong (2008)	Clinical significance of endoleak detected on follow-up CT after endovascular repair of abdominal aortic aneurysm	Not a relevant intervention and/or comparator
Hope (2009)	Initial experience characterizing a type I endoleak from velocity profiles using time-resolved three-dimensional phase-contrast MRI	Not a relevant study design
Houdek (2015)	Initial experience of follow up of patients after the endovascular treatment of abdominal aortic aneurysms using contrast-enhanced ultrasound.	Diagnostic accuracy measures were not available and could not be calculated.
Hovsepian (1999)	Tc-99m sulfur colloid scintigraphy for detecting perigraft flow following endovascular aortic aneurysm repair: A feasibility study	Published before 2000 or systematic review containing only papers published before 2000

Study ID	Title	Reason for Exclusion
Huang (2013)	A prospective study of carbon dioxide digital subtraction versus standard contrast arteriography in the detection of endoleaks in endovascular abdominal aortic aneurysm repairs	Not a relevant intervention and/or comparator
Ichihashi (2013)	Preliminary experience with superparamagnetic iron oxide-enhanced dynamic magnetic resonance imaging and comparison with contrast-enhanced computed tomography in endoleak detection after endovascular aneurysm repair	Not a relevant intervention and/or comparator
lezzi (2007)	MDCT angiography in abdominal aortic aneurysm treated with endovascular repair: diagnostic impact of slice thickness on detection of endoleaks	Not a relevant intervention and/or comparator
lezzi (2008)	Multidetector-row computed tomography angiography in abdominal aortic aneurysm treated with endovascular repair: evaluation of optimal timing of delayed phase imaging for the detection of low-flow endoleaks	Not a relevant intervention and/or comparator. Not a relevant study design
lezzi (2010)	Endoleaks after endovascular repair of abdominal aortic aneurysm: Value of CEUS	Not a relevant study design
lezzi (2011)	Low-dose multidetector-row CT-angiography of abdominal aortic aneurysm after endovascular repair	Not a relevant intervention and/or comparator
Iino (2002)	Iino Misako, Kuribayashi Sachio, Imakita Satoshi, Takamiya Makoto, Matsuo Hiroshi, Ookita Yutaka, Ando Motomi, and Ueda Hatsue (2002) Sensitivity and specificity of CT in the diagnosis of inflammatory abdominal aortic aneurysms. Journal of computer assisted tomography 26, 1006-12	Study did not match objectives of review. Study assessed the diagnostic ability of CT in the diagnosis of inflammatory abdominal aortic aneurysm.
Inoue (2013)	Post-stress perfusion abnormalities detected on myocardial perfusion single-photon emission computed tomography predict long-term mortality after elective abdominal aortic aneurysm repair	Not a relevant intervention and/or comparator
Insko (2003)	MR imaging for the detection of endoleaks in recipients of abdominal aortic stent-grafts with low magnetic susceptibility	Not a relevant intervention and/or comparator
Jawad (2016)	The role of contrast-enhanced ultrasound imaging in the follow-up of patients post-endovascular aneurysm repair	Not a relevant study design
Jung (2010)	Detection and characterization of endoleaks following endovascular treatment of abdominal aortic aneurysms using contrast harmonic imaging (CHI) with quantitative perfusion analysis (TIC) compared to CT angiography (CTA).	Study population did not match review protocol. Individuals with suspected endoleaks in routine follow-up were examined.
Kalman (1999)	The value of late computed tomographic scanning in identification of vascular abnormalities after abdominal aortic aneurysm repair	Published before 2000 or systematic review containing only papers published before 2000
Karanikola (2014)	Duplex Ultrasound versus Computed Tomography for the Postoperative Follow-Up of Endovascular	Not a relevant study design

Study ID	Title	Reason for Exclusion
	Abdominal Aortic Aneurysm Repair. Where Do We Stand Now?	
Karch (1999)	Algorithm for the diagnosis and treatment of endoleaks	Published before 2000 or systematic review containing only papers published before 2000
Karthikesalingam (2012)	Systematic review and meta-analysis of duplex ultrasonography, contrast-enhanced ultrasonography or computed tomography for surveillance after endovascular aneurysm repair (Structured abstract).	No primary studies or no new primary studies extracted from this systematic review
Kaspersen (2005)	Three-dimensional teleradiology for surveillance following endovascular aortic aneurysm repair: a feasibility study	Not a relevant intervention and/or comparator
Kirby (2007)	Computed tomography angiography in abdominal aortic endoleaks: what is the optimal protocol?	Not a relevant intervention and/or comparator
Kirkpatrick (2014)	Surveillance computed tomographic arteriogram does not change management before 3 years in patients who have a normal post-EVAR study	Not a relevant study design
Kranokpiraksa (2008)	Follow-up of Endovascular Aneurysm Repair: Plain Radiography, Ultrasound, CT/CT Angiography, MR Imaging/MR Angiography, or What?	Not a relevant study design
Lookstein (2004)	Time-resolved magnetic resonance angiography as a noninvasive method to characterize endoleaks: initial results compared with conventional angiography	Not a relevant intervention and/or comparator
Maggio (2001)	Colour duplex scanning using contrast medium in the follow-up of patients given endograft treatment for abdominal aorta aneurysms.	Diagnostic accuracy measures were not available and could not be calculated.
Manning (2009)	Duplex ultrasound in aneurysm surveillance following endovascular aneurysm repair: a comparison with computed tomography aortography.	Study did not match objectives of this review. Index test and reference standard were not conducted concurrently. CDUS was conducted within 6 months of the CT scans.
Mattes (2012)	Evaluation of a new computerized analysis system developed for the processing of CT follow-up scans after EVR of infrarenal aneurysm	Not a relevant study design
McLafferty (2002)	The use of color-flow duplex scan for the detection of endoleaks.	Study did not match objectives of the review. Concurrent scans were not conducted.
McWilliams (1999)	Use of contrast-enhanced ultrasound in follow-up after endovascular aortic aneurysm repair	Published before 2000 or systematic review containing only papers published before 2000

Study ID	Title	Reason for Exclusion
Megalopoulos (2008)	Reliability of selective surveillance colonoscopy in the early diagnosis of colonic ischemia after successful ruptured abdominal aortic aneurysm repair	Not a relevant intervention and/or comparator
Mirza (2010)	Duplex ultrasound and contrast-enhanced ultrasound versus computed tomography for the detection of endoleak after EVAR: systematic review and bivariate meta-analysis (Structured abstract).	No primary studies or no new primary studies extracted from this systematic review
Mita (2000)	Complications of endovascular repair for thoracic and abdominal aortic aneurysm: an imaging spectrum	Not a relevant intervention and/or comparator
Muller-Wille (2014)	Dual-energy computed tomography after endovascular aortic aneurysm repair: the role of hard plaque imaging for endoleak detection.	Reference standard used in study did not match review protocol. Triple phased CT and contrast enhanced ultrasound were used as reference standards.
Nakai (2015)	Utility of 99mTc-human serum albumin diethylenetriamine pentaacetic acid SPECT for evaluating endoleak after endovascular abdominal aortic aneurysm repair	Not a relevant intervention and/or comparator
Nambi (2011)	Non-contrast computed tomography is comparable to contrast-enhanced computed tomography for aortic volume analysis after endovascular abdominal aortic aneurysm repair	Not a relevant intervention and/or comparator
Napoli (2004)	Abdominal aortic aneurysm: contrast-enhanced US for missed endoleaks after endoluminal repair	No relevant outcomes reported
Nordon (2010)	Secondary Interventions Following Endovascular Aneurysm Repair (EVAR) and the Enduring Value of Graft Surveillance	Not a relevant intervention and/or comparator. No relevant outcomes reported
Partovi (2015)	Contrast-enhanced ultrasound after endovascular aortic repair-current status and future perspectives	Not a relevant study design
Pfister (2009)	Contrast harmonic imaging ultrasound and perfusion imaging for surveillance after endovascular abdominal aneurysm repair regarding detection and characterization of suspected endoleaks.	Study population did not match review protocol. Study included individuals with clinically suspected endoleaks.
Pistolese (2002)	Postoperative regression of retroperitoneal fibrosis in patients with inflammatory abdominal aortic aneurysms: evaluation with spiral computed tomography	No relevant outcomes reported
Pitton (2005)	MRI versus helical CT for endoleak detection after endovascular aneurysm repair	Not a relevant intervention and/or comparator
Pitton (2006)	Diagnosis and management of endoleaks after endovascular aneurysm repair: role of MRI	Not a relevant intervention and/or comparator. Not a relevant study design

Study ID	Title	Reason for Exclusion
Raithel (1998)	Surveillance of patients after abdominal aortic aneurysm repair with endovascular grafting or conventional treatment	Not a relevant intervention and/or comparator. No relevant outcomes reported
Rand (2013)	Quality improvement guidelines for imaging detection and treatment of endoleaks following endovascular aneurysm repair (EVAR)	Not a relevant study design
Rozenblit (1995)	Endovascular repair of abdominal aortic aneurysm: value of postoperative follow-up with helical CT	Published before 2000 or systematic review containing only papers published before 2000
Rydberg (2004)	Characterization of endoleaks by dynamic computed tomographic angiography	Not a relevant intervention and/or comparator
Saba (2008)	Diagnostic sensitivity of multidetector-row spiral computed tomography angiography in the evaluation of type-II endoleaks and their source: comparison between axial scans and reformatting techniques	Not a relevant intervention and/or comparator
Sandford (2006)	Duplex ultrasound scanning is reliable in the detection of endoleak following endovascular aneurysm repair.	Study did not match objective of this review. Index test and reference standard not conducted concurrently (conducted 6 months apart)
Sato (1998)	Endoleak after aortic stent graft repair: diagnosis by color duplex ultrasound scan versus computed tomography scan	Published before 2000 or systematic review containing only papers published before 2000
Schnitzbauer (2017)	CT after Endovascular Repair of Abdominal Aortic Aneurysms: Diagnostic Accuracy of Diameter Measurements for the Detection of Aneurysm Sac Enlargement.	Voltmetry used as reference standard.
Sommer (2012)	Time-resolved CT angiography for the detection and classification of endoleaks.	Study included people who were suspected of having an endoleak at a previous imaging study or known to have postoperative endoleaks.
Stavropoulos (2005)	Use of CT angiography to classify endoleaks after endovascular repair of abdominal aortic aneurysms	Not a relevant intervention and/or comparator
Sueyoshi (2015)	Carbon dioxide digital subtraction angiography as an option for detection of endoleaks in endovascular abdominal aortic aneurysm repair procedure	Not a relevant intervention and/or comparator
Sun (2006)	Diagnostic value of color duplex ultrasonography in the follow-up of endovascular repair of abdominal aortic aneurysm	Duplicate and/or already included within an included systematic review

Study ID	Title	Reason for Exclusion
Sun (2008)	CT virtual intravascular endoscopy in the visualization of fenestrated stent-grafts	Not a relevant intervention and/or comparator
Sun (2008)	Multislice CT angiography in the follow-up of fenestrated endovascular grafts: Effect of slice thickness on 2D and 3D visualization of the fenestration stents	Not a relevant intervention and/or comparator
Sun (2017)	A meta-analysis of ultrasound imaging in diagnosis of endoleak among patients after endovascular abdominal aortic aneurysm repair.	No primary studies or no new primary studies extracted from this systematic review
Thompson (1998)	Comparison of computed tomography and duplex imaging in assessing aortic morphology following endovascular aneurysm repair	Published before 2000 or systematic review containing only papers published before 2000
Ustymowicz (2009)	Contrast-enhanced ultrasonography versus computed tomographic angiography in the monitoring of patients after endovascular repair of abdominal aortic aneurysm -- preliminary experience	No relevant outcomes reported
van der Laan (2006)	Computed tomography versus magnetic resonance imaging of endoleaks after EVAR.	Study did not compare index tests (CTA and MRI) to a reference standard.
van Keulen (2009)	Potential value of aneurysm sac volume measurements in addition to diameter measurements after endovascular aneurysm repair	Not a relevant intervention and/or comparator
Wacker (2014)	C-Arm CT - An adjunct to DSA for endoleak classification in patients with endovascular repair of abdominal aortic aneurysms	Not a relevant intervention and/or comparator
Wicky (2003)	MR angiography of endoleak with inconclusive concomitant CT angiography	Not a relevant intervention and/or comparator
Wieners (2010)	Detection of type II endoleak after endovascular aortic repair: comparison between magnetic resonance angiography and blood-pool contrast agent and dual-phase computed tomography angiography	Not a relevant intervention and/or comparator
Wolstenhulme (2013)	Review of postoperative CT and ultrasound for endovascular aneurysm repair using Talent stent graft: can we simplify the surveillance protocol and reduce the number of CT scans?	Not a relevant study design
Zaiem (2017)	Surveillance after endovascular aortic repair.	Review did not contain new relevant papers.

Economic studies

Study ID	Title	Reason for Exclusion
Beeman (2009)	Duplex ultrasound imaging alone is sufficient for midterm endovascular aneurysm repair surveillance: a cost analysis study and prospective	Not a CUA

Study ID	Title	Reason for Exclusion
	comparison with computed tomography. J Vasc Surg, 50: 1019-24.	
Manta (2007)	Intense cardiac troponin surveillance for long-term benefits is cost-effective in patients undergoing open abdominal aortic surgery: a decision analysis model. Anesth Analg, 105: 134-56.	Intervention (not imaging)
Post (2004)	Post PN, Kievit J, Van Bockel JH. Optimal follow-up strategies after aorto-iliac prosthetic reconstruction: a decision analysis and cost-effectiveness analysis. European journal of vascular and endovascular surgery. 2004 Sep 30;28(3):287-95.	Comparison (not comparing alternative techniques)
Schuster (2009)	Schuster H, Dünser E, Osinger K, Bergmayr W, Fischer-Scholz U, Richter W, Mostbeck GH. Ultrasound imaging of abdominal aortic aneurysms: diagnosis of aneurysms and complications and follow-up after endovascular repair. Ultraschall in der Medizin (Stuttgart, Germany: 1980). 2009 Dec;30(6):528.	Not a CUA

Appendix I – Glossary

Abdominal Aortic Aneurysm (AAA)

A localised bulge in the abdominal aorta (the major blood vessel that supplies blood to the lower half of the body including the abdomen, pelvis and lower limbs) caused by weakening of the aortic wall. It is defined as an aortic diameter greater than 3 cm or a diameter more than 50% larger than the normal width of a healthy aorta. The clinical relevance of AAA is that the condition may lead to a life-threatening rupture of the affected artery. Abdominal aortic aneurysms are generally characterised by their shape, size and cause:

- **Infrarenal AAA:** an aneurysm located in the lower segment of the abdominal aorta below the kidneys.
- **Juxtarenal AAA:** a type of infrarenal aneurysm that extends to, and sometimes, includes the lower margin of renal artery origins.
- **Suprarenal AAA:** an aneurysm involving the aorta below the diaphragm and above the renal arteries involving some or all of the visceral aortic segment and hence the origins of the renal, superior mesenteric, and celiac arteries, it may extend down to the aortic bifurcation.

Abdominal compartment syndrome

Abdominal compartment syndrome occurs when the pressure within the abdominal cavity increases above 20 mm Hg (intra-abdominal hypertension). In the context of a ruptured AAA this is due to the mass effect of a volume of blood within or behind the abdominal cavity. The increased abdominal pressure reduces blood flow to abdominal organs and impairs pulmonary, cardiovascular, renal, and gastro-intestinal function. This can cause multiple organ dysfunction and eventually lead to death.

Cardiopulmonary exercise testing

Cardiopulmonary Exercise Testing (CPET, sometimes also called CPX testing) is a non-invasive approach used to assess how the body performs before and during exercise. During CPET, the patient performs exercise on a stationary bicycle while breathing through a mouthpiece. Each breath is measured to assess the performance of the lungs and cardiovascular system. A heart tracing device (Electrocardiogram) will also record the hearts electrical activity before, during and after exercise.

Device migration

Migration can occur after device implantation when there is any movement or displacement of a stent-graft from its original position relative to the aorta or renal arteries. The risk of migration increases with time and can result in the loss of device fixation. Device migration may not need further treatment but should be monitored as it can lead to complications such as aneurysm rupture or endoleak.

Endoleak

An endoleak is the persistence of blood flow outside an endovascular stent - graft but within the aneurysm sac in which the graft is placed.

- Type I – Perigraft (at the proximal or distal seal zones): This form of endoleak is caused by blood flowing into the aneurysm because of an incomplete or ineffective seal at either end of an endograft. The blood flow creates pressure within the sac and significantly increases the risk of sac enlargement and rupture. As a result, Type I endoleaks typically require urgent attention.
- Type II – Retrograde or collateral (mesenteric, lumbar, renal accessory): These endoleaks are the most common type of endoleak. They occur when blood bleeds into the sac from small side branches of the aorta. They are generally considered benign because they are usually at low pressure and tend to resolve spontaneously over time without any need for intervention. Treatment of the endoleak is indicated if the aneurysm sac continues to expand.
- Type III – Midgraft (fabric tear, graft dislocation, graft disintegration): These endoleaks occur when blood flows into the aneurysm sac through defects in the endograft (such as graft fractures, misaligned graft joints and holes in the graft fabric). Similarly to Type I endoleak, a Type III endoleak results in systemic blood pressure within the aneurysm sac that increases the risk of rupture. Therefore, Type III endoleaks typically require urgent attention.
- Type IV– Graft porosity: These endoleaks often occur soon after AAA repair and are associated with the porosity of certain graft materials. They are caused by blood flowing through the graft fabric into the aneurysm sac. They do not usually require treatment and tend to resolve within a few days of graft placement.
- Type V – Endotension: A Type V endoleak is a phenomenon in which there is continued sac expansion without radiographic evidence of a leak site. It is a poorly understood abnormality. One theory that it is caused by pulsation of the graft wall, with transmission of the pulse wave through the aneurysm sac to the native aneurysm wall. Alternatively it may be due to intermittent leaks which are not apparent at imaging. It can be difficult to identify and treat any cause.

Endovascular aneurysm repair

Endovascular aneurysm repair (EVAR) is a technique that involves placing a stent –graft prosthesis within an aneurysm. The stent-graft is inserted through a small incision in the femoral artery in the groin, then delivered to the site of the aneurysm using catheters and guidewires and placed in position under X-ray guidance.

- Conventional EVAR refers to placement of an endovascular stent graft in an AAA where the anatomy of the aneurysm is such that the ‘instructions for use’ of that particular device are adhered to. Instructions for use define tolerances for AAA anatomy that the device manufacturer considers appropriate for that device. Common limitations on AAA anatomy are infrarenal neck length (usually >10mm), diameter (usually ≤30mm) and neck angle relative to the main body of the AAA
- Complex EVAR refers to a number of endovascular strategies that have been developed to address the challenges of aortic proximal neck fixation associated with complicated aneurysm anatomies like those seen in juxtarenal and suprarenal AAAs.

These strategies include using conventional infrarenal aortic stent grafts outside their 'instructions for use', using physician-modified endografts, utilisation of customised fenestrated endografts, and employing snorkel or chimney approaches with parallel covered stents.

Goal directed therapy

Goal directed therapy refers to a method of fluid administration that relies on minimally invasive cardiac output monitoring to tailor fluid administration to a maximal cardiac output or other reliable markers of cardiac function such as stroke volume variation or pulse pressure variation.

Post processing technique

For the purpose of this review, a post-processing technique refers to a software package that is used to augment imaging obtained from CT scans, (which are conventionally presented as axial images), to provide additional 2- or 3-dimensional imaging and data relating to an aneurysm's, size, position and anatomy.

Permissive hypotension

Permissive hypotension (also known as hypotensive resuscitation and restrictive volume resuscitation) is a method of fluid administration commonly used in people with haemorrhage after trauma. The basic principle of the technique is to maintain haemostasis (the stopping of blood flow) by keeping a person's blood pressure within a lower than normal range. In theory, a lower blood pressure means that blood loss will be slower, and more easily controlled by the pressure of internal self-tamponade and clot formation.

Remote ischemic preconditioning

Remote ischemic preconditioning is a procedure that aims to reduce damage (ischaemic injury) that may occur from a restriction in the blood supply to tissues during surgery. The technique aims to trigger the body's natural protective functions. It is sometimes performed before surgery and involves repeated, temporary cessation of blood flow to a limb to create ischemia (lack of oxygen and glucose) in the tissue. In theory, this "conditioning" activates physiological pathways that render the heart muscle resistant to subsequent prolonged periods of ischaemia.

Tranexamic acid

Tranexamic acid is an antifibrinolytic agent (medication that promotes blood clotting) that can be used to prevent, stop or reduce unwanted bleeding. It is often used to reduce the need for blood transfusion in adults having surgery, in trauma and in massive obstetric haemorrhage.