

## Caesarean birth

### [H] Placenta accreta spectrum (PAS)

*NICE guideline number NG192 (update CB4)*

*Evidence review underpinning recommendations 1.2.7 to 1.2.14  
in the NICE guideline*

*November 2023*

*Draft for consultation*



## **Disclaimer**

The recommendations in this guideline represent the view of NICE, arrived at after careful consideration of the evidence available. When exercising their judgement, professionals are expected to take this guideline fully into account, alongside the individual needs, preferences and values of their patients or service users. The recommendations in this guideline are not mandatory and the guideline does not override the responsibility of healthcare professionals to make decisions appropriate to the circumstances of the individual patient, in consultation with the patient and/or their carer or guardian.

Local commissioners and/or providers have a responsibility to enable the guideline to be applied when individual health professionals and their patients or service users wish to use it. They should do so in the context of local and national priorities for funding and developing services, and in light of their duties to have due regard to the need to eliminate unlawful discrimination, to advance equality of opportunity and to reduce health inequalities. Nothing in this guideline should be interpreted in a way that would be inconsistent with compliance with those duties.

NICE guidelines cover health and care in England. Decisions on how they apply in other UK countries are made by ministers in the [Welsh Government](#), [Scottish Government](#), and [Northern Ireland Executive](#). All NICE guidance is subject to regular review and may be updated or withdrawn.

## **Copyright**

© NICE 2023. All rights reserved. Subject to [Notice of rights](#).

ISBN: TBC

## Contents

<b>Placenta accreta spectrum (PAS)</b> .....	<b>6</b>
Review question.....	6
Introduction.....	6
Summary of the protocol.....	6
Methods and process.....	7
Diagnostic evidence.....	7
Summary of included studies.....	11
Summary of the evidence.....	30
Economic evidence.....	32
Economic model.....	32
The committee’s discussion and interpretation of the evidence.....	32
Recommendations supported by this evidence review.....	36
References – included studies.....	37
<b>Appendices</b> .....	<b>42</b>
<b>Appendix A     Review protocols</b> .....	<b>42</b>
Review protocol for review question: What is the accuracy of imaging techniques for diagnosis of a placenta accreta spectrum (PAS) in pregnant women who have had a previous caesarean birth and are currently diagnosed with placenta praevia?.....	42
<b>Appendix B     Literature search strategies</b> .....	<b>51</b>
Literature search strategies for review question: What is the accuracy of imaging techniques for diagnosis of a placenta accreta spectrum (PAS) in pregnant women who have had a previous caesarean birth and are currently diagnosed with placenta praevia?.....	51
<b>Appendix C     Diagnostic evidence study selection</b> .....	<b>60</b>
Study selection for: What is the accuracy of imaging techniques for diagnosis of a placenta accreta spectrum (PAS) in pregnant women who have had a previous caesarean birth and are currently diagnosed with placenta praevia?.....	60
<b>Appendix D     Evidence tables</b> .....	<b>61</b>
Evidence tables for review question: What is the accuracy of imaging techniques for diagnosis of a placenta accreta spectrum (PAS) in pregnant women who have had a previous caesarean birth and are currently diagnosed with placenta praevia?.....	61
<b>Appendix E     Forest plots</b> .....	<b>185</b>
Forest plots for review question: What is the accuracy of imaging techniques for diagnosis of a placenta accreta spectrum (PAS) in pregnant women who have had a previous caesarean birth and are currently diagnosed with placenta praevia?.....	185
<b>Appendix F     GRADE tables</b> .....	<b>188</b>
GRADE tables for review question: What is the accuracy of imaging techniques for diagnosis of a placenta accreta spectrum (PAS) in	

---

	pregnant women who have had a previous caesarean birth and are currently diagnosed with placenta praevia? .....	188
<b>Appendix G</b>	<b>Economic evidence study selection</b> .....	<b>196</b>
	Study selection for: What is the accuracy of imaging techniques for diagnosis of a placenta accreta spectrum (PAS) in pregnant women who have had a previous caesarean birth and are currently diagnosed with placenta praevia? .....	196
<b>Appendix H</b>	<b>Economic evidence tables</b> .....	<b>197</b>
	Economic evidence tables for review question: What is the accuracy of imaging techniques for diagnosis of a placenta accreta spectrum (PAS) in pregnant women who have had a previous caesarean birth and are currently diagnosed with placenta praevia? .....	197
<b>Appendix I</b>	<b>Economic model</b> .....	<b>198</b>
	Economic model for review question: What is the accuracy of imaging techniques for diagnosis of a placenta accreta spectrum (PAS) in pregnant women who have had a previous caesarean birth and are currently diagnosed with placenta praevia? .....	198
<b>Appendix J</b>	<b>Excluded studies</b> .....	<b>199</b>
	Excluded studies for review question: What is the accuracy of imaging techniques for diagnosis of a placenta accreta spectrum (PAS) in pregnant women who have had a previous caesarean birth and are currently diagnosed with placenta praevia? .....	199
<b>Appendix K</b>	<b>Research recommendations – full details</b> .....	<b>228</b>
	Research recommendations for review question: What is the accuracy of imaging techniques for diagnosis of a placenta accreta spectrum (PAS) in pregnant women who have had a previous caesarean birth and are currently diagnosed with placenta praevia? .....	228

# 1 **Placenta accreta spectrum (PAS)**

## 2 **Review question**

3 What is the accuracy of imaging techniques for diagnosis of a placenta accreta spectrum  
4 (PAS) in pregnant women who have had a previous caesarean birth and are currently  
5 diagnosed with placenta praevia?

## 6 **Introduction**

7 Women and pregnant people who have had a previous caesarean birth or other previous  
8 uterine surgery will have uterine scar tissue at the location of the incision. Following  
9 caesarean birth this scar tissue is usually in the lower segment of the uterus and if, in a  
10 subsequent pregnancy, the placenta is low-lying or placenta praevia (covering the cervix)  
11 then there is the possibility that placenta accreta may develop. This occurs when the  
12 placenta grows abnormally into the uterine wall at the location of the scar tissue. Placenta  
13 accreta includes a spectrum of conditions depending on the depth of invasion of the  
14 placenta, ranging from accreta where there is less invasion, increta where there is greater  
15 invasion and percreta where the placenta passes through the uterine wall and may grow onto  
16 surrounding tissues and organs such as the bladder or bowel. Antenatal diagnosis of  
17 placenta accreta is extremely important to prevent serious morbidity and mortality during  
18 birth, due to the excessive bleeding when the placenta fails to separate from the uterus.  
19 Early diagnosis will also allow for a carefully planned caesarean procedure with a  
20 multidisciplinary team, as other surgical and radiological procedures may be required to  
21 control bleeding and limit damage to other organs.

22 Due to the serious nature of placenta accreta, the aim of this review is to determine the most  
23 accurate imaging technique for diagnosis.

## 24 **Summary of the protocol**

25 See Table 1 for a summary of the Population, Index tests, Reference standard and Target  
26 condition (PIRT) characteristics of this review.

1 **Table 1: Summary of the protocol (PIRT table)**

<b>Population</b>	<p>Pregnant women:</p> <ul style="list-style-type: none"> <li>• with a previous lower segment caesarean birth currently diagnosed with placenta praevia or low-lying placenta.</li> <li>• with a previous uterus surgery (for example, myomectomy, perforation of the uterus) who also have a low-lying placenta, even if they do not have a caesarean birth scar.</li> </ul> <p>Population will include:</p> <ul style="list-style-type: none"> <li>• In-vitro fertilization conceptions</li> <li>• Advanced maternal age</li> <li>• Multiparity</li> <li>• Previous uterine curettage</li> <li>• Previous caesarean birth</li> </ul>
<b>Index tests</b>	<ul style="list-style-type: none"> <li>• Grey scale ultrasound (transabdominal and transvaginal)</li> <li>• Colour-flow Doppler ultrasound</li> <li>• 3D ultrasound</li> <li>• MRI (magnetic resonance imaging) (all types)</li> </ul> <p>To analyse grey scale transabdominal and transvaginal ultrasound together.</p>
<b>Reference standard</b>	<ul style="list-style-type: none"> <li>• Operative findings without histology reports/lab findings</li> <li>• Operative findings with histology reports/lab findings</li> <li>• Post caesarean birth examination with histology.</li> </ul>
<b>Target condition</b>	Placenta accreta spectrum
<b>Outcome</b>	<p><b>Critical</b></p> <p>Diagnostic accuracy of imaging techniques (grey scale ultrasound, colour-flow Doppler ultrasound, 3D ultrasound, MRI) with diagnostic test accuracy data (that is, TP, FP, TN, FN) that allows calculation of:</p> <ul style="list-style-type: none"> <li>• Sensitivity and specificity</li> </ul>

2 *FN: false negative; FP: false positive; MRI: magnetic resonance imaging; PAS: placenta accreta spectrum; PIRT:*  
3 *Population, Index tests, Reference standard and Target condition; TN: true negative; TP: true positive; 3D: three*  
4 *dimensional*

5 For further details see the review protocol in appendix A.

## 6 **Methods and process**

7 This evidence review was developed using the methods and process described in  
8 [Developing NICE guidelines: the manual](#). Methods specific to this review question are  
9 described in the review protocol in appendix A.

10 Declarations of interest were recorded according to [NICE's conflicts of interest policy](#).

## 11 **Diagnostic evidence**

### 12 **Included studies**

13 Forty one studies were included for this review, 1 cross-sectional study (Naghshineh 2015),  
14 27 prospective cohort studies (Abdel Magied 2018, Akhtar 2020, Alalfy 2021, Algebally 2014,  
15 Alici Davutoglu 2018, Bourgioti 2021, Cali 2018b, El Wakeel 2018, Elhawary 2013, Gadelrab  
16 2022, Gulati 2021, Haba 2022, Haidar 2017, Hashem 2016, Hussein 2022, Khalaf 2019,  
17 Maher 2013, Mansour 2011, Mathur 2019, Maurea 2018, Othman 2018, Panaiotova 2019,  
18 Patru 2019, Rezk 2016, Satija 2015, Shweel 2012, UI Hassan 2020), 12 retrospective cohort

1 studies (Cali 2018a, Coutinho 2021, di Pasquo 2020, Einerson 2021, Faralli 2022, Fiocchi  
2 2020, Fujisaki 2017, Lim 2011, Maurea 2022, Millischer 2017, Romeo 2019, Romeo 2021),  
3 and 1 cohort study, which included both retrospective and prospective cohorts (Reeder  
4 2022).

5 The included studies are summarised in Table 2.

## 6 **Population**

7 All studies included pregnant women with placenta praevia or low-lying placenta and  
8 previous caesarean birth or other uterine procedures (for example, myomectomy or dilatation  
9 and curettage).

10 Fourteen studies included pregnant women with a previous caesarean birth (Akhtar 2020,  
11 Alici Davutoglu 2018, Gulati 2021, Haba 2022, Hussein 2022, Khalaf 2019, Mathur 2019,  
12 Maurea 2022, Millischer 2017, Othman 2018, Patru 2019, Romeo 2019, Romeo 2021, Ul  
13 Hassan 2020). Twenty six studies included pregnant women with a previous caesarean birth  
14 and other uterine surgeries (for example, dilatation and curettage, fractional curettage,  
15 hysterotomies, myomectomy, and endometrial ablation) (Abdel Magied 2018, Alalfy 2021,  
16 Algebally 2014, Bourgioti 2021, Cali 2018a, Cali 2018b, Coutinho 2021, di Pasquo 2020,  
17 Einerson 2021, El Wakeel 2018, Elhawary 2013, Faralli 2022, Fiocchi 2020, Fujisaki 2017,  
18 Gadelrab 2022, Haidar 2017, Lim 2011, Maher 2013, Mansour 2011, Maurea 2018,  
19 Naghshineh 2015, Panaiotova 2019, Reeder 2022, Rezk 2016, Satija 2015, Shweel 2012).  
20 One study included participants with uterine surgery, but types of uterine surgery were not  
21 specified (Hashem 2016).

22 Twenty eight studies included pregnant women with placenta praevia (Abdel Magied 2018,  
23 Akhtar 2020, Alalfy 2021, Algebally 2014, Alici Davutoglu 2018, Cali 2018a, Cali 2018b,  
24 Coutinho 2021, Einerson 2021, El Wakeel 2018, Faralli 2022, Fiocchi 2020, Fujisaki 2017,  
25 Haba 2022, Haidar 2017, Lim 2011, Mansour 2011, Mathur 2019, Maurea 2018, Maurea  
26 2022, Millischer 2017, Naghshineh 2015, Patru 2019, Reeder 2022, Rezk 2016, Romeo  
27 2019, Romeo 2021, Satija 2015). Thirteen studies included pregnant women with placenta  
28 praevia or low-lying placenta (Bourgioti 2021, di Pasquo 2020, Elhawary 2013, Gadelrab  
29 2022, Gulati 2021, Hashem 2016, Hussein 2022, Khalaf 2019, Maher 2013, Othman 2018,  
30 Panaiotova 2019, Shweel 2012, Ul Hassan 2020).

## 31 **Index tests**

32 Single studies investigated the diagnostic test accuracy (DTA) of the following imaging  
33 techniques: three-dimensional (3D) multislice view Doppler ultrasound (Gadelrab 2022), 3D  
34 tomographic ultrasound imaging (3D-TUI) (Alalfy 2021), 3D power Doppler ultrasound plus  
35 3D tomographic ultrasound imaging (3D-TUI) (Alalfy 2021), Doppler ultrasound (unspecified  
36 type) (Akhtar 2020), grey scale ultrasound plus power Doppler ultrasound (Haba 2022), grey  
37 scale ultrasound plus colour-flow and power Doppler ultrasounds (Lim 2011), grey scale  
38 ultrasound plus colour-flow Doppler ultrasound integrated by pulse wave spectral Doppler  
39 (Romeo 2019), grey scale ultrasound plus colour-flow Doppler ultrasound with or without MRI  
40 (Coutinho 2021), and ultrasound (sonography including Doppler interrogation) with or without  
41 MRI (Reeder 2022).

42 Three studies investigated the DTA of grey scale ultrasound (Fujisaki 2017, Gadelrab 2022,  
43 Haidar 2017), 2 studies assessed colour-flow Doppler ultrasound (Naghshineh 2015, Shweel  
44 2012), and 13 studies assessed grey scale ultrasound plus colour-flow Doppler ultrasound  
45 (Abdel Magied 2018, Algebally 2014, Alici Davutoglu 2018, Cali 2018a, Cali 2018b, El  
46 Wakeel 2018, Elhawary 2013, Faralli 2022, Gulati 2021, Hussein 2022, Mansour 2011, Rezk  
47 2016, Romeo 2021). Three studies investigated the DTA of grey scale ultrasound plus  
48 colour-flow or power Doppler ultrasound (Hashem 2016, Patru 2019, Satija 2015), and 2  
49 studies assessed grey scale ultrasound plus colour-flow and 3D power Doppler ultrasounds  
50 (di Pasquo 2020, Panaiotova 2019).



1 Twenty one studies investigated the DTA of MRI without contrast (Abdel Magied 2018,  
2 Algebally 2014, Alici Davutoglu 2018, Bourgioti 2021, Einerson 2021, El Wakeel 2018,  
3 Elhawary 2013, Haba 2022, Hashem 2016, Khalaf 2019, Lim 2011, Maher 2013, Mansour  
4 2011, Maurea 2018, Maurea 2022, Millischer 2017, Othman 2018, Romeo 2019, Romeo  
5 2021, Satija 2015, Shweel 2012), but only 2 studies investigated the DTA of MRI with  
6 contrast (Millischer 2017, Rezk 2016). Four studies investigated the DTA of MRI, but these  
7 studies did not specify type of MRI (that is, MRI with or without contrast) (Faralli 2022,  
8 Focchi 2020, Mathur 2019, UI Hassan 2020).

9 In this review, imaging performed around 20 weeks of gestation (18-22 weeks) was  
10 considered as the first scan for PAS as the committee acknowledged that every pregnant  
11 woman has an anomaly scan at 20 weeks. In addition, they acknowledged that the second  
12 scan for PAS is generally performed around 28 weeks, but it can also be done before 28  
13 weeks if there is a clinical indication (please see review protocol in Appendix A).

#### 14 **Reference standard**

15 The majority of the studies used operative findings with or without histopathology or  
16 pathology results, or post caesarean birth examination with histology as the reference  
17 standard, and only 3 studies used operative findings alone (without histology reports/lab  
18 findings) (Akhtar 2020, Algebally 2014, Elhawary 2013). Studies with different reference  
19 standards were pooled in the analyses.

#### 20 **Outcomes**

21 The outcome of interest was overall diagnosis of placenta accreta spectrum (PAS), including  
22 accreta, increta and percreta. Where the data were reported separately for three sub-  
23 categories, this has been noted in the evidence tables. The included studies used different  
24 radiological features (for example, placental lacunae and myometrial thinning) and diagnostic  
25 criteria (for example, the presence of at least one of radiological features or three features)  
26 for the diagnosis of PAS. However, studies using different criteria for the diagnosis of PAS  
27 were pooled in the analyses. The included studies were required to report diagnostic  
28 accuracy of overall radiological features, and if a study assessed diagnostic accuracy of an  
29 individual feature and overall features, the latter was reported.

#### 30 **Outcome measures**

31 Sensitivity and specificity were prioritised in this review, and all included studies reported the  
32 diagnostic test accuracy (DTA) data (that is, true positive, false positive, true negative, and  
33 false negative) that allow calculation of sensitivity and specificity. Studies that only reported  
34 index test positive cases (that is, true positive and false positive) were excluded as this does  
35 not allow accurate calculation of sensitivity and specificity.

36 The following decision thresholds were used for sensitivity and specificity:

37 (1) low sensitivity or specificity (defined as <50%)

38 (2) moderate sensitivity or specificity (defined as  $\geq 50\%$  to <90%)

39 (3) high sensitivity or specificity (defined as  $\geq 90\%$ ).

40 When a study reported the DTA data assessed by less experienced and more experienced  
41 examiners/study personnel, the data assessed by more experienced examiners/study  
42 personnel was reported in this review.

43 There was a variation in the role (sonographer/fetal medicine specialist/consultant  
44 radiologist/obstetrician) and the level of experience of the operators in performing the  
45 imaging tests in the studies. Ultrasound scans were performed by sonographers in 2 studies  
46 (di Pasquo 2020, Patru 2019), obstetricians in 2 studies (Romeo 2019, Romeo 2021),

1 maternal-fetal medicine specialist in 1 study (Haba 2022), radiologists in 2 studies (Abdel  
2 Magied 2018, Satija 2015), sonographers and radiologists in 1 study (Algebally 2014),  
3 sonographers and consultant with experience in the diagnosis of PAS in 1 study (Coutinho  
4 2021), a sonographer and an expert in the diagnosis of PAS in 1 study (Panaiotova 2019),  
5 sonographers and maternal-fetal medicine specialists in 2 studies (Haidar 2017, Lim 2011),  
6 consultants or physicians of obstetrics and gynaecology and radiologists in 2 studies  
7 (Hashem 2016, Mansour 2011), and experts in the diagnosis of PAS in 1 study (Faralli  
8 2022). MRI scans were conducted by radiologists with different levels of experience in 19  
9 studies (Abdel Magied 2018, Algebally 2014, Alici Davutoglu 2018, Bourgioti 2021, Einerson  
10 2021, Fiocchi 2020, Hashem 2016, Khalaf 2019, Lim 2011, Mansour 2011, Maher 2013,  
11 Maurea 2018, Maurea 2022, Millischer 2017, Othman 2018, Reeder 2022, Romeo 2019,  
12 Romeo 2021, Satija 2015), and experts in the diagnosis of PAS in 1 study (Faralli 2022).

13 Fifteen studies did not report information on the study personnel who performed the tests  
14 (Akhtar 2020, Alfaly 2021, Cali 2018a, Cali 2018b, El Wakeel 2018, Elhawary 2013, Fujisaki  
15 2017, Gadelrab 2022, Gulati 2021, Hussein 2022, Mathur 2019, Naghshineh 2015, Rezk  
16 2016, Shweel 2012, UI Hassan 2020).

## 17 **Analysis**

18 Meta-analysis was performed where possible (for example, if there were at least three  
19 studies reporting the same index test) and where there was no significant variation between  
20 studies or very serious heterogeneity. For those where meta-analysis could not be  
21 performed, the results for each individual study have been reported in the review.

22 In this review, studies were categorised and reported separately according to type of imaging  
23 (that is, ultrasound, MRI, and ultrasound with or without MRI).

24 Diagnostic accuracy can also be different between different types of ultrasounds; therefore,  
25 different types of ultrasound were reported separately (that is, grey scale ultrasound, colour-  
26 flow Doppler ultrasound, 3D multislice view Doppler ultrasound, and 3D tomographic  
27 ultrasound imaging). However, the DTA of the combination of different types of ultrasound  
28 (that is, grey scale ultrasound plus colour-flow Doppler ultrasound, grey scale ultrasound plus  
29 power Doppler ultrasound, grey scale ultrasound plus colour-flow and power Doppler  
30 ultrasounds, grey scale ultrasound plus colour-flow or power Doppler ultrasound, grey scale  
31 ultrasound plus colour-flow and 3D power Doppler ultrasounds, and grey scale ultrasound  
32 plus colour-flow Doppler ultrasound integrated by pulse wave spectral Doppler) were also  
33 reported in this review because some studies reported such data and the committee also  
34 acknowledged that combination of ultrasound methods (for example, grey scale ultrasound  
35 plus colour-flow Doppler ultrasound) was used clinically as it may be useful for diagnosis of  
36 PAS.

37 The committee advised that MRI with contrast is not normally used in pregnancy, therefore,  
38 they agreed that the data on MRI without contrast and MRI with contrast should be reported  
39 separately to determine if there were differences in diagnostic accuracy between them.

40 The committee also acknowledged that the combination of ultrasound and MRI is often  
41 useful, therefore studies reporting the DTA of the combination of ultrasound and MRI were  
42 reported separately.

43 Evidence was sub-grouped by the following when there was significant heterogeneity in the  
44 outcomes: BMI thresholds and timing of imaging for the second scan (please see details in  
45 full protocol in Appendix A). However, sub-group analysis could not be conducted in this  
46 review because the majority of studies did not report BMI and specific timing for the second  
47 scan.

48 The new evidence identified from this review update was not pooled with evidence from  
49 previous review version due to differences in stratifications and subgroups.

1 See the literature search strategy in appendix B and study selection flow chart in appendix C.

2 **Excluded studies**

3 Studies not included in this review are listed, and reasons for their exclusion are provided in  
4 appendix J.

5 **Summary of included studies**

6 Summaries of the studies that were included in this review are presented in Table 2.

7 **Table 2: Summary of included studies.**

Study	Population	Index test(s)	Reference standard(s)	Outcomes
Abdel Magied 2018  Prospective cohort study  Egypt	N=23  Pregnant women with placenta praevia and risk factors for PAS  Age in years, mean (SD): 30.96 (NR)  Gestational age in weeks, range: 25-37  Parity: multiparous  BMI: NR	1. Grey scale ultrasound plus colour-flow Doppler ultrasound (transabdominal and/or transvaginal) 2. MRI without contrast  Ultrasound and MRI scans performed before 36 weeks of gestation	Operative findings with pathology reports	<ul style="list-style-type: none"> <li>• Sensitivity</li> <li>• Specificity</li> </ul>
Akhtar 2020  Prospective cohort study  Pakistan	N=27  Pregnant women with PAS major or anterior low-lying placenta and previous caesarean section  Age in years, mean (SD): 35.8 (NR)  Gestational age in weeks at birth, mean (SD): 36 (NR)  Parity: NR  BMI: NR	1. Doppler ultrasound (unspecified type)  Timing of scan not reported	Diagnosis was confirmed at the time of caesarean section	<ul style="list-style-type: none"> <li>• Sensitivity</li> <li>• Specificity</li> </ul>

Study	Population	Index test(s)	Reference standard(s)	Outcomes
Alalfy 2021  Prospective cohort study  Egypt	N=90  Pregnant women with gestational age 30 to 40 weeks, one or more previous caesarean section and placenta praevia  Age in years, mean (SD): 31.9 (4.9)  Gestational age in weeks, mean (SD): 35.4 (1.6)  Parity: NR  BMI in kg/m <sup>2</sup> , mean (SD): 30.7 (3.4)	1. 3D-TUI (transabdominal and transvaginal) 2. 3D power Doppler ultrasound plus 3D-TUI (transabdominal and transvaginal)  Timing of scan not reported	Operative findings with pathology reports	<ul style="list-style-type: none"> <li>• Sensitivity</li> <li>• Specificity</li> </ul>
Algebally 2014  Prospective cohort study  Qatar	N=100  Pregnant women with placenta praevia and risk factors for abnormal placentation, including previous uterine interventions  Age in years, mean (SD): 33 (NR)  Gestational age in weeks at birth: 36  Parity: grand multiparity  BMI: NR	1. Grey scale ultrasound plus colour-flow Doppler ultrasound* 2. MRI without contrast  Timing of scan not reported  *Ultrasound approach not reported	Operative findings at caesarean section without histology reports/lab findings	<ul style="list-style-type: none"> <li>• Sensitivity</li> <li>• Specificity</li> </ul>
Alici Davutoglu 2018  Prospective cohort study	N=29  Pregnant women with anterior placenta previa and at least one of risk factors for PAS, including a	1. Grey scale ultrasound plus colour-flow Doppler ultrasound (transvaginal) 2. MRI without contrast	Operative findings with/without pathology reports	<ul style="list-style-type: none"> <li>• Sensitivity</li> <li>• Specificity</li> </ul>

Study	Population	Index test(s)	Reference standard(s)	Outcomes
Turkey	<p>previous caesarean birth, curettage or myomectomy</p> <p>Age in years, mean (SD): PAS: 31.7 (4.2) No PAS: 30.9 (5.9)</p> <p>Gestational age in weeks at birth, mean (SD): PAS: 34.6 (5.0) No PAS: 37.7 (0.8)</p> <p>Parity, mean (SD): PAS: 2.2 (0.7) No PAS: 1.1 (0.7)</p> <p>BMI: NR</p>	<p>Ultrasound and MRI scans performed at mean (SD) gestational age 29.4 (2.9) and 30.4 (2.4) weeks, respectively</p>		
<p>Bourgioti 2021</p> <p>Prospective cohort study</p> <p>Greece</p>	<p>N=155</p> <p>Pregnant women in the third trimester who were at high risk for PAS (due to presence of placenta praevia and/or suspected PAS on second-trimester ultrasound) and were referred for MRI examination</p> <p>Age in years, mean (SD): 35 (5)</p> <p>Gestational age: NR</p> <p>BMI: NR</p>	<p>1. MRI without contrast</p> <p>MRI performed at mean (SD) gestational age 32 (3) weeks</p>	<p>Post caesarean birth examination with histology</p>	<ul style="list-style-type: none"> <li>• Sensitivity</li> <li>• Specificity</li> </ul>
<p>Cali 2018a</p> <p>Retrospective cohort study</p> <p>Italy</p>	<p>N=188</p> <p>Pregnant women with at least a previous caesarean section and/or uterus surgery and</p>	<p>1. Grey scale ultrasound plus colour-flow Doppler ultrasound (transabdominal with or without transvaginal)</p>	<p>Operative findings with histology reports</p>	<ul style="list-style-type: none"> <li>• Sensitivity</li> <li>• Specificity</li> </ul>

Study	Population	Index test(s)	Reference standard(s)	Outcomes
	<p>placenta praevia who had ultrasound scan at 11 to 14 weeks of gestation</p> <p>Age in years, mean (SD): 31.7 (5.4)</p> <p>Gestational age in weeks at birth, mean (SD): 35.4 (2.3)</p> <p>Parity, median (range): PAS: 2 (2-3) No PAS: 2 (0-2)</p> <p>BMI: NR</p>	<p>Ultrasound scans performed between 11 and 14 weeks of gestation</p>		
<p>Cali 2018b</p> <p>Prospective cohort study</p> <p>Italy</p>	<p>N=210</p> <p>Pregnant women with placenta praevia and at least one previous caesarean birth or uterus surgery</p> <p>Age in years, mean (SD): 32.1 (5.4)</p> <p>Gestational age in weeks at birth, mean (SD): 35.3 (2.2)</p> <p>Parity, median (range): PAS: 2 (2-3) No PAS: 2 (0-2)</p> <p>BMI: NR</p>	<p>1. Grey scale ultrasound and colour-flow Doppler ultrasound (transabdominal and transvaginal)</p> <p>Ultrasound scans performed at second and third trimester, but the exact gestational age in weeks at scan not reported</p>	<p>Operative findings and histology reports</p>	<ul style="list-style-type: none"> <li>• Sensitivity</li> <li>• Specificity</li> </ul>
<p>Coutinho 2021</p> <p>Retrospective cohort study</p> <p>UK</p>	<p>N=173 (Diagnostic cohort) (Whole cohort or screening cohort N=415)</p> <p>Age in years, median (IQR)*:</p>	<p>1. Grey scale ultrasound (2D) plus colour-flow Doppler ultrasound with or without MRI**</p>	<p>Operative findings with or without histopathological reports</p>	<ul style="list-style-type: none"> <li>• Sensitivity</li> <li>• Specificity</li> </ul>

Study	Population	Index test(s)	Reference standard(s)	Outcomes
	<p>No PAS: 35.0 (32.0-38.0) PAS: 39.0 (35.0-40.7)</p> <p>Parity 0*: No PAS: N=180 PAS: N=1</p> <p>Parity 1*: No PAS: N=142 PAS: N=7</p> <p>Parity ≥2*: No PAS: N=15 PAS: N=9</p> <p>BMI in kg/m<sup>2</sup>, median (IQR)*: No PAS: 24.2 (21.9-27.6) PAS: 25.9 (22.9-28.3)</p> <p>*The data on screening cohort (N=415) was reported as data on diagnostic cohort was not reported separately.</p>	<p>Timing of ultrasound and MRI scans not reported</p> <p>**Ultrasound approach not reported and unclear whether MRI with or without contrast was used</p>		
<p>di Pasquo 2020</p> <p>Retrospective cohort study</p> <p>Italy</p>	<p>N=332</p> <p>Pregnant women with low-lying placenta or placenta praevia at ≥26 weeks of gestation and previous uterine intervention, and delivery and histopathologic results</p> <p>Age in years, median (IQR): 33.0 (29.0-37.0)</p> <p>Gestational age in weeks at birth, median (IQR): 36.1 (35.0-37.0)</p>	<p>1. Grey scale ultrasound plus colour-flow and 3D power Doppler ultrasounds (transabdominal and transvaginal)</p> <p>Timing of scan not reported</p>	<p>Operative findings with/without histology reports</p>	<ul style="list-style-type: none"> <li>• Sensitivity</li> <li>• Specificity</li> </ul>

Study	Population	Index test(s)	Reference standard(s)	Outcomes
	Parity, median (IQR): 1 (0-2)  Prepregnancy BMI in kg/m <sup>2</sup> , median (IQR): 24.2 (21.7-26.6)			
Einerson 2021  Retrospective cohort study  USA	N=68  Pregnant women with placenta praevia and previous caesarean birth who had MRI during the second or third trimester  Age in years, median (IQR): 33.0 (29-37)  Gestational age at birth, median (IQR): 34.8 (33.7-36.2)  Parity, median (IQR): 2.0 (1-3)  BMI: NR	1. MRI without contrast  MRI performed at second or third trimester, but the exact gestational age in weeks at scan not reported	Operative findings with histology reports	<ul style="list-style-type: none"> <li>• Sensitivity</li> <li>• Specificity</li> </ul>
El Wakeel 2018  Prospective cohort study  Egypt	N=20  Pregnant women with persistent placenta praevia after 28 weeks of gestation, implantation on the lower segment of uterus, and previous uterus interventions  Age in years, mean (SD): 30.9 (NR)  Gestational age in weeks, range: 28-37  Parity: NR	1. Grey scale ultrasound plus colour-flow Doppler ultrasound (transabdominal) 2. MRI without contrast  Ultrasound and MRI scans performed between 28 and 37 weeks of gestation	Operative findings with pathology report	<ul style="list-style-type: none"> <li>• Sensitivity</li> <li>• Specificity</li> </ul>



Study	Population	Index test(s)	Reference standard(s)	Outcomes
	BMI: NR			
Elhawary 2013  Prospective cohort study  Egypt	N=39  Pregnant women with placenta praevia and at least one of the following risk factors: age over 35 years, grand multiparity, and previous uterine interventions  Age in years, mean (range): 32.2 (23-40)  Gestational age in weeks at birth, range: 35-37  Parity 1: N=5 Parity 2: N=7 Parity 3: N=19 Parity 4: N=8  BMI: NR	1. Grey scale ultrasound plus colour-flow Doppler ultrasound (transabdominal and translabial) 2. MRI without contrast  Ultrasound scans performed at mean gestational age 29.3 weeks, and MRI scan performed 2 weeks after ultrasound scan	Operative findings at caesarean section	<ul style="list-style-type: none"> <li>• Sensitivity</li> <li>• Specificity</li> </ul>
Faralli 2022  Retrospective cohort study  Italy	N=104  Pregnant women with at least one previous caesarean section and placenta previa or low-lying placenta  Age in years, mean (SD): No PAS: 37(5.5) Accreta: 38 (5.6) Increta: 40 (7.5) Percreta: 38 (8)  Gestational age: NR  Parity: NR  BMI: NR	1. Grey scale ultrasound plus colour-flow Doppler ultrasound (transabdominal/transvaginal) 2. MRI (unspecified type)*  Ultrasound and MRI scans performed in third trimester  *Unclear whether MRI with or without contrast was used	Operative findings with histology reports	<ul style="list-style-type: none"> <li>• Sensitivity</li> <li>• Specificity</li> </ul>

Study	Population	Index test(s)	Reference standard(s)	Outcomes
Fiocchi 2020  Retrospective cohort study  Italy	N=26  Pregnant women at intermediate or high risk for PAS (including placenta praevia and previous caesarean sections) who had ultrasound evaluation  Age in years, mean (SD): 36.24 (6.16)  Gestational age in weeks, mean (SD): 33.81 (5.36)  Parity, mean (SD): 1.54 (1.75)  BMI in kg/m <sup>2</sup> , mean (SD): 23.90 (17.52)	1. MRI (unspecified type)*  MRI scan performed before 38th weeks of gestation  *Unclear whether MRI with or without contrast was used	Operative findings with histology reports	<ul style="list-style-type: none"> <li>• Sensitivity</li> <li>• Specificity</li> </ul>
Fujisaki 2017  Retrospective cohort study  Japan	N=41  Pregnant women with placenta praevia with or without risk factors for PAS  Age in years, mean (SD): 34.0 (5.5)  Gestational age in weeks at birth, mean (SD): 34.1 (4.1)  Parity: Primipara or nulliparous: N=9 Multiparity: N=32  BMI: NR	1. Grey scale ultrasound (2D; transabdominal or transvaginal)  Ultrasound performed after 20 weeks of gestation	Post caesarean birth examination with histology	<ul style="list-style-type: none"> <li>• Sensitivity</li> <li>• Specificity</li> </ul>
Gadelrab 2022	N=78  Pregnant women with persistent	1. Grey scale ultrasound (2D; transabdominal) 2. 3D multislice view Doppler	Operative findings with histopathological results	<ul style="list-style-type: none"> <li>• Sensitivity</li> <li>• Specificity</li> </ul>

Study	Population	Index test(s)	Reference standard(s)	Outcomes
Prospective cohort study  Egypt	low-lying anterior placenta after 28 weeks of gestation and previous caesarean section  Age in years, mean (SD): 29.6 (4.75)  Gestational age: at least 28 weeks  Parity 1: N=15 Parity 2: N=22 Parity 3: N=17 Parity 4: N=12 Parity ≥5: N=12  BMI in kg/m <sup>2</sup> , mean (SD): 26.37 (4.93)	ultrasound (transabdominal)  Ultrasound scans performed after 28 weeks of gestation		
Gulati 2021  Prospective cohort study  India	N=50  Pregnant women with placenta praevia, period of gestation 24 weeks or over and previous caesarean section  Age <25: N=15 Age 25-29: N=20 Age 30-34 N=7 Age >34: N=8  Gestational age: 24 weeks or above  Gravidity <3: N=20 Gravidity 3-6: N=29 Gravidity >6: N=1  BMI: NR	1. Grey scale ultrasound plus colour-flow Doppler ultrasound (transabdominal)  Timing of scan not reported clearly although some participants had scan around 32 weeks	Histopathological/ per-operative findings.	<ul style="list-style-type: none"> <li>• Sensitivity</li> <li>• Specificity</li> </ul>
Haba 2022  Prospective cohort study	N=39  Age in years, mean (SD):	1. Grey scale ultrasound plus power Doppler ultrasound	Post caesarean birth examination with histology	<ul style="list-style-type: none"> <li>• Sensitivity</li> <li>• Specificity</li> </ul>

Study	Population	Index test(s)	Reference standard(s)	Outcomes
Romania	<p>PAS: 32.0 (3.7) No PAS: 31.1 (4.2)</p> <p>Gestational age in weeks at birth, mean (SD): PAS: 35.7 (2.1) No PAS: 36.2 (1.2)</p> <p>Parity, mean (SD): PAS: 2.9 (2.1) No PAS: 2.2 (0.7)</p> <p>BMI in kg/m<sup>2</sup>, mean (SD): PAS: 30.3 (3.5) No PAS: 28.1 (1.6)</p>	<p>(transabdominal and transvaginal)</p> <p>2. MRI without contrast</p> <p>Timing of ultrasound scan not reported</p> <p>MRI scan performed between 28 and 35 weeks of gestation</p>		
<p>Haidar 2017</p> <p>Prospective cohort study</p> <p>USA</p>	<p>N=50</p> <p>Pregnant women referred to the ultrasound for the evaluation of PAS and placenta praevia between 28 and 32 weeks of gestation</p> <p>Age in years, mean (SD): PAS: 32.4 (5.5) No PAS: 31.0 (6.0)</p> <p>Gestational age in weeks at birth, mean (SD): 31.6 (5.8)</p> <p>Multiparity: N=44</p> <p>BMI in kg/m<sup>2</sup> at scan, mean (SD): PAS: 32.2 (5.9) No PAS: 29.9 (6.5)</p>	<p>1. Grey scale ultrasound (2D; transabdominal and transvaginal)</p> <p>Ultrasound scan performed at mean (SD) gestational age 30.7 (1.8) and 29.7 (5.5) weeks in participants with PAS and without PAS, respectively</p>	<p>Operative findings with histology reports</p>	<ul style="list-style-type: none"> <li>• Sensitivity</li> <li>• Specificity</li> </ul>
Hashem 2016	<p>N=39</p> <p>Pregnant women aged 20 to 40</p>	<p>1. Grey scale ultrasound plus colour-flow or power Doppler</p>	<p>Operative findings at caesarean section with or without</p>	<ul style="list-style-type: none"> <li>• Sensitivity</li> <li>• Specificity</li> </ul>

Study	Population	Index test(s)	Reference standard(s)	Outcomes
Prospective cohort study  Egypt	years with abnormal placental location and/or implantation and previous uterine surgery  Age in years, mean (SD): 30.7 (NR)  Gestational age in weeks, range: 25-37  Parity: NR  BMI: NR	ultrasound (transabdominal, transvaginal, and translabial) 2. MRI without contrast  Ultrasound and MRI scan performed between 25 and 37 weeks of gestation	pathological reports	
Husein 2022  Prospective cohort study  Egypt	N=84  Women with a singleton pregnancy, a placenta praevia or anterior low-lying placenta, and previous caesarean birth  Age in years, median (IQR): 32.0 (28.5-34.0)  Gestational age in weeks at birth, median (IQR): 36.2 (36.0-37.0)  Parity, median (IQR): 3.0 (2.0-4.0)  BMI: NR	1. Grey scale ultrasound plus colour-flow Doppler ultrasound (transabdominal and transvaginal)  Timing of scan could be at 36 weeks of gestation	Operative findings with histology reports	<ul style="list-style-type: none"> <li>• Sensitivity</li> <li>• Specificity</li> </ul>
Khalaf 2019  Prospective cohort study  Egypt	N=58  Pregnant women with placenta praevia and with or without multiple previous caesarean birth and other minor risk factors such as multiparity and	1. MRI without contrast  Timing of scan not reported	Operative findings with or without histopathological reports	<ul style="list-style-type: none"> <li>• Sensitivity</li> <li>• Specificity</li> </ul>

Study	Population	Index test(s)	Reference standard(s)	Outcomes
	<p>advanced maternal age</p> <p>Age in years, mean (SD): 31.6 (4.8)</p> <p>Gestational age: second or third trimester</p> <p>Parity, mean (SD): 3.3 (1.3)</p> <p>BMI: NR</p>			
<p>Lim 2011</p> <p>Retrospective cohort study</p> <p>USA</p>	<p>N=13</p> <p>Pregnant women with risk factors for PAS who underwent both ultrasound and MRI examinations</p> <p>Age in years, mean (range): 33 (25-42)</p> <p>Gestational age in weeks at birth, range: 30-39</p> <p>Parity 0 (nulliparous): N=1 Parity 1: N=3 Parity 2: N=5 Parity 3: N=4</p> <p>BMI: NR</p>	<p>1. Grey scale ultrasound (2D) plus colour-flow and power Doppler ultrasounds (transabdominal)</p> <p>2. MRI without contrast</p> <p>Ultrasound scans performed between 18 and 37 weeks of gestation, and MRI performed between 24 and 37 weeks</p>	<p>Operative findings with histology reports</p>	<ul style="list-style-type: none"> <li>• Sensitivity</li> <li>• Specificity</li> </ul>
<p>Maher 2013</p> <p>Prospective cohort study</p> <p>Saudi Arabia</p>	<p>N=63</p> <p>Pregnant women with low-lying placenta confirmed by ultrasound at 28 weeks of gestation and previous uterine interventions</p> <p>Age in years, mean (range): 35.5 (29-47)</p>	<p>1. MRI without contrast</p> <p>Timing of scan not reported</p>	<p>Operative findings with or without histopathological reports</p>	<ul style="list-style-type: none"> <li>• Sensitivity</li> <li>• Specificity</li> </ul>

Study	Population	Index test(s)	Reference standard(s)	Outcomes
	<p>Gestational age in weeks, mean (range): 30.3 (28-36)</p> <p>Parity, mean (range): 6.0 (3-11)</p> <p>BMI: NR</p>			
<p>Mansour 2011</p> <p>Prospective cohort study</p> <p>Egypt</p>	<p>N=35</p> <p>Pregnant women with placenta praevia and risk factors for PAS (age over 35 years, grand multiparity, and previous uterine interventions)</p> <p>Age in years, mean (SD): 32 (NR)</p> <p>Gestational age at birth: at 36 or after 36 weeks</p> <p>BMI: NR</p>	<p>1. Grey scale ultrasound plus colour-flow Doppler ultrasound (transabdominal and translabial)</p> <p>2. MRI without contrast</p> <p>Timing of scan not reported</p>	<p>Operative findings at caesarean section without histology reports</p>	<ul style="list-style-type: none"> <li>• Sensitivity</li> <li>• Specificity</li> </ul>
<p>Mathur 2019</p> <p>Prospective cohort study</p> <p>India</p>	<p>N=80</p> <p>Pregnant women with <math>\geq 28</math> weeks of gestation, placenta praevia and history of previous caesarean or presenting with bleeding per vaginum</p> <p>Gestational age at enrolment: at or after 28 weeks</p> <p>Parity: NR</p> <p>BMI: NR</p>	<p>1. MRI (unspecified type)*</p> <p>Timing of scan not reported</p> <p>*Unclear whether MRI with or without contrast was used</p>	<p>Operative findings with histopathological reports</p>	<ul style="list-style-type: none"> <li>• Sensitivity</li> <li>• Specificity</li> </ul>
<p>Maurea 2018</p>	<p>N=61</p>	<p>1. MRI without contrast</p>	<p>Post caesarean birth examination with histology</p>	<ul style="list-style-type: none"> <li>• Sensitivity</li> <li>• Specificity</li> </ul>

Study	Population	Index test(s)	Reference standard(s)	Outcomes
Prospective cohort study  Italy	Pregnant women with at least 30 weeks of gestation, placenta praevia with suspected PAS, and history of myometrium damage, including caesarean birth and abrasive or curettage interventions  Age in years, mean (SD): 33.4 (NR)  Gravidity, range: 1-12  BMI: NR	MRI scan performed at mean gestational age 34.7 weeks		
Maurea 2022  Retrospective cohort study  Italy	N=65  Pregnant women aged over 18 years with placenta praevia and available histological proof of PAS after caesarean birth or total hysterectomy  Age in years, mean (SD): 33.0 (4.6)  Parity: NR  BMI: NR	1. MRI without contrast  Timing of scan not reported	Post caesarean birth examination with histology	<ul style="list-style-type: none"> <li>• Sensitivity</li> <li>• Specificity</li> </ul>
Millischer 2017  Retrospective cohort study  France	N=20  Pregnant women with placenta praevia, at least a previous caesarean section, and suspected PAS findings on third trimester ultrasound	1. MRI without contrast 2. MRI with contrast  Timing of scan not reported	Operative findings with or without histology reports	<ul style="list-style-type: none"> <li>• Sensitivity</li> <li>• Specificity</li> </ul>



Study	Population	Index test(s)	Reference standard(s)	Outcomes
	Age in years, mean (SD): 34.7 (2.4)  Parity: NR  BMI: NR			
Naghshineh 2015  Cross-sectional study  Iran	N=50  Women with singleton pregnancy of over 28 weeks of gestation and risk factors for PAS  Age in years, mean (SD): 30.2 (4.9) Gestational age in weeks at birth: 37  Parity, mean (SD): PAS: 1.8 (1.2) No PAS: 1.5 (0.9)  BMI: NR	1. Colour-flow Doppler ultrasound*  Timing of scan not reported  *Ultrasound approach not reported	Post caesarean birth examination with histology	<ul style="list-style-type: none"> <li>• Sensitivity</li> <li>• Specificity</li> </ul>
Othman 2018  Prospective cohort study  Egypt	N=40  Pregnant women with suspected PAS findings on ultrasound and advanced maternal age with low-lying anterior placenta  Age in years, mean (SD): 29.2 (6.6)  Parity 0: N=4 Parity 1: N=14 Parity 2: N=14 Parity 3: N=4 Parity 4: N=4  BMI: NR	1. MRI without contrast  MRI scan performed at mean (SD) gestational age 33.8 (3.2) weeks	Operative findings without histology reports	<ul style="list-style-type: none"> <li>• Sensitivity</li> <li>• Specificity</li> </ul>
Panaiotova 2019	N=48	1. Grey scale ultrasound plus colour-flow and 3D power Doppler	Post caesarean birth examination with histology	<ul style="list-style-type: none"> <li>• Sensitivity</li> <li>• Specificity</li> </ul>

Study	Population	Index test(s)	Reference standard(s)	Outcomes
Prospective cohort study  UK	Pregnant women with a singleton pregnancy, history of previous uterine interventions (for example, caesarean section or myomectomy) and low-lying placenta  Age in years: NR  Parity: NR  BMI: NR	ultrasounds (transabdominal and transvaginal)  Ultrasound scans performed at 12 to 16 weeks, 20 to 24 weeks and 28 to 34 weeks of gestation		
Patru 2019  Prospective cohort study  Romania	N=46  Pregnant women with anterior placenta praevia and history of previous caesarean section  Gestational age at enrolment: third trimester  Parity: NR  BMI: NR	1. Grey scale ultrasound (2D) plus colour-flow or power Doppler ultrasound (transabdominal and transvaginal)  Timing of scan not reported	Operative findings with or without histopathological reports	<ul style="list-style-type: none"> <li>• Sensitivity</li> <li>• Specificity</li> </ul>
Reeder 2022  Retrospective cohort study and prospective cohort study  USA	N=82  Retrospective cohort: Pregnant women with clinically suspected and/or pathologically confirmed PAS  Prospective cohort: Pregnant women with $\geq 1$ or $>3$ previous caesarean section and/or intrauterine gynaecologic intervention, placenta praevia in the current pregnancy, and suspected	1. Ultrasound (sonography including Doppler interrogation; transvaginal) with or without MRI*  Timing of scan not reported  *Type of ultrasound and MRI (for example, MRI with or without contrast) were unclear	Operative findings with histopathology reports	<ul style="list-style-type: none"> <li>• Sensitivity</li> <li>• Specificity</li> </ul>

Study	Population	Index test(s)	Reference standard(s)	Outcomes
	caesarean section scar pregnancy  Age: NR  Parity: NR  BMI: NR			
Rezk 2016  Prospective cohort study  Egypt	N=74  Pregnant women with persistent placenta praevia at 32 to 34 weeks and history of previous uterine intervention  Age in years, mean (SD): 30.2 (4.3)  Parity, mean (SD): 2.8 (0.9)  BMI: NR	1. Grey scale ultrasound plus colour-flow Doppler ultrasound (transabdominal and transvaginal) 2. MRI with contrast  Ultrasound and MRI scans performed at 32 to 34 weeks of gestation	Operative findings at caesarean section with histopathology reports	<ul style="list-style-type: none"> <li>• Sensitivity</li> <li>• Specificity</li> </ul>
Romeo 2019  Retrospective cohort study  Italy	N=51  Pregnant women aged over 18 years with placenta praevia who underwent both ultrasound and MRI examinations in the same week and available histological reports after caesarean birth  Age in years, mean (range): 35 (20-45)  Gestational age in weeks, mean (SD): 35 (NR)  Gravidity, range: 1-12  BMI: NR	1. Grey scale ultrasound (B-mode) plus colour-flow Doppler ultrasound integrated by pulse wave spectral Doppler (transabdominal and transvaginal) 2. MRI without contrast  Ultrasound and MRI scans performed at 30 to 38 weeks of gestation	Post caesarean birth examination with histology	<ul style="list-style-type: none"> <li>• Sensitivity</li> <li>• Specificity</li> </ul>

Study	Population	Index test(s)	Reference standard(s)	Outcomes
Romeo 2021  Retrospective cohort study  Italy	N=70  Pregnant women aged over 18 years with placenta praevia who underwent both ultrasound and MRI examinations in the same week and available histological reports after caesarean birth  Age in years, mean (SD): 34.0 (4.8)  Parity: NR  BMI: NR	1. Grey scale ultrasound (B-mode) plus colour-flow Doppler ultrasound (transabdominal and transvaginal) 2. MRI without contrast  Timing of scan not reported	Post caesarean birth examination with histology	<ul style="list-style-type: none"> <li>• Sensitivity</li> <li>• Specificity</li> </ul>
Satija 2015  Prospective cohort study  India	N=30  Pregnant women with suspected PAS based on clinical risk factors, and pregnant women with placenta praevia confirmed by ultrasound and previous caesarean birth  Age in years, mean (SD): PAS: 25.6 (NR) No PAS: NR  Gestational age in weeks at birth, range: PAS: 26-42 No PAS: NR  Parity, range: PAS: 1-2 No PAS: NR  BMI: NR	1. Grey scale ultrasound plus colour-flow or power Doppler ultrasound (transabdominal or transvaginal) 2. MRI without contrast  Ultrasound and MRI scans performed after 20 weeks of gestation	Operative findings and/or pathology reports	<ul style="list-style-type: none"> <li>• Sensitivity</li> <li>• Specificity</li> </ul>

Study	Population	Index test(s)	Reference standard(s)	Outcomes
Shweel 2012  Prospective cohort study  Egypt	N=28  Pregnant women with abnormal placental position and one of the grey scale ultrasound features that suspects PAS  Age in years at diagnosis, mean (SD): 33.2 (NR)  Gestational age in weeks at birth, range: 35-37  Parity 1: N=5 Parity 2: N=7 Parity 3: N=11 Parity 4: N=5  BMI: NR	1. Colour-flow Doppler ultrasound (transabdominal or transvaginal) 2. MRI without contrast  Timing of scan not reported	Operative findings at caesarean section with pathology reports	<ul style="list-style-type: none"> <li>• Sensitivity</li> <li>• Specificity</li> </ul>
Ul Hassan 2020  Prospective cohort study  Pakistan	N=60  Pregnant women aged 25 to 40 years in second or third trimester with risk factors of PAS and suspected PAS findings on ultrasound  Age in years, mean (SD): 31.2 (NR)  Gestational age in weeks, mean (SD): 33.5 (NR)  Parity: NR  BMI: NR	1. MRI (unspecified type)*  Timing of scan not reported  *Unclear whether MRI with or without contrast was used	Operative findings with or without histopathology reports	<ul style="list-style-type: none"> <li>• Sensitivity</li> <li>• Specificity</li> </ul>

1 BMI: body mass index; IQR: interquartile range; MRI: magnetic resonance imaging; NR: not reported; PAS:  
2 placenta accreta spectrum; SD: standard deviation; 2D: two dimensional; 3D: three dimensional; 3D-TUI: Three  
3 Dimensional Tomographic Ultrasound Imaging

4 See the full evidence tables in appendix D and the forest plots in appendix E.

## 1 **Summary of the evidence**

2 This section is a narrative summary of the findings of the review, as presented in the GRADE  
3 tables in appendix F. For details of the committee's confidence in the evidence and how this  
4 affected recommendations, see the section on the committee's discussion of the evidence.

5 Meta-analyses were conducted for the following index tests and all types of reference  
6 standards were pooled: grey scale ultrasound, grey scale ultrasound plus colour-flow  
7 Doppler ultrasound, grey scale ultrasound plus colour-flow or power Doppler ultrasound, and  
8 MRI without contrast. Meta-analysis was conducted in Winbugs and the pooled estimates  
9 from Winbugs analysis are reported in GRADE tables.

10 Results from individual studies have been reported for the following index tests as there were  
11 insufficient studies for conducting a meta-analysis: colour-flow Doppler ultrasound, 3D  
12 multislice view Doppler ultrasound, 3D tomographic ultrasound imaging, 3D power Doppler  
13 ultrasound plus 3D tomographic ultrasound imaging, Doppler ultrasound (unspecified type),  
14 grey scale ultrasound plus power Doppler ultrasound, grey scale ultrasound plus colour-flow  
15 and power Doppler ultrasound, grey scale ultrasound plus colour-flow and 3D power Doppler  
16 ultrasounds, grey scale ultrasound plus colour-flow Doppler ultrasound integrated by pulse  
17 wave spectral Doppler, grey scale ultrasound plus colour-flow Doppler ultrasound with or  
18 without MRI, ultrasound (sonography including Doppler interrogation) with or without MRI,  
19 MRI without contrast, and MRI (unspecified type). Sensitivity and specificity of these  
20 individual studies were reported.

21 The evidence was assessed as being very low to high quality. Studies were downgraded for  
22 risk of bias as per QUADAS-2 (for example, bias due to lack of information about whether the  
23 index test results were interpreted without knowledge of the results of the reference  
24 standard), applicability issues as per QUADAS-2 (for example, inclusion of indirect  
25 population, lack of information on MRI features for diagnosis of PAS, and lack of information  
26 on the total number of participants with placenta praevia or previous caesarean birth or  
27 previous uterine intervention), inconsistency (heterogeneity), and imprecision (95%  
28 confidence intervals crossing decision making thresholds). The majority of the included  
29 studies reported timing of scan however the exact gestational age at scan was not reported  
30 in 17 studies.

31 See the GRADE tables in appendix F for the certainty of the evidence for each individual  
32 outcome.

## 33 **Ultrasound for diagnosis of PAS**

34 The evidence (3 studies, meta-analysis) showed that grey scale ultrasound (first and second  
35 scans) was moderately sensitive and highly specific for a diagnosis of PAS. The evidence  
36 was very low quality for sensitivity and low quality for specificity.

37 Colour-flow Doppler ultrasound (2 studies; unspecified timing of scan) was moderately to  
38 highly sensitive and moderately specific for a diagnosis of PAS. The evidence was low to  
39 moderate quality for sensitivity and specificity.

40 3D multislice view Doppler ultrasound (1 study; the second scan) was moderately sensitive  
41 and highly specific for a diagnosis of PAS. The evidence was moderate quality for both  
42 sensitivity and specificity.

43 3D tomographic ultrasound imaging (1 study; unspecified timing of scan) and 3D power  
44 Doppler ultrasound plus 3D tomographic ultrasound imaging (1 study; unspecified timing of  
45 scan) were considered to be highly sensitive and specific for a diagnosis of PAS. The quality  
46 of evidence was moderate.

- 1 One study showed that Doppler ultrasound (unspecified timing of scan) was highly sensitive  
2 and moderately specific for a diagnosis of PAS, but this study did not specify type of Doppler  
3 ultrasound. The quality of evidence was moderate for sensitivity and specificity.
- 4 Grey scale ultrasound plus colour-flow Doppler ultrasound (13 studies, meta-analysis) (first  
5 and second scans) was moderately sensitive and highly specific for a diagnosis of PAS. The  
6 quality of evidence was moderate.
- 7 Grey scale ultrasound plus power Doppler ultrasound (1 study; unspecified timing of scan)  
8 was moderately sensitive and highly specific for a diagnosis of PAS. The quality of evidence  
9 was moderate.
- 10 Grey scale ultrasound plus colour-flow and power Doppler ultrasounds (1 study; unspecified  
11 timing of scan) was moderately sensitive and specific for a diagnosis of PAS. The quality of  
12 evidence was very low.
- 13 Grey scale ultrasound plus colour-flow or power Doppler ultrasound (3 studies, meta-  
14 analysis) (first and second scans) was moderately sensitive and highly specific for a  
15 diagnosis of PAS. The quality of evidence was low for sensitivity and moderate for specificity.
- 16 Two studies reported the DTA of grey scale ultrasound plus colour-flow and 3D power  
17 Doppler ultrasounds. The first study found that grey scale ultrasound plus colour-flow and 3D  
18 power Doppler ultrasounds (first and second scans) was highly sensitive and specific for a  
19 diagnosis of PAS, and the quality of evidence was moderate (Panaiotova 2019). Another  
20 study found that it (unspecified timing of scan) was highly specific but not sensitive, and the  
21 quality of evidence was low (di Pasquo 2020). Therefore, there was variation in sensitivity  
22 between these two studies. This may be due to the use of different ultrasound features for  
23 diagnosis of PAS because the first study used typical ultrasound features (for example,  
24 bladder wall interruption and irregular placental vascularisation) (Panaiotova 2019), whereas  
25 the second study used a new ultrasound feature (that is, intracervical lakes) in addition to  
26 typical ultrasound features (for example, bladder wall interruption and uterovesical  
27 hypervascularity) (di Pasquo 2020).
- 28 Grey scale ultrasound plus colour-flow Doppler ultrasound integrated by pulse wave spectral  
29 Doppler (1 study; the second scan) was moderately sensitive and specific for a diagnosis of  
30 PAS. The evidence was low quality.

### 31 **MRI for diagnosis of PAS**

- 32 MRI without contrast (21 studies, meta-analysis) (first and second scans) was moderately  
33 sensitive and specific for a diagnosis of PAS. The evidence was moderate quality for both  
34 sensitivity and specificity.
- 35 MRI with contrast (2 studies; unspecified timing of scan in 1 study and the second scan in 1  
36 study) was highly sensitive and moderately specific for a diagnosis of PAS. The evidence  
37 was moderate quality for sensitivity and low to moderate quality for specificity.
- 38 Four studies, which did not specify type of MRI (that is, MRI with or without contrast), found  
39 that MRI (unspecified timing of scan in 2 studies and the second scan in 2 studies) was  
40 moderately to highly sensitive and specific for a diagnosis of PAS. The evidence ranged from  
41 low to moderate quality for both sensitivity and specificity.

### 42 **Ultrasound with or without MRI for diagnosis of PAS**

- 43 Moderate-quality evidence from one study showed that grey scale ultrasound plus colour-  
44 flow Doppler ultrasound with or without MRI (unspecified timing of scan) was highly sensitive  
45 and specific for a diagnosis of PAS, but the type of MRI (that is, MRI with or without contrast)  
46 was unspecified and MRI was only performed if there were ultrasound features of

1 extrauterine invasion. Moreover, this study did not specify the total number of participants  
2 who had adjunct MRI.

3 Very low-quality evidence from another study, which did not specify type of both ultrasound  
4 and MRI, showed that ultrasound (sonography including Doppler interrogation) with or  
5 without MRI (unspecified timing of scan) was moderately sensitive and specific for a  
6 diagnosis of PAS. In this study, the type of MRI was also unspecified, and only 50% of  
7 participants had adjunct MRI to evaluate the extent and topography of trophoblast invasion  
8 and for diagnosis of PAS.

9 See appendix F for full GRADE tables.

## 10 **Economic evidence**

### 11 **Included studies**

12 A systematic review of the economic literature was conducted but no economic studies were  
13 identified which were applicable to this review question.

### 14 **Excluded studies**

15 Economic studies not included in this review are listed, and reasons for their exclusion are  
16 provided in appendix J.

### 17 **Economic model**

18 No economic modelling was undertaken for this review because the committee agreed that  
19 other topics were higher priorities for economic evaluation.

## 20 **The committee's discussion and interpretation of the evidence**

### 21 **The outcomes that matter most**

22 Sensitivity and specificity were selected as critical outcomes as these are commonly used  
23 measures of the discriminative ability of index tests, and therefore provide information about  
24 how well different imaging techniques can discriminate between pregnant women with and  
25 without PAS.

26 The committee considered the impact of true positives (correctly identifying pregnant women  
27 with PAS and starting the appropriate management), true negatives (correctly reassuring  
28 pregnant women that they do not have PAS), false positives (incorrectly diagnosing women  
29 with PAS and potentially promoting further investigations that are unnecessary or starting  
30 unnecessary treatments), and false negatives (failing to identify pregnant women with PAS  
31 who will therefore not receive required interventions and appropriate management). The  
32 committee agreed that it was imperative not to miss anyone with PAS, which is associated  
33 with increased risk of maternal and fetal morbidity and mortality, and that false negatives  
34 could be particularly impactful as they could lead to delays in treatment. Therefore, the  
35 committee agreed that they would prioritise sensitivity over specificity, as identifying all  
36 women with PAS was the primary concern, but that specificity was also an important  
37 consideration as some of the investigations and treatments could be invasive and would  
38 have resource implications.

### 39 **The quality of the evidence**

40 The quality of the evidence was assessed using GRADE methodology. The quality of  
41 evidence ranged from very low to high quality. Studies were downgraded for risk of bias if



1 there was lack of information about whether the index test results were interpreted without  
2 knowledge of the results of the reference standard.

3 To be eligible for this review, studies were required to have at least 60% of participants with  
4 placenta praevia or low-lying placenta and previous caesarean birth or other uterine  
5 procedures (for example, myomectomy or dilatation and curettage).

6 Studies were downgraded for applicability (for example, inclusion of indirect population, lack  
7 of information on MRI features for diagnosis of PAS, and lack of information on the total  
8 number of participants with placenta praevia or previous caesarean birth or previous uterine  
9 intervention). Majority of the studies were from Egypt (12 studies) and Italy (9 studies), and  
10 only two studies (Coutinho 2021, Panaiotova 2019) were from the UK. The committee also  
11 acknowledged that some uncertainty existed across the diagnostic accuracy estimates seen  
12 within the evidence, with some confidence intervals crossing the decision-making thresholds  
13 (0.90 as the upper threshold and 0.50 as the lower threshold for both sensitivity and  
14 specificity were used for assessing imprecision). The evidence was downgraded by one level  
15 when the confidence interval around the point estimate crossed one of the decision-making  
16 thresholds (0.50 or 0.90) and by two levels when the confidence interval around the point  
17 estimate crossed both of the decision-making thresholds. The upper threshold marked the  
18 point above which recommendations would be possible, and the lower threshold marked the  
19 point below which the test would be regarded as of no clinical use. Heterogeneity  
20 (inconsistency) was assessed by visual inspection of forest plots, and the evidence for grey  
21 scale ultrasound was downgraded by one increment as there was apparent heterogeneity  
22 based on point estimates and lack of overlap of confidence intervals across studies. The  
23 committee took into account the quality of the evidence, including the uncertainty in their  
24 interpretation of the evidence.

## 25 **Benefits and harms**

26 The committee agreed that placenta accreta spectrum (PAS), formerly known as morbidly  
27 adherent placenta, is a serious medical condition which is associated with an increased risk  
28 of maternal and fetal morbidity and mortality, and that it was important to identify the  
29 condition before the onset of labour to provide appropriate management and to minimise its  
30 impact on the fetus and mother.

31 The committee discussed that placenta praevia or low-lying placenta and history of previous  
32 caesarean birth (or other uterine surgery) are risk factors for PAS, and in the committee's  
33 experience, the development of PAS is extremely rare in pregnant women or people without  
34 these risk factors. The committee noted that every pregnant woman or person has a routine  
35 ultrasound scan at approximately 20 weeks that checks placental location, and therefore the  
36 position of the placenta would be identified at this stage. Women or pregnant people with a  
37 previous caesarean scar or a scar from previous uterine surgery and a placenta praevia or  
38 low-lying placenta would therefore be identified as at risk and referred for further  
39 investigations for PAS.

40 Having prioritised sensitivity, but also taking into account specificity (as discussed in 'the  
41 outcomes that matter most') the committee then reviewed the evidence for the sensitivity and  
42 specificity of the ultrasound and MRI techniques to diagnose PAS.

43 In this review, 12 types of ultrasound were identified for diagnosis of PAS and both  
44 transabdominal and transvaginal approaches were reported. In the committee's clinical  
45 knowledge and experience, both transabdominal and transvaginal approaches are used in  
46 clinical practice, with operators using whichever gave the best images for the area or organs  
47 they wished to visualise, so the committee agreed that the ultrasound approach need not be  
48 specified in recommendations.

49 For the majority of the types of ultrasound scan the sensitivity was moderate ( $\geq 50\%$  to  
50  $< 90\%$ ), but at the top end of this range and usually above 80%, with similar results for

1 specificity. Grey scale ultrasound had a sensitivity of 65% so the committee considered this  
2 not to be sensitive enough, and 3D tomographic ultrasound, 3D power Doppler ultrasound  
3 plus 3D tomographic ultrasound, Doppler ultrasound (type not specified) and grey scale plus  
4 colour-flow and 3D power Doppler had high sensitivity ( $\geq 90\%$ ) but this was based on very  
5 limited evidence, usually from single studies. The committee discussed that 3D ultrasound  
6 could be extremely operator dependant and a lot of clinicians may not perform 3D  
7 ultrasounds routinely and so chose not to recommend this.

8 There was moderate quality evidence from 13 studies (N=1026) which showed that grey  
9 scale ultrasound plus colour-flow Doppler ultrasound had moderate sensitivity (85%) and  
10 high specificity (94%) and the committee noted that this was the technique commonly used in  
11 practice, and therefore they recommended the use of this type of ultrasound to diagnose  
12 PAS. The committee acknowledged that some uncertainty existed across the diagnostic  
13 accuracy estimates for these imaging techniques within the evidence, but considered that the  
14 benefit of ultrasound imaging in correctly identifying women with PAS and thereby reducing  
15 the risk of maternal and fetal morbidity and mortality justified a strong recommendation.

16 The committee noted that in practice ultrasound could be performed by a number of  
17 operators including sonographers, fetal medicine specialists, obstetricians and consultant  
18 radiologists and there was also variation in the level of experience of the operators  
19 conducting the imaging tests. The review had not been designed to investigate the impact of  
20 the operator on the sensitivity and specificity, but the committee noted that in 2 studies of  
21 grey scale ultrasound plus colour-flow and 3D power Doppler sensitivity was 47% in 1 study  
22 where the scans were performed by sonographers and 100% in the other study where the  
23 scans were performed by operators who had received training in the diagnosis of PAS and  
24 who were working under the supervision of an expert. The committee highlighted that, based  
25 on their experience, ultrasounds conducted by experienced professionals would lead to more  
26 accurate diagnosis of PAS. Hence based on their experience the committee recommended  
27 that operators with expertise in diagnosis of PAS, namely consultant obstetricians  
28 specialising in fetal medicine, should perform the grey scale ultrasound and colour-flow  
29 Doppler ultrasound scans for diagnosing PAS.

30 The committee then discussed the timing of the ultrasound scan to diagnose PAS. The  
31 existing recommendations advised that ultrasound should be performed at 32 to 34 weeks,  
32 but the committee agreed this was too late to allow time for adequate planning of the birth,  
33 and that in some cases an early caesarean at about 34 weeks would be required, particularly  
34 if the woman or pregnant person experienced bleeding. The committee noted that the  
35 majority of the included studies carried out the diagnostic scan between 28 and 37 weeks.  
36 Hence based on the evidence and their collective experience, the committee recommended  
37 that women at risk of PAS should be referred for a greyscale ultrasound scan with colour  
38 Doppler at around 28 weeks. This would allow time for planning and an early birth if  
39 necessary.

40 The committee discussed that since 2020 NHSE has commissioned specialised maternity  
41 care for women and pregnant people diagnosed with placenta accreta spectrum ([Specialised  
42 Maternity Care for Patients \(child bearing age\) Diagnosed with Abnormally Invasive  
43 Placenta](#)) that enables diagnosis and care, including the birth, to be delivered in a centre with  
44 the appropriate multidisciplinary team, access to adult intensive care, level three neonatal  
45 care and access to blood products. The committee therefore recommended that pregnant  
46 women or people should be referred to a specialist regional placenta accreta centre (also  
47 called an abnormally invasive placenta, or AIP, centre) if PAS is diagnosed at the 28-week  
48 scan or cannot be ruled out at the 28-week scan.

49 The committee noted that the existing recommendation in the NICE guideline on caesarean  
50 birth recommended an MRI scan in addition to an ultrasound scan for the diagnosis of PAS.  
51 The committee discussed that current evidence did not suggest that MRI without contrast  
52 was any better than grey scale ultrasound plus colour-flow Doppler ultrasound at diagnosing

1 PAS (sensitivity 88%, specificity 87%), and although MRI with contrast did have higher  
2 sensitivity there would be a reluctance to use contrast in pregnant women or people due to  
3 the possible effects on the fetus. The committee therefore agreed that ultrasound imaging  
4 performed by an experienced operator would be as accurate as MRI and thus did not  
5 recommend MRI to confirm diagnosis of PAS. However, the committee acknowledged that  
6 MRI can be useful to assess the depth of placental invasion into the uterine myometrium and  
7 surrounding structures, which is important in planning surgical management. Therefore, the  
8 committee agreed to amend the existing recommendation to advise that MRI should be  
9 considered when planning ongoing surgical management and to assess the degree of  
10 invasion.

11 The existing recommendations from NICE guideline on caesarean birth also recommended  
12 discussion of birth options and delivery of care for women with PAS. The committee were  
13 aware that as women and pregnant people with placenta accreta are now referred to  
14 specialist regional centres for their care, where healthcare professionals with high levels of  
15 expertise in managing placenta accreta spectrum are available, it may not be necessary to  
16 leave all these detailed recommendations in place. However, they discussed that the  
17 guideline recommendations also provide information for women or pregnant people and that  
18 some may present very late in pregnancy or in labour and need to be cared for at their local  
19 maternity unit, and so agreed that these recommendations should be retained in the  
20 guideline. The committee agreed that the discussion on birth options could be carried out by  
21 a consultant or ST6 or above trainee and so amended the wording of the recommendation.  
22 The committee clarified in these recommendations that a critical care bed should be  
23 available for the woman or pregnant person, and for the baby in case they are needed, the  
24 healthcare professionals who should discuss the diagnosis of placenta accreta with women  
25 or pregnant people, and who may need to be involved in planning or carrying out the  
26 caesarean birth (for example specialists in gynaecological surgery, interventional radiology,  
27 colorectal surgery, urology or vascular surgery depending on the nature of the placenta  
28 accreta spectrum). The committee amended the recommendation on use of blood products  
29 to clarify that this should only be if the use of such products is acceptable to the woman or  
30 pregnant person and clarified the role of the paediatrician at the birth.

31 The existing recommendations also recommended locally agreed protocols for management  
32 of PAS. The committee agreed that as placenta accreta was no longer managed by local  
33 hospitals a local protocol was no longer appropriate, but that specialist regional placenta  
34 accreta centres should develop protocols with their local maternity units about how placenta  
35 accreta should be managed within the network, such as methods for referral and ongoing  
36 management. The committee agreed that the protocol should cover details of how local  
37 maternity units should provide emergency care and management if PAS was identified very  
38 late, including emergency transfer, and getting support from a specialist regional centre.

### 39 **Cost effectiveness and resource use**

40 The committee acknowledged that in current UK practice, ultrasound scans are commonly  
41 used for diagnosis of PAS and MRI is offered as an adjunct, but that the revised  
42 recommendations did not suggest MRI should be used in all women and therefore there was  
43 likely to be a cost-saving resulting from this.

44 The committee discussed that adverse outcomes from undetected PAS could have high  
45 costs to the NHS, and that diagnosing PAS, being prepared for the delivery and offering  
46 timely caesarean birth to prevent complications may lead to savings, although these were  
47 difficult to quantify as there was no evidence to link how successful diagnosis and  
48 management improved outcomes. The committee estimated that the population covered by  
49 the recommendations was relatively small, with approximately 1,000 women per year having  
50 a placenta praevia following a previous lower segment caesarean birth, and approximately  
51 220 women per year developing placenta accreta. Using the sensitivity and specificity for the  
52 use of grey scale ultrasound plus colour-flow Doppler ultrasound the committee estimated

1 that there may be 33 false negatives a year where the diagnosis is missed, and 47 false  
2 positives a year, where women who do not have PAS are diagnosed with it. The committee  
3 agreed that while it was important to minimise false negatives, there was an opportunity cost  
4 for false positives as treating these women would incur costs that were not necessary. The  
5 committee agreed that use of a fetal medicine consultant to conduct the diagnostic scan was  
6 likely to optimise the sensitivity of the scan and so would reduce the number of false  
7 negatives and positives and so was likely to be cost-effective.

8 As the specialist regional PAS centres were already set up the committee did not anticipate  
9 their recommendations to refer women to these centres would lead to additional costs.

10 **Recommendations supported by this evidence review**

11 This evidence review supports recommendations 1.2.7 to 1.2.14 in the NICE guideline.  
12

## 1 **References – included studies**

### 2 **Diagnostic**

#### 3 **Abdel Magied 2018**

4 Abdel Magied, A.M., Salah Eldin, L.A., Tohamey, Y.M., Kader, M.A.A.E., Placenta previa;  
5 MRI as an adjunct to ultrasound in assessment of suspected placental invasion, Egyptian  
6 Journal of Radiology and Nuclear Medicine, 49(1), 284-291, 2018

#### 7 **Akhtar 2020**

8 Akhtar, N., Bari, A., Nazim, F., Hayat, Z., Comparison of diagnosis and management options  
9 for placenta accreta spectrum with standard guidelines, Rawal Medical Journal, 45(4), 813-  
10 816, 2020

#### 11 **Alalfy 2021**

12 Alalfy, M., Hamed, S.T., Ghani, A.S.A.E., Elgazzar, A., Abbassy, A., Rashwan, A.S.S.A.,  
13 Nagy, O., Shalaby, M.A., Hassan, H., Ibrahim, A., Kamal, H., Mahrous, R., Kamal, Eman.,  
14 The accuracy of 3D-TUI and 3D power Doppler using Alalfy simple criteria in the diagnosis of  
15 placenta accreta spectrum, Clinical and Experimental Obstetrics and Gynecology, 48(5),  
16 1132-1140, 2021

#### 17 **Algebally 2014**

18 Algebally, A.M., Yousef, R.R.H., Badr, S.S.H., Obeidly, A.A., Szmigielski, W., Ibrahim,  
19 A.A.A., The value of ultrasound and magnetic resonance imaging in diagnostics and  
20 prediction of morbidity in cases of placenta previa with abnormal placentation, Polish Journal  
21 of Radiology, 79, 409-416, 2014

#### 22 **Alici Davutoglu 2018**

23 Alici Davutoglu, E., Arioiz Habibi, H., Ozel, A., Erenel, H., Adaletli, I., Madazli, R., Diagnostic  
24 accuracy of ultrasonography and magnetic resonance imaging in the assessment of placenta  
25 previa accreta, Turkiye Klinikleri Jinekoloji Obstetrik, 28(3), 105-111, 2018

#### 26 **Bourgioti 2021**

27 Bourgioti, C., Konstantinidou, A.E., Zafeiropoulou, K., Antoniou, A., Fotopoulos, S.,  
28 Theodora, M., Daskalakis, G., Nikolaidou, M.E., Tzavara, C., Letsika, A., Martzoukos, E.A.,  
29 Mouloupoulos, L.A., Intraplacental fetal vessel diameter may help predict for placental  
30 invasiveness in pregnant women at high risk for placenta accreta spectrum disorders.  
31 Radiology, 298(2), 403-412, 2021

#### 32 **Cali 2018a**

33 Cali, G., Forlani, F., Foti, F., Minneci, G., Manzoli, L., Flacco, M.E., Buca, D., Liberati, M.,  
34 Scambia, G., D'Antonio, F., Diagnostic accuracy of first-trimester ultrasound in detecting  
35 abnormally invasive placenta in high-risk women with placenta previa, Ultrasound in  
36 Obstetrics & Gynecology, 52(2), 258-264, 2018a

#### 37 **Cali 2018b**

38 Cali, G., Forlani, F., Timor-Trisch, I., Palacios-Jaraquemada, J., Foti, F., Minneci, G., Flacco,  
39 M.E., Manzoli, L., Familiari, A., Pagani, G., Scambia, G., D'Antonio, G., Diagnostic accuracy

- 1 of ultrasound in detecting the depth of invasion in women at risk of abnormally invasive  
2 placenta: A prospective longitudinal study, *Acta Obstetrica et Gynecologica Scandinavica*,  
3 97(10), 1219-1227, 2018b
- 4 **Coutinho 2021**
- 5 Coutinho, C.M., Giorgione, V., Noel, L., Liu, B., Chandraharan, E., Pryce, J., Frick, A.P.,  
6 Thilaganathan, B., Bhide, A., Effectiveness of contingent screening for placenta accreta  
7 spectrum disorders based on persistent low-lying placenta and previous uterine surgery,  
8 *Ultrasound in Obstetrics & Gynecology*, 57(1), 91-96, 2021
- 9 **di Pasquo 2020**
- 10 di Pasquo, E., Ghi, T., Cali, G., D'Antonio, F., Fratelli, N, Forlani, F., Prefumo, F., Kaihura,  
11 C.t., Volpe, N., Dall'Asta, A., Frusca, T., Intracervical lakes as sonographic marker of  
12 placenta accreta spectrum disorder in patients with placenta previa or low-lying placenta,  
13 *Ultrasound in Obstetrics & Gynecology*, 55(4), 460-466, 2020
- 14 **Einerson 2021**
- 15 Einerson, B.D., Rodriguez, C.E., Silver, R.M., Donnelly, M.A., Kennedy, A.M., Woodward, P.,  
16 Accuracy and interobserver reliability of magnetic resonance imaging for placenta accreta  
17 spectrum disorders, *American Journal of Perinatology*, 38(9), 960-967, 2021
- 18 **El Wakeel 2018**
- 19 El Wakeel, A., Azab, S., Abdel Rahman, H.M., Role of ultrasound, Doppler, and MRI in the  
20 diagnosis of placenta accreta, *Menoufia Medical Journal*, 31, 1023–1029, 2018
- 21 **Elhawary 2013**
- 22 Elhawary, T.M., Dabees, N.L., Youssef, M.A., Diagnostic value of ultrasonography and  
23 magnetic resonance imaging in pregnant women at risk for placenta accreta, *The Journal of*  
24 *Maternal-Fetal & Neonatal Medicine*, 26(14), 1443-1449, 2013
- 25 **Faralli 2022**
- 26 Faralli, I., Del Negro, V., Chine, A., Aleksa, N., Ciminello, E., Piccioni, M.G., Placenta accreta  
27 spectrum (PAS) disorder: ultrasound versus magnetic resonance imaging, *Diagnostics*,  
28 12(11), 2769, 2022
- 29 **Fiocchi 2020**
- 30 Fiocchi, F., Monelli, F., Besutti, G., Casari, F., Petrella, E., Pecchi, A., Caporali, C., Bertucci,  
31 E., Busani, S., Botticelli, L., Facchinetti, F., Torricelli, P., MRI of placenta accreta: diagnostic  
32 accuracy and impact of interventional radiology on foetal-maternal delivery outcomes in high-  
33 risk women, *The British Journal of Radiology*, 93(1114), 20200267, 2020
- 34 **Fujisaki 2017**
- 35 Fujisaki, M., Furukawa, S., Maki, Y., Oohashi, M., Doi, K., Sameshima, H., Maternal  
36 morbidity in women with placenta previa managed with prediction of morbidly adherent  
37 placenta by ultrasonography, *Journal of Pregnancy*, 2017, 8318751, 2017

- 1     **Gadelrab 2022**
- 2     Gadelrab, A.E., Aboelghar, W.M.A., Swedan, K.H., NasrEIDin, E.A., ElShahawy, A.,  
3     Accuracy of three-dimensional multislice view Doppler in diagnosis of placenta accreta  
4     spectrum, *Italian Journal of Gynaecology and Obstetrics*, 34(1), 11-18, 2022
- 5     **Gulati 2021**
- 6     Gulati, A., Anand, R., Aggarwal, K., Agarwal, S., Tomer, S., Ultrasound as a sole modality for  
7     prenatal diagnosis of placenta accreta spectrum: potentialities and pitfalls, *The Indian*  
8     *Journal of Radiology & Imaging*, 31(3), 527-538, 2021
- 9     **Haba 2022**
- 10    Haba, R.M., Pristavu, A.I., Cobzeanu, M-L., Carauleanu, A., Scripcariu, I.S., Vasilache, I.A.,  
11    Minciuna, D.A., Negru, D., Socolov, D.G., Predicting placenta accreta spectrum disorders in  
12    a cohort of pregnant patients in the north-east region of Romania-diagnostic accuracy of  
13    ultrasound and magnetic resonance imaging, *Diagnostics*, 12(9), 2130, 2022
- 14    **Haidar 2017**
- 15    Haidar, Z.A., Papanna, R., Sibai, B.M., Tatevian, N., Viteri, O.A., Vowels, P.C., Blackwell,  
16    S.C., Moise Jr, K.J., Can 3-dimensional power Doppler indices improve the prenatal  
17    diagnosis of a potentially morbidly adherent placenta in patients with placenta previa?,  
18    *American Journal of Obstetrics and Gynecology*, 217(2), 202e1-202e13, 2017
- 19    **Hashem 2016**
- 20    Hashem, L.B., Salem, D.S., Hamed, S.T., Hussein, A.M., Role of MRI versus ultrasound in  
21    the assessment of placental abnormalities and diseases, *Egyptian Journal of Radiology and*  
22    *Nuclear Medicine*, 47(2), 641-658, 2016
- 23    **Hussein 2022**
- 24    Hussein, A.M., Elbarmelgy, R.A., Elbarmelgy, R.M., Thabet, M.M., Jauniaux, E., Prospective  
25    evaluation of impact of post-cesarean section uterine scarring in perinatal diagnosis of  
26    placenta accreta spectrum disorder, *Ultrasound in Obstetrics & Gynecology*, 59(4), 474-482,  
27    2022
- 28    **Khalaf 2019**
- 29    Khalaf, L.M.R., Zeid, H.A., Othman, E.R., Reliability of magnetic resonance imaging in  
30    diagnosis and assessment the depth of invasion of placental accreta in high risk gravid  
31    women, *Clinical imaging*, 58, 5-11, 2019
- 32    **Lim 2011**
- 33    Lim, P.S., Greenberg, M., Edelson, M.I., Bell, K.A., Edmonds, P.R., Mackey, A.M., Utility of  
34    ultrasound and MRI in prenatal diagnosis of placenta accreta: a pilot study, *American Journal*  
35    *of Roentgenology*, 197(6), 1506-1513, 2011
- 36    **Maher 2013**
- 37    Maher, M.A., Abdelaziz, A., Bazeed, M.F., Diagnostic accuracy of ultrasound and MRI in the  
38    prenatal diagnosis of placenta accreta, *Acta Obstetrica et Gynecologica Scandinavica*,  
39    92(9), 1017-1022, 2013

- 1     **Mansour 2011**
- 2     Mansour, S.M., Elkhyat, W.M., Placenta previa - accreta: Do we need MR imaging?,  
3     Egyptian Journal of Radiology and Nuclear Medicine, 42(34), 433-442, 2011
- 4     **Mathur 2019**
- 5     Mathur, A., Rajoria, L., Bansal, A., Hemani, S., Vyas, J., Role of placenta accreta index in  
6     patients with placenta previa with previous cesarean: a prospective study, Journal of  
7     SAFOG, 11(6), 363-367, 2019
- 8     **Maurea 2018**
- 9     Maurea, S., Romeo, V., Mainenti, P.P., Ginocchio, M.I., Frauenfelder, G., Verde, F., Liuzzi,  
10    R., D'Armiento, M., Sarno, L., Morlando, M., Petretta, M., Martinelli, P., Brunetti, A.,  
11    Diagnostic accuracy of magnetic resonance imaging in assessing placental adhesion  
12    disorder in patients with placenta previa: correlation with histological findings, European  
13    Journal of Radiology, 106, 77-84, 2018
- 14    **Maurea 2022**
- 15    Maurea, S., Verde, F., Mainenti, P.P., Barbuto, L., Iacobellis, F., Romeo, V., Liuzzi, R., Raia,  
16    G., Dominicis, G.D., Santangelo, C., Romano, L., Brunetti, A., Qualitative evaluation of MR  
17    images for assessing placenta accreta spectrum disorders in patients with placenta previa: a  
18    pilot validation study, European Journal of Radiology, 146, 110078, 2022
- 19    **Millischer 2017**
- 20    Millischer, A-E., Salomon, L.J., Porcher, R., Brasseur-Daudruy, M., Gourdiere, A-L., Hornoy,  
21    P., Silvera, S., Loisel, D., Tsatsaris, V., Delorme, B., Boddaert, N., Ville, Y., Sentilhes, L.,  
22    Magnetic resonance imaging for abnormally invasive placenta: the added value of  
23    intravenous gadolinium injection. BJOG, 124(1), 88-95, 2017
- 24    **Naghshineh 2015**
- 25    Naghshineh, E., Khorvash, E., Kamali, Sara., A comparison of cell-free placental messenger  
26    ribonucleic acid and color Doppler ultrasound for the prediction of placental invasion in  
27    patients with placenta accreta, Advanced Biomedical Research, 4, 31, 2015
- 28    **Othman 2018**
- 29    Othman, A.I.A., Ibrahim, M.E.A., Mansour, D.Y., Diagnostic accuracy of MRI criteria in  
30    predilection of morbidly adherent placenta, Egyptian Journal of Radiology and Nuclear  
31    Medicine, 49(3), 819-827, 2018
- 32    **Panaiotova 2019**
- 33    Panaiotova, J., Tokunaka, M., Krajewska, K., Zosmer, N., Nicolaidis, K.H., Screening for  
34    morbidly adherent placenta in early pregnancy. Ultrasound in Obstetrics & Gynecology,  
35    53(1), 101-106, 2019
- 36    **Patru 2019**
- 37    Patru, C.L., Marinas, M.C., Tudorache, S., Capitanescu, R.G., Sirbu, O.C., Zorila, G.L.,  
38    Cernea, N., Istrate-Ofiteru, A-M., Rosu, G-C., Iovan, L., Iliescu, D.G., The performance of  
39    hyperadherence markers in anterior placenta praevia overlying the caesarean scar,  
40    Romanian Journal of Morphology and Embryology, 60(3), 861-867, 2019



- 1     **Reeder 2022**
- 2     Reeder, C.F., Sylvester-Armstrong, K.R., Silva, L.M., Wert, E.M., Smulian, J.C., Genc, M.R.,  
3     Outcomes of pregnancies at high-risk for placenta accreta spectrum following negative  
4     diagnostic imaging, *Journal of Perinatal Medicine*, 50(5), 595-600, 2022
- 5     **Rezk 2016**
- 6     Rezk, M.A.A., Shawky, M., Grey-scale and colour Doppler ultrasound versus magnetic  
7     resonance imaging for the prenatal diagnosis of placenta accreta, *The Journal of Maternal-*  
8     *Fetal & Neonatal Medicine*, 29(2), 218-223, 2016
- 9     **Romeo 2019**
- 10    Romeo, V., Sarno, L., Volpe, A., Ginocchio, M.I., Esposito, R., Mainenti, P.P., Petretta, M.,  
11    Liuzzi, R., D'Armiento, M., Martinelli, P., Brunetti, A., Maurea, S., US and MR imaging  
12    findings to detect placental adhesion spectrum (PAS) in patients with placenta previa: a  
13    comparative systematic study, *Abdominal Radiology*, 44(10), 3398-3407, 2019
- 14    **Romeo 2021**
- 15    Romeo, V., Verde, F., Sarno, L., Migliorini, S., Petretta, M., Mainenti, P.P., D'Armiento, M.,  
16    Guida, M., Brunetti, A., Maurea, S., Prediction of placenta accreta spectrum in patients with  
17    placenta previa using clinical risk factors, ultrasound and magnetic resonance imaging  
18    findings, *La Radiologia Medica*, 126(9), 1216-1225, 2021
- 19    **Satija 2015**
- 20    Satija, B., Kumar, S., Wadhwa, L., Gupta, T., Kohli, S., Chandoke, R., Utility of ultrasound  
21    and magnetic resonance imaging in prenatal diagnosis of placenta accreta: a prospective  
22    study, *The Indian Journal of Radiology & Imaging*, 25(4), 464-470, 2015
- 23    **Shweel 2012**
- 24    Shweel, M.A.G., El Ameen, N.F., Ibrahiem, M.A., Kotib, Ahmed., Placenta accreta in women  
25    with prior uterine surgery: diagnostic accuracy of Doppler ultrasonography and MRI, *Egyptian*  
26    *Journal of Radiology and Nuclear Medicine*, 43(3), 473-480, 2012
- 27    **UI Hassan 2020**
- 28    UI Hassan, I., Ishaq, B., Nosheen, A., Javed, A.M., Khan, M.M., Role of magnetic resonance  
29    imaging (MRI) in detecting abnormal placentation in suspected patients, *Pakistan Journal of*  
30    *Medical and Health Sciences*, 14(3), 1049-1051, 2020
- 31    **Other**
- 32    **NICE 2023**
- 33    National Institute for Health and Care Excellence (2023). Caesarean birth. Available at:  
34    <https://www.nice.org.uk/guidance/ng192> [Accessed 28/09/2023]

# 1 Appendices

## 2 Appendix A Review protocols

3 **Review protocol for review question: What is the accuracy of imaging techniques for diagnosis of a placenta accreta**  
4 **spectrum (PAS) in pregnant women who have had a previous caesarean birth and are currently diagnosed with placenta**  
5 **praevia?**

6 **Table 3: Review protocol**

Field	Content
PROSPERO registration number	CRD42023414085
Review title	Placenta accreta spectrum (PAS)
Review question	What is the accuracy of imaging techniques for diagnosis of a placenta accreta spectrum (PAS) in pregnant women who have had a previous caesarean birth and are currently diagnosed with placenta praevia?
Objective	To determine the diagnostic accuracy of imaging techniques for diagnosis of a placenta accreta spectrum (PAS) in pregnant women. This evidence review will allow the committee to consider the evidence to update recs 1.2.7 and 1.2.8 in NG 192.
Searches	The following databases will be searched:  Clinical Searches: Cochrane Central Register of Controlled Trials (CENTRAL) Cochrane Database of Systematic Reviews (CDSR) Embase MEDLINE All Epistemonikos  Economic search:

Field	Content
	<p>MEDLINE ALL Embase International Network of Agencies for Health Technology Assessment (INAHTA) HTA</p> <p>An economic evaluation filter will be applied.</p> <p>Searches will be restricted by: English language Human studies Date limit: 04/10/2010 (last date searched)</p> <p>The full search strategies will be published in the final review.</p>
Condition or domain being studied	Placenta accreta spectrum (PAS)
Population	<p>Inclusion: Pregnant women:</p> <ul style="list-style-type: none"> <li>• with a previous lower segment caesarean birth currently diagnosed with placenta praevia or low-lying placenta.</li> <li>• with a previous uterus surgery (e.g. myomectomy, perforation of the uterus) who also have a low-lying placenta [This population should be included even if they do not have a caesarean birth scar]</li> </ul> <p>Population will include:</p> <ul style="list-style-type: none"> <li>• In-vitro fertilization conceptions</li> <li>• Advanced maternal age</li> <li>• Multiparity</li> <li>• Previous uterine curettage</li> <li>• Previous caesarean birth</li> </ul>
Test	<ul style="list-style-type: none"> <li>• Grey scale ultrasound (transabdominal and transvaginal)</li> </ul>

Field	Content
	<ul style="list-style-type: none"> <li>• Colour-flow Doppler ultrasound</li> <li>• 3D ultrasound</li> <li>• MRI (magnetic resonance imaging) [include all types of MRI]</li> </ul> <p>To analyse grey scale transabdominal and transvaginal together.</p>
Reference standard	<ul style="list-style-type: none"> <li>• operative findings without histology reports/lab findings</li> <li>• operative findings with histology reports/lab findings</li> <li>• post caesarean birth examination with histology.</li> </ul>
Types of study to be included	<ul style="list-style-type: none"> <li>• Cross-sectional studies</li> <li>• Cohort studies (prospective and retrospective)</li> <li>• Systematic reviews and meta-analyses of the above.</li> </ul>
Other exclusion criteria	<p>Non-English language studies.</p> <p>Conference abstracts will be excluded as it is expected there will be sufficient full text published studies available.</p>
Context	<p>Placenta accreta spectrum is associated with serious maternal morbidity including major obstetric haemorrhage, transfusion of large quantities of blood products, hysterectomy and admission to an intensive care unit.</p> <p>There is a need to review the evidence for diagnostic modalities for placenta accreta spectrum. This will help in optimum management once the diagnosis has been made. This review question will partly update the following: Caesarean Birth (NG192)</p>
Primary outcomes (critical outcomes)	<p>Diagnostic accuracy of imaging techniques (grey scale ultrasound, colour-flow Doppler ultrasound, 3D ultrasound, MRI)</p> <p>Diagnostic test accuracy data (i.e. TP, FP, TN, FN) that allows calculation of</p> <ul style="list-style-type: none"> <li>• Sensitivity and specificity</li> </ul> <p>Decision thresholds are:</p> <ul style="list-style-type: none"> <li>• sensitivity: low threshold 50%, high threshold 90%</li> </ul>

Field	Content
	<ul style="list-style-type: none"> <li>• specificity: low threshold 50%, high threshold 90%.</li> </ul> <p>Sensitivity was considered to be more important. This is because you would not want to miss anyone with PAS as it is associated with increased risk of maternal and fetal morbidity and mortality.</p>
Secondary outcomes (important outcomes)	<p>Diagnostic test accuracy data (i.e., TP, FP, TN, FN) that allows calculation of</p> <ul style="list-style-type: none"> <li>• Positive and negative predictive values</li> </ul> <p>Note: Raw data will be extracted from studies and the relevant diagnostic accuracy pair measures calculated if not otherwise reported.</p>
Data extraction (selection and coding)	<p>All references identified by the searches and from other sources will be uploaded into EPPI and de-duplicated.</p> <p>Titles and abstracts of the retrieved citations will be screened to identify studies that potentially meet the inclusion criteria outlined in the review protocol.</p> <p>Dual sifting will be performed on at least 10% of records; 90% agreement is required. Disagreements will be resolved via discussion between the two reviewers, and consultation with senior staff if necessary.</p> <p>Full versions of the selected studies will be obtained for assessment. Studies that fail to meet the inclusion criteria once the full version has been checked will be excluded at this stage. Each study excluded after checking the full version will be listed, along with the reason for its exclusion.</p> <p>A standardised form will be used to extract data from studies. The following data will be extracted: study details (reference, country where study was carried out, type and dates), participant characteristics, inclusion and exclusion criteria, details of the tests/reference standard, setting and follow-up, relevant outcome data and source of funding.</p> <p>One reviewer will extract relevant data into a standardised form, and this will be quality assessed by a senior reviewer.</p>
Risk of bias (quality) assessment	<p>Quality assessment of individual studies will be performed using the following checklists:</p> <ul style="list-style-type: none"> <li>• ROBIS tool for systematic reviews of diagnostic test accuracy studies</li> <li>• QUADAS-2 for diagnostic accuracy studies</li> </ul>

Field	Content
	The quality assessment will be performed by one reviewer, and this will be quality assessed by a senior reviewer.
Strategy for data synthesis	<p>Diagnostic review:</p> <p>Depending on the availability of the evidence, the findings will be summarised narratively or quantitatively. Where appropriate, meta-analysis of diagnostic test accuracy will be performed using Winbugs and Cochrane Review Manager software.</p> <p>Sensitivity, specificity, positive and negative likelihood ratios will be used as outcomes for diagnostic test accuracy. These diagnostic accuracy parameters will be obtained from the studies or calculated by the technical team using data from the studies.</p> <p>The confidence in the findings across all available evidence will be evaluated for each outcome using an adaptation of the 'Grading of Recommendations Assessment, Development and Evaluation (GRADE) toolbox' developed by the international GRADE working group: <a href="http://www.gradeworkinggroup.org/">http://www.gradeworkinggroup.org/</a>"</p> <ul style="list-style-type: none"> <li>• Where available, outcome data from new studies will be meta-analysed with corresponding data included in NG 192.</li> </ul>
Analysis of sub-groups	<p>Evidence will be sub-grouped by the following only in the event that there is significant heterogeneity in outcomes:</p> <p>BMI thresholds:</p> <ul style="list-style-type: none"> <li>• Underweight range: &lt;18.5 kg/m<sup>2</sup></li> <li>• Healthy weight range: 18.5 to 24.9 kg/m<sup>2</sup></li> <li>• Overweight range: 25 to 29.99 kg/m<sup>2</sup></li> <li>• Obesity 1: 30 to 34.99 kg/m<sup>2</sup></li> <li>• Obesity 2: 35 to 39.99 kg/m<sup>2</sup></li> <li>• Obesity 3: &gt;40 kg/m<sup>2</sup></li> </ul> <p>There are challenges in imaging women with raised BMI. Ultrasound is the most affected imaging modality as the thickness of subcutaneous fat and the sound-attenuating properties of fat present challenges especially at increased depths.</p>

Field	Content	
	<p>First scan will be around 20-weeks (18-22 weeks). This timing is chosen for first scan as every woman has anomaly scan at 20 weeks. No sub-group analysis is needed for timing of imaging for first scan.</p> <p>Sub-groups for 2nd scan (US/MRI):</p> <ul style="list-style-type: none"> <li>• Less than 28 weeks</li> <li>• 28-30 weeks</li> <li>• 30-32 weeks</li> <li>• Anytime after 32 weeks</li> </ul> <p>Generally, second scan will be around 28 weeks. The second scan can be done before 28 weeks if there is a clinical indication.</p> <p>Where evidence is stratified or sub-grouped the committee will consider on a case by case basis if separate recommendations should be made for distinct groups. Separate recommendations may be made where there is evidence of a differential effect of interventions in distinct groups. If there is a lack of evidence in one group, the committee will consider, based on their experience, whether it is reasonable to extrapolate and assume the interventions will have similar effects in that group compared with others.</p>	
Type and method of review	<input type="checkbox"/> <input checked="" type="checkbox"/> <input type="checkbox"/> <input type="checkbox"/> <input type="checkbox"/> <input type="checkbox"/> <input type="checkbox"/>	Intervention Diagnostic Prognostic Qualitative Epidemiologic Service Delivery Other (please specify)
Language	English	
Country	England	

Field	Content		
Anticipated or actual start date	May 2023		
Anticipated completion date	January 2024		
Stage of review at time of this submission	Review stage	Started	Completed
	Preliminary searches	<input checked="" type="checkbox"/>	<input checked="" type="checkbox"/>
	Piloting of the study selection process	<input checked="" type="checkbox"/>	<input checked="" type="checkbox"/>
	Formal screening of search results against eligibility criteria	<input checked="" type="checkbox"/>	<input checked="" type="checkbox"/>
	Data extraction	<input checked="" type="checkbox"/>	<input checked="" type="checkbox"/>
	Risk of bias (quality) assessment	<input checked="" type="checkbox"/>	<input checked="" type="checkbox"/>
	Data analysis	<input checked="" type="checkbox"/>	<input checked="" type="checkbox"/>
Named contact	<p>Named contact: National Guideline Alliance development team, NICE</p> <p>Named contact e-mail: CBmorbidity@nice.org.uk</p> <p>Organisational affiliation of the review: National Institute for Health and Care Excellence (NICE)</p>		
Review team members	National Guideline Alliance development team, NICE		
Funding sources/sponsor	This systematic review is being completed by NICE.		
Conflicts of interest	<p>All guideline committee members and anyone who has direct input into NICE guidelines (including the evidence review team and expert witnesses) must declare any potential conflicts of interest in line with NICE's code of practice for declaring and dealing with conflicts of interest. Any relevant interests, or changes to interests, will also be declared publicly at the start of each guideline committee meeting. Before each meeting, any potential conflicts of interest will be considered by the guideline committee Chair and a senior member of the development team. Any decisions to exclude a person from all or part of a meeting will be documented. Any changes to a member's declaration of interests</p>		



Field	Content	
	will be recorded in the minutes of the meeting. Declarations of interests will be published with the final guideline.	
Collaborators	Development of this systematic review will be overseen by an advisory committee who will use the review to inform the development of evidence-based recommendations in line with section 3 of Developing NICE guidelines: the manual. Members of the guideline committee are available on the NICE website: [NICE guideline webpage].	
Other registration details	None	
Reference/URL for published protocol	<a href="https://www.crd.york.ac.uk/prospero/display_record.php?ID=CRD42023414085">https://www.crd.york.ac.uk/prospero/display_record.php?ID=CRD42023414085</a>	
Dissemination plans	<p>NICE may use a range of different methods to raise awareness of the guideline. These include standard approaches such as:</p> <ul style="list-style-type: none"> <li>• notifying registered stakeholders of publication</li> <li>• publicising the guideline through NICE's newsletter and alerts</li> <li>• issuing a press release or briefing as appropriate, posting news articles on the NICE website, using social media channels, and publicising the guideline within NICE.</li> </ul>	
Keywords	Placenta accreta spectrum, ultrasound, MRI, diagnosis, pregnant women, caesarean birth, uterine surgery, placenta praevia, low-lying placenta	
Details of existing review of same topic by same authors	None	
Current review status	<input type="checkbox"/>	Ongoing
	<input checked="" type="checkbox"/>	Completed but not published
	<input type="checkbox"/>	Completed and published
	<input type="checkbox"/>	Completed, published and being updated
	<input type="checkbox"/>	Discontinued
Additional information	None	
Details of final publication	<a href="http://www.nice.org.uk">www.nice.org.uk</a>	

- 1 *BMI: body mass index; CDSR: Cochrane Database of Systematic Reviews; CENTRAL: Cochrane Central Register of Controlled Trials; FN: false negative; FP: false positive;*
- 2 *GRADE: Grading of Recommendations Assessment, Development and Evaluation; INAHTA: International Network of Agencies for Health Technology Assessment; MEDLINE:*
- 3 *Medical Literature Analysis and Retrieval System Online; MRI: magnetic resonance imaging; NICE: National Institute for Health and Care Excellence; PAS: Placenta Accreta*
- 4 *Spectrum; QUADAS: Quality Assessment of Diagnostic Accuracy Studies; ROBIS: Risk of Bias in Systematic Reviews; SRDR: The Systematic Review Data Repository; TN:*
- 5 *true negative; TP: true positive; US: ultrasound; 3D: three dimensional*
- 6

## Appendix B Literature search strategies

**Literature search strategies for review question: What is the accuracy of imaging techniques for diagnosis of a placenta accreta spectrum (PAS) in pregnant women who have had a previous caesarean birth and are currently diagnosed with placenta praevia?**

**Database: Ovid MEDLINE(R) ALL**

**Date of last search: 19/04/2023**

#	Searches
1	Placenta Accreta/
2	(placenta* adj3 (accret* or adhes* or cret* or inret* or infiltrat* or invad* or invas* or percret*)).ti,ab,kf.
3	(AIP or MAP or PAD or PAS).ti.
4	(morbid* adhe* adj3 placenta*).ti,ab,kf.
5	or/1-4
6	Placenta Previa/
7	(placenta* adj3 (cervical os or cervix os or low* or marginal or pr?evia)).ti,ab,kf.
8	(placenta* adj3 (cervix adj2 (block* or cover* or near*))).ti,ab,kf.
9	or/6-8
10	exp Cesarean Section/
11	(caesar* or cesar* or c section* or csection* or cs birth* or cs deliver* or ((birth* or deliver*) adj3 (abdom* or operat* or surg*))).ti,ab,kf.
12	Placenta Diseases/su
13	exp Uterus/su
14	exp Uterine Diseases/su
15	Curettage/ or "Dilatation and Curettage"/
16	Uterine Artery Embolization/
17	Uterine Myomectomy/
18	exp Uterine Rupture/su
19	Postpartum Hemorrhage/su
20	exp Embryo Transfer/ or exp Fertilization in Vitro/
21	Maternal Age/
22	Parity/
23	(curettage* or fibroidectom* or hysteroplast* or hysterotom* or metroplast* or myomectom*).ti,ab,kf.
24	((endometr* or intrauter* or uter* or womb) adj3 (ablat* or adhesiolysis or emboli* or excis* or incis* or lysis or polpectom* or repair* or resect* or scrap* or surg*)).ti,ab,kf.
25	((endometr* or intrauter* or uter* or womb) adj3 (perforat* or ruptur*)).ti,ab,kf.
26	asherman*.ti,ab,kf.
27	((endometri* or intrauter* or uter* or womb) adj2 scar*).ti,ab,kf.
28	((blastocyst* or embryo*) adj2 transfer*) or ((in vitro or invitro) adj2 fertili*) or ivf).ti,ab,kf.
29	((age* or old*) adj3 (matern* or mother*)).ti,ab,kf.
30	(multiparity or multipara* or multiparous or parity or parous).ti,ab,kf.
31	or/10-30
32	9 and 31
33	5 or 32
34	Placenta/dg
35	Placenta Diseases/dg
36	exp Uterine Diseases/dg
37	exp Uterus/dg
38	imaging, three-dimensional/ or ultrasonography/ or ultrasonography, doppler/ or ultrasonography, doppler, duplex/ or ultrasonography, doppler, color/ or ultrasonography, prenatal/
39	((doppler* or echo* or flowmet* or sono* or ultraso*) adj3 (3d or 3 d or colour* or color* or doppler* or grayscale or gray scale or greyscale or grey scale or prenatal* or three dimension* or transabdom* or trans abdom* or transvagina* or trans vagina*).ti,ab,kf.
40	exp Magnetic Resonance Imaging/
41	(magnetic resonance or DWI or EPI or MRE or MRI or MRS or NMR* or T1W or T2W or WB-DWI or ((chemical shift or diffusion or echoplanar or magnet* or MR or nuclear or NM or planar or spin or weight*) adj2 (diagnos* or elastogra* or examin* or imag* or scan* or spectroscop* or tomogra*))).ti,ab,kf.
42	or/34-41
43	33 and 42
44	letter/
45	editorial/
46	news/
47	exp historical article/

#	Searches
48	Anecdotes as topic/
49	comment/
50	case reports/
51	(letter or comment*).ti.
52	or/44-51
53	animals/ not humans/
54	exp Animals, Laboratory/
55	exp Animal Experimentation/
56	exp Models, Animal/
57	exp Rodentia/
58	(rat or rats or rodent* or mouse or mice).ti.
59	or/53-58
60	52 or 59
61	43 not 60
62	limit 61 to english language
63	limit 62 to dt=20101004-20230419
64	limit 62 to ed=20101004-20230419
65	63 or 64

## Database: Embase

Date of last search: 19/04/2023

#	Searches	Results
1	placenta accreta/	5001
2	(placenta* adj3 (accret* or adhes* disorder* or cret* or incret* or infiltrat* or invad* or invas* or percret*).ti,ab,kf.	6931
3	(AIP or MAP or PAD or PAS).ti.	27064
4	(morbid* adhe* adj3 placenta*).ti,ab,kf.	663
5	or/1-4	35078
6	placenta previa/	6781
7	(placenta* adj3 (cervical os or cervix os or low* or marginal or pr?evia)).ti,ab,kf.	7570
8	(placenta* adj3 (cervix adj2 (block* or cover* or near*))).ti,ab,kf.	4
9	or/6-8	9922
10	exp cesarean section/	110054
11	(caesar* or cesar* or c section* or csection* or cs birth* or cs deliver* or ((birth* or deliver*) adj3 (abdom* or operat* or surg*))).ti,ab,kf.	108542
12	placenta/su	16
13	placenta disorder/su	293
14	exp uterus/su	655
15	exp uterus disease/su	37155
16	curettage/ or "dilatation and curettage"/	14162
17	uterine artery embolization/	4553
18	myomectomy/	8602
19	uterine rupture/su	646
20	postpartum hemorrhage/su	1056
21	exp embryo transfer/ or in vitro fertilization/	49205
22	maternal age/	42735
23	multipara/	9680
24	(curettage* or fibroidectom* or hysteroplast* or hysterotom* or metroplast* or myomectom*).ti,ab,kf.	22238
25	((endometr* or intrauter* or uter* or womb) adj3 (ablat* or adhesiolysis or emboli* or excis* or incis* or lysis or polpectom* or repair* or resect* or scrap* or surg*)).ti,ab,kf.	25413
26	((endometr* or intrauter* or uter* or womb) adj3 (perforat* or ruptur*)).ti,ab,kf.	7644
27	asherman*.ti,ab,kf.	744
28	((endometri* or intrauter* or uter* or womb) adj2 scar*).ti,ab,kf.	2439
29	((blastocyst* or embryo*) adj2 transfer*) or ((in vitro or invitro) adj2 fertili*) or ivf).ti,ab,kf.	77794
30	((age* or old*) adj3 (matern* or mother*)).ti,ab,kf.	53574
31	(multiparity or multipara* or multiparous or parity or parous).ti,ab,kf.	82679
32	or/10-31	416288
33	9 and 32	6542
34	5 or 33	39173
35	placenta disorder/di	1172
36	exp uterus disease/di	44006
37	three dimensional echography/ or three-dimensional imaging/ or echography/ or Doppler ultrasonography/ or duplex Doppler ultrasonography/ or color Doppler flowmetry/ or Doppler flowmetry/ or fetus echography/ or gray scale echography/	498107

#	Searches	Results
38	((doppler* or echo* or flowmet* or sono* or ultraso*) adj3 (3d or 3 d or colour* or color* or doppler* or grayscale or gray scale or greyscale or grey scale or prenatal* or three dimension* or transabdom* or trans abdom* or transvagina* or trans vagina*)).ti,ab,kf.	198929
39	exp nuclear magnetic resonance imaging/	1169685
40	(magnetic resonance or DWI or EPI or MRE or MRI or MRS or NMR* or T1W or T2W or WB-DWI or ((chemical shift or diffusion or echoplanar or magnet* or MR or nuclear or NM or planar or spin or weight*) adj2 (diagnos* or elastogra* or examin* or imag* or scan* or spectroscop* or tomogra*))).ti,ab,kf.	1166991
41	or/35-40	2124904
42	34 and 41	5231
43	letter.pt. or letter/	1009598
44	note.pt.	828915
45	editorial.pt.	680869
46	case report/ or case study/	2188289
47	(letter or comment*).ti.	195899
48	or/43-47	4485131
49	animal/ not human/	761963
50	nonhuman/	6020041
51	exp Animal Experiment/	2236774
52	exp Experimental Animal/	742485
53	animal model/	1574470
54	exp Rodent/	2907951
55	(rat or rats or rodent* or mouse or mice).ti.	1095711
56	or/49-55	7266531
57	48 or 56	11415317
58	42 not 57	3368
59	limit 58 to english language	3187
60	(conference abstract* or conference review or conference paper or conference proceeding).db,pt,su.	5248687
61	59 not 60	2430
62	limit 61 to dc=20101004-20230419	2018

**Database: Cochrane Database of Systematic Reviews (CDJR) Issue 4 of 12, April 2023**

**Date of last search: 19/04/2023**

ID	Search
#1	MeSH descriptor: [Placenta Accreta] this term only
#2	(placenta* near/3 (accret* or adhes* or cret* or inret* or infiltrat* or invad* or invas* or percret*)):ti,ab,kw
#3	(AIP or MAP or PAD or PAS):ti
#4	((morbid* next adhe*) near/3 placenta*):ti,ab,kw
#5	{or #1-#4}
#6	MeSH descriptor: [Placenta Previa] this term only
#7	(placenta* near/3 ("cervical os" or "cervix os" or low* or marginal or praevia or previa)):ti,ab,kw
#8	(placenta* near/3 (cervix near/2 (block* or cover* or near*)):ti,ab,kw
#9	{or #6-#8}
#10	MeSH descriptor: [Caesarean Section] explode all trees
#11	(caesar* or cesar* or "c section*" or csection* or "cs birth*" or "cs deliver*" or ((birth* or deliver*) near/3 (abdom* or operat* or surg*)):ti,ab,kw
#12	MeSH descriptor: [Placenta Diseases] this term only and with qualifier(s): [surgery - SU]
#13	MeSH descriptor: [Uterus] explode all trees and with qualifier(s): [surgery - SU]
#14	MeSH descriptor: [Uterine Diseases] explode all trees and with qualifier(s): [surgery - SU]
#15	MeSH descriptor: [Curettage] this term only
#16	MeSH descriptor: [Dilatation and Curettage] this term only
#17	MeSH descriptor: [Uterine Artery Embolization] this term only
#18	MeSH descriptor: [Uterine Myomectomy] this term only
#19	MeSH descriptor: [Uterine Rupture] explode all trees and with qualifier(s): [surgery - SU]
#20	MeSH descriptor: [Postpartum Hemorrhage] this term only and with qualifier(s): [surgery - SU]
#21	MeSH descriptor: [Embryo Transfer] explode all trees
#22	MeSH descriptor: [Fertilization in Vitro] explode all trees
#23	MeSH descriptor: [Maternal Age] this term only
#24	MeSH descriptor: [Parity] this term only
#25	(curettage* or fibroidectom* or hysteroplast* or hysterotom* or metroplast* or myomectom*):ti,ab,kw
#26	((endometr* or intrauter* or uter* or womb) near/3 (ablat* or adhesiolysis or emboli* or excis* or incis* or lysis or polpectom* or repair* or resect* or scrap* or surg*)):ti,ab,kw
#27	((endometr* or intrauter* or uter* or womb) near/3 (perforat* or ruptur*)):ti,ab,kw
#28	asherman*:ti,ab,kw

ID	Search
#29	((endometri* or intrauter* or uter* or womb) near/2 scar*):ti,ab,kw
#30	(((blastocyst* or embryo*) near/2 transfer*) or (("in vitro" or invitro) near/2 fertili*) or ivf):ti,ab,kw
#31	((age* or old*) near/3 (matern* or mother*)):ti,ab,kw
#32	(multiparity or multipara* or multiparous or parity or parous):ti,ab,kw
#33	{or #10-#32}
#34	#9 and #33
#35	#5 or #34
#36	MeSH descriptor: [Placenta] this term only and with qualifier(s): [diagnostic imaging - DG]
#37	MeSH descriptor: [Placenta Diseases] this term only and with qualifier(s): [diagnostic imaging - DG]
#38	MeSH descriptor: [Uterine Diseases] explode all trees and with qualifier(s): [diagnostic imaging - DG]
#39	MeSH descriptor: [Uterus] explode all trees and with qualifier(s): [diagnostic imaging - DG]
#40	MeSH descriptor: [Imaging, Three-Dimensional] this term only
#41	MeSH descriptor: [Ultrasonography] this term only
#42	MeSH descriptor: [Ultrasonography, Doppler] this term only
#43	MeSH descriptor: [Ultrasonography, Doppler, Duplex] this term only
#44	MeSH descriptor: [Ultrasonography, Doppler, Color] this term only
#45	MeSH descriptor: [Ultrasonography, Prenatal] this term only
#46	((doppler* or echo* or flowmet* or sono* or ultraso*) near/3 (3d or "3 d" or colour* or color* or doppler* or grayscale or "gray scale" or greyscale or "grey scale" or prenatal* or "three dimension*" or transabdom* or " trans abdom*" or transvagina* or "trans vagina*")):ti,ab,kw
#47	MeSH descriptor: [Magnetic Resonance Imaging] explode all trees
#48	("magnetic resonance" or DWI or EPI or MRE or MRI or MRS or NMR* or T1W or T2W or "WB-DWI" or ("chemical shift" or diffusion or echoplanar or magnet* or MR or nuclear or NM or planar or spin or weight*) near/2 (diagnos* or elastogra* or examin* or imag* or scan* or spectroscop* or tomogra*)):ti,ab,kw
#49	{or #36-#48}
#50	#35 and #49 with Cochrane Library publication date from Oct 2010 to Apr 2023, in Cochrane Reviews and Cochrane Protocols

**Database: Cochrane Central Register of Controlled Trials (CENTRAL) Issue 4 of 12, April 2023**

**Date of last search: 19/04/2023**

ID	Search
#1	MeSH descriptor: [Placenta Accreta] this term only
#2	(placenta* near/3 (accret* or adhes* or cret* or incret* or infiltrat* or invad* or invas* or percret*)):ti,ab,kw
#3	(AIP or MAP or PAD or PAS):ti
#4	((morbid* next adhe*) near/3 placenta*):ti,ab,kw
#5	{or #1-#4}
#6	MeSH descriptor: [Placenta Previa] this term only
#7	(placenta* near/3 ("cervical os" or "cervix os" or low* or marginal or praevia or previa)):ti,ab,kw
#8	(placenta* near/3 (cervix near/2 (block* or cover* or near*)):ti,ab,kw
#9	{or #6-#8}
#10	MeSH descriptor: [Cesarean Section] explode all trees
#11	(caesar* or cesar* or "c section*" or csection* or "cs birth*" or "cs deliver*" or ((birth* or deliver*) near/3 (abdom* or operat* or surg*)):ti,ab,kw
#12	MeSH descriptor: [Placenta Diseases] this term only and with qualifier(s): [surgery - SU]
#13	MeSH descriptor: [Uterus] explode all trees and with qualifier(s): [surgery - SU]
#14	MeSH descriptor: [Uterine Diseases] explode all trees and with qualifier(s): [surgery - SU]
#15	MeSH descriptor: [Curettage] this term only
#16	MeSH descriptor: [Dilatation and Curettage] this term only
#17	MeSH descriptor: [Uterine Artery Embolization] this term only
#18	MeSH descriptor: [Uterine Myomectomy] this term only
#19	MeSH descriptor: [Uterine Rupture] explode all trees and with qualifier(s): [surgery - SU]
#20	MeSH descriptor: [Postpartum Hemorrhage] this term only and with qualifier(s): [surgery - SU]
#21	MeSH descriptor: [Embryo Transfer] explode all trees
#22	MeSH descriptor: [Fertilization in Vitro] explode all trees
#23	MeSH descriptor: [Maternal Age] this term only
#24	MeSH descriptor: [Parity] this term only
#25	(curettage* or fibroidectom* or hysteroplast* or hysterotom* or metroplast* or myomectom*):ti,ab,kw
#26	((endometr* or intrauter* or uter* or womb) near/3 (ablat* or adhesiolysis or emboli* or excis* or incis* or lysis or polpectom* or repair* or resect* or scrap* or surg*)):ti,ab,kw
#27	((endometr* or intrauter* or uter* or womb) near/3 (perforat* or ruptur*)):ti,ab,kw
#28	asherman*:ti,ab,kw
#29	((endometri* or intrauter* or uter* or womb) near/2 scar*):ti,ab,kw
#30	(((blastocyst* or embryo*) near/2 transfer*) or (("in vitro" or invitro) near/2 fertili*) or ivf):ti,ab,kw
#31	((age* or old*) near/3 (matern* or mother*)):ti,ab,kw

ID	Search
#32	(multiparity or multipara* or multiparous or parity or parous):ti,ab,kw
#33	{or #10-#32}
#34	#9 and #33
#35	#5 or #34
#36	MeSH descriptor: [Placenta] this term only and with qualifier(s): [diagnostic imaging - DG]
#37	MeSH descriptor: [Placenta Diseases] this term only and with qualifier(s): [diagnostic imaging - DG]
#38	MeSH descriptor: [Uterine Diseases] explode all trees and with qualifier(s): [diagnostic imaging - DG]
#39	MeSH descriptor: [Uterus] explode all trees and with qualifier(s): [diagnostic imaging - DG]
#40	MeSH descriptor: [Imaging, Three-Dimensional] this term only
#41	MeSH descriptor: [Ultrasonography] this term only
#42	MeSH descriptor: [Ultrasonography, Doppler] this term only
#43	MeSH descriptor: [Ultrasonography, Doppler, Duplex] this term only
#44	MeSH descriptor: [Ultrasonography, Doppler, Color] this term only
#45	MeSH descriptor: [Ultrasonography, Prenatal] this term only
#46	((doppler* or echo* or flowmet* or sono* or ultraso*) near/3 (3d or "3 d" or colour* or color* or doppler* or grayscale or "gray scale" or greyscale or "grey scale" or prenatal* or "three dimension*" or transabdom* or " trans abdom*" or transvagina* or "trans vagina*")):ti,ab,kw
#47	MeSH descriptor: [Magnetic Resonance Imaging] explode all trees
#48	("magnetic resonance" or DWI or EPI or MRE or MRI or MRS or NMR* or T1W or T2W or "WB-DWI" or ("chemical shift" or diffusion or echoplanar or magnet* or MR or nuclear or NM or planar or spin or weight*) near/2 (diagnos* or elastogra* or examin* or imag* or scan* or spectroscop* or tomogra*)):ti,ab,kw
#49	{or #36-#48}
#50	#35 and #49
#51	"conference":pt or (clinicaltrials or trialsearch):so
#52	#50 not #51 with Publication Year from 2010 to 2023, in Trials

## Database: Epistemonikos

Date of last search: 19/04/2023

#1	((placenta* and (accret* or adhes* or cret* or incret* or infiltrat* or invad* or invas* or percret*)) or (morbid* and adhe* and placenta*))
#2	((((placenta* and (cervical or cervix or low* or marginal or praevia or previa) and (caesar* or cesar* or "c section" or csection* or (cs and (birth* or deliver*))) or ((birth* or deliver*) and (abdom* or operat* or surg*))))))
#3	(placenta* and (curettage* or fibroidectom* or hysteroplast* or hysterotom* or metroplast* or myomectom*))
#4	(placenta* and (((endomet* or intrauter* or uter* or womb) and (ablat* or adhesiolysis or emboli* or excis* or incis* or lysis or perforat* or polpectom* or repair* or resect* or rupture* or scar* or scrap* or surg*)) or asherman*))
#5	(placenta* and (((blastocyst* or embryo*) and transfer*) or (("in vitro" or invitro) and fertili*) or ivf))
#6	(placenta* and ((age* or old*) and (matern* or mother*)))
#7	(placenta* and (multiparity or multipara* or multiparous or parity or parous))
#8	#1 or #2 or #3 or #4 or #5 or #6 or #7
#9	((((doppler* or echo* or flowmet* or sono* or ultraso* or grayscale or "gray scale" or greyscale or "grey scale") or ("magnetic resonance" or DWI or EPI or MRE or MRI or MRS or NMR* or T1W or T2W or WB-DWI or ("chemical shift" or diffusion or echoplanar or magnet* or MR or nuclear or NM or planar or spin or weight*) and (diagnos* or elastogra* or examin* or imag* or scan* or spectroscop* or tomogra*))))))
#10	#8 and #9
#11	[Filters: min_date=20101004, max_date=20230419]

## Economic searches

### Database: Ovid MEDLINE(R) ALL

Date of last search: 19/04/2023

#	Searches
1	Placenta Accreta/
2	(placenta* adj3 (accret* or adhes* disorder* or cret* or incret* or infiltrat* or invad* or invas* or percret*)):ti,ab,kf.
3	(API or MAP or PAD or PAS).ti.
4	(morbid* adhe* adj3 placenta*):ti,ab,kf.
5	or/1-4
6	Placenta Previa/
7	(placenta* adj3 (cervical os or cervix os or low* or marginal or pr?evia)):ti,ab,kf.
8	(placenta* adj3 (cervix adj2 (block* or cover* or near*)):ti,ab,kf.
9	or/6-8

#	Searches
10	exp Cesarean Section/
11	(caesar* or cesar* or c section* or csection* or cs birth* or cs deliver* or ((birth* or deliver*) adj3 (abdom* or operat* or surg*))).ti,ab,kf.
12	Placenta Diseases/su
13	exp Uterus/su
14	exp Uterine Diseases/su
15	Curettage/ or "Dilatation and Curettage"/
16	Uterine Artery Embolization/
17	Uterine Myomectomy/
18	exp Uterine Rupture/su
19	Postpartum Hemorrhage/su
20	exp Embryo Transfer/ or exp Fertilization in Vitro/
21	Maternal Age/
22	Parity/
23	(curettage* or fibroidectom* or hysteroplast* or hysterotom* or metroplast* or myomectom*).ti,ab,kf.
24	((endometr* or intrauter* or uter* or womb) adj3 (ablat* or adhesiolysis or emboli* or excis* or incis* or lysis or polpectom* or repair* or resect* or scrap* or surg*)).ti,ab,kf.
25	((endometr* or intrauter* or uter* or womb) adj3 (perforat* or ruptur*)).ti,ab,kf.
26	asherman*.ti,ab,kf.
27	((endometri* or intrauter* or uter* or womb) adj2 scar*).ti,ab,kf.
28	((blastocyst* or embryo*) adj2 transfer*) or ((in vitro or invitro) adj2 fertili*) or ivf).ti,ab,kf.
29	((age* or old*) adj3 (matern* or mother*)).ti,ab,kf.
30	(multiparity or multipara* or multiparous or parity or parous).ti,ab,kf.
31	or/10-30
32	9 and 31
33	5 or 32
34	Placenta/dg
35	Placenta Diseases/dg
36	exp Uterine Diseases/dg
37	exp Uterus/dg
38	imaging, three-dimensional/ or ultrasonography/ or ultrasonography, doppler/ or ultrasonography, doppler, duplex/ or ultrasonography, doppler, color/ or ultrasonography, prenatal/
39	((doppler* or echo* or flowmet* or sono* or ultraso*) adj3 (3d or 3 d or colo?* or doppler* or grayscale or gray scale or greyscale or grey scale or prenatal* or three dimension* or transabdominal* or transvaginal*)).ti,ab,kf.
40	exp Magnetic Resonance Imaging/
41	(magnetic resonance or DWI or EPI or MRE or MRI or MRS or NMR* or T1W or T2W or WB-DWI or ((chemical shift or diffusion or echoplanar or magnet* or MR or nuclear or NM or planar or spin or weight*) adj2 (diagnos* or elastogra* or examin* or imag* or scan* or spectroscop* or tomogra*))).ti,ab,kf.
42	or/34-41
43	33 and 42
44	letter/
45	editorial/
46	news/
47	exp historical article/
48	Anecdotes as topic/
49	comment/
50	case reports/
51	(letter or comment*).ti.
52	or/44-51
53	animals/ not humans/
54	exp Animals, Laboratory/
55	exp Animal Experimentation/
56	exp Models, Animal/
57	exp Rodentia/
58	(rat or rats or rodent* or mouse or mice).ti.
59	or/53-58
60	52 or 59
61	43 not 60
62	limit 61 to english language
63	Economics/
64	Value of life/
65	exp "Costs and Cost Analysis"/
66	exp Economics, Hospital/
67	exp Economics, Medical/
68	exp Resource Allocation/
69	Economics, Nursing/
70	Economics, Pharmaceutical/
71	exp "Fees and Charges"/
72	exp Budgets/



#	Searches
73	budget*.ti,ab.
74	cost*.ti,ab.
75	(economic* or pharmaco?economic*).ti,ab.
76	(price* or pricing*).ti,ab.
77	(financ* or fee or fees or expenditure* or saving*).ti,ab.
78	(value adj2 (money or monetary)).ti,ab.
79	resourc* allocat*.ti,ab.
80	(fund or funds or funding* or funded).ti,ab.
81	(ration or rations or rationing* or rationed).ti,ab.
82	ec.fs.
83	or/63-82
84	62 and 83
85	limit 84 to ed=20101004-20230419
86	limit 84 to dt=20101004-20230419
87	85 or 86

## Database: Embase

Date of last search: 19/04/2023

#	Searches
1	placenta accreta/
2	(placenta* adj3 (accret* or adhes* disorder* or cret* or incret* or infiltrat* or invad* or invas* or percret*)).ti,ab,kf.
3	(AIP or MAP or PAD or PAS).ti.
4	(morbid* adhe* adj3 placenta*).ti,ab,kf.
5	or/1-4
6	placenta previa/
7	(placenta* adj3 (cervical os or cervix os or low* or marginal or pr?evia)).ti,ab,kf.
8	(placenta* adj3 (cervix adj2 (block* or cover* or near*))).ti,ab,kf.
9	or/6-8
10	exp cesarean section/
11	(caesar* or cesar* or c section* or csection* or cs birth* or cs deliver* or ((birth* or deliver*) adj3 (abdom* or operat* or surg*))).ti,ab,kf.
12	placenta/su
13	placenta disorder/su
14	exp uterus/su
15	exp uterus disease/su
16	curettage/ or "dilatation and curettage"/
17	uterine artery embolization/
18	myomectomy/
19	uterine rupture/su
20	postpartum hemorrhage/su
21	exp embryo transfer/ or in vitro fertilization/
22	maternal age/
23	multipara/
24	(curettage* or fibroidectom* or hysteroplast* or hysterotom* or metroplast* or myomectom*).ti,ab,kf.
25	((endometr* or intrauter* or uter* or womb) adj3 (ablat* or adhesiolysis or emboli* or excis* or incis* or lysis or polpectom* or repair* or resect* or scrap* or surg*)).ti,ab,kf.
26	((endometr* or intrauter* or uter* or womb) adj3 (perforat* or ruptur*)).ti,ab,kf.
27	asherman*.ti,ab,kf.
28	((endometri* or intrauter* or uter* or womb) adj2 scar*).ti,ab,kf.
29	((blastocyst* or embryo*) adj2 transfer*) or ((in vitro or invitro) adj2 fertili*) or ivf).ti,ab,kf.
30	((age* or old*) adj3 (matern* or mother*)).ti,ab,kf.
31	(multiparity or multipara* or multiparous or parity or parous).ti,ab,kf.
32	or/10-31
33	9 and 32
34	5 or 33
35	placenta disorder/di
36	exp uterus disease/di
37	three dimensional echography/ or three-dimensional imaging/ or echography/ or Doppler ultrasonography/ or duplex Doppler ultrasonography/ or color Doppler flowmetry/ or Doppler flowmetry/ or fetus echography/ or gray scale echography/
38	((doppler* or echo* or flowmet* or sono* or ultraso*) adj3 (3d or 3 d or colo?r* or doppler* or grayscale or gray scale or greyscale or grey scale or prenatal* or three dimension* or transabdominal* or transvaginal*)).ti,ab,kf.
39	exp nuclear magnetic resonance imaging/
40	(magnetic resonance or DWI or EPI or MRE or MRI or MRS or NMR* or T1W or T2W or WB-DWI or ((chemical shift or diffusion or echoplanar or magnet* or MR or nuclear or NM or planar or spin or weight*) adj2 (diagnos* or elastogra* or examin* or imag* or scan* or spectroscop* or tomogra*))).ti,ab,kf.

#	Searches
41	or/35-40
42	34 and 41
43	letter.pt. or letter/
44	note.pt.
45	editorial.pt.
46	case report/ or case study/
47	(letter or comment*).ti.
48	or/43-47
49	animal/ not human/
50	nonhuman/
51	exp Animal Experiment/
52	exp Experimental Animal/
53	animal model/
54	exp Rodent/
55	(rat or rats or rodent* or mouse or mice).ti.
56	or/49-55
57	48 or 56
58	42 not 57
59	limit 58 to english language
60	(conference abstract* or conference review or conference paper or conference proceeding).db,pt,su.
61	59 not 60
62	health economics/
63	exp economic evaluation/
64	exp health care cost/
65	exp fee/
66	budget/
67	funding/
68	resource allocation/
69	budget*.ti,ab.
70	cost*.ti,ab.
71	(economic* or pharmaco?economic*).ti,ab.
72	(price* or pricing*).ti,ab.
73	(financ* or fee or fees or expenditure* or saving*).ti,ab.
74	(value adj2 (money or monetary)).ti,ab.
75	resourc* allocat*.ti,ab.
76	(fund or funds or funding* or funded).ti,ab.
77	(ration or rations or rationing* or rationed).ti,ab.
78	or/62-77
79	61 and 78
80	limit 79 to dc=20101004-20230419

## Database: Health Technology Assessment (HTA)

Date of last search: 19/04/2023

#	Searches
1	MeSH DESCRIPTOR Placenta Accreta IN HTA
2	(placenta* adj3 (accret* or adhes* disorder* or cret* or incret* or infiltrat* or invad* or invas* or percret*)) IN HTA
3	((morbid* adhe* adj3 placenta*)) IN HTA
4	((AIP or MAP or PAD or PAS)):TI IN HTA
5	#1 OR #2 OR #3 OR #4
6	MeSH DESCRIPTOR Placenta Previa IN HTA
7	((placenta* adj3 (cervical os or cervix os or low* or marginal or praevia or previa))) IN HTA
8	(placenta* adj3 (cervix adj2 (block* or cover* or near*))) IN HTA
9	#6 OR #7 OR #8
10	MeSH DESCRIPTOR Cesarean Section EXPLODE ALL TREES IN HTA
11	(caesar* or cesar* or c section* or csection* or cs birth* or cs deliver* or ((birth* or deliver*) adj3 (abdom* or operat* or surg*))) IN HTA
12	MeSH DESCRIPTOR Placenta Diseases WITH QUALIFIER SU IN HTA
13	MeSH DESCRIPTOR Uterus EXPLODE ALL TREES WITH QUALIFIER SU IN HTA
14	MeSH DESCRIPTOR Uterine Diseases EXPLODE ALL TREES WITH QUALIFIER SU IN HTA
15	MeSH DESCRIPTOR Curettage in HTA
16	MeSH DESCRIPTOR Dilatation and Curettage in HTA
17	MeSH DESCRIPTOR Uterine Artery Embolization in HTA
18	MeSH DESCRIPTOR Uterine Myomectomy IN HTA
19	MeSH DESCRIPTOR Uterine Rupture EXPLODE ALL TREES WITH QUALIFIER SU IN HTA

#	Searches
20	MeSH DESCRIPTOR Postpartum Hemorrhage WITH QUALIFIER SU IN HTA
21	MeSH DESCRIPTOR Embryo Transfer EXPLODE ALL TREES IN HTA
22	MeSH DESCRIPTOR Fertilization in Vitro EXPLODE ALL TREES IN HTA
23	MeSH DESCRIPTOR Maternal Age IN HTA
24	MeSH DESCRIPTOR Parity IN HTA
25	((curettage* or fibroidectom* or hysteroplast* or hysterotom* or metroplast* or myomectom*)) IN HTA
25	((((endometr* or intrauter* or uter* or womb) adj3 (ablat* or adhesiolysis or emboli* or excis* or incis* or lysis or polpectom* or repair* or resect* or scrap* or surg*))) IN HTA
27	((((endometr* or intrauter* or uter* or womb) adj3 (perforat* or ruptur*))) IN HTA
28	(asherman*) IN HTA
29	((endometri* or intrauter* or uter* or womb) adj2 scar*) IN HTA
30	(((((blastocyst* or embryo*) adj2 transfer*) or ((in vitro or invitro) adj2 fertili*) or ivf)) IN HTA
31	((age* or old*) adj3 (matern* or mother*)) IN HTA
32	((multiparity or multipara* or multiparous or parity or parous)) IN HTA
33	#10 OR #11 OR #12 OR #13 OR #14 OR #15 OR #16 OR #17 OR #18 OR #19 OR #20 OR #21 OR #22 OR #23 OR #24 OR #25 OR #26 OR #27 OR #28 OR #29 OR #30 OR #31 OR #32
34	#9 AND #33
35	#5 OR #34
36	MeSH DESCRIPTOR Ultrasonography EXPLODE ALL TREES IN HTA
37	((doppler* or echo* or flowmet* or sono* or ultraso*) adj3 (3d or 3 d or colour* or color* or doppler* or grayscale or gray scale or greyscale or grey scale or prenatal* or three dimension* or transabdom* or trans abdom* or transvagina* or trans vagina*)) IN HTA
38	MeSH DESCRIPTOR Magnetic Resonance Imaging EXPLODE ALL TREES IN HTA
39	((magnetic resonance or DWI or EPI or MRE or MRI or MRS or NMR* or T1W or T2W or WB-DWI or ((chemical shift or diffusion or echoplanar or magnet* or MR or nuclear or NM or planar or spin or weight*) adj2 (diagnos* or elastogra* or examin* or imag* or scan* or spectroscop* or tomogra*))) IN HTA
40	#36 OR #37 OR #38 OR #39
41	#35 AND #40
42	* IN HTA WHERE LPD FROM 04/10/2010 TO 19/04/2023
43	#41 AND #42

## Database: INAHTA International HTA Database

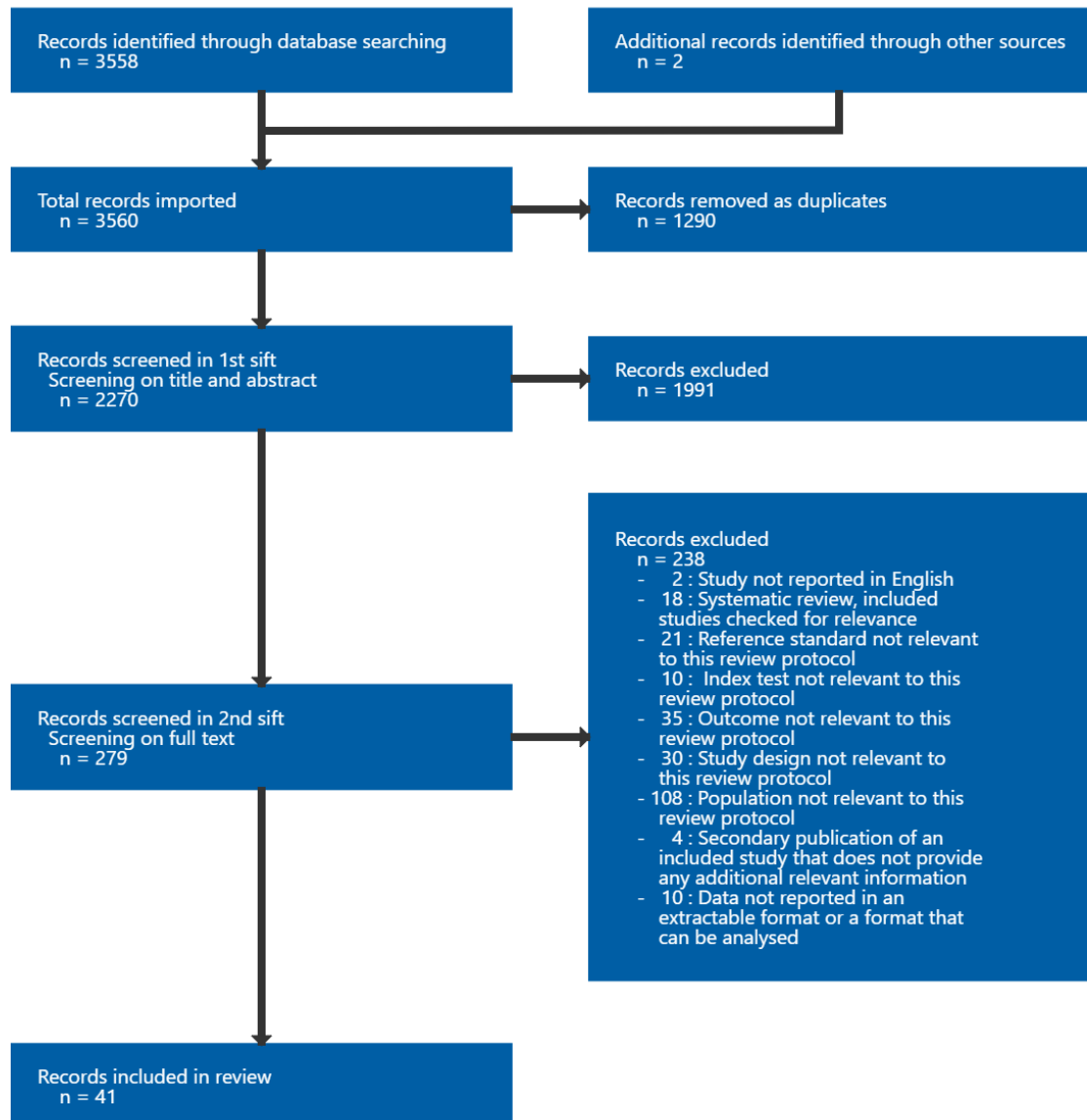
Date of last search: 19/04/2023

Line	Query
15	#9 and #14 FROM 2010 TO 2023 AND (English)[Language]
14	#10 or #11 or #12 or #13
13	("magnetic resonance" or DWI or EPI or MRE or MRI or MRS or NMR* or T1W or T2W or WB-DWI or ((chemical shift" or diffusion or echoplanar or magnet* or MR or nuclear or NM or planar or spin or weight*) and (diagnos* or elastogra* or examin* or imag* or scan* or spectroscop* or tomogra*))
12	"Magnetic Resonance Imaging"[mhe]
11	(doppler* or echo* or flowmet* or sono* or ultraso* or grayscale or "gray scale" or greyscale or "grey scale")
10	"Ultrasonography"[mhe]
9	#1 or #2 or #3 or #4 or #5 or #6 or #7 or #8
8	(placenta* and (multiparity or multipara* or multiparous or parity or parous))
7	(placenta* and ((age* or old*) and (matern* or mother*)))
6	(placenta* and (((blastocyst* or embryo*) and transfer*) or ((in vitro" or invitro) and fertili*) or ivf))
5	(placenta* and (((endometr* or intrauter* or uter* or womb) and (ablat* or adhesiolysis or emboli* or excis* or incis* or lysis or perforat* or polpectom* or repair* or resect* or rupture* or scar* or scrap* or surg*)) or asherman*))
4	(placenta* and (curettage* or fibroidectom* or hysteroplast* or hysterotom* or metroplast* or myomectom*))
3	((((placenta* and (cervical or cervix or low* or marginal or praevia or previa)) and (caesar* or cesar* or "c section" or csection* or (cs and (birth* or deliver*)) or ((birth* or deliver*) and (abdom* or operat* or surg*))))))
2	((placenta* and (accret* or adhes* or cret* or incret* or infiltrat* or invad* or invas* or percret*)) or (morbid* and adhe* and placenta*))
1	"Placenta Accreta"[mh]

## Appendix C Diagnostic evidence study selection

Study selection for: What is the accuracy of imaging techniques for diagnosis of a placenta accreta spectrum (PAS) in pregnant women who have had a previous caesarean birth and are currently diagnosed with placenta praevia?

Figure 1: Study selection flow chart



## Appendix D Evidence tables

**Evidence tables for review question: What is the accuracy of imaging techniques for diagnosis of a placenta accreta spectrum (PAS) in pregnant women who have had a previous caesarean birth and are currently diagnosed with placenta praevia?**

**Table 4: Evidence tables**

**Abdel Magied, 2018**

**Bibliographic Reference** Abdel Magied, A.M.; Salah Eldin, L.A.; Tohamey, Y.M.; Abd El Kader, M.A.; Placenta previa; MRI as an adjunct to ultrasound in assessment of suspected placental invasion; Egyptian Journal of Radiology and Nuclear Medicine; 2018; vol. 49 (no. 1); 284-291

### Study details

<b>Country/ies where study was carried out</b>	Egypt
<b>Study type</b>	Prospective cohort study
<b>Study dates</b>	Not reported
<b>Inclusion criteria</b>	Pregnant women with placenta praevia and risk factors, such as maternal age over 35 years, having many children and prior uterine intervention (for example, caesarean sections and dilatation and curettage)
<b>Exclusion criteria</b>	Not reported
<b>Patient characteristics</b>	N=23 Mean age in years (SD): 30.96 (NR) Gestational age in weeks (range): 25-37 Parity: multiparous

	<p>Mean BMI in kg/m<sup>2</sup> (SD): not reported</p> <p>Placenta praevia: N=23</p> <p>Gestational age at diagnosis of placenta praevia: not reported</p> <p>Previous uterine surgery: N=22</p> <p>Ethnicity: not reported</p>
<b>Index test(s)</b>	<ol style="list-style-type: none"> <li>1. Grey scale ultrasound plus colour-flow Doppler ultrasound (transabdominal and/or transvaginal)</li> <li>2. MRI without contrast (1.5-T MRI without contrast)</li> </ol> <p>Timing of ultrasound and MRI scans was before 36 weeks (elective delivery).</p> <p>Ultrasound features for diagnosis of PAS were the placental lacunae, whether retroplacental space was present or absent, absence of interface between the uterus and the bladder wall, increased vascularity along the interface between the serosal lining of the uterus and the bladder wall on colour-flow Doppler, and myometrial thinning.</p> <p>MRI features for diagnosis of PAS were heterogeneity in signal pattern of the placenta, uterus bulge, dark T2-WI intraplacental bands, focal interruption of myometrium, tenting of the bladder, and invasion of adjacent structures.</p> <p>Ultrasound and MRI examinations were performed by qualified consultants of radiology.</p>
<b>Reference standard(s)</b>	Operative findings with pathology reports
<b>Duration of follow-up</b>	Not reported
<b>Sources of funding</b>	Not reported
<b>Target condition</b>	PAS
<b>Results</b>	<p>Outcome: diagnosis of PAS (accreta, increta and percreta)*</p> <p>Grey scale ultrasound plus colour-flow Doppler ultrasound (N=23): TP 7; FP 1; FN 4; TN 11</p>

MRI without contrast (N=23): TP 8; FP 0; FN 3; TN 12

\*The study included N=6 with accreta, N=2 with increta, and N=3 with percreta, and N=10 participants with PAS had hysterectomy.

*BMI: body mass index; FN: false negative; FP: false positive; MRI: magnetic resonance imaging; NR: not reported; PAS: placenta accreta spectrum; SD: standard deviation; TN: true negative; TP: true positive; T2-WI: T2 weighted image; 1.5-T: 1.5 Tesla*

### Critical appraisal - NGA Critical appraisal - QUADAS-2

Section	Question	Answer
Patient selection: risk of bias	Could the selection of patients have introduced bias?	Unclear (Case-control design was avoided, but exclusion criteria not provided)
Patient selection: applicability	Are there concerns that included patients do not match the review question?	Low
Index tests: risk of bias	Could the conduct or interpretation of the index test have introduced bias?	Low
Index tests: applicability	Are there concerns that the index test, its conduct, or interpretation differ from the review question?	Low
Reference standard: risk of bias	Could the reference standard, its conduct, or its interpretation have introduced bias?	Low
Reference standard: applicability	Is there concern that the target condition as defined by the reference standard does not match the review question?	Low
Flow and timing: risk of bias	Could the patient flow have introduced bias?	Low

*QUADAS: Quality Assessment of Diagnostic Accuracy Studies*

### Akhtar, 2020

**Bibliographic Reference** Akhtar, N.; Bari, A.; Nazim, F.; Hayat, Z.; Comparison of diagnosis and management options for placenta accreta spectrum with standard guidelines; Rawal Medical Journal; 2020; vol. 45 (no. 4); 813-816

**Study details**

<b>Country/ies where study was carried out</b>	Pakistan
<b>Study type</b>	Prospective cohort study
<b>Study dates</b>	January 2017 - July 2019
<b>Inclusion criteria</b>	Pregnant women with history of previous caesarean section and with a diagnosis of either PAS major or anterior low-lying placenta in index pregnancy
<b>Exclusion criteria</b>	Not reported
<b>Patient characteristics</b>	<p>N=27</p> <p>Placenta praevia major: N=27</p> <p>Mean age in years (SD): 35.8 (NR)</p> <p>Mean gestational age in weeks for elective caesarean section (SD): 36 (NR)</p> <p>Gestational age at diagnosis of placenta praevia: not reported</p> <p>Parity: not reported</p> <p>Mean BMI in kg/m<sup>2</sup> (SD): not reported</p> <p>Ethnicity: not reported</p>
<b>Index test(s)</b>	Doppler ultrasound (unspecified type)



	Information on timing of Doppler ultrasound scan, Doppler ultrasound features for diagnosis of PAS, ultrasound approach, and the study personnel who conducted the scan not reported
<b>Reference standard(s)</b>	Confirmation of this antenatal diagnosis was done at the time of caesarean section
<b>Duration of follow-up</b>	Not reported
<b>Sources of funding</b>	Not reported
<b>Target condition</b>	PAS
<b>Results</b>	Outcome: diagnosis of PAS* Doppler ultrasound (unspecified type) (N=27): TP 11; FP 6; FN 1; TN 9 *The study did not specify type of PAS disorders. N=11 participants with PAS had hysterectomy.

BMI: body mass index; FN: false negative; FP: false positive; NR: not reported; PAS: placenta accreta spectrum; SD: standard deviation; TN: true negative; TP: true positive

### Critical appraisal - NGA Critical appraisal - QUADAS-2

Section	Question	Answer
Patient selection: risk of bias	Could the selection of patients have introduced bias?	Unclear (Case-control design was avoided, but exclusion criteria not provided)
Patient selection: applicability	Are there concerns that included patients do not match the review question?	Low
Index tests: risk of bias	Could the conduct or interpretation of the index test have introduced bias?	Low

Section	Question	Answer
Index tests: applicability	Are there concerns that the index test, its conduct, or interpretation differ from the review question?	Low
Reference standard: risk of bias	Could the reference standard, its conduct, or its interpretation have introduced bias?	Low
Reference standard: applicability	Is there concern that the target condition as defined by the reference standard does not match the review question?	Low
Flow and timing: risk of bias	Could the patient flow have introduced bias?	Low

QUADAS: *Quality Assessment of Diagnostic Accuracy Studies*

## Alalfy, 2021

**Bibliographic Reference** Alalfy, M.; Hamed, S.T.; Ghani, A.S.A.E.; Elgazzar, A.; Abbassy, A.; Rashwan, A.S.S.A.; Nagy, O.; Shalaby, M.A.; Hassan, H.; Ibrahim, A.; Kamal, H.; Mahrous, R.; Kamal, E.; The accuracy of 3D-TUI and 3D power Doppler using Alalfy simple criteria in the diagnosis of placenta accreta spectrum; *Clinical and Experimental Obstetrics and Gynecology*; 2021; vol. 48 (no. 5); 1132-1140

## Study details

<b>Country/ies where study was carried out</b>	Egypt
<b>Study type</b>	Prospective cohort study
<b>Study dates</b>	March 2018 - June 2019
<b>Inclusion criteria</b>	Pregnant women with gestational age 30 to 40 weeks, one or more previous caesarean section and placenta praevia with the lower placental edge reaches the level of internal os or covering the cervix

<b>Exclusion criteria</b>	Pregnant women with BMI over 40, any medical conditions (for example, diabetes and hypertension) and pregnancy-induced hypertension and who attended the emergency department with placenta praevia or suspected PAS
<b>Patient characteristics</b>	<p>N=90</p> <p>Mean age in years (SD): 31.9 (4.9)</p> <p>Mean gestational age in weeks (SD): 35.4 (1.6)</p> <p>Gestational age in weeks at diagnosis of placenta praevia (range): 30-40</p> <p>Mean BMI in kg/m<sup>2</sup> (SD): 30.7 (3.4)</p> <p>Placenta praevia: N=90</p> <p>Number of previous caesarean birth; mean (SD): 2.3 (0.9)</p> <p>Number of previous hysterotomies; mean (SD): 0.1 (0.3)</p>
<b>Index test(s)</b>	<ol style="list-style-type: none"> <li>1. 3D tomographic ultrasound imaging (3D-TUI) (transabdominal and transvaginal)</li> <li>2. 3D power Doppler ultrasound plus 3D tomographic ultrasound imaging (3D-TUI) (transabdominal and transvaginal)</li> </ol> <p>Ultrasound features for diagnosis of PAS were obliteration of clear space between the placenta and uterus, placental lacunae (irregular vascular spaces), reduced myometrial thickness less than 1 mm in the retroplacental area, increased placental vascularity, uterine serosa-bladder interface interruption, invasion of the bladder wall, vessels invading the myometrium, and bridging vessels.</p> <p>The study did not report information on timing of scan and radiologists who performed the tests.</p>
<b>Reference standard(s)</b>	Operative findings with pathology reports
<b>Duration of follow-up</b>	Not reported
<b>Sources of funding</b>	Not industry funded

<b>Target condition</b>	PAS
<b>Results</b>	<p>Outcome: diagnosis of PAS (accreta, increta, and percreta)*</p> <p>3D tomographic ultrasound imaging (3D-TUI) (N=90): TP 54; FP 0; FN 0; TN 36</p> <p>3D power Doppler ultrasound plus 3D tomographic ultrasound imaging (3D-TUI) (N=90): TP 54; FP 0; FN 0; TN 36</p> <p>*The study included N=17 with accreta, N=23 with increta, and N=14 with percreta, and N=40 participants with PAS had hysterectomy.</p>

*BMI: body mass index; FN: false negative; FP: false positive; PAS: placenta accreta spectrum; SD: standard deviation; TN: true negative; TP: true positive; 3D-TUI: Three Dimensional Tomographic Ultrasound Imaging*

#### Critical appraisal - NGA Critical appraisal - QUADAS-2

Section	Question	Answer
Patient selection: risk of bias	Could the selection of patients have introduced bias?	Low
Patient selection: applicability	Are there concerns that included patients do not match the review question?	Unclear <i>(All participants had placenta praevia, but no information on the total number of participants with a previous uterus intervention)</i>
Index tests: risk of bias	Could the conduct or interpretation of the index test have introduced bias?	Low
Index tests: applicability	Are there concerns that the index test, its conduct, or interpretation differ from the review question?	Low
Reference standard: risk of bias	Could the reference standard, its conduct, or its interpretation have introduced bias?	Low
Reference standard: applicability	Is there concern that the target condition as defined by the reference standard does not match the review question?	Low

Section	Question	Answer
Flow and timing: risk of bias	Could the patient flow have introduced bias?	Low

QUADAS: *Quality Assessment of Diagnostic Accuracy Studies*

### Algebally, 2014

**Bibliographic Reference** Algebally, Ahmed M; Yousef, Reda Ramadan Hussein; Badr, Sanaa Sayed Hussein; Al Obeidly, Amal; Szmigielski, Wojciech; Al Ibrahim, Abdullah A; The value of ultrasound and magnetic resonance imaging in diagnostics and prediction of morbidity in cases of placenta previa with abnormal placentation.; Polish journal of radiology; 2014; vol. 79; 409-16

### Study details

<b>Country/ies where study was carried out</b>	Qatar
<b>Study type</b>	Prospective cohort study
<b>Study dates</b>	January 2011 - March 2014
<b>Inclusion criteria</b>	Pregnant women with placenta praevia who were examined in the Department of Radiology, Hamad Medical Corporation, Doha
<b>Exclusion criteria</b>	Not reported
<b>Patient characteristics</b>	N=100 Mean age in years (SD): 33 (NR) Gestational age in weeks at birth: 36 Parity: grand multiparity

	<p>Placenta praevia: N=100</p> <p>Gestational age at diagnosis of placenta praevia: not reported</p> <p>BMI: not reported</p> <p>The study stated that participants had risk factors for abnormal placentation, including previous uterine interventions (for example, caesarean sections, dilation and curettage and myomectomy); however, the study did not specify the number of participants with each uterine intervention.</p>
<b>Index test(s)</b>	<ol style="list-style-type: none"> <li>1. Grey scale ultrasound plus colour-flow Doppler ultrasound*</li> <li>2. MRI without contrast (1.5-T MRI without contrast)</li> </ol> <p>Radiological examinations were performed by registered sonographers and interpreted by an accompanied radiologist.</p> <p>Ultrasound features for diagnosis of PAS were loss of the retroplacental hypoechoic clear zone, loss of the bladder wall-uterine interface, presence of placental lacunae (vascular spaces), abnormal colour Doppler imaging pattern as the presence of hypervascularity of the interface between the uterine serosa and the bladder wall, turbulent flow within placental lacunae and reduced myometrial thickness.</p> <p>MRI features for diagnosis of PAS were uterine bulging, heterogeneous signal intensity within the placenta, dark intraplacental bands on T2-WI, focal defects in the myometrial wall, tenting of the bladder, and direct visualization of invasion of pelvic structures by placental tissue.</p> <p>The study did not report information on timing of ultrasound and MRI scan.</p> <p>*The study did not specify whether transabdominal or transvaginal or translabial approach was used</p>
<b>Reference standard(s)</b>	Operative findings at caesarean section without histology reports/lab findings
<b>Duration of follow-up</b>	Not reported
<b>Sources of funding</b>	Not reported

<b>Target condition</b>	PAS
<b>Results</b>	<p>Outcome: diagnosis of PAS (accreta, increta, and percreta)*</p> <p>Grey scale ultrasound plus colour-flow Doppler ultrasound (N=100): TP 30; FP 2; FN 2; TN 66</p> <p>MRI without contrast (N=100): TP 32; FP 0; FN 0; TN 68</p> <p>*The study included N=12 with accreta, N=8 with increta, and N=12 with percreta and stated that hysterectomy was more common in participants with PAS associated with placenta praevia.</p>

*FN: false negative; FP: false positive; MRI: magnetic resonance imaging; NR: not reported; PAS: placenta accreta spectrum; TN: true negative; TP: true positive; T2-WI: T2 weighted image; 1.5-T: 1.5 Tesla*

#### Critical appraisal - NGA Critical appraisal - QUADAS-2

Section	Question	Answer
Patient selection: risk of bias	Could the selection of patients have introduced bias?	Unclear (Case-control design was avoided, but exclusion criteria not provided)
Patient selection: applicability	Are there concerns that included patients do not match the review question?	Unclear (All participants had placenta praevia, but no information on the total number of participants with a previous uterus intervention)
Index tests: risk of bias	Could the conduct or interpretation of the index test have introduced bias?	Low
Index tests: applicability	Are there concerns that the index test, its conduct, or interpretation differ from the review question?	Low
Reference standard: risk of bias	Could the reference standard, its conduct, or its interpretation have introduced bias?	Low

Section	Question	Answer
Reference standard: applicability	Is there concern that the target condition as defined by the reference standard does not match the review question?	Low
Flow and timing: risk of bias	Could the patient flow have introduced bias?	Low

QUADAS: *Quality Assessment of Diagnostic Accuracy Studies*

### Alici Davutoglu, 2018

**Bibliographic Reference** Alici Davutoglu, E.; Arioiz Habibi, H.; Ozel, A.; Erenel, H.; Adaletli, I.; Madazli, R.; Diagnostic accuracy of ultrasonography and magnetic resonance imaging in the assessment of placenta previa accreta; *Turkiye Klinikleri Jinekoloji Obstetrik*; 2018; vol. 28 (no. 3); 105-111

### Study details

<b>Country/ies where study was carried out</b>	Turkey
<b>Study type</b>	Prospective cohort study
<b>Study dates</b>	January 2015 - November 2015
<b>Inclusion criteria</b>	Pregnant women with anterior placenta previa and at least one of risk factors for PAS, including a previous caesarean birth, curettage or myomectomy
<b>Exclusion criteria</b>	Presence of high blood pressure, pre-eclampsia, gestational diabetes, multiple gestations, contraindication for MRI, and foetal structural or chromosomal abnormalities; and smoking and taking medication
<b>Patient characteristics</b>	N=29 (PAS: N=13; No PAS: N=16) Mean age in years (SD):



	<p>PAS: 31.7 (4.2) No PAS: 30.9 (5.9)</p> <p>Mean gestational age in weeks at birth (SD): PAS: 34.6 (5.0) No PAS: 37.7 (0.8)</p> <p>Mean parity (SD): PAS: 2.2 (0.7) No PAS: 1.1 (0.7)</p> <p>Placenta praevia: N=29</p> <p>Gestational age at diagnosis of placenta praevia: not reported</p> <p>1 previous caesarean birth: PAS: N=2 No PAS: N=8</p> <p>≥2 previous caesarean birth: PAS: N=11 No PAS: N=3</p> <p>BMI: not reported</p>
<b>Index test(s)</b>	<ol style="list-style-type: none"> <li>1. Grey scale ultrasound plus colour-flow Doppler ultrasound (transvaginal)</li> <li>2. MRI without contrast (1.5-T MRI without contrast)</li> </ol> <p>Radiological examinations were performed by two experienced radiologists.</p> <p>Ultrasound features for diagnosis of PAS were loss of myometrial interface or retroplacental clear space, placental lacunae, reduced myometrial thickness &lt;1 mm, loss of the bladder wall–uterine border, presence of a focal exophytic mass with the same echogenicity as placenta beyond the uterine serosa, chaotic intra-placental blood flow and intra-placental lacunae, bladder uterine serosa interface hypervascularity, vessels extending from placenta to bladder, and vessels bridging from placenta to margin of uterus.</p>

	<p>MRI features for diagnosis of PAS were dark intra-placental bands, placental heterogeneity, intra-placental haemorrhages, focal interruption of the myometrium and tenting of the bladder, and uterine bulging.</p> <p>Grey scale ultrasound plus colour-flow Doppler ultrasound and MRI were performed at mean (SD) gestational age 29.4 (2.9) and 30.4 (2.4) weeks.</p>
<b>Reference standard(s)</b>	Operative findings with/without pathology reports
<b>Duration of follow-up</b>	<p>Not reported*</p> <p>*It could be up to 11 weeks as participants had ultrasound and MRI examinations at 29 and 30 weeks.</p>
<b>Sources of funding</b>	Not industry funded
<b>Target condition</b>	PAS
<b>Results</b>	<p>Outcome: diagnosis of PAS (accreta, increta, and percreta)*</p> <p>Grey scale ultrasound plus colour-flow Doppler ultrasound (N=29): TP 11; FP 3; FN 2; TN 13</p> <p>MRI without contrast (N=29): TP 13; FP 4; FN 0; TN 12</p> <p>*The study did not specify number of participants with accreta, increta and percreta, and N=7 participants with PAS had hysterectomy.</p>

FN: false negative; FP: false positive; MRI: magnetic resonance imaging; PAS: placenta accreta spectrum; SD: standard deviation; TN: true negative; TP: true positive; 1.5-T: 1.5 Tesla

### Critical appraisal - NGA Critical appraisal - QUADAS-2

Section	Question	Answer
Patient selection: risk of bias	Could the selection of patients have introduced bias?	Low

Section	Question	Answer
Patient selection: applicability	Are there concerns that included patients do not match the review question?	High <i>(All participants had placenta praevia, but only 83% of participants had a previous caesarean birth.)</i>
Index tests: risk of bias	Could the conduct or interpretation of the index test have introduced bias?	Low
Index tests: applicability	Are there concerns that the index test, its conduct, or interpretation differ from the review question?	Low
Reference standard: risk of bias	Could the reference standard, its conduct, or its interpretation have introduced bias?	Low
Reference standard: applicability	Is there concern that the target condition as defined by the reference standard does not match the review question?	Low
Flow and timing: risk of bias	Could the patient flow have introduced bias?	Low

QUADAS: *Quality Assessment of Diagnostic Accuracy Studies*

### Bourgioti, 2021

#### Bibliographic Reference

Bourgioti, Charis; Konstantinidou, Anastasia Evangelia; Zafeiropoulou, Konstantina; Antoniou, Aristeidis; Fotopoulos, Stavros; Theodora, Marianna; Daskalakis, George; Nikolaidou, Maria Evangelia; Tzavara, Chara; Letsika, Aikaterini; Martzoukos, Epameinondas Anastasios; Mouloupoulos, Lia Angela; Intraplacental Fetal Vessel Diameter May Help Predict for Placental Invasiveness in Pregnant Women at High Risk for Placenta Accreta Spectrum Disorders.; *Radiology*; 2021; vol. 298 (no. 2); 403-412

#### Study details

<b>Country/ies where study was carried out</b>	Greece
<b>Study type</b>	Prospective cohort study
<b>Study dates</b>	March 2016 - October 2019
<b>Inclusion criteria</b>	Pregnant women in the third trimester who were at high risk for PAS (due to presence of placenta praevia and/or suspected PAS on the second-trimester ultrasound) and were referred for MRI examination
<b>Exclusion criteria</b>	Pregnant women who did not complete the MRI examination due to claustrophobia or obesity
<b>Patient characteristics</b>	<p>N=155</p> <p>Mean age in years (SD): 35 (5)</p> <p>Placenta praevia: N=138</p> <p>Low-lying placenta: N=8</p> <p>Gestational age at diagnosis of placenta praevia or low-lying placenta: third trimester</p> <p>Previous caesarean birth and/or other uterine intervention: N=128</p> <p>In-vitro fertilization conceptions: N=19</p> <p>Parity: not reported</p> <p>BMI: not reported</p> <p>Participants with placenta praevia and/or suspicious PAS findings at the second-trimester ultrasound were included and underwent MRI examinations.</p>
<b>Index test(s)</b>	<p>MRI without contrast (1.5-T or 3-T MRI without contrast)</p> <p>Two radiologists experienced in genitourinary MRI performed MRI readings.</p>

	<p>MRI features for diagnosis of PAS were myometrial thinning, intraplacental T2-hypointense bands, uterine bulge, exophytic placental mass, serosal, bladder and parametrial vessel sign, and signs of bladder invasion.</p> <p>MRI examination was performed at mean (SD) gestational age 32 (3) weeks.</p>
<b>Reference standard(s)</b>	Post caesarean birth examination with histology
<b>Duration of follow-up</b>	2 weeks (all women underwent caesarean section within a median interval of 2 weeks from MRI examination)
<b>Sources of funding</b>	Not reported
<b>Target condition</b>	PAS
<b>Results</b>	<p>Outcome: diagnosis of PAS (accreta, increta and, percreta)*</p> <p>MRI without contrast (N=155): TP 121; FP 4; FN 5; TN 25</p> <p>2x2 table not reported by the study but calculated based on sensitivity and specificity presented</p> <p>*The study included N=58 with accreta and/or increta, and N=68 with percreta, and N=56 participants with PAS had hysterectomy.</p>

*FN: false negative; FP: false positive; MRI: magnetic resonance imaging; PAS: placenta accreta spectrum; SD: standard deviation; TN: true negative; TP: true positive; 1.5-T: 1.5 Tesla; 3-T: 3 Tesla*

### Critical appraisal - NGA Critical appraisal - QUADAS-2

Section	Question	Answer
Patient selection: risk of bias	Could the selection of patients have introduced bias?	Low
Patient selection: applicability	Are there concerns that included patients do not match the review question?	High <i>(About 94% of participants had placenta praevia, but only 82%</i>

Section	Question	Answer
		<i>of participants had a previous caesarean birth or uterine intervention)</i>
Index tests: risk of bias	Could the conduct or interpretation of the index test have introduced bias?	Low
Index tests: applicability	Are there concerns that the index test, its conduct, or interpretation differ from the review question?	Low
Reference standard: risk of bias	Could the reference standard, its conduct, or its interpretation have introduced bias?	Low
Reference standard: applicability	Is there concern that the target condition as defined by the reference standard does not match the review question?	Low
Flow and timing: risk of bias	Could the patient flow have introduced bias?	Low

QUADAS: *Quality Assessment of Diagnostic Accuracy Studies*

## Cali, 2018a

**Bibliographic Reference** Cali, G; Forlani, F; Foti, F; Minneci, G; Manzoli, L; Flacco, M E; Buca, D; Liberati, M; Scambia, G; D'Antonio, F; Diagnostic accuracy of first-trimester ultrasound in detecting abnormally invasive placenta in high-risk women with placenta previa.; *Ultrasound in obstetrics & gynecology : the official journal of the International Society of Ultrasound in Obstetrics and Gynecology*; 2018; vol. 52 (no. 2); 258-264

## Study details

<b>Country/ies where study was carried out</b>	Italy
--	-------

<b>Study type</b>	Retrospective cohort study
<b>Study dates</b>	2007 – 2017
<b>Inclusion criteria</b>	Pregnant women with at least a previous caesarean section and/or uterus surgery and placenta praevia who had ultrasound scan for PAS at 11 to 14 weeks of gestation
<b>Exclusion criteria</b>	Not reported
<b>Patient characteristics</b>	<p>N=188</p> <p>Mean age in years (SD): 31.7 (5.4)</p> <p>Mean gestational age in weeks at birth (SD): 35.4 (2.3)</p> <p>Median parity (range):  PAS: 2 (2-3)  No PAS: 2 (0-2)</p> <p>Placenta praevia: N=188</p> <p>Gestational age at diagnosis of placenta praevia: not reported*</p> <p>Previous caesarean birth:  ≤1 previous caesarean birth: N=75  2 previous caesarean birth: N=71  ≥3 previous caesarean birth: N=42</p> <p>Number of previous caesarean birth; median (range):  PAS: 2 (1-2)  No PAS: 2 (0-2)</p> <p>Previous uterus surgery (other than caesarean birth): N=70</p> <p>BMI: not reported</p> <p>*It could be before or at 11 to 14 weeks as ultrasound scan for PAS was performed at 11 to 14 weeks of gestation.</p>

<b>Index test(s)</b>	<p>Grey scale ultrasound plus colour-flow Doppler ultrasound (transabdominal with or without transvaginal)</p> <p>Radiological examinations were performed by two examiners, but no further information on examiners was provided.</p> <p>Ultrasound features for diagnosis of PAS were loss of clear zone, placental lacunae, bladder wall interruption, and uterovesical hypervascularity.</p> <p>This study reported diagnostic accuracy of individual feature, <math>\geq 1</math> feature, <math>\geq 2</math> features, and <math>\geq 3</math> features. However, this review only reported diagnostic accuracy data on <math>\geq 3</math> features.</p> <p>Grey scale and colour-flow Doppler ultrasound examinations were performed between 11 and 14 weeks of gestation.</p>
<b>Reference standard(s)</b>	Operative findings with histology reports
<b>Duration of follow-up</b>	<p>Not reported*</p> <p>*It could be up to 25 weeks as participants had ultrasound scan between 11 to 14 weeks and delivery at 34 or 36 weeks.</p>
<b>Sources of funding</b>	Not reported
<b>Target condition</b>	PAS
<b>Results</b>	<p>Outcome: diagnosis of PAS (accreta, increta, and percreta)*</p> <p>Grey scale ultrasound plus colour-flow Doppler ultrasound (N=188): TP 58; FP 0; FN 25; TN 105</p> <p>2x2 table not reported by the study but calculated based on sensitivity and specificity presented</p> <p>*The study included N=45 with accreta or increta, and N=38 with percreta and did not specify number of participants with PAS who had hysterectomy.</p>

FN: false negative; FP: false positive; PAS: placenta accreta spectrum; SD: standard deviation; TN: true negative; TP: true positive

### Critical appraisal - NGA Critical appraisal - QUADAS-2



Section	Question	Answer
Patient selection: risk of bias	Could the selection of patients have introduced bias?	Unclear (Case-control design was avoided, but exclusion criteria not provided)
Patient selection: applicability	Are there concerns that included patients do not match the review question?	Low
Index tests: risk of bias	Could the conduct or interpretation of the index test have introduced bias?	Low
Index tests: applicability	Are there concerns that the index test, its conduct, or interpretation differ from the review question?	Low
Reference standard: risk of bias	Could the reference standard, its conduct, or its interpretation have introduced bias?	Low
Reference standard: applicability	Is there concern that the target condition as defined by the reference standard does not match the review question?	Low
Flow and timing: risk of bias	Could the patient flow have introduced bias?	Low

QUADAS: *Quality Assessment of Diagnostic Accuracy Studies*

## Cali, 2018b

**Bibliographic Reference** Cali, Giuseppe; Forlani, Francesco; Timor-Trisch, Ilan; Palacios-Jaraquemada, Jose; Foti, Francesca; Minneci, Gabriella; Flacco, Maria E; Manzoli, Lamberto; Familiari, Alessandra; Pagani, Giorgio; Scambia, Giovanni; D'Antonio, Francesco; Diagnostic accuracy of ultrasound in detecting the depth of invasion in women at risk of abnormally invasive placenta: A prospective longitudinal study.; *Acta obstetrica et gynecologica Scandinavica*; 2018; vol. 97 (no. 10); 1219-1227

## Study details

<b>Country/ies where study was carried out</b>	Italy
<b>Study type</b>	Prospective cohort study
<b>Study dates</b>	2007 – 2017
<b>Inclusion criteria</b>	Pregnant women with placenta praevia and at least one previous caesarean birth or uterus surgery
<b>Exclusion criteria</b>	Not reported
<b>Patient characteristics</b>	<p>N=210</p> <p>Mean age in years (SD): 32.1 (5.4)</p> <p>Mean gestational age in weeks at birth (SD): 35.3 (2.2)</p> <p>Gestational age at diagnosis of placenta praevia: not reported</p> <p>Median parity (range):  PAS: 2 (2-3)  No PAS: 2 (0-2)</p> <p>Placenta praevia: N=210</p> <p>Previous caesarean birth: N=182</p> <p>Number of previous caesarean birth; median (range): 2 (1-2)</p> <p>Myomectomy or uterine curettage: N=28</p> <p>BMI: not reported</p>
<b>Index test(s)</b>	Grey scale ultrasound and colour-flow Doppler ultrasound (transabdominal and transvaginal)

	<p>Ultrasound features for diagnosis of PAS were loss of the clear zone, placental lacunae, bladder wall interruption, and uterovesical hypervascularity.</p> <p>This study reported diagnostic accuracy of individual feature, <math>\geq 1</math> feature, <math>\geq 2</math> features, and <math>\geq 3</math> features. However, this review only reported diagnostic accuracy data on <math>\geq 3</math> features.</p> <p>Grey scale and colour-flow Doppler ultrasound examinations were performed at the second and third trimester, but the exact gestational age in weeks at scan not reported. No information on radiologists was reported.</p>
<b>Reference standard(s)</b>	Operative findings and histology reports
<b>Duration of follow-up</b>	<p>Not reported*</p> <p>*It could be up to 23 weeks as participants had ultrasound scan at the second (from 13 weeks of gestational age) and third trimester of pregnancy and had delivery at 34 or 36 weeks of gestational age.</p>
<b>Sources of funding</b>	Not reported
<b>Target condition</b>	PAS
<b>Results</b>	<p>Outcome: diagnosis of PAS (accreta, increta, and percreta)*</p> <p>Grey scale ultrasound plus colour-flow Doppler ultrasound (N=210): TP 85; FP 0; FN 20; TN 105</p> <p>*The study included N=57 with accreta or increta, and N=48 with percreta and did not specify whether participants with PAS had hysterectomy.</p>

FN: false negative; FP: false positive; MRI: magnetic resonance imaging; PAS: placenta accreta spectrum; SD: standard deviation; TN: true negative; TP: true positive

## Critical appraisal - NGA Critical appraisal - QUADAS-2

Section	Question	Answer
Patient selection: risk of bias	Could the selection of patients have introduced bias?	Unclear <i>(Case-control design was avoided, but exclusion criteria not provided)</i>
Patient selection: applicability	Are there concerns that included patients do not match the review question?	Low
Index tests: risk of bias	Could the conduct or interpretation of the index test have introduced bias?	Low
Index tests: applicability	Are there concerns that the index test, its conduct, or interpretation differ from the review question?	Low
Reference standard: risk of bias	Could the reference standard, its conduct, or its interpretation have introduced bias?	Low
Reference standard: applicability	Is there concern that the target condition as defined by the reference standard does not match the review question?	Low
Flow and timing: risk of bias	Could the patient flow have introduced bias?	Low

QUADAS: *Quality Assessment of Diagnostic Accuracy Studies*

## Coutinho, 2021

### Bibliographic Reference

Coutinho, C M; Giorgione, V; Noel, L; Liu, B; Chandrabaran, E; Pryce, J; Frick, A P; Thilaganathan, B; Bhide, A; Effectiveness of contingent screening for placenta accreta spectrum disorders based on persistent low-lying placenta and previous uterine surgery.; *Ultrasound in obstetrics & gynecology : the official journal of the International Society of Ultrasound in Obstetrics and Gynecology*; 2021; vol. 57 (no. 1); 91-96

### Study details

<b>Country/ies where study was carried out</b>	UK
<b>Study type</b>	Retrospective cohort study
<b>Study dates</b>	2009 – 2019
<b>Inclusion criteria</b>	Pregnant women with persistent low-lying placenta in the third trimester with a history of previous uterine surgery or Caesarean section
<b>Exclusion criteria</b>	Pregnant women with a low-lying placenta at the mid-trimester ultrasound examination who transferred to another centre before assessment of placental location at 32–34 weeks
<b>Patient characteristics</b>	<p>N=173 (Diagnostic cohort) (Whole cohort/screening cohort N=415)*</p> <p>Median maternal age in years (IQR)**:  No PAS: 35.0 (32.0-38.0)  PAS: 39.0 (35.0-40.7)</p> <p>Gestational age in weeks at diagnosis of placenta praevia (range): 32-34</p> <p>Parity 0**:  No PAS: N=180  PAS: N=1</p> <p>Parity 1**:  No PAS: N=142  PAS: N=7</p> <p>Parity ≥2**:  No PAS: N=15  PAS: N=9</p> <p>BMI (kg/m<sup>2</sup>) (median, IQR)**:</p>

No PAS: 24.2 (21.9-27.6)

PAS: 25.9 (22.9-28.3)

0 previous caesarean section\*\*:

No PAS: N=314

PAS: N=2

1 previous caesarean section\*\*:

No PAS: N=64

PAS: N=11

≥2 previous caesarean section\*\*:

No PAS: N=15

PAS: N=9

Previous other uterine surgery\*\*:

No PAS: N=17

PAS: N=3

Ethnicity\*\*: Caucasian

No PAS: N=243

PAS: N=3

Ethnicity\*\*: Asian

No PAS: N=94

PAS: N=6

Ethnicity\*\*: Afro-Caribbean

No PAS: N=46

PAS: N=11

BMI: not reported

\*Those with confirmed placenta praevia and a previous uterine intervention from screening cohort were referred to PAS diagnostic service (Diagnostic cohort).

	<p>**The data on screening cohort (N=415) were reported as the study did not report baseline characteristics of diagnostic cohort separately.</p>
<b>Index test(s)</b>	<p>Grey scale ultrasound (2D) plus colour-flow Doppler ultrasound with or without MRI</p> <p>Ultrasound and MRI did not happen together. Ultrasound was first and MRI was performed only if there were ultrasound features of extrauterine invasion (that is, focal exophytic mass, distortion of parametrial anatomy or cervix).</p> <p>Qualified sonographers assessed the pregnant women. The PAS diagnostic service was run by two consultants with significant experience in the prenatal diagnosis of PAS.</p> <p>Ultrasound features for diagnosis of PAS were the presence of multiple irregular lacunar spaces within the placenta with turbulent blood flow on Doppler ultrasound, absence of the clear zone (that is, the normal hypoechoic line between the placenta and the myometrium), thinning of myometrium at retroplacental area, increased placental thickness, and the presence of bladder wall interruption (that is, loss or irregularity of the hyperechoic line between the uterine serosa and bladder).</p> <p>Ultrasound approach not reported</p> <p>Timing of Ultrasound and MRI scans in diagnostic cohort not reported</p>
<b>Reference standard(s)</b>	Operative findings with or without histopathological reports
<b>Duration of follow-up</b>	Not reported
<b>Sources of funding</b>	Not industry funded
<b>Target condition</b>	PAS
<b>Results</b>	<p>Outcome: diagnosis of PAS*</p> <p>Grey scale ultrasound plus colour-flow Doppler ultrasound with or without MRI (N=173): TP 86; FP 1; FN 3; TN 83</p> <p>*N=89 had PAS, but the study did not specify type of PAS disorder and whether participants had hysterectomy.</p>

*BMI: body mass index; FN: false negative; FP: false positive; IQR: interquartile range; MRI: magnetic resonance imaging; PAS: placenta accreta spectrum; TN: true negative; TP: true positive; 2D: two dimensional*

Section	Question	Answer
Patient selection: risk of bias	Could the selection of patients have introduced bias?	Low
Patient selection: applicability	Are there concerns that included patients do not match the review question?	Low
Index tests: risk of bias	Could the conduct or interpretation of the index test have introduced bias?	Unclear (MRI features not reported)
Index tests: applicability	Are there concerns that the index test, its conduct, or interpretation differ from the review question?	Low
Reference standard: risk of bias	Could the reference standard, its conduct, or its interpretation have introduced bias?	Low
Reference standard: applicability	Is there concern that the target condition as defined by the reference standard does not match the review question?	Low
Flow and timing: risk of bias	Could the patient flow have introduced bias?	Low

*MRI: magnetic resonance imaging; QUADAS: Quality Assessment of Diagnostic Accuracy Studies*

### di Pasquo, 2020

**Bibliographic Reference** di Pasquo, E; Ghi, T; Cali, G; D'Antonio, F; Fratelli, N; Forlani, F; Prefumo, F; Kaihura, C T; Volpe, N; Dall'Asta, A; Frusca, T; Intracervical lakes as sonographic marker of placenta accreta spectrum disorder in patients with placenta previa or low-lying placenta.; *Ultrasound in obstetrics & gynecology : the official journal of the International Society of Ultrasound in Obstetrics and Gynecology*; 2020; vol. 55 (no. 4); 460-466



**Study details**

<b>Country/ies where study was carried out</b>	Italy
<b>Study type</b>	Retrospective cohort study
<b>Study dates</b>	January 2015 - September 2018
<b>Inclusion criteria</b>	Pregnant women with low-lying placenta or placenta praevia at $\geq 26$ weeks of gestation who had delivery outcome and histopathological results
<b>Exclusion criteria</b>	Pregnant women who lost to follow-up and did not have histological examination
<b>Patient characteristics</b>	<p>N=332</p> <p>Median age in years (IQR): 33.0 (29.0-37.0)</p> <p>Median gestational age in weeks at birth (IQR): 36.1 (35.0-37.0)</p> <p>Gestational age at diagnosis of placenta praevia: at or after 26 weeks</p> <p>Median parity (IQR): 1 (0-2)</p> <p>Median pre-pregnancy BMI in kg/m<sup>2</sup> (IQR): 24.2 (21.7-26.6)</p> <p>Placenta praevia: N=293</p> <p>Low-lying placenta: N=39</p> <p>Previous caesarean birth: N=210</p> <p>1 previous caesarean birth: N=65</p> <p>2 previous caesarean birth: N=92</p> <p><math>\geq 3</math> previous caesarean birth: N=53</p> <p>Previous myomectomy: N=13</p>

	Previous uterine curettage: N=64
<b>Index test(s)</b>	<p>Grey scale ultrasound plus colour-flow and 3D power Doppler ultrasounds (transabdominal and transvaginal)</p> <p>Six expert sonographers with more than 10 years of experience in prenatal diagnosis performed ultrasound examinations.</p> <p>This study reported diagnostic accuracy of individual feature and combination of features. In this review, the latter was reported.</p> <p>The diagnosis of PAS was regarded as positive when at least one typical ultrasound features (loss of the clear zone, presence of placental lacunae, bladder wall interruption and uterovesical hypervascularity on Grey scale and colour-flow Doppler ultrasound) and intracervical lakes on colour-flow Doppler ultrasound were present.</p> <p>The study did not report information on timing of scan.</p>
<b>Reference standard(s)</b>	Operative findings with/without histology reports
<b>Duration of follow-up</b>	Not reported
<b>Sources of funding</b>	Not reported
<b>Target condition</b>	PAS
<b>Results</b>	<p>Outcome: diagnosis of PAS (percreta and other PAS disorder)*</p> <p>Grey scale ultrasound plus colour-flow and 3D power Doppler ultrasounds (N=332): TP 82; FP 9; FN 94; TN 147</p> <p>2x2 table not reported by the study but calculated based on sensitivity and specificity presented</p> <p>*The study included N=74 with percreta and N=102 with other PAS disorder, and N=132 participants with PAS had hysterectomy.</p>

*FN: false negative; FP: false positive; IQR: interquartile range; PAS: placenta accreta spectrum; TN: true negative; TP: true positive; 3D: three dimensional*

### Critical appraisal - NGA Critical appraisal - QUADAS-2

Section	Question	Answer
Patient selection: risk of bias	Could the selection of patients have introduced bias?	Low
Patient selection: applicability	Are there concerns that included patients do not match the review question?	High <i>(All participants had placenta praevia, but only 86% of participants had a previous caesarean birth or myomectomy or uterine curettage)</i>
Index tests: risk of bias	Could the conduct or interpretation of the index test have introduced bias?	Low
Index tests: applicability	Are there concerns that the index test, its conduct, or interpretation differ from the review question?	Low
Reference standard: risk of bias	Could the reference standard, its conduct, or its interpretation have introduced bias?	Low
Reference standard: applicability	Is there concern that the target condition as defined by the reference standard does not match the review question?	Low
Flow and timing: risk of bias	Could the patient flow have introduced bias?	Low

QUADAS: *Quality Assessment of Diagnostic Accuracy Studies*

## Einerson, 2021

**Bibliographic Reference** Einerson, Brett D; Rodriguez, Christina E; Silver, Robert M; Donnelly, Meghan A; Kennedy, Anne M; Woodward, Paula J; Accuracy and Interobserver Reliability of Magnetic Resonance Imaging for Placenta Accreta Spectrum Disorders.; American journal of perinatology; 2021; vol. 38 (no. 9); 960-967

## Study details

<b>Country/ies where study was carried out</b>	USA
<b>Study type</b>	Retrospective cohort study
<b>Study dates</b>	1997 – 2017
<b>Inclusion criteria</b>	Pregnant women with an MRI performed for to evaluate possible PAS during the second or third trimester at the University of Utah and the University of Colorado
<b>Exclusion criteria</b>	Pregnant women delivering outside of the study institutions
<b>Patient characteristics</b>	<p>N=68</p> <p>Median age in years (IQR): 33.0 (29-37)</p> <p>Median parity (IQR): 2.0 (1-3)</p> <p>Median gestational age at birth (IQR): 34.8 (33.7-36.2)</p> <p>Gestational age at diagnosis of placenta praevia: not reported</p> <p>Placenta praevia: N=51</p> <p>Number of previous caesarean birth; median (IQR): 2 (1-3)</p> <p>BMI: not reported</p> <p>In this study, participants with suspicious PAS findings on ultrasound or clinically suspicious PAS findings (for example, history of endometrial ablation, major myomectomy, or treatment for Asherman's syndrome) underwent MRI examinations. The timing of ultrasound scan was not reported.</p>
<b>Index test(s)</b>	MRI without contrast (1.5-T MRI without contrast)

	<p>MRI examination was performed by two experienced radiologists. The study reported diagnostic accuracy data for PAS when (1) either radiologist made an interpretation and (2) both radiologists agreed on an interpretation. In this review, only the latter was reported.</p> <p>MRI features for diagnosis of PAS were presence of placenta praevia, focal myometrial interruptions, placental bulging/balling, dark intra-placental bands (T2), uterine bulging, intra-placental flow voids, invasion of pelvic structures, and tortuous parametrial vessels.</p> <p>MRI examination was performed at the second or third trimester, but the exact gestational age in weeks at scan was not reported.</p>
<b>Reference standard(s)</b>	Operative findings with histology reports
<b>Duration of follow-up</b>	<p>Not reported*</p> <p>*It could be up to 27 weeks as participants had MRI examinations at the second or third trimester.</p>
<b>Sources of funding</b>	Not reported
<b>Target condition</b>	PAS
<b>Results</b>	<p>Outcome: diagnosis of PAS (accreta, increta, and percreta)*</p> <p>MRI without contrast (N=68): TP 25; FP 2; FN 19; TN 22</p> <p>2x2 table not reported by the study but calculated based on sensitivity and specificity presented</p> <p>*The study included N=24 with accreta or increta, and N=20 with percreta and did not specify whether participants with PAS had hysterectomy.</p>

FN: false negative; FP: false positive; IQR: interquartile range; MRI: magnetic resonance imaging; PAS: placenta accreta spectrum; TN: true negative; TP: true positive; 1.5-T: 1.5 Tesla

### Critical appraisal - NGA Critical appraisal - QUADAS-2

Section	Question	Answer
Patient selection: risk of bias	Could the selection of patients have introduced bias?	Low
Patient selection: applicability	Are there concerns that included patients do not match the review question?	High <i>(All participants had placenta praevia, but only 75% of participants had a previous caesarean birth)</i>
Index tests: risk of bias	Could the conduct or interpretation of the index test have introduced bias?	Low
Index tests: applicability	Are there concerns that the index test, its conduct, or interpretation differ from the review question?	Low
Reference standard: risk of bias	Could the reference standard, its conduct, or its interpretation have introduced bias?	Low
Reference standard: applicability	Is there concern that the target condition as defined by the reference standard does not match the review question?	Low
Flow and timing: risk of bias	Could the patient flow have introduced bias?	Low

QUADAS: *Quality Assessment of Diagnostic Accuracy Studies*

## El Wakeel, 2018

### Bibliographic Reference

El Wakeel A; Azab S; Abdel Rahman HM.; Role of ultrasound, Doppler, and MRI in the diagnosis of placenta accreta; Menoufia Medical Journal; 2018; vol. 31; 1023–1029

### Study details

<b>Country/ies where study was carried out</b>	Egypt
<b>Study type</b>	Prospective cohort study
<b>Study dates</b>	Not reported
<b>Inclusion criteria</b>	Pregnant women with persistent placenta praevia after 28 weeks of gestation, implantation on the lower segment of uterus, and previous uterus interventions (for example, caesarean section, myomectomy, or fractional curettage)
<b>Exclusion criteria</b>	Pregnant women with medical conditions (for example, diabetes, hypertension, or epilepsy), and metallic prosthesis (pacemakers, valves, cochlear implants, or plates and screws)
<b>Patient characteristics</b>	<p>N=20</p> <p>Mean age in years (SD): 30.9 (NR)</p> <p>Gestational age in weeks (range): 28-37</p> <p>Gestational age at diagnosis of placenta praevia (persistent placenta praevia): after 28 weeks</p> <p>Placenta praevia: N=20</p> <p>Previous uterus surgery (for example, caesarean section, myomectomy, or fractional curettage): N=19</p> <p>Parity: not reported</p> <p>BMI: not reported</p>
<b>Index test(s)</b>	<ol style="list-style-type: none"> <li>1. Grey scale ultrasound plus colour-flow Doppler ultrasound (transabdominal)</li> <li>2. MRI without contrast (1.5-T MRI without contrast)</li> </ol> <p>Grey scale ultrasound features for diagnosis of PAS were complete loss of the retroplacental sonolucent zone, irregular retroplacental sonolucent zone, thinning or disruption of the hyperechoic uterine serosa–bladder interface, presence of focal</p>

	<p>exophytic masses invading the urinary bladder, presence of abnormal placental lacunae, and decreased myometrial thickness (&lt;1 mm).</p> <p>Colour-flow doppler ultrasound features for diagnosis of PAS were diffuse or focal lacunar flow pattern, sonolucent vascular lakes with turbulent flow typified by high velocity (peak systolic velocity &gt;15 cm/s) and low resistance waveform, hypervascularity of the uterine–bladder interface with abnormal blood vessels linking the placenta to the bladder (areas of increased vascularity and continuum of lacunar flow from the placenta through the myometrial layer without intervening clear space), and markedly dilated vessels over the peripheral subplacental region.</p> <p>MRI features for diagnosis of PAS were uterine bulging, heterogeneous signal intensity within the placenta, focal interruptions in the myometrial wall, and dark intraplacental bands on T2 weighted images.</p> <p>The diagnosis of PAS was regarded as positive when any one of these radiological features was present.</p> <p>Grey scale ultrasound, colour-flow Doppler ultrasound and MRI examinations were performed between 28 and 37 weeks of gestation.</p>
<b>Reference standard(s)</b>	Operative findings with pathology report
<b>Duration of follow-up</b>	<p>Not reported*</p> <p>*It could be up to 12 weeks as participants had ultrasound and MRI examinations between 28 and 37 weeks.</p>
<b>Sources of funding</b>	Not industry funded
<b>Target condition</b>	PAS
<b>Results</b>	<p>Outcome: diagnosis of PAS (accreta, increta, and percreta)*</p> <p>Grey scale ultrasound plus colour-flow Doppler ultrasound (N=20): TP 7; FP 1; FN 4; TN 8</p> <p>MRI without contrast (N=20): TP 8; FP 0; FN 3; TN 9</p> <p>*The study included N=6 with accreta, N=2 with increta, and N=3 with percreta, and N=10 participants with PAS had hysterectomy.</p>

FN: false negative; FP: false positive; MRI: magnetic resonance imaging; NR: not reported; PAS: placenta accreta spectrum; TN: true negative; TP: true positive; 1.5-T: 1.5 Tesla



**Critical appraisal - NGA Critical appraisal - QUADAS-2**

Section	Question	Answer
Patient selection: risk of bias	Could the selection of patients have introduced bias?	Low
Patient selection: applicability	Are there concerns that included patients do not match the review question?	Low
Index tests: risk of bias	Could the conduct or interpretation of the index test have introduced bias?	Low
Index tests: applicability	Are there concerns that the index test, its conduct, or interpretation differ from the review question?	Low
Reference standard: risk of bias	Could the reference standard, its conduct, or its interpretation have introduced bias?	Low
Reference standard: applicability	Is there concern that the target condition as defined by the reference standard does not match the review question?	Low
Flow and timing: risk of bias	Could the patient flow have introduced bias?	Low

QUADAS: *Quality Assessment of Diagnostic Accuracy Studies*

**Elhawary, 2013**

**Bibliographic Reference** Elhawary, Tarek M; Dabees, Naglaa Lotfy; Youssef, Mohamed Ahmed; Diagnostic value of ultrasonography and magnetic resonance imaging in pregnant women at risk for placenta accreta.; The journal of maternal-fetal & neonatal medicine: the official journal of the European Association of Perinatal Medicine, the Federation of Asia and Oceania Perinatal Societies, the International Society of Perinatal Obstetricians; 2013; vol. 26 (no. 14); 1443-9

**Study details**

<b>Country/ies where study was carried out</b>	Egypt
<b>Study type</b>	Prospective cohort study

<b>Study dates</b>	January 2010 - June 2012
<b>Inclusion criteria</b>	Pregnant women with placenta praevia and at least one of the following risk factors: age over 35 years, grand multiparity, and previous uterine interventions (for example, caesarean birth, dilatation and curettage, and myomectomy)
<b>Exclusion criteria</b>	Not reported
<b>Patient characteristics</b>	<p>N=39</p> <p>Mean age in years (range): 32.2 (23-40)</p> <p>Gestational age in weeks at birth (range): 35-37</p> <p>Gestational age at diagnosis of placenta praevia or low-lying placenta: not reported</p> <p>Parity:</p> <p>Parity 1: N=5</p> <p>Parity 2: N=7</p> <p>Parity 3: N=19</p> <p>Parity 4: N=8</p> <p>Placenta praevia: N=18</p> <p>Low-lying placenta: N=21</p> <p>Previous caesarean birth:</p> <p>1 previous caesarean birth: N=7</p> <p>2 previous caesarean birth: N=11</p> <p>3 previous caesarean birth: N=14</p> <p>Previous uterine curettage: N=4</p> <p>Previous myomectomy: N=3</p> <p>BMI: not reported</p>
<b>Index test(s)</b>	1. Grey scale ultrasound plus colour-flow Doppler ultrasound (transabdominal and translabial)

	<p>2. MRI without contrast (1.5-T MRI without contrast)</p> <p>Ultrasound features for diagnosis of PAS were loss of the retroplacental hypoechoic clear zone, loss of the bladder wall-uterine interface, presence of placental lacunae (vascular space), and presence of hypervascularity of the interface between the bladder wall and uterine serosa on colour-flow Doppler imaging.</p> <p>MRI features for diagnosis of PAS were uterine bulging, inhomogenous intensity within the placenta, focal interruption in the myometrial wall, hypointense (dark) intraplacental bands on T2-WI, tenting of the bladder, and invasion of pelvic structures by placental tissue.</p> <p>Grey scale and colour-flow Doppler ultrasound examinations were performed at mean gestational age 29.3 weeks, and MRI scan was done 2 weeks after ultrasound scan.</p>
<b>Reference standard(s)</b>	Operative findings at caesarean section
<b>Duration of follow-up</b>	<p>Not reported*</p> <p>*It could be up to 8 weeks as participants had ultrasound scan at 29 weeks of gestation and caesarean birth between 35-37 weeks.</p>
<b>Sources of funding</b>	Not reported
<b>Target condition</b>	PAS
<b>Results</b>	<p>Outcome: diagnosis of PAS (percreta and other PAS disorders)*</p> <p>Grey scale ultrasound plus colour-flow Doppler ultrasound (N=39): TP 8; FP 3; FN 2; TN 26</p> <p>MRI without contrast (N=39)**: TP 9; FP 4; FN 1; TN 25</p> <p>*The study included N=10 with percreta and other PAS disorders but did not specify whether participants with PAS had hysterectomy.</p> <p>**2x2 table was calculated based on sensitivity and specificity presented as there was discrepancy in raw data.</p>

FN: false negative; FP: false positive; MRI: magnetic resonance imaging; PAS: placenta accreta spectrum; TN: true negative; TP: true positive; 1.5-T: 1.5 Tesla

**Critical appraisal - NGA Critical appraisal - QUADAS-2**

Section	Question	Answer
Patient selection: risk of bias	Could the selection of patients have introduced bias?	Unclear (Case-control design was avoided, but exclusion criteria not provided)
Patient selection: applicability	Are there concerns that included patients do not match the review question?	Low
Index tests: risk of bias	Could the conduct or interpretation of the index test have introduced bias?	Low
Index tests: applicability	Are there concerns that the index test, its conduct, or interpretation differ from the review question?	Low
Reference standard: risk of bias	Could the reference standard, its conduct, or its interpretation have introduced bias?	Low
Reference standard: applicability	Is there concern that the target condition as defined by the reference standard does not match the review question?	Low
Flow and timing: risk of bias	Could the patient flow have introduced bias?	Low

QUADAS: *Quality Assessment of Diagnostic Accuracy Studies*

**Faralli, 2022****Bibliographic Reference**

Faralli, Ida; Del Negro, Valentina; Chine, Alessandra; Aleksa, Natalia; Ciminello, Enrico; Piccioni, Maria Grazia; Placenta Accreta Spectrum (PAS) Disorder: Ultrasound versus Magnetic Resonance Imaging.; *Diagnostics* (Basel, Switzerland); 2022; vol. 12 (no. 11)

**Study details**

<b>Country/ies where study was carried out</b>	Italy
<b>Study type</b>	Retrospective cohort study
<b>Study dates</b>	January 2014 – January 2020
<b>Inclusion criteria</b>	Pregnant women with at least one previous caesarean section and placenta previa or low-lying placenta
<b>Exclusion criteria</b>	Not reported
<b>Patient characteristics</b>	<p>N=104</p> <p>Mean age in years (SD):  No PAS: 37(5.5)  Accreta: 38 (5.6)  Increta: 40 (7.5)  Percreta: 38 (8)</p> <p>Gestational age at diagnosis of placenta praevia: not reported</p> <p>No previous caesarean:  No PAS: N=48  Accreta: N=2  Increta: N=1  Percreta: N=0</p> <p>1 previous caesarean:  No PAS: N=24  Accreta: N=7  Increta: N=2  Percreta: N=0</p> <p>2 previous caesarean:</p>

	<p>No PAS: N=5  Accreta: N=3  Increta: N=1  Percreta: N=3</p> <p>&gt;2 previous caesarean:  No PAS: N=2  Accreta: N=2  Increta: N=3  Percreta: N=1</p> <p>Major placenta praevia  No PAS: N=45  Accreta: N=11  Increta: N=7  Percreta: N=4</p> <p>Minor placenta praevia  No PAS: N=34  Accreta: N=3  Increta: N=0  Percreta: N=0</p> <p>Previous curettage  No PAS: N=25  Accreta: N=4  Increta: N=1  Percreta: N=2</p> <p>BMI (kg/m<sup>2</sup>): not reported</p> <p>Ethnicity: not reported</p> <p>Gestational age (weeks): not reported</p>
<b>Index test(s)</b>	1. Grey scale ultrasound plus colour-flow Doppler ultrasound (transabdominal/transvaginal)

	<p>2. MRI (unspecified type*, 1.5-T MRI)</p> <p>Ultrasound and MRI examinations were performed by two experts with more than 5 years of experience in the diagnosis of PAS.</p> <p>For ultrasound images, an ultrasound score developed by a working group was used to make diagnosis of PAS, which was based on ultrasound descriptors suggested by the European Working Group on Abnormally Invasive Placenta (EW-AIP), stratified by severity score and combined with anamnestic data.</p> <p>MRI features previously described in the literature was used to make diagnosis of PAS. These included heterogenous placenta, placental bulge, dark intraplacental bands, placental ischaemic infarction, loss of retroplacental dark zone, myometrial thinning, bladder wall interruption, focal exophytic mass and abnormal vascularisation of the placental bed.</p> <p>Timing of ultrasound and MRI scans: third trimester</p> <p>Order and concurrence of grey scale ultrasound, colour-flow Doppler ultrasound and MRI was not reported.</p> <p>*The study did not specify whether MRI with or without contrast was used.</p>
<b>Reference standard(s)</b>	Operative findings with histology reports
<b>Duration of follow-up</b>	Not reported
<b>Sources of funding</b>	Not industry funded
<b>Target condition</b>	PAS
<b>Results</b>	<p>Outcome: diagnosis of PAS (accreta, increta, and percreta)*</p> <p>Grey scale ultrasound plus colour-flow Doppler ultrasound (N=104): TP 23; FP 9; FN 2; TN 70</p> <p>MRI (unspecified type) (N=104): TP 22; FP 9; FN 3; TN 70</p> <p>*The study included N=14 with accreta, N=7 with increta, and N=4 with percreta.</p>

EW-AIP: European Working Group on Abnormally Invasive Placenta; BMI: body mass index; FN: false negative; FP: false positive; MRI: magnetic resonance imaging; PAS: placenta accreta spectrum; SD: standard deviation; TN: true negative; TP: true positive; 1.5-T: 1.5 Tesla

**Critical appraisal - NGA Critical appraisal - QUADAS-2**

Section	Question	Answer
Patient selection: risk of bias	Could the selection of patients have introduced bias?	Unclear <i>(Case-control design was avoided, but exclusion criteria not provided)</i>
Patient selection: applicability	Are there concerns that included patients do not match the review question?	High <i>(All participants had placenta praevia, but only 81% of participants had previous uterine intervention)</i>
Index tests: risk of bias	Could the conduct or interpretation of the index test have introduced bias?	Low
Index tests: applicability	Are there concerns that the index test, its conduct, or interpretation differ from the review question?	Low
Reference standard: risk of bias	Could the reference standard, its conduct, or its interpretation have introduced bias?	Low
Reference standard: applicability	Is there concern that the target condition as defined by the reference standard does not match the review question?	Low
Flow and timing: risk of bias	Could the patient flow have introduced bias?	Low

UADAS: *Quality Assessment of Diagnostic Accuracy Studies*

**Fiocchi, 2020**

**Bibliographic Reference** Fiocchi, Federica; Monelli, Filippo; Besutti, Giulia; Casari, Federico; Petrella, Elisabetta; Pecchi, Annarita; Caporali, Cristian; Bertucci, Emma; Busani, Stefano; Botticelli, Laura; Facchinetti, Fabio; Torricelli, Pietro; MRI of placenta accreta: diagnostic



accuracy and impact of interventional radiology on foetal-maternal delivery outcomes in high-risk women.; The British journal of radiology; 2020; vol. 93 (no. 1114); 20200267

### Study details

<b>Country/ies where study was carried out</b>	Italy
<b>Study type</b>	Retrospective cohort study
<b>Study dates</b>	June 2013 – November 2018
<b>Inclusion criteria</b>	<p>Pregnant women at intermediate or high risk for PAS who had ultrasound evaluation.</p> <p>The following risk factors were considered: placenta previa, multiple previous caesarean sections or other surgical uterine procedures, posterior placenta, high parity defined as more than four pregnancies, maternal age over 35 years and obesity defined as a BMI over 30.</p>
<b>Exclusion criteria</b>	Not reported
<b>Patient characteristics</b>	<p>N=26</p> <p>Mean age in years (SD): 36.24 (6.16)</p> <p>Gestational age in weeks (mean; SD): 33.81 (5.36)</p> <p>Gestational age at diagnosis of placenta praevia: not reported</p> <p>Previous pregnancies (mean; SD): 3.35 (2.53)</p> <p>Parity (mean; SD): 1.54 (1.75)</p> <p>Uterine surgery (mean; SD): 1.23 (1.11)</p> <p>BMI in kg/m<sup>2</sup> (mean; SD): 23.90 (17.52)</p> <p>Placenta praevia diagnoses: not reported</p>

	Ethnicity: not reported
<b>Index test(s)</b>	<p>MRI (unspecified type*, 1.5-T MRI)</p> <p>MRI was evaluated by two radiologists, dedicated to pelvic and gynaecological MRI.</p> <p>Timing: MRI was scheduled before 38th gestational week.</p> <p>MRI features for diagnosis of PAs were uterine bulging, placental signal heterogeneity, dark intraplacental bands, hyperintense placental lacunae, interruption of the myometrium and of inner myometrial layer, placental implant on previous caesarean section uterine scar and tenting of the bladder.</p> <p>*The study did not specify whether MRI with or without contrast was used.</p>
<b>Reference standard(s)</b>	Operative findings with histology reports
<b>Duration of follow-up</b>	Not reported
<b>Sources of funding</b>	Not reported
<b>Target condition</b>	PAS
<b>Results</b>	<p>Outcome: diagnosis of PAS (accreta, increta and percreta)*</p> <p>MRI (unspecified type) (N=26): TP 13; FP 1; FN 0; TN 12</p> <p>2x2 table not reported by the study but calculated based on sensitivity and specificity presented</p> <p>*The study included N=10 with accreta/increta and N=3 with percreta.</p>

*BMI: body mass index; FN: false negative; FP: false positive; MRI: magnetic resonance imaging; PAS: placenta accreta spectrum; SD: standard deviation; TN: true negative; TP: true positive; T2-WI: 1.5-T: 1.5 Tesla*

### Critical appraisal - NGA Critical appraisal - QUADAS-2

Section	Question	Answer
Patient selection: risk of bias	Could the selection of patients have introduced bias?	Unclear (Case-control design was avoided, but exclusion criteria not provided)
Patient selection: applicability	Are there concerns that included patients do not match the review question?	Unclear (Unclear how many patients had placenta praevia and previous surgery)
Index tests: risk of bias	Could the conduct or interpretation of the index test have introduced bias?	Low
Index tests: applicability	Are there concerns that the index test, its conduct, or interpretation differ from the review question?	Low
Reference standard: risk of bias	Could the reference standard, its conduct, or its interpretation have introduced bias?	Low
Reference standard: applicability	Is there concern that the target condition as defined by the reference standard does not match the review question?	Low
Flow and timing: risk of bias	Could the patient flow have introduced bias?	Low

QUADAS: *Quality Assessment of Diagnostic Accuracy Studies*

### Fujisaki, 2017

#### Bibliographic Reference

Fujisaki, Midori; Furukawa, Seishi; Maki, Yohei; Oohashi, Masanao; Doi, Koutarou; Sameshima, Hiroshi; Maternal Morbidity in Women with Placenta Previa Managed with Prediction of Morbidly Adherent Placenta by Ultrasonography.; *Journal of pregnancy*; 2017; vol. 2017; 8318751

#### Study details

<b>Country/ies where study was carried out</b>	Japan
<b>Study type</b>	Retrospective cohort study
<b>Study dates</b>	January 2008 - February 2014
<b>Inclusion criteria</b>	Pregnant women with placenta praevia with or without risk factors for PAS
<b>Exclusion criteria</b>	Pregnant women with multi-foetal pregnancies and deliveries under 22 weeks of gestation
<b>Patient characteristics</b>	<p>N=41</p> <p>Mean age in years (SD): 34.0 (5.5)</p> <p>Mean gestational age in weeks at birth (SD): 34.1 (4.1)</p> <p>Gestational age at diagnosis of placenta praevia: after 20 weeks</p> <p>Parity:  Primipara or nulliparous: N=9  Multiparity: N=32</p> <p>Placenta praevia: N=41</p> <p>Previous caesarean birth:  1 previous caesarean birth: N=16  2 previous caesarean birth: N=3  ≥3 previous caesarean birth: N=1</p> <p>Previous uterine curettage: N=15</p> <p>BMI: not reported</p>
<b>Index test(s)</b>	Grey scale ultrasound (2D grey scale ultrasound; transabdominal or transvaginal)

	<p>Ultrasound features for diagnosis of PAS were bladder line interruption, absence of the retroplacental clear zone and placental lacunae.</p> <p>Grey scale ultrasound examination was performed after 20 weeks of gestation.</p> <p>The study did not report information on radiologists who performed ultrasound scan.</p>
<b>Reference standard(s)</b>	Post caesarean birth examination with histology
<b>Duration of follow-up</b>	<p>Not reported*</p> <p>*It could be up to 14 weeks as participants had ultrasound scan after 20 weeks of gestation and caesarean birth at 34 weeks.</p>
<b>Sources of funding</b>	Not industry funded
<b>Target condition</b>	PAS
<b>Results</b>	<p>Outcome: diagnosis of PAS (accreta, increta, and percreta)*</p> <p>Grey scale ultrasound (N=41): TP 9; FP 0; FN 5; TN 27</p> <p>2x2 table not reported by the study but calculated based on sensitivity and PPV presented</p> <p>*The study included N=5 with accreta and N=9 with increta or percreta, and N=12 participants with PAS had hysterectomy.</p>

*FN: false negative; FP: false positive; PAS: placenta accreta spectrum; PPV: positive predictive value; SD: standard deviation; TN: true negative; TP: true positive; 2D: two dimensional*

### Critical appraisal - NGA Critical appraisal - QUADAS-2

Section	Question	Answer
Patient selection: risk of bias	Could the selection of patients have introduced bias?	Low

Section	Question	Answer
Patient selection: applicability	Are there concerns that included patients do not match the review question?	High (All participants had placenta praevia, but only 85% of participants had a previous caesarean birth or uterine curettage)
Index tests: risk of bias	Could the conduct or interpretation of the index test have introduced bias?	Low
Index tests: applicability	Are there concerns that the index test, its conduct, or interpretation differ from the review question?	Low
Reference standard: risk of bias	Could the reference standard, its conduct, or its interpretation have introduced bias?	Low
Reference standard: applicability	Is there concern that the target condition as defined by the reference standard does not match the review question?	Low
Flow and timing: risk of bias	Could the patient flow have introduced bias?	Low

QUADAS: *Quality Assessment of Diagnostic Accuracy Studies*

### Gadelrab, 2022

#### Bibliographic Reference

Gadelrab, A.E.; Aboelghar, W.M.A.; Swedan, K.H.; Nasreldin, E.A.; Elshahawy, A.; Accuracy of three-dimensional multislice view Doppler in diagnosis of placenta accreta spectrum; *Italian Journal of Gynaecology and Obstetrics*; 2022; vol. 34 (no. 1); 11-18

#### Study details

Country/ies where study was carried out	Egypt
---	-------

<b>Study type</b>	Prospective cohort study
<b>Study dates</b>	December 2019 – September 2021
<b>Inclusion criteria</b>	Pregnant women with persistent low-lying anterior placenta covering the scar of previous caesarean section after 28 weeks of gestation
<b>Exclusion criteria</b>	Not reported
<b>Patient characteristics</b>	<p>N=78 (N=65 with histopathology reports)</p> <p>Mean age in years (SD): 29.6 (4.75)</p> <p>Gestational age at diagnosis of persistent placenta praevia or low-lying placenta: after 28 weeks</p> <p>Parity 1: N=15  Parity 2: N=22  Parity 3: N=17  Parity 4: N=12  Parity ≥5: N=12</p> <p>Mean BMI in kg/m<sup>2</sup> (SD): 26.37 (4.93)</p> <p>Placenta praevia or low-lying placenta: N=78</p> <p>1 previous caesarean section: N=19  2 previous caesarean sections: N=24  3 previous caesarean sections: N=20  4 previous caesarean sections: N=8  5 previous caesarean sections: N=7</p> <p>0 previous uterine curettage: N=27  1 previous uterine curettage: N=34  2 previous uterine curettage: N=14  ≥3 previous uterine curettage: N=3</p>

	<p>Ethnicity: not reported</p> <p>Gestational age: at least 28 weeks</p>
<b>Index test(s)</b>	<ol style="list-style-type: none"> <li>1. Grey scale ultrasound (2D; transabdominal)</li> <li>2. 3D multislice view Doppler ultrasound (transabdominal)</li> </ol> <p>Grey scale ultrasound features for diagnosis of PAS were absence of the retro placental sonolucent zone, disruption or thinning of hyperechoic serosa-bladder interface, irregular retro placental sonolucent zone, presence of focal exophytic masses invading the urinary bladder and abdominal placental lacunae.</p> <p>3D multislice view Doppler ultrasound features for diagnosis of PAS were disruption of the uterine serosa-bladder interface, presence of abnormal placental lacunae, presence of many vessels invading the uterine serosa-bladder interface and crowded vessels over peripheral sub-placental zone.</p> <p>Order and concurrence of Doppler and grey scale ultrasound were not reported.</p> <p>Who conducted the scans was not reported.</p> <p>Timing of scans: after 28 weeks</p> <p>This study reported diagnostic accuracy of individual feature and <math>\geq 2</math> features. However, this review only reported diagnostic accuracy data on <math>\geq 2</math> features.</p>
<b>Reference standard(s)</b>	Operative findings with histopathological results
<b>Duration of follow-up</b>	Not reported
<b>Sources of funding</b>	Not industry funded
<b>Target condition</b>	PAS
<b>Results</b>	Outcome: diagnosis of PAS (accreta, increta and percreta)



Grey scale ultrasound (N=65): TP 18; FP 3; FN 21; TN 23

3D multislice view Doppler ultrasound (N=65): TP 34; FP 1; FN 5; TN 25

2x2 table not reported by the study but calculated based on sensitivity and specificity presented

\*N=39 had PAS, but the study did not specify number of participants with each PAS disorder. N=24 had hysterectomy.

BMI: body mass index; FN: false negative; FP: false positive; PAS: placenta accreta spectrum; SD: standard deviation; TN: true negative; TP: true positive; 2D: two dimensional; 3D: three dimensional

### Critical appraisal - NGA Critical appraisal - QUADAS-2

Section	Question	Answer
Patient selection: risk of bias	Could the selection of patients have introduced bias?	Unclear (Case-control design was avoided, but exclusion criteria not provided)
Patient selection: applicability	Are there concerns that included patients do not match the review question?	Low
Index tests: risk of bias	Could the conduct or interpretation of the index test have introduced bias?	Low
Index tests: applicability	Are there concerns that the index test, its conduct, or interpretation differ from the review question?	Low
Reference standard: risk of bias	Could the reference standard, its conduct, or its interpretation have introduced bias?	Low
Reference standard: applicability	Is there concern that the target condition as defined by the reference standard does not match the review question?	Low
Flow and timing: risk of bias	Could the patient flow have introduced bias?	Low

QUADAS: Quality Assessment of Diagnostic Accuracy Studies

**Gulati, 2021**

**Bibliographic Reference** Gulati, Anshika; Anand, Rama; Aggarwal, Kiran; Agarwal, Shilpi; Tomer, Shaili; Ultrasound as a Sole Modality for Prenatal Diagnosis of Placenta Accreta Spectrum: Potentialities and Pitfalls.; The Indian journal of radiology & imaging; 2021; vol. 31 (no. 3); 527-538

**Study details**

<b>Country/ies where study was carried out</b>	India
<b>Study type</b>	Prospective cohort study
<b>Study dates</b>	November 2015 – March 2017
<b>Inclusion criteria</b>	Pregnant women with placenta praevia, period of gestation 24 weeks or over and history of at least one prior caesarean section
<b>Exclusion criteria</b>	Pregnant women with without low-lying placenta at an initial scan or on subsequent scans due to placental migration
<b>Patient characteristics</b>	<p>N=50</p> <p>Gestational age: 24 weeks or above</p> <p>Age &lt;25: N=15  Age 25-29: N=20  Age 30-34 N=7  Age &gt;34: N=8</p> <p>Gestational age at diagnosis of placenta praevia or low-lying placenta: not reported*</p> <p>Gravidity &lt;3: N=20  Gravidity 3-6: N=29  Gravidity &gt;6: N=1</p>

	<p>Placenta praevia: N=50</p> <p>1 previous caesarean section: N=34 2 previous caesarean sections: N=11 3 or more previous caesarean sections: N=5</p> <p>BMI (kg/m<sup>2</sup>): not reported</p> <p>Ethnicity: not reported</p> <p>*It could be 24 weeks or over as the study included participants with placenta praevia with period of gestation 24 weeks or over</p>
<b>Index test(s)</b>	<p>Grey scale ultrasound plus colour-flow Doppler ultrasound (transabdominal)</p> <p>Grey scale ultrasound features for diagnosis of PAS were disruption of uterine serosa-bladder wall interface, intraplacental lacunae, absence of retroplacental clear zone, focal exophytic masses, and myometrial thinning (&lt;1 mm).</p> <p>Colour-flow Doppler ultrasound features for diagnosis of PAS were hypervascularity of uterine serosa-bladder wall interface, sonolucent vascular lacunae with turbulent flow typified by high velocity and reduced resistance waveform, reduced impedance flow in vascular branches coursing between the myometrium and placenta, and significantly dilated vessels over the peripheral subplacental zone.</p> <p>Grey scale ultrasound was performed before Doppler ultrasound.</p> <p>For participants presenting early in the third trimester, a follow-up scan was conducted around 32 weeks to investigate changes in placental localisation, after which placental migration is unlikely. A single scan was performed for participants presenting late in the third trimester.</p> <p>For some participants, MRI findings were also recorded based on the treating obstetrician's advice, but the study did not report diagnostic accuracy of MRI.</p>
<b>Reference standard(s)</b>	<p>Histopathological/per-operative findings.</p>
<b>Duration of follow-up</b>	<p>Not reported</p>

<b>Sources of funding</b>	Not industry funded
<b>Target condition</b>	PAS
<b>Results</b>	<p>Outcome: diagnosis of PAS (accreta, increta, and percreta)*</p> <p>Grey scale ultrasound plus colour-flow Doppler ultrasound (N=50): TP 18; FP 4; FN 1; TN 27</p> <p>*The study included N=5 with accreta, N=2 with increta, and N=12 with percreta, and N=16 participants with PAS had hysterectomy.</p>

*BMI: body mass index; FN: false negative; FP: false positive; MRI: magnetic resonance imaging; PAS: placenta accreta spectrum; TN: true negative; TP: true positive*

### Critical appraisal - NGA Critical appraisal - QUADAS-2

Section	Question	Answer
Patient selection: risk of bias	Could the selection of patients have introduced bias?	Low
Patient selection: applicability	Are there concerns that included patients do not match the review question?	Low
Index tests: risk of bias	Could the conduct or interpretation of the index test have introduced bias?	Low
Index tests: applicability	Are there concerns that the index test, its conduct, or interpretation differ from the review question?	Low
Reference standard: risk of bias	Could the reference standard, its conduct, or its interpretation have introduced bias?	Low
Reference standard: applicability	Is there concern that the target condition as defined by the reference standard does not match the review question?	Low
Flow and timing: risk of bias	Could the patient flow have introduced bias?	Low

*QUADAS: Quality Assessment of Diagnostic Accuracy Studies*

### Haba, 2022

**Bibliographic Reference** Haba, Raluca Maria; Pristavu, Anda Ioana; Cobzeanu, Maria-Luiza; Carauleanu, Alexandru; Sadiye Scripcariu, Ioana; Vasilache, Ingrid Andrada; Minciuna, Dorina Adelina; Negru, Dragos; Socolov, Demetra Gabriela; Predicting Placenta Accreta Spectrum Disorders in a Cohort of Pregnant Patients in the North-East Region of Romania-Diagnostic Accuracy of Ultrasound and Magnetic Resonance Imaging.; *Diagnostics* (Basel, Switzerland); 2022; vol. 12 (no. 9)

### Study details

<b>Country/ies where study was carried out</b>	Romania
<b>Study type</b>	Prospective cohort study
<b>Study dates</b>	January 2019 - November 2021
<b>Inclusion criteria</b>	Pregnant women aged over 18 years with placenta praevia and at least one previous caesarean birth, who underwent both ultrasound and MRI investigations for suspicion of PAS
<b>Exclusion criteria</b>	Ectopic pregnancies and loss of pregnancy during first and the second trimester, and women who failed to attend all the study visits, to provide informed consent, and did not have ultrasound and MRI examinations
<b>Patient characteristics</b>	<p>N=39 (PAS: N=26; No PAS: N=13)</p> <p>Mean age in years (SD):  PAS: 32.0 (3.7)  No PAS: 31.1 (4.2)</p> <p>Mean gestational age in weeks at birth (SD):  PAS: 35.7 (2.1)  No PAS: 36.2 (1.2)</p> <p>Gestational age at diagnosis of placenta praevia: not reported</p> <p>Mean parity (SD):  PAS: 2.9 (2.1)</p>

	<p>No PAS: 2.2 (0.7)</p> <p>Mean BMI in kg/m<sup>2</sup> (SD):  PAS: 30.3 (3.5)  No PAS: 28.1 (1.6)</p> <p>Placenta praevia: N=39</p> <p>Number of previous caesarean birth; mean (SD):  PAS: 2.3 (1.5)  No PAS: 1.3 (0.6)</p>
<b>Index test(s)</b>	<ol style="list-style-type: none"> <li>1. Grey scale ultrasound plus power Doppler ultrasound (transabdominal and transvaginal)</li> <li>2. MRI without contrast (1.5-T MRI without contrast)</li> </ol> <p>Ultrasound examinations were performed by a maternal-foetal specialist, but the study did not specify who performed MRI examinations.</p> <p>Ultrasound features for diagnosis of PAS were intra-placental lacunae, loss of the retroplacental hypoechoic zone, placental bulging, myometrial thinning less than 1 mm, bladder wall interruption, bridging vessels, and the hypervascularity of the uterovesical or retroplacental space.</p> <p>MRI features for diagnosis of PAS were intra-placental dark T2 bands, loss of retroplacental hypointense line on T2 images, placental bulging, myometrial thinning, bladder wall interruption, focal exophytic placental mass, and abnormal vascularization of the placental bed.</p> <p>This study reported diagnostic accuracy of individual feature, and <math>\geq 3</math> features. However, this review only reported diagnostic accuracy data on <math>\geq 3</math> features.</p> <p>MRI examination was performed between 28 and 35 weeks of gestation, but timing of ultrasound scans was not reported.</p>
<b>Reference standard(s)</b>	Post caesarean birth examination with histology
<b>Duration of follow-up</b>	Not reported*

	*It could be up to 8 weeks as participants had MRI examination between 28 and 35 weeks of gestation and caesarean birth at 35 and 36 weeks.
<b>Sources of funding</b>	Not industry funded
<b>Target condition</b>	PAS
<b>Results</b>	<p>Outcome: diagnosis of PAS (accreta, increta, and percreta)*</p> <p>Grey scale ultrasound plus power Doppler ultrasound (N=39): TP 22; FP 1; FN 4; TN 12</p> <p>MRI without contrast (N=39): TP 24; FP 5; FN 2; TN 8</p> <p>*N=26 had PAS, but the study did not specify number of participants with each PAS disorder. All participants with PAS (N=26) had hysterectomy.</p>

*BMI: body mass index; FN: false negative; FP: false positive; MRI: magnetic resonance imaging; PAS: placenta accreta spectrum; SD: standard deviation; TN: true negative; TP: true positive; 1.5-T: 1.5 Tesla*

### Critical appraisal - NGA Critical appraisal - QUADAS-2

Section	Question	Answer
Patient selection: risk of bias	Could the selection of patients have introduced bias?	Low
Patient selection: applicability	Are there concerns that included patients do not match the review question?	Low
Index tests: risk of bias	Could the conduct or interpretation of the index test have introduced bias?	Low
Index tests: applicability	Are there concerns that the index test, its conduct, or interpretation differ from the review question?	Low
Reference standard: risk of bias	Could the reference standard, its conduct, or its interpretation have introduced bias?	Low
Reference standard: applicability	Is there concern that the target condition as defined by the reference standard does not match the review question?	Low

Section	Question	Answer
Flow and timing: risk of bias	Could the patient flow have introduced bias?	Low

*QUADAS: Quality Assessment of Diagnostic Accuracy Studies*

**Haidar, 2017**

**Bibliographic Reference** Haidar, Ziad A; Papanna, Ramesha; Sibai, Baha M; Tatevian, Nina; Viteri, Oscar A; Vowels, Patricia C; Blackwell, Sean C; Moise, Kenneth J Jr; Can 3-dimensional power Doppler indices improve the prenatal diagnosis of a potentially morbidly adherent placenta in patients with placenta previa?.; American journal of obstetrics and gynecology; 2017; vol. 217 (no. 2); 202e1-202e13

**Study details**

<b>Country/ies where study was carried out</b>	USA
<b>Study type</b>	Prospective cohort study
<b>Study dates</b>	October 2014 - December 2015
<b>Inclusion criteria</b>	Pregnant women who were referred to the ultrasound for the evaluation of PAS and placenta praevia between 28 and 32 weeks of gestation
<b>Exclusion criteria</b>	Pregnant women with foetal abnormality and multiple gestations
<b>Patient characteristics</b>	N=50 (PAS: N=23; No PAS: N=27) Mean age in years (SD): PAS: 32.4 (5.5) No PAS: 31.0 (6.0)



	<p>Mean gestational age in weeks at birth (SD): 31.6 (5.8)</p> <p>Gestational age in weeks at diagnosis of placenta praevia (range): 28-32</p> <p>Multiparity: N=44</p> <p>Mean BMI in kg/m<sup>2</sup> at scan (SD):  PAS: 32.2 (5.9)  No PAS: 29.9 (6.5)</p> <p>Placenta praevia: N=50</p> <p>Previous caesarean birth: N=35</p> <p>Number of previous caesarean birth; median (range):  PAS: 2 (0-5)  No PAS: 0 (0-4)</p> <p>Previous myomectomy: N=1</p> <p>Previous dilatation and curettage: N=2</p> <p>Ethnicity:  African American: N=15  White: N=11  Hispanic: N=14  Other: N=10</p>
<b>Index test(s)</b>	<p>Grey scale ultrasound (2D; transabdominal and transvaginal)</p> <p>Ultrasound examination was performed by certified sonographers under the supervision of maternal-foetal medicine specialists.</p> <p>The diagnosis of PAS was regarded as positive when at least one of three grey scale ultrasound features (placental lacunae, loss of sonolucency, and abnormal uterine serosa-bladder interface) was present.</p> <p>The study reported diagnostic accuracy of individual Doppler ultrasound features, but this review did not report the data on these individual features.</p>

	Grey scale ultrasound examination was performed at mean (SD) gestational age 30.7 (1.8) and 29.7 (5.5) weeks in participants with PAS and without PAS, respectively.
<b>Reference standard(s)</b>	Operative findings with histology reports
<b>Duration of follow-up</b>	Not reported* *It could be up to 2 weeks as participants had ultrasound scan at 29.7 or 30.7 weeks of gestation and caesarean birth at 31.6 weeks.
<b>Sources of funding</b>	Not reported
<b>Target condition</b>	PAS
<b>Results</b>	Outcome: diagnosis of PAS (accreta, increta, and percreta)* Grey scale ultrasound (N=50): TP 19; FP 3; FN 4; TN 24 2x2 table not reported by the study but calculated based on sensitivity and specificity presented *The study included N=7 with accreta, N=6 with increta, and N=10 with percreta, and all participants (N=23) with PAS had hysterectomy.

*BMI: body mass index; FN: false negative; FP: false positive; PAS: placenta accreta spectrum; SD: standard deviation; TN: true negative; TP: true positive; 2D: two dimensional*

### Critical appraisal - NGA Critical appraisal - QUADAS-2

Section	Question	Answer
Patient selection: risk of bias	Could the selection of patients have introduced bias?	Low
Patient selection: applicability	Are there concerns that included patients do not match the review question?	High (All participants had placenta praevia, but only 76% of

Section	Question	Answer
		<i>participants had a previous caesarean birth or uterine intervention)</i>
Index tests: risk of bias	Could the conduct or interpretation of the index test have introduced bias?	Low
Index tests: applicability	Are there concerns that the index test, its conduct, or interpretation differ from the review question?	Low
Reference standard: risk of bias	Could the reference standard, its conduct, or its interpretation have introduced bias?	Low
Reference standard: applicability	Is there concern that the target condition as defined by the reference standard does not match the review question?	Low
Flow and timing: risk of bias	Could the patient flow have introduced bias?	Low

QUADAS: *Quality Assessment of Diagnostic Accuracy Studies*

## Hashem, 2016

**Bibliographic Reference** Hashem, L.B.; Salem, D.S.; Hamed, S.T.; Hussein, A.M.; Role of MRI versus ultrasound in the assessment of placental abnormalities and diseases; Egyptian Journal of Radiology and Nuclear Medicine; 2016; vol. 47 (no. 2); 641-658

## Study details

<b>Country/ies where study was carried out</b>	Egypt
<b>Study type</b>	Prospective cohort study
<b>Study dates</b>	Not reported

<b>Inclusion criteria</b>	Pregnant women aged 20 to 40 years with abnormal placental location and/or implantation at antepartum ultrasound
<b>Exclusion criteria</b>	Not reported
<b>Patient characteristics</b>	<p>N=39</p> <p>Mean age in years (SD): 30.7 (NR)</p> <p>Gestational age in weeks (range): 25-37</p> <p>Gestational age at diagnosis of placenta praevia: not reported</p> <p>Placenta praevia: N=38</p> <p>Low-lying placenta: N=1</p> <p>Previous uterine surgery: N=38</p> <p>Parity: not reported</p> <p>BMI: not reported</p>
<b>Index test(s)</b>	<ol style="list-style-type: none"> <li>1. Grey scale ultrasound plus colour-flow or power Doppler ultrasound (transabdominal, transvaginal, and translabial)</li> <li>2. MRI without contrast (1.5-T MRI without contrast)</li> </ol> <p>Ultrasound examinations were conducted by qualified physicians of Obstetrics and Gynaecology and/or Radiology, and MRI examination was conducted by two qualified consultants of Radiology.</p> <p>Ultrasound features of diagnosis of PAS were abnormal clear space, loss of bladder uterine interface, placental lacunae, hypervascularity on colour Doppler, and decreased myometrial thickness.</p> <p>MRI features for diagnosis of PAS were uterine bulging, heterogeneous signal intensity, dark intraplacental bands, focal interruption in the myometrium, and invasion of surrounding.</p> <p>Ultrasound and MRI examinations were performed between 25 and 37 weeks of gestation.</p>
<b>Reference standard(s)</b>	Operative findings at caesarean section with or without pathological reports

<b>Duration of follow-up</b>	Not reported
<b>Sources of funding</b>	Not reported
<b>Target condition</b>	PAS
<b>Results</b>	<p>Outcome: diagnosis of PAS (accreta, increta, and percreta)*</p> <p>Grey scale ultrasound plus colour-flow or power Doppler ultrasound (N=39): TP 17; FP 3; FN 8; TN 11</p> <p>MRI without contrast (N=39): TP 20; FP 2; FN 5; TN 12</p> <p>*The study included N=9 with accreta, N=7 with increta, and N=9 with percreta, and N=23 participants with PAS had hysterectomy.</p>

FN: false negative; FP: false positive; MRI: magnetic resonance imaging; NR: not reported; PAS: placenta accreta spectrum; TN: true negative; TP: true positive; 1.5-T: 1.5 Tesla

### Critical appraisal - NGA Critical appraisal - QUADAS-2

Section	Question	Answer
Patient selection: risk of bias	Could the selection of patients have introduced bias?	Unclear (Case-control design was avoided, but exclusion criteria not provided)
Patient selection: applicability	Are there concerns that included patients do not match the review question?	Low
Index tests: risk of bias	Could the conduct or interpretation of the index test have introduced bias?	Low
Index tests: applicability	Are there concerns that the index test, its conduct, or interpretation differ from the review question?	Low
Reference standard: risk of bias	Could the reference standard, its conduct, or its interpretation have introduced bias?	Low

Section	Question	Answer
Reference standard: applicability	Is there concern that the target condition as defined by the reference standard does not match the review question?	Low
Flow and timing: risk of bias	Could the patient flow have introduced bias?	Low

QUADAS: *Quality Assessment of Diagnostic Accuracy Studies*

### Hussein, 2022

**Bibliographic Reference** Hussein, A M; Elbarmelgy, R A; Elbarmelgy, R M; Thabet, M M; Jauniaux, E; Prospective evaluation of impact of post-Cesarean section uterine scarring in perinatal diagnosis of placenta accreta spectrum disorder.; *Ultrasound in obstetrics & gynecology : the official journal of the International Society of Ultrasound in Obstetrics and Gynecology*; 2022; vol. 59 (no. 4); 474-482

### Study details

<b>Country/ies where study was carried out</b>	Egypt
<b>Study type</b>	Prospective cohort study
<b>Study dates</b>	January 2019 - December 2020
<b>Inclusion criteria</b>	Women presented with a singleton pregnancy at 32-37 weeks of gestation who had two or more previous caesarean births and were diagnosed prenatally with a placenta praevia or anterior low-lying placenta with ultrasound signs of PAS
<b>Exclusion criteria</b>	Pregnant women requiring emergency delivery before 32 weeks of gestation or women with a multiple pregnancy
<b>Patient characteristics</b>	N=84 Median age in years (IQR): 32.0 (28.5-34.0)

	<p>Median gestational age in weeks at birth (IQR): 36.2 (36.0-37.0)</p> <p>Gestational age in weeks at diagnosis of placenta or low-lying placenta (range): 32-37</p> <p>Median parity (IQR): 3.0 (2.0-4.0)</p> <p>Placenta praevia: N=76</p> <p>Low-lying placenta: N=8</p> <p>Number of previous caesarean birth; median (IQR): 3.0 (2.0-4.0)</p> <p>BMI: not reported</p>
<b>Index test(s)</b>	<p>Grey scale ultrasound plus colour-flow Doppler ultrasound (transabdominal and transvaginal)</p> <p>Grey scale ultrasound features for diagnosis of PAS were loss of clear zone, myometrial thinning, bladder wall interruption, presence of placental lacunae, placental bulge and focal exophytic mass.</p> <p>Doppler ultrasound features for diagnosis of PAS were uterovesical hypervascularity, subplacental hypervascularity, placental lacunae feeder vessels and bridging vessels.</p> <p>Grey scale and colour-flow Doppler ultrasound examinations were performed within 48 hours before surgery, so the timing of scan could be at 36 weeks of gestation.</p> <p>The study did not specify who performed ultrasound examinations.</p>
<b>Reference standard(s)</b>	Operative findings with histology reports
<b>Duration of follow-up</b>	<p>N/A*</p> <p>*Participants had ultrasound examinations within 48 hours before surgery</p>
<b>Sources of funding</b>	Not reported
<b>Target condition</b>	PAS

<b>Results</b>	<p>Outcome: diagnosis of PAS (accreta and increta)*</p> <p>Grey scale ultrasound plus colour-flow Doppler ultrasound (N=84): TP 41; FP 1; FN 10; TN 32</p> <p>*The study included N=6 with accreta and N=45 with increta, and N=48 with PAS and N=16 without PAS had hysterectomy.</p>
----------------	--

FN: false negative; FP: false positive; IQR: interquartile range; PAS: placenta accreta spectrum; TN: true negative; TP: true positive

### Critical appraisal - NGA Critical appraisal - QUADAS-2

Section	Question	Answer
Patient selection: risk of bias	Could the selection of patients have introduced bias?	Low
Patient selection: applicability	Are there concerns that included patients do not match the review question?	Low
Index tests: risk of bias	Could the conduct or interpretation of the index test have introduced bias?	Unclear <i>(No information about whether index tests were interpreted without knowledge of the results of the reference standard)</i>
Index tests: applicability	Are there concerns that the index test, its conduct, or interpretation differ from the review question?	Low
Reference standard: risk of bias	Could the reference standard, its conduct, or its interpretation have introduced bias?	Low
Reference standard: applicability	Is there concern that the target condition as defined by the reference standard does not match the review question?	Low
Flow and timing: risk of bias	Could the patient flow have introduced bias?	Low

QUADAS: *Quality Assessment of Diagnostic Accuracy Studies*



## Khalaf, 2019

**Bibliographic Reference** Khalaf, Lamiaa M R; Zeid, Hazem Abou; Othman, Essam Rashad; Reliability of Magnetic Resonance Imaging in diagnosis and assessment the depth of invasion of placental accreta in high risk gravid women.; Clinical imaging; 2019; vol. 58; 5-11

### Study details

<b>Country/ies where study was carried out</b>	Egypt
<b>Study type</b>	Prospective cohort study
<b>Study dates</b>	January 2016 - December 2017
<b>Inclusion criteria</b>	Pregnant women with placenta praevia and with or without multiple previous caesarean birth and other minor risk factors such as multiparity and advanced maternal age
<b>Exclusion criteria</b>	Pregnant women who did not have surgical and histopathological reports and had contraindications for MRI rests (that is, having an artificial cardiac pacemaker or metallic prosthesis or severe claustrophobia)
<b>Patient characteristics</b>	<p>N=58</p> <p>Mean age in years (SD): 31.6 (4.8)</p> <p>Gestational age: second or third trimester</p> <p>Gestational age at diagnosis of placenta praevia or low-lying placenta: not reported</p> <p>Mean parity (SD): 3.3 (1.3)</p> <p>Parity <math>\geq</math>4: N=22</p> <p>Placenta praevia or low-lying placenta: N=44</p> <p>Low-lying placenta: 14</p> <p><math>\geq</math>2 previous caesarean birth: N=43</p>

	<p>BMI: not reported</p> <p>Participants with PAS or suspicious PAS findings at initial ultrasound examination were included in this study, but timing of ultrasound scan was not reported.</p>
<b>Index test(s)</b>	<p>MRI without contrast (1.5-T MRI without contrast)</p> <p>MRI examination was performed by two experienced radiologists (8 and 12 years of experience in MRI of the female pelvis).</p> <p>MRI features for diagnosis of PAS were focal myometrial interruption, placental heterogeneity, dark intra-placental bands, focal uterine bulge and invasion to the surrounding organs.</p> <p>Timing of MRI scan was not reported.</p> <p>This review did not report diagnostic accuracy of individual feature although the study reported such data.</p>
<b>Reference standard(s)</b>	Operative findings with or without histopathological reports
<b>Duration of follow-up</b>	Not reported
<b>Sources of funding</b>	Not industry funded
<b>Target condition</b>	PAS
<b>Results</b>	<p>Outcome: diagnosis of PAS (accreta, increta, and percreta)*</p> <p>MRI without contrast (N=58): TP 46; FP 3; FN 0; TN 9</p> <p>2x2 table not reported by the study but calculated based on sensitivity and specificity presented</p> <p>*The study included N=15 with accreta, N=17 with increta, N=13 with percreta and N=1 with ectopic pregnancy, and N=23 participants with PAS had hysterectomy.</p>

*FN: false negative; FP: false positive; MRI: magnetic resonance imaging; PAS: placenta accreta spectrum; SD: standard deviation; TN: true negative; TP: true positive; 1.5-T: 1.5 Tesla*

**Critical appraisal - NGA Critical appraisal - QUADAS-2**

Section	Question	Answer
Patient selection: risk of bias	Could the selection of patients have introduced bias?	Low
Patient selection: applicability	Are there concerns that included patients do not match the review question?	Unclear <i>(All participants had placenta praevia or low-lying placenta, but no information on whether all participants had a previous caesarean section or uterine intervention)</i>
Index tests: risk of bias	Could the conduct or interpretation of the index test have introduced bias?	Low
Index tests: applicability	Are there concerns that the index test, its conduct, or interpretation differ from the review question?	Low
Reference standard: risk of bias	Could the reference standard, its conduct, or its interpretation have introduced bias?	Low
Reference standard: applicability	Is there concern that the target condition as defined by the reference standard does not match the review question?	Low
Flow and timing: risk of bias	Could the patient flow have introduced bias?	Low

QUADAS: *Quality Assessment of Diagnostic Accuracy Studies*

**Lim, 2011**

**Bibliographic Reference**

Lim, Philip S; Greenberg, Marianne; Edelson, Mitchell I; Bell, Karen A; Edmonds, Pamela R; Mackey, Amy M; Utility of ultrasound and MRI in prenatal diagnosis of placenta accreta: a pilot study.; AJR. American journal of roentgenology; 2011; vol. 197 (no. 6); 1506-13

**Study details**

<b>Country/ies where study was carried out</b>	USA
<b>Study type</b>	Retrospective cohort study
<b>Study dates</b>	January 2009 - November 2010
<b>Inclusion criteria</b>	Pregnant women with risk factors for PAS who underwent both ultrasound and MRI examinations
<b>Exclusion criteria</b>	Pregnant women without MRI imaging
<b>Patient characteristics</b>	<p>N=13</p> <p>Mean age in years (range): 33 (25-42)</p> <p>Gestational age in weeks at birth (range): 30-39</p> <p>Gestational age in weeks at diagnosis of placenta praevia (range): 18-37</p> <p>Parity:</p> <p>Parity 0 (nulliparous): N=1</p> <p>Parity 1: N=3</p> <p>Parity 2: N=5</p> <p>Parity 3: N=4</p> <p>Placenta praevia: N=11</p> <p>Previous caesarean birth:</p> <p>1 previous caesarean birth: N=6</p> <p>2 previous caesarean birth: N=3</p> <p>3 previous caesarean birth: N=2</p> <p>Previous dilatation and curettage: N=1</p> <p>BMI: not reported</p>

<b>Index test(s)</b>	<ol style="list-style-type: none"> <li>1. Grey scale ultrasound (2D) plus colour-flow and power Doppler ultrasounds (transabdominal)</li> <li>2. MRI without contrast (1.5-T MRI without contrast)</li> </ol> <p>Ultrasound scans were conducted by registered sonographers and the findings were interpreted by maternal-foetal medicine obstetricians, and MRI examination was conducted by a radiologist with 10 years of experience in body MRI.</p> <p>Ultrasound features for diagnosis of PAS were loss of echolucent area between the placenta and the uterus or urinary bladder, a mass extending into the urinary bladder, and lacunae in the placenta.</p> <p>MRI features for diagnosis of PAS were intraplacental bands of low signal intensity on T-weighted images, placenta praevia, heterogeneous signal intensity in the placenta, uterine bulging, myometrial thinning less than 1 mm thick, focal interruption in the myometrial wall, tenting of the urinary bladder, and invasion of placental tissue outside the uterus.</p> <p>The diagnosis of PAS was regarded as positive when any one of these radiological features was present.</p> <p>Grey scale plus colour-flow and power Doppler ultrasound examinations were performed between 18 and 37 weeks of gestation, and MRI was conducted between 24 and 37 weeks.</p>
<b>Reference standard(s)</b>	Operative findings with histology reports
<b>Duration of follow-up</b>	<p>Not reported*</p> <p>*It could be up to 21 weeks as participants had ultrasound scan from 18 weeks and surgery between 30 and 39 weeks.</p>
<b>Sources of funding</b>	Not reported
<b>Target condition</b>	PAS
<b>Results</b>	<p>Outcome: diagnosis of PAS (accreta, increta, and percreta)*</p> <p>Grey scale ultrasound (2D) plus colour-flow and power Doppler ultrasounds (N=13): TP 6; FP 2; FN 3; TN 2</p> <p>MRI without contrast (N=13): TP 7; FP 1; FN 2; TN 3</p>

\*The study included N=5 with accreta, N=3 with increta, and N=1 with percreta, and all participants with PAS (N=9) had hysterectomy.

FN: false negative; FP: false positive; MRI: magnetic resonance imaging; PAS: placenta accreta spectrum; TN: true negative; TP: true positive; 2D: two dimensional; 1.5-T: 1.5 Tesla

### Critical appraisal - NGA Critical appraisal - QUADAS-2

Section	Question	Answer
Patient selection: risk of bias	Could the selection of patients have introduced bias?	Low
Patient selection: applicability	Are there concerns that included patients do not match the review question?	High (92% of participants had a previous caesarean birth or uterine curettage, but only 84% of participants had placenta praevia.)
Index tests: risk of bias	Could the conduct or interpretation of the index test have introduced bias?	Low
Index tests: applicability	Are there concerns that the index test, its conduct, or interpretation differ from the review question?	Low
Reference standard: risk of bias	Could the reference standard, its conduct, or its interpretation have introduced bias?	Low
Reference standard: applicability	Is there concern that the target condition as defined by the reference standard does not match the review question?	Low
Flow and timing: risk of bias	Could the patient flow have introduced bias?	Low

QUADAS: Quality Assessment of Diagnostic Accuracy Studies

### Maher, 2013

**Bibliographic Reference** Maher, Mohammad A; Abdelaziz, Ahmed; Bazeed, Mohamed F; Diagnostic accuracy of ultrasound and MRI in the prenatal diagnosis of placenta accreta.; Acta obstetrica et gynecologica Scandinavica; 2013; vol. 92 (no. 9); 1017-22

### Study details

<b>Country/ies where study was carried out</b>	Saudi Arabia
<b>Study type</b>	Prospective cohort study
<b>Study dates</b>	August 2008 - September 2011
<b>Inclusion criteria</b>	Pregnant women with low-lying placenta confirmed by ultrasound at 28 weeks of gestation
<b>Exclusion criteria</b>	Pregnant women without full delivery data and those who delivered outside the study hospital
<b>Patient characteristics</b>	<p>N=63 (Whole cohort N=577)*</p> <p>Mean age in years (range): 35.5 (29-47)</p> <p>Mean gestational age in weeks (range): 30.3 (28-36)</p> <p>Gestational age in weeks at diagnosis of placenta praevia: 28</p> <p>Mean parity (range): 6.0 (3-11)</p> <p>Placenta praevia or low-lying placenta: N=63</p> <p>Previous caesarean birth:  1 previous caesarean birth: N=4  ≥2 previous caesarean birth: N=59</p> <p>Previous uterine curettage: N=24</p> <p>Previous myomectomy: N=3</p>

	<p>BMI: not reported</p> <p>*In this review N=20 participants with suspicious PAS findings on ultrasound at 30 weeks were included and underwent MRI examinations. The data on ultrasound group were not reported because the study did not specify whether this cohort (N=514) had previous caesarean birth or uterine intervention.</p>
<b>Index test(s)</b>	<p>MRI without contrast (1.5-T MRI without contrast)</p> <p>MRI examination was performed by a radiologist with 10 years of experience in placental MRI.</p> <p>MRI features for diagnosis of PAS were uterine bulge, heterogeneous signal intensity in the placenta with increased vascularity, focal interruptions of myometrium wall and placental tissue extending through the myometrium with invasion of surrounding structures, and dark intraplacental bands on T2-weighted images.</p> <p>Timing of MRI scan was not reported.</p>
<b>Reference standard(s)</b>	Operative findings with or without histopathological reports
<b>Duration of follow-up</b>	Not reported
<b>Sources of funding</b>	Not reported
<b>Target condition</b>	PAS
<b>Results</b>	<p>Outcome: diagnosis of PAS (accreta, increta, and percreta)*</p> <p>MRI without contrast (N=20): TP 6; FP 3; FN 1; TN 10</p> <p>*The study did not specify number of participants with each PAS disorder in MRI cohort. All participants with PAS (N=7) had hysterectomy.</p>

*FN: false negative; FP: false positive; MRI: magnetic resonance imaging; PAS: placenta accreta spectrum; TN: true negative; TP: true positive; 1.5-T: 1.5 Tesla*

### Critical appraisal - NGA Critical appraisal - QUADAS-2



Section	Question	Answer
Patient selection: risk of bias	Could the selection of patients have introduced bias?	Low
Patient selection: applicability	Are there concerns that included patients do not match the review question?	Low
Index tests: risk of bias	Could the conduct or interpretation of the index test have introduced bias?	Low
Index tests: applicability	Are there concerns that the index test, its conduct, or interpretation differ from the review question?	Low
Reference standard: risk of bias	Could the reference standard, its conduct, or its interpretation have introduced bias?	Low
Reference standard: applicability	Is there concern that the target condition as defined by the reference standard does not match the review question?	Low
Flow and timing: risk of bias	Could the patient flow have introduced bias?	Low

QUADAS: *Quality Assessment of Diagnostic Accuracy Studies*

### Mansour, 2011

**Bibliographic Reference** Mansour, S.M.; Elkhyat, W.M.; Placenta previa - Accreta: Do we need MR imaging?; Egyptian Journal of Radiology and Nuclear Medicine; 2011; vol. 42 (no. 34); 433-442

### Study details

<b>Country/ies where study was carried out</b>	Egypt
<b>Study type</b>	Prospective cohort study
<b>Study dates</b>	January 2010 - June 2011

<b>Inclusion criteria</b>	Pregnant women with placenta praevia and either one or all of the following risk factors for PAS: maternal age over 35 years, grand multiparity, and previous uterine interventions (for example, caesarean birth, dilatation and curettage, and myomectomy)
<b>Exclusion criteria</b>	Participants without ultrasound imaging conducted by the study personnel
<b>Patient characteristics</b>	<p>N=35*</p> <p>Mean age in years (SD): 32 (NR)</p> <p>Gestational age at birth: at 36 or after 36 weeks</p> <p>Gestational age at diagnosis of placenta praevia: not reported</p> <p>Placenta praevia: N=35</p> <p>Previous uterine surgery: N=28</p> <p>Parity: not reported</p> <p>BMI: not reported</p> <p>*N=36 was recruited but N=1 without ultrasound imaging conducted by the study personnel was not included in final analysis.</p>
<b>Index test(s)</b>	<ol style="list-style-type: none"> <li>1. Grey scale ultrasound plus colour-flow Doppler ultrasound (transabdominal and translabial)</li> <li>2. MRI without contrast (1.5-T MRI without contrast)</li> </ol> <p>Initial ultrasound examination was conducted by a qualified consultant (a lecturer with 10 years' experience) of Obstetrics and Gynaecology.</p> <p>Second look ultrasound and MRI analysis were conducted by a qualified consultant (a lecturer with 9 years' experience) of Radiology.</p> <p>Ultrasound features for diagnosis of PAS were loss of the retroplacental hypoechoic clear zone, presence of placental lacunae (vascular spaces), loss of the bladder wall-uterine interface, and presence of hypervascularity of the interface between the bladder wall and the uterine serosa on colour-flow Doppler.</p>

	<p>MRI features for diagnosis of PAS were placenta praevia, uterine bulging, dark intraplacental bands on T2-WI, heterogeneous signal intensity within the placenta, tenting of the bladder, focal interruptions in the myometrial wall, direct visualisation of the invasion of pelvic structures by placental tissue.</p> <p>The study did not specify timing of ultrasound and MRI scans, but it stated that participants were subjected to ultrasound and MRI prior to elective delivery (<math>\geq 36</math> weeks).</p>
<b>Reference standard(s)</b>	Operative findings at caesarean section without histology reports
<b>Duration of follow-up</b>	Not reported
<b>Sources of funding</b>	Not reported
<b>Target condition</b>	PAS
<b>Results</b>	<p>Outcome: diagnosis of PAS (accreta and percreta)*</p> <p>Grey scale ultrasound plus colour-flow Doppler ultrasound (N=35): TP 13; FP 4; FN 2; TN 16</p> <p>MRI without contrast (N=35): TP 14; FP 3; FN 1; TN 17</p> <p>*N=15 had PAS, but the study did not specify number of participants with each PAS disorder and whether participants had hysterectomy.</p>

FN: false negative; FP: false positive; MRI: magnetic resonance imaging; NR: not reported; PAS: placenta accreta spectrum; TN: true negative; TP: true positive; T2-WI: T2 weighted image; 1.5-T: 1.5 Tesla

### Critical appraisal - NGA Critical appraisal - QUADAS-2

Section	Question	Answer
Patient selection: risk of bias	Could the selection of patients have introduced bias?	Low

Section	Question	Answer
Patient selection: applicability	Are there concerns that included patients do not match the review question?	High <i>(All participants had placenta praevia, but only 80% of participants had a previous uterine intervention)</i>
Index tests: risk of bias	Could the conduct or interpretation of the index test have introduced bias?	Low
Index tests: applicability	Are there concerns that the index test, its conduct, or interpretation differ from the review question?	Low
Reference standard: risk of bias	Could the reference standard, its conduct, or its interpretation have introduced bias?	Low
Reference standard: applicability	Is there concern that the target condition as defined by the reference standard does not match the review question?	Low
Flow and timing: risk of bias	Could the patient flow have introduced bias?	Low

QUADAS: *Quality Assessment of Diagnostic Accuracy Studies*

### Mathur, 2019

#### Bibliographic Reference

Mathur, A.; Rajoria, L.; Bansal, A.; Hemani, S.; Vyas, J.; Role of placenta accreta index in patients with placenta previa with previous cesarean: A prospective study; Journal of SAFOG; 2019; vol. 11 (no. 6); 363-367

#### Study details

Country/ies where study was carried out	India
Study type	Prospective cohort study

<b>Study dates</b>	April 2017 - November 2018
<b>Inclusion criteria</b>	Pregnant women with $\geq 28$ weeks of gestation and a history of one or more previous caesarean or presenting with bleeding per vaginum
<b>Exclusion criteria</b>	Pregnant women with multifetal gestation, known coagulopathy, and foetal distress that needs immediate emergency caesarean section
<b>Patient characteristics</b>	<p>N=80</p> <p>Gestational age at enrolment: at or after 28 weeks</p> <p>Gestational age at diagnosis of placenta praevia: at or after 28 weeks</p> <p>Placenta praevia: N=80</p> <p><math>\geq 1</math> previous caesarean birth: N=80</p> <p>Parity: not reported</p> <p>BMI: not reported</p> <p>Participants underwent ultrasound examination to calculate the PAI score and then underwent MRI examination. The data on PAI score were not reported in this review because it included non-radiological feature (that is, previous caesarean delivery) in addition to ultrasound features. Timing of ultrasound scan was not reported.</p>
<b>Index test(s)</b>	<p>MRI (unspecified type)</p> <p>The study did not report information on type of MRI examination (for example, MRI with contrast), the study personnel who performed MRI examination, MRI features for diagnosis of PAS, and timing of MRI scan.</p>
<b>Reference standard(s)</b>	Operative findings with histopathological reports
<b>Duration of follow-up</b>	Up to 9 weeks

<b>Sources of funding</b>	Not industry funded
<b>Target condition</b>	PAS
<b>Results</b>	<p>Outcome: diagnosis of PAS (accreta, increta, and percreta)*</p> <p>MRI (unspecified type) (N=80): TP 28; FP 0; FN 14; TN 38</p> <p>2x2 table not reported by the study but calculated based on sensitivity and specificity presented</p> <p>*N=42 had PAS, but the study did not specify number of participants with each PAS disorder. N=20 participants had hysterectomy.</p>

FN: false negative; FP: false positive; MRI: magnetic resonance imaging; PAI: placenta accreta index; PAS: placenta accreta spectrum; TN: true negative; TP: true positive

#### Critical appraisal - NGA Critical appraisal - QUADAS-2

Section	Question	Answer
Patient selection: risk of bias	Could the selection of patients have introduced bias?	Low
Patient selection: applicability	Are there concerns that included patients do not match the review question?	Low
Index tests: risk of bias	Could the conduct or interpretation of the index test have introduced bias?	Unclear (MRI features for diagnosis of PAS not reported)
Index tests: applicability	Are there concerns that the index test, its conduct, or interpretation differ from the review question?	Low
Reference standard: risk of bias	Could the reference standard, its conduct, or its interpretation have introduced bias?	Low

Section	Question	Answer
Reference standard: applicability	Is there concern that the target condition as defined by the reference standard does not match the review question?	Low
Flow and timing: risk of bias	Could the patient flow have introduced bias?	Low

*MRI: magnetic resonance imaging; PAS: placenta accreta spectrum; QUADAS: Quality Assessment of Diagnostic Accuracy Studies*

### Maurea, 2018

**Bibliographic Reference** Maurea, S; Romeo, V; Mainenti, P P; Ginocchio, M I; Frauenfelder, G; Verde, F; Liuzzi, R; D'Armiento, M; Sarno, L; Morlando, M; Petretta, M; Martinelli, P; Brunetti, A; Diagnostic accuracy of magnetic resonance imaging in assessing placental adhesion disorder in patients with placenta previa: Correlation with histological findings.; European journal of radiology; 2018; vol. 106; 77-84

### Study details

<b>Country/ies where study was carried out</b>	Italy
<b>Study type</b>	Prospective cohort study
<b>Study dates</b>	January 2012 - December 2017
<b>Inclusion criteria</b>	Pregnant women with at least 30 weeks of gestation, the presence of placenta praevia with suspected PAS on ultrasound, and history of myometrium damage, including caesarean birth or abrasive/curettage interventions
<b>Exclusion criteria</b>	Not reported
<b>Patient characteristics</b>	N=61 Mean age in years (SD): 33.4 (NR)

	<p>Gestational age in weeks at diagnosis of placenta praevia: 33*</p> <p>Gravidity (range): 1-12</p> <p>Placenta praevia: N=61</p> <p>Previous caesarean birth:  1 previous caesarean birth: N=33  2 previous caesarean birth: N=21  3 previous caesarean birth: N=4</p> <p>Other uterine interventions (abortion, curettage): N=32</p> <p>BMI: not reported</p> <p>Participants with suspected PAS on ultrasound were included and underwent MRI examination. Ultrasound scan was performed within one week prior to MRI scan.</p> <p>*It could be about 33 weeks as ultrasound was performed one week before MRI which was done at 34.7 weeks.</p>
<b>Index test(s)</b>	<p>MRI without contrast (1.5-T MRI without contrast)</p> <p>MRI examination was performed by two radiologists with eighteen and seven years of experience in genitourinary MRI, and for discordant cases, advice from a third radiologist with twelve years' experience in female pelvis imaging was sought.</p> <p>MRI features for diagnosis of PAS were intraplacental dark bands, intraplacental abnormal vascularity, focal interruption of myometrial border with loss of the trilaminar structure, uterine bulging, tenting of the bladder, and direct visualisation of adjacent tissues invasion.</p> <p>The study reported diagnostic accuracy of the presence of at least one feature and two features. However, this review only reported the latter.</p> <p>MRI examination was performed at mean gestational age 34.7 weeks.</p>
<b>Reference standard(s)</b>	<p>Post caesarean birth examination with histology</p>



<b>Duration of follow-up</b>	Not reported
<b>Sources of funding</b>	Not industry funded
<b>Target condition</b>	PAS
<b>Results</b>	<p>Outcome: diagnosis of PAS (accreta, increta, and percreta)*</p> <p>MRI without contrast (N=61): TP 23; FP 3; FN 2; TN 33</p> <p>*The study included N=14 with accreta, N=8 with increta, and N=3 with percreta. N=23 with PAS and N=13 without PAS had hysterectomy.</p>

FN: false negative; FP: false positive; MRI: magnetic resonance imaging; NR: not reported; PAS: placenta accreta spectrum; SD: standard deviation; TN: true negative; TP: true positive; 1.5-T: 1.5 Tesla

### Critical appraisal - NGA Critical appraisal - QUADAS-2

Section	Question	Answer
Patient selection: risk of bias	Could the selection of patients have introduced bias?	Unclear (Case-control design was avoided, but exclusion criteria not provided)
Patient selection: applicability	Are there concerns that included patients do not match the review question?	Low
Index tests: risk of bias	Could the conduct or interpretation of the index test have introduced bias?	Low
Index tests: applicability	Are there concerns that the index test, its conduct, or interpretation differ from the review question?	Low
Reference standard: risk of bias	Could the reference standard, its conduct, or its interpretation have introduced bias?	Low

Section	Question	Answer
Reference standard: applicability	Is there concern that the target condition as defined by the reference standard does not match the review question?	Low
Flow and timing: risk of bias	Could the patient flow have introduced bias?	Low

QUADAS: *Quality Assessment of Diagnostic Accuracy Studies*

## Maurea, 2022

**Bibliographic Reference** Maurea, Simone; Verde, Francesco; Mainenti, Pier Paolo; Barbuto, Luigi; Iacobellis, Francesca; Romeo, Valeria; Liuzzi, Raffaele; Raia, Giorgio; De Dominicis, Gianfranco; Santangelo, Claudio; Romano, Luigia; Brunetti, Arturo; Qualitative evaluation of MR images for assessing placenta accreta spectrum disorders in patients with placenta previa: A pilot validation study.; *European journal of radiology*; 2022; vol. 146; 110078

## Study details

<b>Country/ies where study was carried out</b>	Italy
<b>Study type</b>	Retrospective cohort study
<b>Study dates</b>	January 2018 - January 2020
<b>Inclusion criteria</b>	Pregnant women aged over 18 years with placenta praevia and available histological proof of PAS after caesarean birth or total hysterectomy.
<b>Exclusion criteria</b>	Pregnant women with incomplete MRI images, MRI examinations substantially impacted by mother or foetal motion artifacts, and incomplete histological and/or clinical data
<b>Patient characteristics</b>	N=65

	<p>Mean age in years (SD): 33.0 (4.6)</p> <p>Gestational age at diagnosis of placenta praevia: not reported</p> <p>Placenta praevia: N=65</p> <p>Previous caesarean birth:  1 previous caesarean birth: N=25  2 previous caesarean birth: N=12  3 previous caesarean birth: N=4  4 previous caesarean birth: N=1</p> <p>BMI: not reported</p> <p>The study did not specify whether ultrasound examination was performed before MRI examination.</p>
<b>Index test(s)</b>	<p>MRI without contrast (1.5-T MRI without contrast)</p> <p>In this study, MRI examinations were performed by three groups of radiologists: (1) board-certified radiologists with minimum 5 years' experience in body diagnostic imaging, (2) two board-certified radiologists with minimum 10 years' experience in MRI genitourinary imaging, and (3) two board-certified radiologists with minimum 20 years' experience in MRI genitourinary imaging. For discordant cases, advice from a third radiologist with the same level of MRI experience was sought.</p> <p>This review only reported the data assessed by Group 3.</p> <p>MRI features for diagnosis of PAS were intraplacental dark bands, abnormal placental vascularity, and focal interruption of myometrial border.</p> <p>The diagnosis of PAS was regarded as positive when at least one or two of these features were present. However, this review only reported the latter.</p> <p>Timing of MRI scan was not reported.</p>
<b>Reference standard(s)</b>	<p>Post caesarean birth examination with histology</p>

<b>Duration of follow-up</b>	Not reported
<b>Sources of funding</b>	Not reported
<b>Target condition</b>	PAS
<b>Results</b>	<p>Outcome: diagnosis of PAS (accreta, and increta)*</p> <p>MRI without contrast (N=65): TP 16; FP 5; FN 2; TN 42</p> <p>*The study included N=14 with accreta, and N=4 with increta, and all participants (N=18) with PAS had hysterectomy.</p>

FN: false negative; FP: false positive; MRI: magnetic resonance imaging; PAS: placenta accreta spectrum; SD: standard deviation; TN: true negative; TP: true positive; 1.5-T: 1.5 Tesla

#### Critical appraisal - NGA Critical appraisal - QUADAS-2

Section	Question	Answer
Patient selection: risk of bias	Could the selection of patients have introduced bias?	Low
Patient selection: applicability	Are there concerns that included patients do not match the review question?	High <i>(All participants had placenta praevia, but only 65% of participants had a previous caesarean section)</i>
Index tests: risk of bias	Could the conduct or interpretation of the index test have introduced bias?	Low
Index tests: applicability	Are there concerns that the index test, its conduct, or interpretation differ from the review question?	Low
Reference standard: risk of bias	Could the reference standard, its conduct, or its interpretation have introduced bias?	Low

Section	Question	Answer
Reference standard: applicability	Is there concern that the target condition as defined by the reference standard does not match the review question?	Low
Flow and timing: risk of bias	Could the patient flow have introduced bias?	Low

QUADAS: *Quality Assessment of Diagnostic Accuracy Studies*

### Millischer, 2017

**Bibliographic Reference** Millischer, A-E; Salomon, L J; Porcher, R; Brasseur-Daudruy, M; Gourdier, A-L; Hornoy, P; Silvera, S; Loisel, D; Tsatsaris, V; Delorme, B; Boddaert, N; Ville, Y; Sentilhes, L; Magnetic resonance imaging for abnormally invasive placenta: the added value of intravenous gadolinium injection.; BJOG : an international journal of obstetrics and gynaecology; 2017; vol. 124 (no. 1); 88-95

### Study details

<b>Country/ies where study was carried out</b>	France
<b>Study type</b>	Retrospective cohort study
<b>Study dates</b>	March 2009 - October 2012
<b>Inclusion criteria</b>	Pregnant women with placenta praevia, at least a previous caesarean section, and suspected PAS findings on third trimester ultrasound
<b>Exclusion criteria</b>	Pregnant women who declined MRI examination and gadolinium injection or had delivery before MRI examination could be performed
<b>Patient characteristics</b>	N=20

	<p>Mean age in years (SD): 34.7 (2.4)</p> <p>Gestational age at diagnosis of placenta praevia: third trimester</p> <p>Placenta praevia: N=20</p> <p>Previous caesarean birth:  1 previous caesarean birth: N=6  2 previous caesarean birth: N=12  3 previous caesarean birth: N=2</p> <p>Parity: not reported</p> <p>BMI: not reported</p> <p>Participants with suspected PAS findings on third trimester ultrasound were included and underwent MRI examination. The exact gestational age in weeks at ultrasound scan was not reported.</p>
<b>Index test(s)</b>	<ol style="list-style-type: none"> <li>1. MRI without contrast (1.5-T MRI without contrast)</li> <li>2. MRI with contrast (1.5-T MRI with contrast)</li> </ol> <p>MRI examinations were performed by two junior radiologists with less than 2 years of experience in foetal MRI and two senior radiologists with over 5 years of experience in foetal and placental MRI. This review reported data assessed by senior radiologists.</p> <p>MRI features for diagnosis of PAS were heterogeneous intraplacental signal intensity on T2-WI, dark placental bands on T2-weighted sequences, focal interruption of the myometrial borders with exophytic placental tissue throughout the myometrium, placental invasion of adjacent structures (suspected in case of irregularity or tenting of the bladder wall), abnormal uterine bulging, visibility of the entire hypointense T2-weighted interface between the myometrium and the placenta, and good contrast between the myometrium and placenta.</p> <p>The study reported diagnostic accuracy of individual feature and overall diagnostic accuracy of the features. However, this review only reported the latter.</p> <p>The study did not specify timing of MRI scan.</p>

<b>Reference standard(s)</b>	Operative findings with or without histology reports
<b>Duration of follow-up</b>	Not reported
<b>Sources of funding</b>	Not industry funded
<b>Target condition</b>	PAS
<b>Results</b>	<p>Outcome: diagnosis of PAS (accreta and percreta)*</p> <p>MRI without contrast (N=20): TP 7; FP 4; FN 1; TN 8</p> <p>MRI with contrast (N=20): TP 8; FP 4; FN 0; TN 8</p> <p>2x2 tables not reported by the study but calculated based on sensitivity and specificity presented</p> <p>*The study included N=7 with accreta and N=1 with percreta, and N=3 with PAS had hysterectomy.</p>

FN: false negative; FP: false positive; MRI: magnetic resonance imaging; PAS: placenta accreta spectrum; SD: standard deviation; TN: true negative; TP: true positive; T2-WI: T2 weighted image; 1.5-T: 1.5 Tesla

#### Critical appraisal - NGA Critical appraisal - QUADAS-2

Section	Question	Answer
Patient selection: risk of bias	Could the selection of patients have introduced bias?	Low
Patient selection: applicability	Are there concerns that included patients do not match the review question?	Low
Index tests: risk of bias	Could the conduct or interpretation of the index test have introduced bias?	Low
Index tests: applicability	Are there concerns that the index test, its conduct, or interpretation differ from the review question?	Low

Section	Question	Answer
Reference standard: risk of bias	Could the reference standard, its conduct, or its interpretation have introduced bias?	Low
Reference standard: applicability	Is there concern that the target condition as defined by the reference standard does not match the review question?	Low
Flow and timing: risk of bias	Could the patient flow have introduced bias?	Low

QUADAS: *Quality Assessment of Diagnostic Accuracy Studies*

### Naghshineh, 2015

**Bibliographic Reference** Naghshineh, Elham; Khorvash, Elahe; Kamali, Sara; A comparison of cell-free placental messenger ribonucleic acid and color Doppler ultrasound for the prediction of placental invasion in patients with placenta accreta.; *Advanced biomedical research*; 2015; vol. 4; 31

### Study details

<b>Country/ies where study was carried out</b>	Iran
<b>Study type</b>	Cross-sectional study
<b>Study dates</b>	April 2012 - February 2013
<b>Inclusion criteria</b>	Women with singleton pregnancy of over 28 weeks of gestation and risk factors for PAS, including previous history of one or more caesarean birth, placenta praevia, previous curettage or uterus surgery
<b>Exclusion criteria</b>	Preterm labor, pre-eclampsia, intrauterine growth restriction, current use of tocolytic agent, and uterine bleeding at or after blood sampling



<b>Patient characteristics</b>	<p>N=50 (PAS: N=12; No PAS: N=38)</p> <p>Mean age in years (SD): 30.2 (4.9)</p> <p>Gestational age in weeks at birth: 37</p> <p>Gestational age at diagnosis of placenta praevia: not reported</p> <p>Mean parity (SD):  PAS: 1.8 (1.2)  No PAS: 1.5 (0.9)</p> <p>Number of previous caesarean birth; mean (SD):  PAS: 1.8 (1.1)  No PAS: 1.4 (0.8)</p> <p>Number of previous curettage; mean (SD):  PAS: 0.6 (0.7)  No PAS: 0.5 (0.8)</p> <p>BMI: not reported</p>
<b>Index test(s)</b>	<p>Colour-flow Doppler ultrasound*</p> <p>Ultrasound features for diagnosis of PAS were turbulent or diffuse blood flow through placental lacunae, and vessels crossing the interface disruption site.</p> <p>The study did not specify who performed ultrasound scan and timing of scan.</p> <p>*Unclear whether transvaginal or transabdominal approach was used</p>
<b>Reference standard(s)</b>	<p>Post caesarean birth examination with histology</p>
<b>Duration of follow-up</b>	<p>Not reported</p>

<b>Sources of funding</b>	Not reported
<b>Target condition</b>	PAS
<b>Results</b>	Outcome: diagnosis of PAS (accreta, increta, and percreta)* Colour-flow Doppler ultrasound (50): TP 10; FP 8; FN 2; TN 30 *N=12 had PAS, but the study did not specify number of participants who had each PAS disorder and hysterectomy.

FN: false negative; FP: false positive; PAS: placenta accreta spectrum; SD: standard deviation; TN: true negative; TP: true positive

#### Critical appraisal - NGA Critical appraisal - QUADAS-2

Section	Question	Answer
Patient selection: risk of bias	Could the selection of patients have introduced bias?	Low
Patient selection: applicability	Are there concerns that included patients do not match the review question?	Unclear (No information on the total number of participants with placenta praevia and previous caesarean birth)
Index tests: risk of bias	Could the conduct or interpretation of the index test have introduced bias?	Low
Index tests: applicability	Are there concerns that the index test, its conduct, or interpretation differ from the review question?	Low
Reference standard: risk of bias	Could the reference standard, its conduct, or its interpretation have introduced bias?	Low
Reference standard: applicability	Is there concern that the target condition as defined by the reference standard does not match the review question?	Low

Section	Question	Answer
Flow and timing: risk of bias	Could the patient flow have introduced bias?	Low

QUADAS: *Quality Assessment of Diagnostic Accuracy Studies*

### Othman, 2018

**Bibliographic Reference** Othman, A.I.A.; Ibrahim, M.E.A.; Mansour, D.Y.; Diagnostic accuracy of MRI criteria in predilection of morbidly adherent placenta; Egyptian Journal of Radiology and Nuclear Medicine; 2018; vol. 49 (no. 3); 819-827

### Study details

<b>Country/ies where study was carried out</b>	Egypt
<b>Study type</b>	Prospective cohort study
<b>Study dates</b>	October 2015 - February 2017
<b>Inclusion criteria</b>	Pregnant women with suspected PAS findings on ultrasound and advanced maternal age with low-lying anterior placenta
<b>Exclusion criteria</b>	Pregnant women with implanted electrical devices (for example, cardiac pacemakers) that are contraindications to MRI
<b>Patient characteristics</b>	<p>N=40</p> <p>Mean age in years (SD): 29.2 (6.6)</p> <p>Gestational age at diagnosis of placenta praevia: not reported</p> <p>Parity:</p> <p>Parity 0: N=4</p> <p>Parity 1: N=14</p> <p>Parity 2: N=14</p>

	<p>Parity 3: N=4 Parity 4: N=4</p> <p>Placenta praevia: N=30</p> <p>Low-lying placenta: N=8</p> <p>Previous caesarean birth: N=36</p> <p>BMI: not reported</p>
<b>Index test(s)</b>	<p>MRI without contrast (1.5-T MRI without contrast)</p> <p>MRI examination was performed by two radiologists, and no further information on radiologists was reported.</p> <p>MRI features for diagnosis of PAS were loss of retroplacental zone, intraplacental dark bands on T2-WI, lower uterine contour bulge, abnormal disorganised placental vascularity, marked placental heterogeneity, and loss of dark myometrium (focal myometrial interruption) on T2-WI.</p> <p>MRI examination was performed at mean (SD) gestational age 33.8 (3.2) weeks.</p>
<b>Reference standard(s)</b>	Operative findings without histology reports
<b>Duration of follow-up</b>	Not reported
<b>Sources of funding</b>	Not reported
<b>Target condition</b>	PAS
<b>Results</b>	<p>Outcome: diagnosis of PAS (accreta, increta, and percreta)*</p> <p>MRI without contrast (N=40): TP 12; FP 4; FN 0; TN 24</p> <p>2x2 table not reported by the study but calculated based on sensitivity and specificity presented</p> <p>*The study included N=4 with accreta, N=4 with increta, and N=4 with percreta, and no participants had hysterectomy.</p>

FN: false negative; FP: false positive; MRI: magnetic resonance imaging; PAS: placenta accreta spectrum; SD: standard deviation; TN: true negative; TP: true positive; T2-WI: T2 weighted image; 1.5-T: 1.5 Tesla

### Critical appraisal - NGA Critical appraisal - QUADAS-2

Section	Question	Answer
Patient selection: risk of bias	Could the selection of patients have introduced bias?	Low
Patient selection: applicability	Are there concerns that included patients do not match the review question?	Low
Index tests: risk of bias	Could the conduct or interpretation of the index test have introduced bias?	Low
Index tests: applicability	Are there concerns that the index test, its conduct, or interpretation differ from the review question?	Low
Reference standard: risk of bias	Could the reference standard, its conduct, or its interpretation have introduced bias?	Low
Reference standard: applicability	Is there concern that the target condition as defined by the reference standard does not match the review question?	Low
Flow and timing: risk of bias	Could the patient flow have introduced bias?	Low

QUADAS: *Quality Assessment of Diagnostic Accuracy Studies*

### Panaiotova, 2019

**Bibliographic Reference** Panaiotova, J; Tokunaka, M; Krajewska, K; Zosmer, N; Nicolaidis, K H; Screening for morbidly adherent placenta in early pregnancy.; *Ultrasound in obstetrics & gynecology : the official journal of the International Society of Ultrasound in Obstetrics and Gynecology*; 2019; vol. 53 (no. 1); 101-106

### Study details

<b>Country/ies where study was carried out</b>	UK
--	----

<b>Study type</b>	Prospective cohort study
<b>Study dates</b>	August 2013 - August 2016
<b>Inclusion criteria</b>	Pregnant women with a singleton pregnancy attending a routine antenatal visit at 11 to 13 weeks of gestation who had history of previous uterine interventions (for example, caesarean section or myomectomy) and low-lying placenta
<b>Exclusion criteria</b>	Pregnant women who had miscarriage, pregnancy termination, high placenta, low posterior placenta but not reaching os, no outcome data, and no previous surgery, and did not attend specialist MAP clinic
<b>Patient characteristics</b>	<p>N=48</p> <p>Gestational age at diagnosis of placenta praevia or low-lying placenta: at 11 to 13 weeks, 12 to 16 weeks, 20 to 24 weeks, and 28 to 34 weeks*</p> <p>Placenta praevia or low-lying placenta: N=48</p> <p>Previous uterine surgery (for example, caesarean section or myomectomy): N=48</p> <p>N=9 and N=4 with PAS had delivery at mean gestational age 37 weeks and 32 weeks, respectively, but no information on timing of delivery in those without PAS was provided.</p> <p>Parity: not reported</p> <p>BMI: not reported</p> <p>*Participants diagnosed with persistent placenta praevia (confirmed by ultrasound at 28 to 34 weeks) were included.</p>
<b>Index test(s)</b>	<p>Grey scale ultrasound plus colour-flow and 3D power Doppler ultrasounds (transabdominal and transvaginal)*</p> <p>Ultrasound examinations were conducted by an operator who had received training in the diagnosis of PAS, including review of videos and pictures and ultrasound scanning under the direct supervision of an expert.</p> <p>Ultrasound features for diagnosis of PAS were non-visible caesarean section scar, thin retroplacental myometrium, bladder wall interruption, retroplacental arterial-trophoblastic blood flow, and irregular placental vascularisation on 3D power Doppler.</p> <p>The diagnosis of PAS was regarded as positive when at least three of these features were present.</p>

	<p>Ultrasound scans were performed at 12 to 16 weeks, 20 to 24 weeks and 28 to 34 weeks of gestation.</p> <p>*Type of ultrasounds were reported based on ultrasound images presented in the study as the study did not specify it.</p>
<b>Reference standard(s)</b>	Post caesarean birth examination with histology
<b>Duration of follow-up</b>	Not reported
<b>Sources of funding</b>	Not industry funded
<b>Target condition</b>	PAS
<b>Results</b>	<p>Outcome: diagnosis of PAS*</p> <p>Grey scale ultrasound plus colour-flow and 3D power Doppler ultrasounds (N=48): TP 13; FP 1; FN 0; TN 34</p> <p>*N=13 had PAS, but the study did not specify type of PAS disorders.</p>

*FN: false negative; FP: false positive; PAS: placenta accreta spectrum; TN: true negative; TP: true positive; 3D: three dimensional*

### Critical appraisal - NGA Critical appraisal - QUADAS-2

Section	Question	Answer
Patient selection: risk of bias	Could the selection of patients have introduced bias?	Low
Patient selection: applicability	Are there concerns that included patients do not match the review question?	Low
Index tests: risk of bias	Could the conduct or interpretation of the index test have introduced bias?	Low
Index tests: applicability	Are there concerns that the index test, its conduct, or interpretation differ from the review question?	Low

Section	Question	Answer
Reference standard: risk of bias	Could the reference standard, its conduct, or its interpretation have introduced bias?	Low
Reference standard: applicability	Is there concern that the target condition as defined by the reference standard does not match the review question?	Low
Flow and timing: risk of bias	Could the patient flow have introduced bias?	Low

QUADAS: *Quality Assessment of Diagnostic Accuracy Studies*

### Patru, 2019

**Bibliographic Reference** Patru, Ciprian Laurentiu; Marinas, Marius Cristian; Tudorache, Stefania; Capitanescu, Razvan Grigoras; Sirbu, Ovidiu Costinel; Zorila, George Lucian; Cernea, Nicolae; Istrate-Ofiteru, Anca Maria; Rosu, Gabriela Camelia; Iovan, Larisa; Iliescu, Dominic Gabriel; The performance of hyperadherence markers in anterior placenta praevia overlying the Caesarean scar.; Romanian journal of morphology and embryology = Revue roumaine de morphologie et embryologie; 2019; vol. 60 (no. 3); 861-867

### Study details

<b>Country/ies where study was carried out</b>	Romania
<b>Study type</b>	Prospective cohort study
<b>Study dates</b>	January 2016 - December 2017
<b>Inclusion criteria</b>	Pregnant women with anterior placenta praevia covering the internal os and history of previous caesarean section
<b>Exclusion criteria</b>	Not reported



<b>Patient characteristics</b>	<p>N=46</p> <p>Gestational age at enrolment: third trimester</p> <p>Gestational age at diagnosis of placenta praevia: third trimester</p> <p>Placenta praevia: N=46</p> <p>Previous caesarean birth: N=46</p> <p>Parity: not reported</p> <p>BMI: not reported</p>
<b>Index test(s)</b>	<p>Grey scale ultrasound (2D) plus colour-flow or power Doppler ultrasound (transabdominal and transvaginal)</p> <p>Ultrasound examinations were performed by at least two operators, but no further information on operators was provided.</p> <p>Ultrasound features for diagnosis of PAS were thinning of the hyperechogenic uterine serosa-bladder wall interface, loss of normal hypoechoic retroplacental myometrial space, intraplacental lacunae, and colour-flow doppler abnormalities, including abnormal blood vessels at the myometrium-bladder interface.</p> <p>The combinations of these features were considered specific for PAS.</p> <p>Timing of grey scale and colour-flow or power Doppler ultrasound was not reported.</p>
<b>Reference standard(s)</b>	Operative findings with or without histopathological reports
<b>Duration of follow-up</b>	Not reported
<b>Sources of funding</b>	Not reported
<b>Target condition</b>	PAS

<b>Results</b>	<p>Outcome: diagnosis of PAS*</p> <p>Grey scale ultrasound (2D) plus colour-flow or power Doppler ultrasound (N=46): TP 11; FP 1; FN 0; TN 34</p> <p>2x2 table was calculated based on sensitivity and specificity as there was discrepancy in 2x2 table reported by the study</p> <p>*N=11 had PAS, but the study did not specify type of PAS disorders and number of participants who had hysterectomy.</p>
----------------	---

FN: false negative; FP: false positive; PAS: placenta accreta spectrum; TN: true negative; TP: true positive; 2D: two dimensional

### Critical appraisal - NGA Critical appraisal - QUADAS-2

Section	Question	Answer
Patient selection: risk of bias	Could the selection of patients have introduced bias?	Unclear (Case-control design was avoided, but exclusion criteria not provided)
Patient selection: applicability	Are there concerns that included patients do not match the review question?	Low
Index tests: risk of bias	Could the conduct or interpretation of the index test have introduced bias?	Low
Index tests: applicability	Are there concerns that the index test, its conduct, or interpretation differ from the review question?	Low
Reference standard: risk of bias	Could the reference standard, its conduct, or its interpretation have introduced bias?	Low
Reference standard: applicability	Is there concern that the target condition as defined by the reference standard does not match the review question?	Low
Flow and timing: risk of bias	Could the patient flow have introduced bias?	Low

QUADAS: Quality Assessment of Diagnostic Accuracy Studies

**Reeder, 2022**

**Bibliographic Reference** Reeder, Callie F; Sylvester-Armstrong, Kendra R; Silva, Lauren M; Wert, Erika M; Smulian, John C; Genc, Mehmet R; Outcomes of pregnancies at high-risk for placenta accreta spectrum following negative diagnostic imaging.; Journal of perinatal medicine; 2022; vol. 50 (no. 5); 595-600

**Study details**

<b>Country/ies where study was carried out</b>	USA
<b>Study type</b>	Retrospective cohort study and prospective cohort study
<b>Study dates</b>	January 2013 - December 2020* The data were collected retrospectively between January 2013 and April 2018, but from April 2018 it was collected prospectively.
<b>Inclusion criteria</b>	Retrospective cohort: Pregnant women with clinically suspected and/or pathologically confirmed PAS Prospective cohort: Pregnant women with $\geq 1$ previous caesarean section and/or intrauterine gynaecologic intervention (for example, hysteroscopy, sharp or suction curettage, surgical termination and endometrial ablation) and placenta praevia in the current pregnancy, history of retained placenta that requires manual removal and/or curettage, $>3$ previous caesarean birth and/or gynaecologic intervention, and suspected caesarean section scar pregnancy
<b>Exclusion criteria</b>	Participants who did not deliver at the study hospital and had no imaging
<b>Patient characteristics</b>	N=82 Gestational age at diagnosis of PAS: not reported Placenta praevia: N=55 Previous uterine surgery: $\geq 1$ previous uterine surgery: N=55 $>3$ uterine surgeries: N=23

	<p>History of retained placenta and/or curettage: N=3</p> <p>Parity: not reported</p> <p>BMI: not reported</p>
<b>Index test(s)</b>	<p>Ultrasound (sonography including Doppler interrogation; transvaginal) with or without MRI*</p> <p>Board-certified maternal-foetal medicine specialists and experienced radiologists performed sonography (ultrasound) and MRI examinations, respectively.</p> <p>Ultrasound features for diagnosis of PAS were placental lacunae, increased vascularity, disruption of bladder mucosa or myometrial interface, loss of sonolucent space between the placenta and the uterine myometrium, and invasion of pelvic structures.</p> <p>MRI features were not reported, and MRI was performed to evaluate the extent and topography of trophoblast invasion and for diagnosis of PAS.</p> <p>The diagnosis of PAS was regarded as positive when ultrasound and/or MRI were suggestive of PAS.</p> <p>All participants (N=82) had ultrasound examination, and N=40 had adjunct MRI.</p> <p>Timing of ultrasound and MRI scans not reported, and ultrasound could be performed before MRI as MRI was used as an adjunct.</p> <p>*The study did not clearly describe type of ultrasound and MRI (for example, MRI with or without contrast).</p>
<b>Reference standard(s)</b>	Operative findings with histopathology reports
<b>Duration of follow-up</b>	Not reported
<b>Sources of funding</b>	Not reported
<b>Target condition</b>	PAS

<b>Results</b>	<p>Outcome: diagnosis of PAS*</p> <p>Ultrasound (sonography including Doppler interrogation) with or without MRI (N=80)**: TP 44; FP 6; FN 6; TN 24</p> <p>*N=50 had PAS, but the study did not specify number of participants with each PAS disorder and total number of participants who had hysterectomy.</p> <p>**N=80 (all participants) and N=40 had ultrasound and MRI examinations, respectively.</p>
----------------	---

FN: false negative; FP: false positive; MRI: magnetic resonance imaging; PAS: placenta accreta spectrum; TN: true negative; TP: true positive

### Critical appraisal - NGA Critical appraisal - QUADAS-2

Section	Question	Answer
Patient selection: risk of bias	Could the selection of patients have introduced bias?	Low
Patient selection: applicability	Are there concerns that included patients do not match the review question?	High <i>(95% of participants had a previous uterine surgery, but only 67% of participants had placenta praevia)</i>
Index tests: risk of bias	Could the conduct or interpretation of the index test have introduced bias?	Unclear <i>(No clear information about whether the index test results were interpreted without knowledge of the results of the reference standard, and MRI features were not reported)</i>
Index tests: applicability	Are there concerns that the index test, its conduct, or interpretation differ from the review question?	Low
Reference standard: risk of bias	Could the reference standard, its conduct, or its interpretation have introduced bias?	Low

Section	Question	Answer
Reference standard: applicability	Is there concern that the target condition as defined by the reference standard does not match the review question?	Low
Flow and timing: risk of bias	Could the patient flow have introduced bias?	Low

*MRI: magnetic resonance imaging; QUADAS: Quality Assessment of Diagnostic Accuracy Studies*

## Rezk, 2016

**Bibliographic Reference** Rezk, Mohamed Abd-Allah; Shawky, Mohamed; Grey-scale and colour Doppler ultrasound versus magnetic resonance imaging for the prenatal diagnosis of placenta accreta.; The journal of maternal-fetal & neonatal medicine : the official journal of the European Association of Perinatal Medicine, the Federation of Asia and Oceania Perinatal Societies, the International Society of Perinatal Obstetricians; 2016; vol. 29 (no. 2); 218-23

## Study details

<b>Country/ies where study was carried out</b>	Egypt
<b>Study type</b>	Prospective cohort study
<b>Study dates</b>	March 2012 - August 2014
<b>Inclusion criteria</b>	Haemodynamically stable pregnant women with persistent placenta praevia at 32 to 34 weeks and history of previous uterine intervention (caesarean section and/or myomectomy scar) who attended the antenatal care clinic or were referred to the study hospital
<b>Exclusion criteria</b>	Pregnant women with active bleeding or ultrasonographic diagnosis of uteri with congenital abnormalities

<b>Patient characteristics</b>	<p>N=74</p> <p>Mean age in years (SD): 30.2 (4.3)</p> <p>Gestational age in weeks at diagnosis of persistent placenta praevia (range): 32-34</p> <p>Mean parity (SD): 2.8 (0.9)</p> <p>Parity:          Parity 1: N=7          Parity 2: N=22          Parity 3: N=23          Parity 4: N=22</p> <p>Placenta praevia: N=74</p> <p>Previous caesarean birth:          1 previous caesarean birth: N=22          2 previous caesarean birth: N=22          3 previous caesarean birth: N=16          4 previous caesarean birth: N=7</p> <p>Previous dilatation and curettage: N=44</p> <p>Previous myomectomy: N=29</p> <p>BMI: not reported</p>
<b>Index test(s)</b>	<ol style="list-style-type: none"> <li>1. Grey scale ultrasound plus colour-flow Doppler ultrasound (transabdominal and transvaginal)</li> <li>2. MRI with contrast (1.5-T MRI with contrast)</li> </ol> <p>Ultrasound and MRI examinations were performed by different observers, but no further information on observers was reported.</p> <p>Ultrasound features for diagnosis of PAS were loss of the retro-placental clear space, bladder line interruption, vascular lacunae, and turbulent blood flow extending from the placenta into the surrounding structures and hypervascularity of uterine serosa bladder wall on colour Doppler.</p>

	<p>MRI features for diagnosis of PAS were T2 hypointense placental band, abnormal intraplacental vascularity, and interruption of the myometrial line and direct invasion of pelvic structures.</p> <p>Grey scale ultrasound, colour-flow doppler ultrasound and MRI examinations were performed at 32 to 34 weeks of gestation.</p>
<b>Reference standard(s)</b>	Operative findings at caesarean section with histopathology reports
<b>Duration of follow-up</b>	Not reported* *Participants were followed up till delivery, but gestational age at birth was not reported.
<b>Sources of funding</b>	Not reported
<b>Target condition</b>	PAS
<b>Results</b>	<p>Outcome: diagnosis of PAS (accreta, increta, and percreta)*</p> <p>Grey scale ultrasound plus colour-flow Doppler ultrasound (N=74): TP 50; FP 2; FN 3; TN 19</p> <p>MRI with contrast (N=74): TP 51; FP 3; FN 2; TN 18</p> <p>*The study included N=31 with accreta, N=14 with increta, and N=8 with percreta, and all participants with PAS (N=53) had hysterectomy.</p>

FN: false negative; FP: false positive; MRI: magnetic resonance imaging; PAS: placenta accreta spectrum; SD: standard deviation; TN: true negative; TP: true positive; 1.5-T: 1.5 Tesla

### Critical appraisal - NGA Critical appraisal - QUADAS-2

Section	Question	Answer
Patient selection: risk of bias	Could the selection of patients have introduced bias?	Low
Patient selection: applicability	Are there concerns that included patients do not match the review question?	Low



Section	Question	Answer
Index tests: risk of bias	Could the conduct or interpretation of the index test have introduced bias?	Low
Index tests: applicability	Are there concerns that the index test, its conduct, or interpretation differ from the review question?	Low
Reference standard: risk of bias	Could the reference standard, its conduct, or its interpretation have introduced bias?	Low
Reference standard: applicability	Is there concern that the target condition as defined by the reference standard does not match the review question?	Low
Flow and timing: risk of bias	Could the patient flow have introduced bias?	Low

QUADAS: *Quality Assessment of Diagnostic Accuracy Studies*

## Romeo, 2019

**Bibliographic Reference** Romeo, V; Sarno, L; Volpe, A; Ginocchio, M I; Esposito, R; Mainenti, P P; Petretta, M; Liuzzi, R; D'Armiento, M; Martinelli, P; Brunetti, A; Maurea, S; US and MR imaging findings to detect placental adhesion spectrum (PAS) in patients with placenta previa: a comparative systematic study.; *Abdominal radiology (New York)*; 2019; vol. 44 (no. 10); 3398-3407

## Study details

<b>Country/ies where study was carried out</b>	Italy
<b>Study type</b>	Retrospective cohort study
<b>Study dates</b>	January 2012 - June 2018

<b>Inclusion criteria</b>	Pregnant women aged over 18 years with placenta praevia who underwent both ultrasound and MRI examinations in the same week and available histological reports after caesarean birth
<b>Exclusion criteria</b>	Pregnant women with incomplete or not retrieved ultrasound and MRI images, MRI images significantly affected by mother or foetal motion artifacts or prematurely interrupted by the participants because of claustrophobia, and unavailable histological reports
<b>Patient characteristics</b>	<p>N=51</p> <p>Mean age in years (range): 35 (20-45)</p> <p>Mean gestational age in weeks: 35</p> <p>Gestational age at diagnosis of placenta praevia: not reported</p> <p>Gravidity (range): 1-12</p> <p>Placenta praevia: N=51</p> <p>Previous caesarean birth:</p> <p>1 previous caesarean birth: N=27</p> <p>2 previous caesarean birth: N=13</p> <p>3 previous caesarean birth: N=5</p> <p>Parity: not reported</p> <p>BMI: not reported</p>
<b>Index test(s)</b>	<ol style="list-style-type: none"> <li>1. Grey scale ultrasound (B-mode) plus colour-flow Doppler ultrasound integrated by pulse wave spectral Doppler (transabdominal and transvaginal)</li> <li>2. MRI without contrast (1.5-T MRI without contrast)</li> </ol> <p>Ultrasound and MRI examinations were performed by two obstetricians trained in placenta sonographic assessment and two radiologists with 8 and 15 years of experience in genitourinary MRI, respectively. For discordant cases, advice from an obstetrician with 30 years of experience and a radiologist with 20 years of experience was sought.</p>

	<p>Ultrasound features for diagnosis of PAS were absence of retroplacental clear space, myometrial thinning, and placenta lacunar spaces.</p> <p>MRI features for diagnosis of PAS were intraplacental dark bands, focal interruption of myometrial border, and abnormal vascularity.</p> <p>The study reported diagnostic accuracy of the presence of at least 1, 2 and 3 features. However, this review only reported the data on the presence of 3 features.</p> <p>Ultrasound and MRI examinations were performed at 30 to 38 weeks of gestation.</p>
<b>Reference standard(s)</b>	Post caesarean birth examination with histology
<b>Duration of follow-up</b>	Not reported
<b>Sources of funding</b>	Not reported
<b>Target condition</b>	PAS
<b>Results</b>	<p>Outcome: diagnosis of PAS (accreta, increta, and percreta)*</p> <p>Grey scale ultrasound plus colour-flow Doppler ultrasound integrated by pulse wave spectral Doppler (N=51): TP 15; FP 5; FN 8; TN 23</p> <p>MRI without contrast (N=51): TP 9; FP 1; FN 14; TN 27</p> <p>2x2 tables not reported by the study but calculated based on sensitivity and specificity presented</p> <p>*The study included N=15 with accreta, N=4 with increta, and N=4 with percreta but did not specify whether participants had hysterectomy.</p>

*FN: false negative; FP: false positive; MRI: magnetic resonance imaging; PAS: placenta accreta spectrum; TN: true negative; TP: true positive; 1.5-T: 1.5 Tesla*

### Critical appraisal - NGA Critical appraisal - QUADAS-2

Section	Question	Answer
Patient selection: risk of bias	Could the selection of patients have introduced bias?	Low
Patient selection: applicability	Are there concerns that included patients do not match the review question?	High <i>(All participants had placenta praevia, but only 88% of participants had a previous caesarean section)</i>
Index tests: risk of bias	Could the conduct or interpretation of the index test have introduced bias?	Low
Index tests: applicability	Are there concerns that the index test, its conduct, or interpretation differ from the review question?	Low
Reference standard: risk of bias	Could the reference standard, its conduct, or its interpretation have introduced bias?	Low
Reference standard: applicability	Is there concern that the target condition as defined by the reference standard does not match the review question?	Low
Flow and timing: risk of bias	Could the patient flow have introduced bias?	Low

QUADAS: *Quality Assessment of Diagnostic Accuracy Studies*

## Romeo, 2021

### Bibliographic Reference

Romeo, Valeria; Verde, Francesco; Sarno, Laura; Migliorini, Sonia; Petretta, Mario; Mainenti, Pier Paolo; D'Armiento, Maria; Guida, Maurizio; Brunetti, Arturo; Maurea, Simone; Prediction of placenta accreta spectrum in patients with placenta previa using clinical risk factors, ultrasound and magnetic resonance imaging findings.; *La Radiologia medica*; 2021; vol. 126 (no. 9); 1216-1225

### Study details

<b>Country/ies where study was carried out</b>	Italy
<b>Study type</b>	Retrospective cohort study
<b>Study dates</b>	February 2013 - June 2019
<b>Inclusion criteria</b>	Pregnant women aged over 18 years with placenta praevia who underwent both ultrasound and MRI examinations in the same week and available histological reports after caesarean birth
<b>Exclusion criteria</b>	Pregnant women with incomplete or not retrieved ultrasound and MRI images, MRI images significantly affected by mother or foetal motion artifacts, and incomplete clinical data
<b>Patient characteristics</b>	<p>N=70</p> <p>Mean age in years (SD): 34.0 (4.8)</p> <p>Gestational age at diagnosis of placenta praevia: not reported</p> <p>Placenta praevia: N=70</p> <p>Previous caesarean birth:</p> <p>1 previous caesarean birth: N=34</p> <p>2 previous caesarean birth: N=22</p> <p>3 previous caesarean birth: N=4</p> <p>4 previous caesarean birth: N=3</p> <p>Parity: not reported</p> <p>BMI: not reported</p>
<b>Index test(s)</b>	<ol style="list-style-type: none"> <li>1. Grey scale ultrasound (B-mode) plus colour-flow Doppler ultrasound (transabdominal and transvaginal)</li> <li>2. MRI without contrast (1.5-T MRI without contrast)</li> </ol>

	<p>Ultrasound and MRI examinations were performed by two obstetricians trained in placenta sonographic assessment and two radiologists with 8 and 15 years of experience in genitourinary MRI, respectively. For discordant cases, advice from an obstetrician with 32 years of experience and a radiologist with 22 years of experience was sought.</p> <p>Ultrasound features for diagnosis of PAS were abnormal placental lacunae, myometrial thinning, placental bulge, absence of the retroplacental clear space, focal exophytic mass, and bladder wall interruption.</p> <p>MRI features for diagnosis of PAS were intraplacental dark bands, focal interruption of myometrial border, abnormal vascularity, uterine bulging, tenting of the bladder, and invasion of surrounding structures.</p> <p>The study did not report timing of ultrasound and MRI scans.</p>
<b>Reference standard(s)</b>	Post caesarean birth examination with histology
<b>Duration of follow-up</b>	Not reported
<b>Sources of funding</b>	Not industry funded
<b>Target condition</b>	PAS
<b>Results</b>	<p>Outcome: diagnosis of PAS (accreta, increta, and percreta)*</p> <p>Grey scale ultrasound plus colour-flow Doppler ultrasound (N=70): TP 20; FP 13; FN 4; TN 33</p> <p>MRI without contrast (N=70): TP 23; FP 7; FN 1; TN 39</p> <p>*The study included N=14 with accreta, N=7 with increta, and N=3 with percreta; and N=24 with PAS and N=13 without PAS had hysterectomy.</p>

FN: false negative; FP: false positive; MRI: magnetic resonance imaging; PAS: placenta accreta spectrum; SD: standard deviation; TN: true negative; TP: true positive; 1.5-T: 1.5 Tesla

### Critical appraisal - NGA Critical appraisal - QUADAS-2

Section	Question	Answer
Patient selection: risk of bias	Could the selection of patients have introduced bias?	Low
Patient selection: applicability	Are there concerns that included patients do not match the review question?	Low
Index tests: risk of bias	Could the conduct or interpretation of the index test have introduced bias?	Low
Index tests: applicability	Are there concerns that the index test, its conduct, or interpretation differ from the review question?	Low
Reference standard: risk of bias	Could the reference standard, its conduct, or its interpretation have introduced bias?	Low
Reference standard: applicability	Is there concern that the target condition as defined by the reference standard does not match the review question?	Low
Flow and timing: risk of bias	Could the patient flow have introduced bias?	Low

QUADAS: *Quality Assessment of Diagnostic Accuracy Studies*

### Satija, 2015

**Bibliographic Reference** Satija, Bhawna; Kumar, Sanyal; Wadhwa, Leena; Gupta, Taru; Kohli, Supreethi; Chandoke, Rajkumar; Gupta, Pratibha; Utility of ultrasound and magnetic resonance imaging in prenatal diagnosis of placenta accreta: A prospective study.; *The Indian journal of radiology & imaging*; 2015; vol. 25 (no. 4); 464-70

### Study details

<b>Country/ies where study was carried out</b>	India
<b>Study type</b>	Prospective cohort study
<b>Study dates</b>	Not reported

<b>Inclusion criteria</b>	<p>Pregnant women with suspected PAS based on clinical risk factors, including previous caesarean birth or uterus surgery and dilatation and curettage, uterine abnormalities, Asherman's syndrome, submucous leiomyoma, advanced maternal age, hypertension, smoking, and multiparity.</p> <p>Pregnant women with placenta praevia confirmed by ultrasound and previous caesarean birth</p>
<b>Exclusion criteria</b>	<p>Pregnant women with contraindications to MRI, including pacemaker and cochlear implants, and claustrophobia</p>
<b>Patient characteristics</b>	<p>N=30 (PAS: N=8; No PAS: N=22)</p> <p>Mean age in years (SD):  PAS: 25.6 (NR)  No PAS: not reported</p> <p>Gestational age in weeks at birth (range):  PAS: 26-42  No PAS: not reported</p> <p>Gestational age at diagnosis of PAS: not reported</p> <p>Parity (range):  PAS: 1-2  No PAS: not reported</p> <p>Placenta praevia:  PAS: N=7  No PAS: not reported</p> <p>Previous caesarean birth (range):  PAS: 1-2  No PAS: not reported</p> <p>Previous dilatation and curettage: N=2</p> <p>Previous myomectomy: N=1</p> <p>BMI: not reported</p>



<b>Index test(s)</b>	<ol style="list-style-type: none"> <li>1. Grey scale ultrasound plus colour-flow or power Doppler ultrasound (transabdominal or transvaginal)</li> <li>2. MRI without contrast (1.5-T MRI without contrast)</li> </ol> <p>Ultrasound and MRI examinations were performed by two radiologists (9 and 12 years of experience in radiology).</p> <p>Ultrasound features for diagnosis of PAS were placenta praevia, irregular bladder wall with extensive associated vascularity, placental lacunae with turbulent flow, absence of retroplacental clear spaces, gap in the retroplacental blood flow, and myometrial thinning (&lt;1 mm or loss of visualisation of the myometrium).</p> <p>MRI features for diagnosis of PAS were placenta praevia, heterogeneous signal intensity within placenta, uterine bulging, dark intraplacental bands on T2-WI, focal interruptions in the myometrial wall, abnormal disorganised placental vascularity, tenting of the bladder, and direct visualisation invasion of surrounding structures by the placental tissue.</p> <p>Ultrasound and MRI scans were performed at first presentation of participants to the hospital (after 20 weeks).</p>
<b>Reference standard(s)</b>	Operative findings and/or pathology reports
<b>Duration of follow-up</b>	Not reported
<b>Sources of funding</b>	Not reported
<b>Target condition</b>	PAS
<b>Results</b>	<p>Outcome: diagnosis of PAS (accreta, increta, and percreta)*</p> <p>Grey scale ultrasound plus colour-flow or power Doppler ultrasound (N=30): TP 7; FP 3; FN 1; TN 19</p> <p>MRI without contrast (N=30): TP 6; FP 5; FN 2; TN 17</p> <p>2x2 tables were checked against sensitivity and specificity presented as there was discrepancy in raw data.</p> <p>*The study included N=3 with accreta, N=4 with increta, and N=1 with percreta, and N=7 with PAS had hysterectomy.</p>

FN: false negative; FP: false positive; MRI: magnetic resonance imaging; NR: not reported; PAS: placenta accreta spectrum; SD: standard deviation; TN: true negative; TP: true positive; T2-WI: T2 weighted image; 1.5-T: 1.5 Tesla

### Critical appraisal - NGA Critical appraisal - QUADAS-2

Section	Question	Answer
Patient selection: risk of bias	Could the selection of patients have introduced bias?	Low
Patient selection: applicability	Are there concerns that included patients do not match the review question?	Unclear <i>(No information on the total number of participants with a previous uterus intervention and placenta praevia)</i>
Index tests: risk of bias	Could the conduct or interpretation of the index test have introduced bias?	Low
Index tests: applicability	Are there concerns that the index test, its conduct, or interpretation differ from the review question?	Low
Reference standard: risk of bias	Could the reference standard, its conduct, or its interpretation have introduced bias?	Low
Reference standard: applicability	Is there concern that the target condition as defined by the reference standard does not match the review question?	Low
Flow and timing: risk of bias	Could the patient flow have introduced bias?	Low

QUADAS: *Quality Assessment of Diagnostic Accuracy Studies*

### Shweel, 2012

**Bibliographic Reference** Shweel, M.A.G.; El Ameen, N.F.; Ibrahiem, M.A.; Kotib, A.; Placenta accreta in women with prior uterine surgery: Diagnostic accuracy of Doppler ultrasonography and MRI; Egyptian Journal of Radiology and Nuclear Medicine; 2012; vol. 43 (no. 3); 473-480

### Study details

<b>Country/ies where study was carried out</b>	Egypt
<b>Study type</b>	Prospective cohort study
<b>Study dates</b>	January 2009 - October 2011
<b>Inclusion criteria</b>	Pregnant women with abnormal placental position (placenta praevia or low-lying placenta) and one of the grey scale ultrasound features that suspects PAS (placental lacunae, thinning or disruption of hyperechoic serosa-bladder interface, and loss of the retroplacental sonolucent zone)
<b>Exclusion criteria</b>	Not reported
<b>Patient characteristics</b>	<p>N=28</p> <p>Mean age in years at diagnosis (SD): 33.2 (NR)</p> <p>Gestational age in weeks at birth (range): 35-37</p> <p>Gestational age at diagnosis of placenta praevia or low-lying placenta: not reported</p> <p>Parity:</p> <p>Parity 1: N=5</p> <p>Parity 2: N=7</p> <p>Parity 3: N=11</p> <p>Parity 4: N=5</p> <p>Placenta praevia: N=7</p> <p>Low-lying placenta: N=21</p> <p>Previous caesarean birth: N=23</p> <p>Previous uterine curettage: N=3</p> <p>Previous myomectomy: N=2</p>

	BMI: not reported
<b>Index test(s)</b>	<ol style="list-style-type: none"> <li>1. Colour-flow Doppler ultrasound (transabdominal or transvaginal)</li> <li>2. MRI without contrast (1.0-T MRI without contrast)</li> </ol> <p>The clinical data were obtained by referral obstetricians, but no further information on the study personnel who performed ultrasound and MRI examinations was provided.</p> <p>Colour-flow Doppler ultrasound features for diagnosis of PAS were placental lacunae with turbulent blood flow pattern, gap in the myometrial blood flow and hypervascular serosa-bladder interface or dilated vessels over peripheral subplacental zone.</p> <p>MRI features for diagnosis of PAS were placental heterogeneous signal, uterine wall bulging, dark intraplacental bands on T2-WI, focal interruptions in myometrial wall, tenting of the bladder, and invasion of surrounding structures.</p> <p>The study did not specify timing of Doppler and MRI scans.</p>
<b>Reference standard(s)</b>	Operative findings at caesarean section with pathology reports
<b>Duration of follow-up</b>	Not reported
<b>Sources of funding</b>	Not reported
<b>Target condition</b>	PAS
<b>Results</b>	<p>Outcome: diagnosis of PAS*</p> <p>Colour-flow Doppler ultrasound (N=28)**: TP 10; FP 5; FN 1; TN 12</p> <p>MRI without contrast (N=28): TP 10; FP 4; FN 1; TN 13</p> <p>*N=11 had PAS, but the study did not specify type of PAS disorders and whether participants had hysterectomy.</p> <p>**2x2 table was checked against sensitivity and specificity presented as there was discrepancy in raw data</p>

FN: false negative; FP: false positive; MRI: magnetic resonance imaging; NR: not reported; PAS: placenta accreta spectrum; SD: standard deviation; TN: true negative; TP: true positive; T2-WI: T2 weighted image; 1.0-T: 1.0 Tesla

### Critical appraisal - NGA Critical appraisal - QUADAS-2

Section	Question	Answer
Patient selection: risk of bias	Could the selection of patients have introduced bias?	Unclear (Case-control design was avoided, but exclusion criteria not provided)
Patient selection: applicability	Are there concerns that included patients do not match the review question?	Low
Index tests: risk of bias	Could the conduct or interpretation of the index test have introduced bias?	Low
Index tests: applicability	Are there concerns that the index test, its conduct, or interpretation differ from the review question?	Low
Reference standard: risk of bias	Could the reference standard, its conduct, or its interpretation have introduced bias?	Low
Reference standard: applicability	Is there concern that the target condition as defined by the reference standard does not match the review question?	Low
Flow and timing: risk of bias	Could the patient flow have introduced bias?	Low

QUADAS: *Quality Assessment of Diagnostic Accuracy Studies*

### UI Hassan, 2020

**Bibliographic Reference** UI Hassan, I.; Ishaq, B.; Nosheen, A.; Role of magnetic resonance imaging (MRI) in detecting abnormal placentation in suspected patients; Pakistan Journal of Medical and Health Sciences; 2020; vol. 14 (no. 3); 1049-1051

### Study details

<b>Country/ies where study was carried out</b>	Pakistan
<b>Study type</b>	Prospective cohort study
<b>Study dates</b>	January 2019 - September 2020
<b>Inclusion criteria</b>	Pregnant women aged 25 to 40 years in the second or third trimester with risk factors of PAS, including previous caesarean birth, placenta praevia and advanced maternal age, and suspected PAS findings on ultrasound
<b>Exclusion criteria</b>	Pregnant women with artificial metallic structures, including pacemaker and prosthetic heart valve, and claustrophobia
<b>Patient characteristics</b>	<p>N=60</p> <p>Mean age in years (SD): 31.2 (NR)</p> <p>Mean gestational age in weeks (SD): 33.5 (NR)</p> <p>Gestational age at diagnosis of placenta praevia or low-lying placenta: second or third trimester</p> <p>Placenta praevia: N=58</p> <p>Low-lying placenta: N=2</p> <p>Parity: not reported</p> <p>BMI: not reported</p> <p>Participants with suspected PAS findings on ultrasound in the second and third trimester were included and underwent MRI examination.</p>
<b>Index test(s)</b>	<p>MRI (unspecified type*, 1.5-T MRI)</p> <p>MRI features for diagnosis of PAS were placental heterogeneity, invasion of bladder, dark intraplacental bands, and uterine bulging.</p>

	The study did not report information on the study personnel who performed MRI examination and timing of MRI scan. *The study did not specify whether MRI with or without contrast was used.
<b>Reference standard(s)</b>	Operative findings with or without histopathology reports
<b>Duration of follow-up</b>	Not reported* *Participants were followed up till delivery, but the exact duration of follow up was not reported.
<b>Sources of funding</b>	Not reported
<b>Target condition</b>	PAS
<b>Results</b>	Outcome: diagnosis of PAS (accreta, increta, and percreta)* MRI (unspecified type) (N=60): TP 21; FP 2; FN 2; TN 35 2x2 table was checked against specificity as there was discrepancy in the data. *The study included N=15 with accreta, N=6 with increta, and N=2 with percreta. The study did not specify whether participants had hysterectomy.

FN: false negative; FP: false positive; MRI: magnetic resonance imaging; NR: not reported; PAS: placenta accreta spectrum; SD: standard deviation; TN: true negative; TP: true positive; 1.5-T: 1.5 Tesla

### Critical appraisal - NGA Critical appraisal - QUADAS-2

Section	Question	Answer
Patient selection: risk of bias	Could the selection of patients have introduced bias?	Low
Patient selection: applicability	Are there concerns that included patients do not match the review question?	Unclear (All participants had placenta praevia or low-lying placenta, but no

Section	Question	Answer
		<i>information on the total number of participants with a previous uterus intervention)</i>
Index tests: risk of bias	Could the conduct or interpretation of the index test have introduced bias?	Low
Index tests: applicability	Are there concerns that the index test, its conduct, or interpretation differ from the review question?	Low
Reference standard: risk of bias	Could the reference standard, its conduct, or its interpretation have introduced bias?	Low
Reference standard: applicability	Is there concern that the target condition as defined by the reference standard does not match the review question?	Low
Flow and timing: risk of bias	Could the patient flow have introduced bias?	Low

QUADAS: *Quality Assessment of Diagnostic Accuracy Studies*



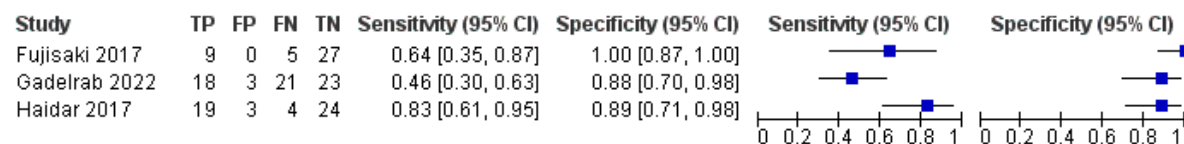
## Appendix E Forest plots

### Forest plots for review question: What is the accuracy of imaging techniques for diagnosis of a placenta accreta spectrum (PAS) in pregnant women who have had a previous caesarean birth and are currently diagnosed with placenta praevia?

This section includes forest plots only for outcomes that are meta-analysed. Outcomes from single studies are not presented here; the quality assessment for such outcomes is provided in the GRADE profiles in appendix F.

#### Ultrasound for diagnosis of PAS

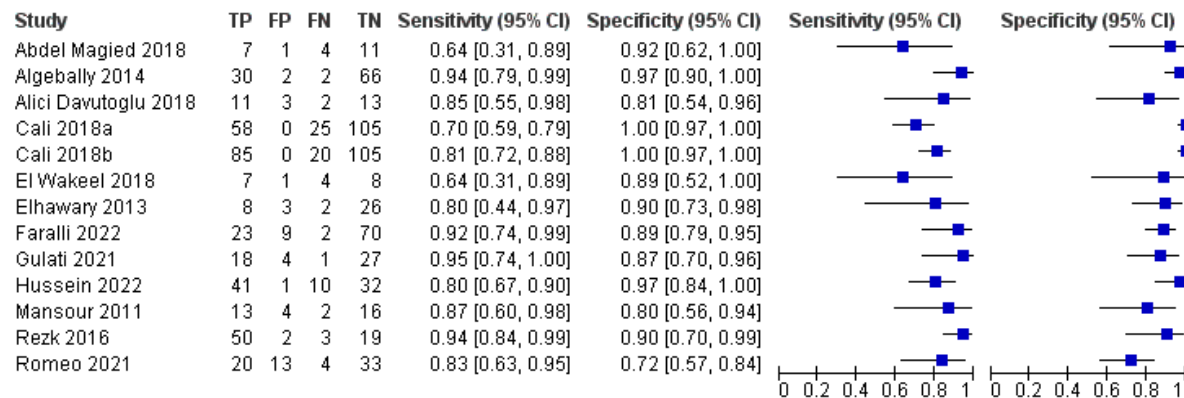
**Figure 2: Grey scale ultrasound for diagnosis of PAS (transabdominal or/and transvaginal; timing of scan: after 20 weeks in Fujisaki 2017 and after 28 weeks to 30.7 weeks in 2 studies; first and second scans)**



We used the definitions of first scan (around 20 weeks) and second scan (around 28 weeks) for PAS as in the protocol.

CI: confidence interval; FN: false negative; FP: false positive; PAS: placenta accreta spectrum; TN: true negative; TP: true positive

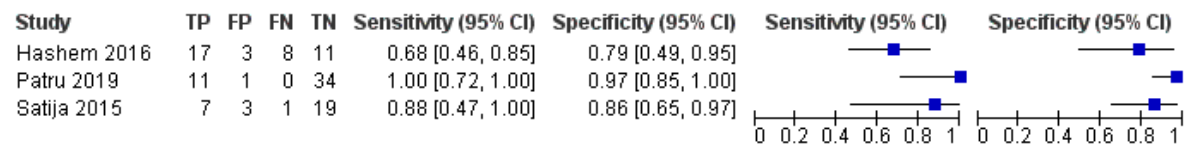
**Figure 3: Grey scale ultrasound plus colour-flow Doppler ultrasound for diagnosis of PAS (transabdominal and/or transvaginal or transabdominal and translabial or unspecified approach; timing of scan: 11 to 14 weeks in Cali 2018a, second and third trimester in Cali 2018b, 28 to 37 weeks in 7 studies and NR in 4 studies; first and second scans)**



We used the definitions of first scan (around 20 weeks) and second scan (around 28 weeks) for PAS as in the protocol.

CI: confidence interval; FN: false negative; FP: false positive; NR: not reported; PAS: placenta accreta spectrum; TN: true negative; TP: true positive

**Figure 4: Grey scale ultrasound plus colour-flow or power Doppler ultrasound (transabdominal and/or transvaginal or transabdominal, transvaginal and translabial; timing of scan: after 20 weeks in Satija 2015, 25 to 37 weeks in Hashem 2016 and NR in 1 study; first and second scans)**



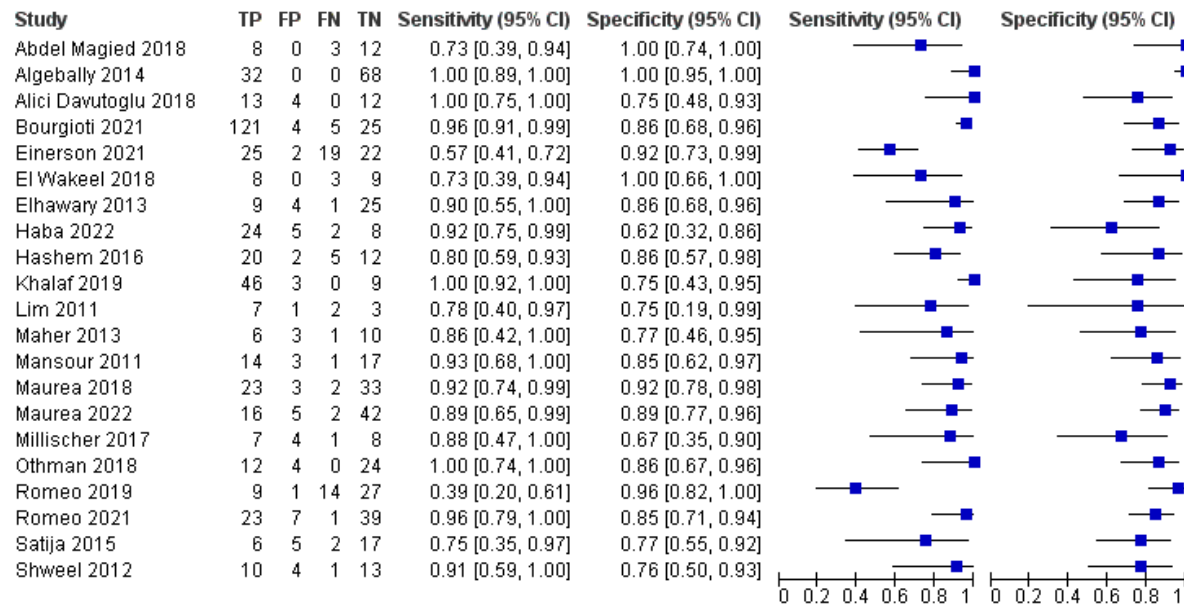
Patru 2019 stated that two-dimensional (2D) grey scale ultrasound was used.

We used the definitions of first scan (around 20 weeks) and second scan (around 28 weeks) for PAS as in the protocol.

CI: confidence interval; FN: false negative; FP: false positive; NR: not reported; PAS: placenta accreta spectrum; TN: true negative; TP: true positive

## MRI for diagnosis of PAS

**Figure 5: MRI without contrast (timing of scan: second or third trimester in Einerson 2021, after 20 weeks in Satija 2015, 24 to 38 weeks in 11 studies and NR in 8 studies; first and second scans)**



We used the definitions of first scan (around 20 weeks) and second scan (around 28 weeks) for PAS as in the protocol.

CI: confidence interval; FN: false negative; FP: false positive; MRI: magnetic resonance imaging; NR: not reported; PAS: placenta accreta spectrum; TN: true negative; TP: true positive

## Appendix F GRADE tables

**GRADE tables for review question: What is the accuracy of imaging techniques for diagnosis of a placenta accreta spectrum (PAS) in pregnant women who have had a previous caesarean birth and are currently diagnosed with placenta praevia?**

**Table 5: Ultrasound for diagnosis of PAS**

No of studies	Study details	No of participants	Diagnostic accuracy estimate (95% CI)	Risk of bias	Inconsistency	Indirectness	Imprecision	Quality of evidence
<b>Grey scale ultrasound (transabdominal or/and transvaginal; timing of scan: after 20 weeks in Fujisaki 2017 and after 28 weeks to 30.7 weeks in 2 studies; first and second scans)</b>								
3 (Fujisaki 2017, Gadelrab 2022, Haidar 2017)	Population: Pregnant women with placenta praevia or low-lying placenta and previous caesarean birth or uterus surgery  Reference standard: Operative findings with histopathological results or post caesarean birth examination with histology	N=156	Sensitivity: 0.65 (0.27 to 0.92)	No serious	Serious <sup>1</sup>	Serious <sup>2</sup>	Very serious <sup>3</sup>	<b>VERY LOW</b>
			Specificity: 0.92 (0.71 to 0.99)	No serious	No serious	Serious <sup>2</sup>	Serious <sup>4</sup>	<b>LOW</b>
<b>Colour-flow Doppler ultrasound (unspecified approach in Naghshineh 2015 and transabdominal/transvaginal in Shweel 2012; timing of scan: NR)</b>								
1 (Naghshineh 2015)	Population: Pregnant women with placenta praevia and previous caesarean birth or curettage  Reference standard: Post caesarean birth examination with histology	N=50	Sensitivity: 0.83 (0.52 to 0.98)	No serious	No serious	Serious <sup>5</sup>	Serious <sup>4</sup>	<b>LOW</b>
			Specificity: 0.79 (0.63 to 0.905)	No serious	No serious	Serious <sup>5</sup>	Serious <sup>4</sup>	<b>LOW</b>
1 (Shweel 2012)	Population: Pregnant women with placenta praevia or low-lying placenta and previous caesarean birth or uterine intervention (curettage or myomectomy)	N=28	Sensitivity: 0.91 (0.59 to 1.00)	No serious	No serious	No serious	Serious <sup>4</sup>	<b>MODERATE</b>
			Specificity: 0.71 (0.44 to 0.897)	No serious	No serious	No serious	Serious <sup>4</sup>	<b>MODERATE</b>

No of studies	Study details	No of participants	Diagnostic accuracy estimate (95% CI)	Risk of bias	Inconsistency	Indirectness	Imprecision	Quality of evidence
	Reference standard: Operative findings with histopathological results							
<b>3D multislice view Doppler ultrasound (transabdominal; timing of scan: after 28 weeks; second scan)</b>								
1 (Gadelrab 2022)	Population: Pregnant women with placenta praevia or low-lying placenta and previous caesarean birth or uterine curettage  Reference standard: Operative findings with histopathological results	N=65	Sensitivity: 0.87 (0.73 to 0.96)	No serious	No serious	No serious	Serious <sup>4</sup>	<b>MODERATE</b>
			Specificity: 0.96 (0.80 to 1.00)	No serious	No serious	No serious	Serious <sup>4</sup>	<b>MODERATE</b>
<b>3D tomographic ultrasound imaging (3D-TUI) (transabdominal and transvaginal; timing of scan: NR)</b>								
1 (Alafy 2021)	Population: Pregnant women with placenta praevia and previous caesarean birth  Reference standard: Operative findings with pathology reports	N=90	Sensitivity: 1.00 (0.93 to 1.00)	No serious	No serious	Serious <sup>5</sup>	No serious	<b>MODERATE</b>
			Specificity: 1.00 (0.903 to 1.00)	No serious	No serious	Serious <sup>5</sup>	No serious	<b>MODERATE</b>
<b>3D power Doppler ultrasound plus 3D tomographic ultrasound imaging (3D-TUI) (transabdominal and transvaginal; timing of scan: NR)</b>								
1 (Alafy 2021)	Population: Pregnant women with placenta praevia and previous caesarean birth  Reference standard: Operative findings with pathology reports	N=90	Sensitivity: 1.00 (0.93 to 1.00)	No serious	No serious	Serious <sup>5</sup>	No serious	<b>MODERATE</b>
			Specificity: 1.00 (0.903 to 1.00)	No serious	No serious	Serious <sup>5</sup>	No serious	<b>MODERATE</b>
<b>Doppler ultrasound (unspecified type; timing of scan: NR)</b>								
1 (Akhtar 2020)		N=27	Sensitivity: 0.92 (0.62 to 1.00)	No serious	No serious	No serious	Serious <sup>4</sup>	<b>MODERATE</b>

No of studies	Study details	No of participants	Diagnostic accuracy estimate (95% CI)	Risk of bias	Inconsistency	Indirectness	Imprecision	Quality of evidence
	Population: Pregnant women with placenta praevia and previous caesarean birth  Reference standard: Operative findings at caesarean section		Specificity: 0.60 (0.32 to 0.84)	No serious	No serious	No serious	Serious <sup>4</sup>	<b>MODERATE</b>
<b>Grey scale ultrasound plus colour-flow Doppler ultrasound (transabdominal and/or transvaginal or transabdominal and translabial or unspecified approach; timing of scan: 11 to 14 weeks in Cali 2018a, second and third trimester in Cali 2018b, 28 to 37 weeks in 7 studies and NR in 4 studies; first and second scans)</b>								
13 (Abdel Magied 2018, Algebally 2014, Alici Davutoglu 2018, Cali 2018a, Cali 2018b, El Wakeel 2018, Elhawary 2013, Faralli 2022, Gulati 2021, Hussein 2022, Mansour 2011, Rezk 2016, Romeo 2021)	Population: Pregnant women with placenta praevia or low-lying placenta and previous caesarean birth or uterus surgery  Reference standard: Operative findings with or without histopathological results or post caesarean birth examination with histology	N=1026	Sensitivity: 0.85 (0.77 to 0.91)	No serious	No serious	No serious	Serious <sup>4</sup>	<b>MODERATE</b>
			Specificity: 0.94 (0.87 to 0.97)	No serious	No serious	No serious	Serious <sup>4</sup>	<b>MODERATE</b>
<b>Grey scale ultrasound plus power Doppler ultrasound (transabdominal and transvaginal; timing of scan: NR)</b>								
1 (Haba 2022)	Population: Pregnant women with placenta praevia and previous caesarean birth  Reference standard: Post caesarean birth examination with histology	N=39	Sensitivity: 0.85 (0.65 to 0.96)	No serious	No serious	No serious	Serious <sup>4</sup>	<b>MODERATE</b>
			Specificity: 0.92 (0.64 to 1.00)	No serious	No serious	No serious	Serious <sup>4</sup>	<b>MODERATE</b>
<b>Grey scale ultrasound (2D) plus colour-flow and power Doppler ultrasounds (transabdominal; timing of scan: NR)</b>								
1 (Lim 2011)	Population: Pregnant women with placenta praevia and previous caesarean birth or dilatation and curettage	N=13	Sensitivity: 0.67 (0.30 to 0.93)	No serious	No serious	Serious <sup>2</sup>	Very serious <sup>3</sup>	<b>VERY LOW</b>
			Specificity: 0.50 (0.07 to 0.93)	No serious	No serious	Serious <sup>2</sup>	Very serious <sup>3</sup>	<b>VERY LOW</b>

No of studies	Study details	No of participants	Diagnostic accuracy estimate (95% CI)	Risk of bias	Inconsistency	Indirectness	Imprecision	Quality of evidence
	Reference standard: Operative findings with histology reports							
<b>Grey scale ultrasound plus colour-flow or power Doppler ultrasound (transabdominal and/or transvaginal or transabdominal, transvaginal and translabial; timing of scan: after 20 weeks in Satija 2015, 25 to 37 weeks in Hashem 2016 and NR in 1 study; first and second scans)</b>								
3 (Hashem 2016, Patru 2019, Satija 2015)	Population: Pregnant women with placenta praevia or low-lying placenta and previous caesarean birth or uterus surgery  Reference standard: Operative findings with or without histology reports	N=115	Sensitivity: 0.83 (0.47 to 0.98)	No serious	No serious	No serious	Very serious <sup>3</sup>	<b>LOW</b>
			Specificity: 0.91 (0.61 to 0.99)	No serious	No serious	No serious	Serious <sup>4</sup>	<b>MODERATE</b>
<b>Grey scale ultrasound plus colour-flow and 3D power Doppler ultrasounds (transabdominal and transvaginal in both studies, timing of scan: NR in di Pasquo 2020 and 12 to 34 weeks in Panaiotova 2019; first and second scans)</b>								
1 (di Pasquo 2020)	Population: Pregnant women with placenta praevia or low-lying placenta and previous caesarean birth or uterus surgery  Reference standard: Operative findings with or without histology reports	N=332	Sensitivity: 0.47 (0.39 to 0.54)	No serious	No serious	Serious <sup>2</sup>	Serious <sup>4</sup>	<b>LOW</b>
			Specificity: 0.94 (0.89 to 0.97)	No serious	No serious	Serious <sup>2</sup>	Serious <sup>4</sup>	<b>LOW</b>
1 (Panaiotova 2019)	Population: Pregnant women with placenta praevia or low-lying placenta and previous caesarean birth or uterus surgery  Reference standard: Post caesarean birth examination with histology	N=48	Sensitivity: 1.00 (0.75 to 1.00)	No serious	No serious	No serious	Serious <sup>4</sup>	<b>MODERATE</b>
			Specificity: 0.97 (0.85 to 1.00)	No serious	No serious	No serious	Serious <sup>4</sup>	<b>MODERATE</b>
<b>Grey scale ultrasound plus colour-flow Doppler ultrasound integrated by pulse wave spectral Doppler (transabdominal and transvaginal; timing of scan 30 to 38 weeks; second scan)</b>								

No of studies	Study details	No of participants	Diagnostic accuracy estimate (95% CI)	Risk of bias	Inconsistency	Indirectness	Imprecision	Quality of evidence
1 (Romeo 2019)	Population: Pregnant women with placenta praevia and previous caesarean birth  Reference standard: Post caesarean birth examination with histology	N=51	Sensitivity: 0.65 (0.43 to 0.84)	No serious	No serious	Serious <sup>2</sup>	Serious <sup>4</sup>	<b>LOW</b>
			Specificity: 0.82 (0.63 to 0.94)	No serious	No serious	Serious <sup>2</sup>	Serious <sup>4</sup>	<b>LOW</b>

CI: confidence interval; NR: not reported; PAS: placenta accreta spectrum

We used the definitions of first scan (around 20 weeks) and second scan (around 28 weeks) for PAS as in the protocol.

<sup>1</sup> Serious heterogeneity unexplained by subgroup analysis. Random effects analysis used in Winbugs analysis. Sub-group analysis could not be conducted as there was no sufficient information on sub-groups from the studies.

<sup>2</sup> Population is indirect as >10% of participants were without previous caesarean birth or uterine intervention or placenta praevia

<sup>3</sup> 95% CI crosses 2 decision making thresholds (0.50 and 0.90)

<sup>4</sup> 95% CI crosses 1 decision making threshold (0.50 and 0.90)

<sup>5</sup> Total number of participants with placenta praevia or previous caesarean birth or previous uterine intervention was unclear

**Table 6: MRI for diagnosis of PAS**

No of studies	Study details	No of participants	Diagnostic accuracy estimate (95% CI)	Risk of bias	Inconsistency	Indirectness	Imprecision	Quality of evidence
<b>MRI without contrast (timing of scan: second or third trimester in Einerson 2021, after 20 weeks in Satija 2015, 24 to 38 weeks in 11 studies and NR in 8 studies; first and second scans)</b>								
21 (Abdel Magied 2018, Algebally 2014, Alici Davutoglu 2018, Bourgioti 2021, Einerson 2021, El Wakeel 2018, Elhawary 2013, Haba 2022, Hashem 2016, Khalaf 2019, Lim 2011, Maher 2013, Mansour 2011, Maurea 2018, Maurea 2022, Millischer 2017, Othman 2018, Romeo 2019, Romeo 2021, Satija 2015, Shweel 2012)	Population: Pregnant women with placenta praevia or low-lying placenta and previous caesarean birth or uterus surgery  Reference standard: Operative findings with or without histopathological results or post caesarean birth examination with histology	N=1003	Sensitivity: 0.88 (0.82 to 0.93)	No serious	No serious	No serious	Serious <sup>1</sup>	<b>MODERATE</b>
			Specificity: 0.87 (0.81 to 0.91)	No serious	No serious	No serious	Serious <sup>1</sup>	<b>MODERATE</b>
<b>MRI with contrast (timing of scan: NR in Millischer 2017 and 32 to 34 weeks in Rezk 2016; second scan)</b>								



No of studies	Study details	No of participants	Diagnostic accuracy estimate (95% CI)	Risk of bias	Inconsistency	Indirectness	Imprecision	Quality of evidence
1 (Millischer 2017)	Population: Pregnant women with placenta praevia and previous caesarean birth  Reference standard: Operative findings with or without histopathological results	N=20	Sensitivity: 1.00 (0.63 to 1.00)	No serious	No serious	No serious	Serious <sup>1</sup>	<b>MODERATE</b>
			Specificity: 0.67 (0.35 to 0.90)	No serious	No serious	No serious	Very serious <sup>2</sup>	<b>LOW</b>
1 (Rezk 2016)	Population: Pregnant women with placenta praevia and previous caesarean birth or uterus surgery  Reference standard: Operative findings with histopathological results	N=74	Sensitivity: 0.96 (0.87 to 1.00)	No serious	No serious	No serious	Serious <sup>1</sup>	<b>MODERATE</b>
			Specificity: 0.86 (0.64 to 0.97)	No serious	No serious	No serious	Serious <sup>1</sup>	<b>MODERATE</b>
<b>MRI (unspecified type; timing of scan: third trimester in Faralli 2022, before 38 weeks in Fiocchi 2020 and NR in Mathur 2019 and UI Hassan 2020; second scan)</b>								
1 (Faralli 2022)	Population: Pregnant women with placenta praevia and previous caesarean birth or uterine curettage  Reference standard: Operative findings with histology reports	N=104	Sensitivity: 0.88 (0.69 to 0.97)	No serious	No serious	Serious <sup>3</sup>	Serious <sup>1</sup>	<b>LOW</b>
			Specificity: 0.89 (0.79 to 0.95)	No serious	No serious	Serious <sup>3</sup>	Serious <sup>1</sup>	<b>LOW</b>
1 (Fiocchi 2020)	Population: Pregnant women with placenta praevia and previous uterus surgery	N=26	Sensitivity: 1.00 (0.75 to 1.00)	No serious	No serious	Serious <sup>4</sup>	Serious <sup>1</sup>	<b>LOW</b>
			Specificity: 0.92 (0.64 to 1.00)	No serious	No serious	Serious <sup>4</sup>	Serious <sup>1</sup>	<b>LOW</b>

No of studies	Study details	No of participants	Diagnostic accuracy estimate (95% CI)	Risk of bias	Inconsistency	Indirectness	Imprecision	Quality of evidence
	Reference standard: Operative findings with histology reports							
1 (Mathur 2019)	Population: Pregnant women with placenta praevia and previous caesarean birth  Reference standard: Operative findings with histopathological reports	N=80	Sensitivity: 0.67 (0.505 to 0.80)	No serious	No serious	Serious <sup>5</sup>	No serious	<b>MODERATE</b>
			Specificity: 1.00 (0.91 to 1.00)	No serious	No serious	Serious <sup>5</sup>	No serious	<b>MODERATE</b>
1 (Ul Hassan 2020)	Population: Pregnant women with placenta praevia or low-lying placenta and previous caesarean birth  Reference standard: Operative findings with or without histopathology reports	N=60	Sensitivity: 0.91 (0.72 to 0.99)	No serious	No serious	Serious <sup>4</sup>	Serious <sup>1</sup>	<b>LOW</b>
			Specificity: 0.95 (0.82 to 0.99)	No serious	No serious	Serious <sup>4</sup>	Serious <sup>1</sup>	<b>LOW</b>

CI: confidence interval; NR: not reported; MRI: magnetic resonance imaging; PAS: placenta accreta spectrum

We used the definitions of first scan (around 20 weeks) and second scan (around 28 weeks) for PAS as in the protocol.

<sup>1</sup> 95% CI crosses 1 decision making threshold (0.50 and 0.90)

<sup>2</sup> 95% CI crosses 2 decision making thresholds (0.50 and 0.90)

<sup>3</sup> Population is indirect as >10% of participants were without previous caesarean birth or uterine intervention

<sup>4</sup> Total number of participants with placenta praevia or previous caesarean birth or previous uterine intervention was unclear

<sup>5</sup> MRI feature for diagnosis of PAS was unclear

**Table 7: Ultrasound with or without MRI for diagnosis of PAS**

No of studies	Study details	No of participants	Diagnostic accuracy estimate (95% CI)	Risk of bias	Inconsistency	Indirectness	Imprecision	Quality of evidence
<b>Grey scale ultrasound plus colour-flow Doppler ultrasound (unspecified approach) with or without MRI (timing of scan: NR; ultrasound was performed before MRI)*</b>								
1 (Coutinho 2021)	Population: Pregnant women with placenta praevia or low-lying placenta and previous caesarean birth or uterus surgery  Reference standard: Operative findings with or without histopathological reports	N=173	Sensitivity: 0.97 (0.905 to 0.99)	No serious	No serious	Serious <sup>1</sup>	No serious	<b>MODERATE</b>
			Specificity: 0.99 (0.94 to 1.00)	No serious	No serious	Serious <sup>1</sup>	No serious	<b>MODERATE</b>
<b>Ultrasound (sonography including Doppler interrogation; transvaginal) with or without MRI (timing of scan: NR; ultrasound was performed before MRI)**</b>								
1 (Reeder 2022)	Population: Pregnant women with placenta praevia and previous uterus surgery  Reference standard: Operative findings with histopathological reports	N=80	Sensitivity: 0.88 (0.76 to 0.95)	Serious <sup>2</sup>	No serious	Serious <sup>3</sup>	Serious <sup>4</sup>	<b>VERY LOW</b>
			Specificity: 0.80 (0.61 to 0.92)	Serious <sup>2</sup>	No serious	Serious <sup>3</sup>	Serious <sup>4</sup>	<b>VERY LOW</b>

CI: confidence interval; NR: not reported; MRI: magnetic resonance imaging; PAS: placenta accreta spectrum

\*MRI was performed if there were ultrasound features of extrauterine invasion, but type of MRI (that is, MRI with or without contrast) was unspecified

\*\*N=40 had adjunct MRI to evaluate the extent and topography of trophoblast invasion and for diagnosis of PAS, but type of MRI (that is, MRI with or without contrast) was unspecified

<sup>1</sup> MRI feature for diagnosis of PAS was unclear

<sup>2</sup> Serious risk of bias in the evidence contributing to the outcomes as per QUADAS-2

<sup>3</sup> Population is indirect as >10% of participants were without placenta praevia

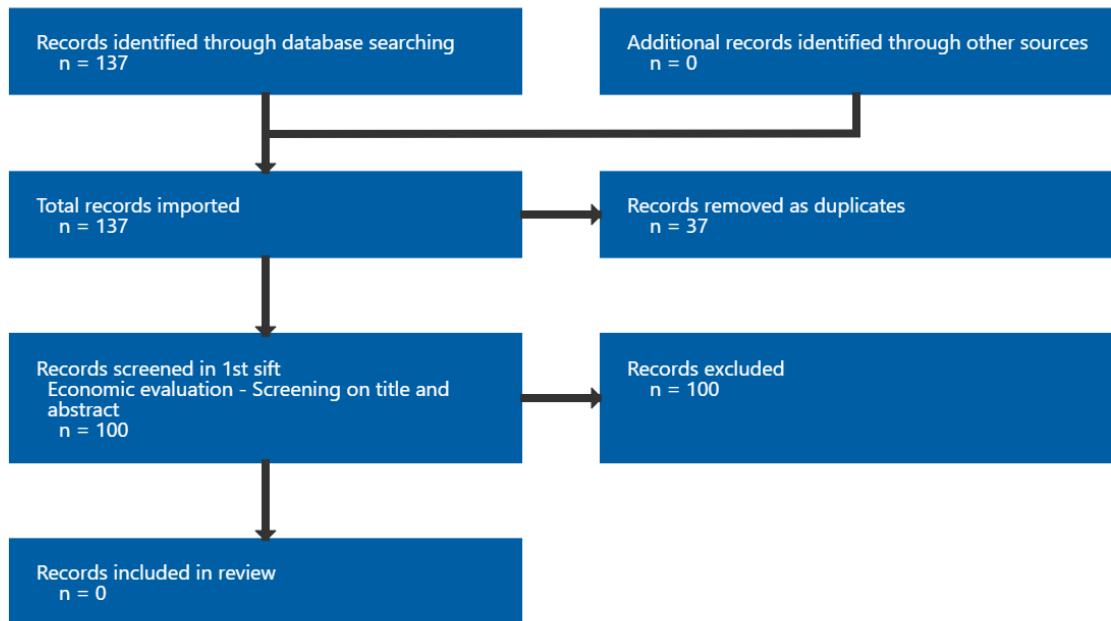
<sup>4</sup> 95% CI crosses 1 decision making threshold (0.50 and 0.90)

## Appendix G Economic evidence study selection

**Study selection for: What is the accuracy of imaging techniques for diagnosis of a placenta accreta spectrum (PAS) in pregnant women who have had a previous caesarean birth and are currently diagnosed with placenta praevia?**

No economic evidence was identified for this review as indicated in Figure 6 below.

**Figure 6: Study selection flow chart**



## **Appendix H Economic evidence tables**

**Economic evidence tables for review question: What is the accuracy of imaging techniques for diagnosis of a placenta accreta spectrum (PAS) in pregnant women who have had a previous caesarean birth and are currently diagnosed with placenta praevia?**

No economic evidence was identified for this review.

## **Appendix I Economic model**

**Economic model for review question: What is the accuracy of imaging techniques for diagnosis of a placenta accreta spectrum (PAS) in pregnant women who have had a previous caesarean birth and are currently diagnosed with placenta praevia?**

No economic analysis was conducted for this review question.

## Appendix J Excluded studies

**Excluded studies for review question: What is the accuracy of imaging techniques for diagnosis of a placenta accreta spectrum (PAS) in pregnant women who have had a previous caesarean birth and are currently diagnosed with placenta praevia?**

### Excluded diagnostic studies

**Table 8: Excluded studies and reasons for their exclusion**

Study	Code [Reason]
<a href="#">Abdel Moniem, Alaa M, Ibrahim, Ahmed, Akl, Sherif A et al. (2015) Accuracy of three-dimensional multislice view Doppler in diagnosis of morbid adherent placenta.</a> Journal of the Turkish German Gynecological Association 16(3): 126-36	- Outcome not relevant to this review protocol <i>Diagnostic accuracy of individual parameters but not overall diagnostic accuracy of their combination was reported</i>
<a href="#">Abu Hashim, Hatem, Shalaby, Eman M, Hussien, Mohammed H et al. (2022) Diagnostic accuracy of the placenta accreta index for placenta accreta spectrum: A prospective study.</a> International journal of gynaecology and obstetrics: the official organ of the International Federation of Gynaecology and Obstetrics 156(1): 71-76	- Outcome not relevant to this review protocol <i>Diagnostic accuracy of individual parameter and placenta accreta index that includes non-radiological parameter (previous caesarean section) were reported</i>
<a href="#">Agarwal, S.; Agarwal, A.; Chandak, S. (2021) Role of placenta accreta index in prediction of morbidly adherent placenta: A reliability study.</a> Ultrasound 29(2): 92-99	- Index test not relevant to this review protocol <i>Placenta accreta index that includes non radiological parameter (that is, previous caesarean section) was used</i>
<a href="#">AHMAD, N., HAIDER, F., AKHTAR, F. et al. (2020) Frequency of morbidly adherent placenta in previous scar.</a> Pakistan Journal of Medical and Health Sciences 14(4): 1052-1054	- Study design not relevant to this review protocol <i>Not a diagnostic accuracy study as this cross-sectional study only investigates the risk of morbid adherent placenta in women with previous caesarean section</i>
<a href="#">Aioab, A., Gaziyeu, Z., Mikhail, S.M. et al. (2023) The value of a simple sonographic screening test for placenta accreta spectrum prediction: A case-control study.</a> Australian and New Zealand Journal of Obstetrics and Gynaecology 63(2): 228-233	- Population not relevant to this review protocol <i>Only 19% of participants had placenta praevia, and diagnosis of placenta accreta spectrum was confirmed during both caesarean and vaginal deliveries</i>
<a href="#">Aitken, Kara, Allen, Lisa, Pantazi, Sophia et al. (2016) MRI Significantly Improves Disease Staging to Direct Surgical Planning for Abnormal Invasive Placentation: A Single Centre Experience.</a> Journal of obstetrics and gynaecology Canada : JOGC = Journal d'obstetrique et gynecologie du Canada : JOGC 38(3): 246-251e1	- Population not relevant to this review protocol <i>No information on whether participants had a previous lower segment caesarean birth or uterus surgery and a low-lying placenta or placenta praevia</i>
<a href="#">Al-Khan, Abdulla, Alshowaikh, Khadija, Krishnamoorthy, Kaila et al. (2022) Pulsatile vessel at the posterior bladder wall: A new sonographic marker for placenta percreta.</a> The	- Population not relevant to this review protocol <i>Case-control study that includes study population without placenta praevia or low lying placenta</i>

Study	Code [Reason]
journal of obstetrics and gynaecology research 48(5): 1149-1156	
<a href="#">Alamo, Leonor, Anaye, Anass, Rey, Jannick et al. (2013) Detection of suspected placental invasion by MRI: do the results depend on observer' experience?.</a> European journal of radiology 82(2): e51-7	- Population not relevant to this review protocol <i>Only 12% of participants had previous caesarean birth</i>
Alchalabi, H., Lataifeh, I., Obeidat, B. et al. (2014) Morbidly adherent placenta previa in current practice: Prediction and maternal morbidity in a series of 23 women who underwent hysterectomy. Journal of Maternal-Fetal and Neonatal Medicine 27(17): 1734-1737	- Population not relevant to this review protocol <i>Only 54% of participants had previous caesarean birth</i>
<a href="#">Ali Nahra, R., Ullah, H.E., Nahra, A.R. et al. (2023) Anatomically Abnormal Placement of Placenta and its under Lying Factors Maternal Tobacco Exposure, History of Cesarean Section and Hypertension among Gravid Females Detected by Sonographically.</a> Pakistan Journal of Medical and Health Sciences 17(1): 283-285	- Study design not relevant to this review protocol <i>Not a diagnostic accuracy study as this cross-sectional study only investigates risk factors (for example, smoking) for abnormal placement of placenta</i>
<a href="#">Allwood, R X; Self, A; Collins, S L (2022) Separation sign: novel ultrasound sign for ruling out diagnosis of placenta accreta spectrum.</a> Ultrasound in Obstetrics & gynecology : the official journal of the International Society of Ultrasound in Obstetrics and Gynecology 60(3): 390-395	- Reference standard not relevant to this review protocol <i>Operative findings with or without histology reports/lab findings were not used.</i>
Ari, Sabahattin Anil, Suner, Asli, Senkaya, Ayse Rabia et al. (2023) A prospective cohort study: can advanced ultrasonography replace magnetic resonance imaging in the diagnosis of placental adhesion disorders?. Journal of perinatal medicine	- Population not relevant to this review protocol <i>Only 50% of participants had a previous caesarean birth</i>
Aryananda, Rozi Aditya, Akbar, Aldika, Wardhana, Manggala Pasca et al. (2019) New three-dimensional/four-dimensional volume rendering imaging software for detecting the abnormally invasive placenta. Journal of clinical ultrasound : JCU 47(1): 9-13	- Population not relevant to this review protocol <i>No information on whether participants had a previous lower segment caesarean birth or uterus surgery and a low-lying placenta or placenta praevia</i>
<a href="#">Awan, M.M., Shaheen, U., Noreen, A. et al. (2021) Diagnostic accuracy of doppler ultrasound in diagnosis of morbidly adherent placenta (MAP) keeping per operative diagnosis as gold standard.</a> Medical Forum Monthly 32(4): 28-32	- Population not relevant to this review protocol <i>No information on whether participants had a low-lying placenta or placenta praevia. Only 30.6% of participants had a previous lower segment caesarean birth.</i>
Ayati, Sedigheh, Leila, Leila, Pezeshkirad, Masoud et al. (2017) Accuracy of color Doppler ultrasonography and magnetic resonance imaging in diagnosis of placenta accreta: A survey of 82 cases. International journal of reproductive biomedicine 15(4): 225-230	- Population not relevant to this review protocol <i>Only 46% of participants had low lying placenta</i>



Study	Code [Reason]
<p>Azadi, A., Mousavi, S., Zare, S. et al. (2020) Peak systolic velocity of subplacental blood flow as prenatal diagnosis of placenta accreta spectrum in patients with anterior placenta previa. Crescent Journal of Medical and Biological Sciences 7(2): 279-284</p>	<p>- Outcome not relevant to this review protocol <i>Diagnostic accuracy of individual parameters but not overall diagnostic accuracy of their combination was reported</i></p>
<p><a href="#">Balcacer, Patricia, Pahade, Jay, Spektor, Michael et al. (2016) Magnetic Resonance Imaging and Sonography in the Diagnosis of Placental Invasion.</a> Journal of ultrasound in medicine : official journal of the American Institute of Ultrasound in Medicine 35(7): 1445-56</p>	<p>- Population not relevant to this review protocol <i>No information on whether participants had a previous lower segment caesarean birth or uterus surgery.</i></p>
<p>Baldassarre, Randall L, Gabe, Michael, Pretorius, Dolores H et al. (2016) Placental Sonolucencies in the First Trimester: Incidence and Clinical Significance. Ultrasound quarterly 32(1): 43-6</p>	<p>- Study design not relevant to this review protocol <i>Not a diagnostic accuracy study, and only 19% had previous caesarean section</i></p>
<p><a href="#">Ballas, Jerasimos, Pretorius, Dolores, Hull, Andrew D et al. (2012) Identifying sonographic markers for placenta accreta in the first trimester.</a> Journal of ultrasound in medicine : official journal of the American Institute of Ultrasound in Medicine 31(11): 1835-41</p>	<p>- Study design not relevant to this review protocol <i>Case series that investigates whether sonographic markers for placenta accreta may be present as early as the first trimester in participants with pathologically proven accreta.</i></p>
<p><a href="#">Bansal, S., Suri, J., Bajaj, S.K. et al. (2022) Role of Placenta Accreta Index for Diagnosis of Placenta Accreta Spectrum in High-Risk Patients.</a> Journal of Obstetrics and Gynecology of India 72(supplement1): 55-60</p>	<p>- Outcome not relevant to this review protocol <i>Diagnostic accuracy of individual parameters but not overall diagnostic accuracy of their combination was reported</i></p>
<p>Barati, M., Zargar, M., Najafian, M. et al. (2020) Predicting value of different ultrasound markers for diagnosing morbidly adherent placenta and associated complications. International Journal of Women's Health and Reproduction Sciences 8(2): 169-173</p>	<p>- Reference standard not relevant to this review protocol <i>No clear information on whether all participants had operative findings with/without histology reports/lab findings and post caesarean birth examination with histology</i></p>
<p><a href="#">Barzilay, Eran, Brandt, Benny, Gilboa, Yinon et al. (2022) Comparative analysis of ultrasound and MRI in the diagnosis of placenta accreta spectrum.</a> The journal of maternal-fetal &amp; neonatal medicine : the official journal of the European Association of Perinatal Medicine, the Federation of Asia and Oceania Perinatal Societies, the International Society of Perinatal Obstetricians 35(21): 4056-4059</p>	<p>- Population not relevant to this review protocol <i>Placenta praevia or low-lying placenta and previous caesarean birth or uterus surgery were not stated as inclusion criteria, and no information on number of participants with these conditions</i></p>
<p><a href="#">Bassetty, K.C., Vijayaselvi, R., Yadav, B. et al. (2021) Placenta accreta spectrum: Management and outcomes in a tertiary centre in India: An observational cross-sectional study.</a> Tropical Doctor 51(3): 398-403</p>	<p>- Index test not relevant to this review protocol <i>No information on whether all participants had imaging tests, and not all participants had surgery</i></p>
<p>Baumann, Hanna Elise, Pawlik, Laura Katharina Andrea, Hoesli, Irene et al. (2022) Accuracy of ultrasound for the detection of placenta accreta</p>	<p>- Population not relevant to this review protocol <i>No information on whether participants had a previous lower segment caesarean birth or uterus</i></p>

Study	Code [Reason]
spectrum in a universal screening population. International journal of gynaecology and obstetrics: the official organ of the International Federation of Gynaecology and Obstetrics	<i>surgery and a low-lying placenta or placenta praevia</i>
<a href="#">Bayramoglu Tepe, Neslihan, Gelebek Yilmaz, Feyza, Bozdog, Zehra et al. (2020) Subgroup analysis of accreta, increta and percreta cases using acoustic radiation force impulse elastography.</a> The journal of obstetrics and gynaecology research 46(5): 699-706	- Reference standard not relevant to this review protocol <i>No information on whether all participants had operative findings with/without histology reports/lab findings and post caesarean birth examination with histology, and case-control study design was used</i>
<a href="#">Berkley, Eliza M and Abuhamad, Alfred Z (2013) Prenatal diagnosis of placenta accreta: is sonography all we need?.</a> Journal of ultrasound in medicine : official journal of the American Institute of Ultrasound in Medicine 32(8): 1345-50	- Study design not relevant to this review protocol <i>Narrative review</i>
<a href="#">Bhatia, A, Palacio, M, Wright, A M et al. (2022) Lower uterine segment scar assessment at 11-14 weeks' gestation to screen for placenta accreta spectrum in women with prior Cesarean delivery.</a> Ultrasound in obstetrics & gynecology : the official journal of the International Society of Ultrasound in Obstetrics and Gynecology 59(1): 40-48	- Population not relevant to this review protocol <i>Only 23% of participants had low laying placenta, and no information on reference test provided</i>
<a href="#">Bhide, A, Hussein, A M, Elbarmelgy, R M et al. (2023) Association of ultrasound features with outcome and interobserver agreement in women at risk of placenta accreta spectrum.</a> Ultrasound in obstetrics & gynecology : the official journal of the International Society of Ultrasound in Obstetrics and Gynecology	- Study design not relevant to this review protocol <i>Not a diagnostic accuracy study as this retrospective cohort study only investigates the prenatal ultrasound features associated with operative complications and the interobserver agreement</i>
<a href="#">Bhide, Amarnath, Laoreti, Arianna, Kaelin Agten, Andrea et al. (2019) Lower uterine segment placental thickness in women with abnormally invasive placenta.</a> Acta obstetrica et gynecologica Scandinavica 98(1): 95-100	- Population not relevant to this review protocol <i>Only 45% of participants had previous caesarean birth</i>
<a href="#">Bloomfield, Valerie, Rogers, Stacey, Scattolon, Sarah et al. (2022) Informing the Spectrum of Approaches: Institutional Review of Placenta Accreta Spectrum Disorders Management.</a> Journal of obstetrics and gynaecology Canada : JOGC = Journal d'obstetrique et gynecologie du Canada : JOGC 44(4): 365-371	- Data not reported in an extractable format or a format that can be analysed <i>Only index text positive cases were included</i>
<a href="#">Boroomand Fard, Mahboobeh, Kasraeian, Maryam, Vafaei, Homeira et al. (2020) Introducing an efficient model for the prediction of placenta accreta spectrum using the MCP regression approach based on sonography indexes: how efficient is sonography in diagnosing accreta?.</a> BMC pregnancy and childbirth 20(1): 111	- Population not relevant to this review protocol <i>Only 56% of participants had low lying placenta or placenta praevia</i>

Study	Code [Reason]
<p>Bostanci, Evrim, Kilicci, Cetin, Ozkaya, Enis et al. (2020) Ultrasound predictors of candidates for segmental resection in pregnant women with placenta accreta. The journal of maternal-fetal &amp; neonatal medicine : the official journal of the European Association of Perinatal Medicine, the Federation of Asia and Oceania Perinatal Societies, the International Society of Perinatal Obstetricians 33(6): 1004-1007</p>	<p>- Study design not relevant to this review protocol <i>A prognostic study investigating ultrasound parameters that predict candidates for segmental resection in pregnant women with placenta accreta</i></p>
<p><a href="#">Bour, Laurence, Place, Vinciane, Bendavid, Sandra et al. (2014) Suspected invasive placenta: evaluation with magnetic resonance imaging.</a> European radiology 24(12): 3150-60</p>	<p>- Population not relevant to this review protocol <i>Only 53% and 59% of participants had placenta praevia and previous caesarean birth, respectively</i></p>
<p>Bourgioti, C., Zafeiropoulou, K., Fotopoulos, S. et al. (2019) MRI prognosticators for adverse maternal and neonatal clinical outcome in patients at high risk for placenta accreta spectrum (PAS) disorders. Journal of Magnetic Resonance Imaging 50(2): 602-618</p>	<p>- Secondary publication of an included study that does not provide any additional relevant information <i>Study includes same participants and data as already included study (Bourgioti 2021)</i></p>
<p>Bourgioti, Charis, Zafeiropoulou, Konstantina, Fotopoulos, Stavros et al. (2018) MRI Features Predictive of Invasive Placenta With Extrauterine Spread in High-Risk Gravid Patients: A Prospective Evaluation. AJR. American journal of roentgenology 211(3): 701-711</p>	<p>- Secondary publication of an included study that does not provide any additional relevant information <i>Study includes same participants and data as already included study (Bourgioti 2021)</i></p>
<p>Bourgioti, Charis, Zafeiropoulou, Konstantina, Tzavara, Chara et al. (2022) Comparison between 1.5-T and 3.0-T MRI for the diagnosis of placenta accreta spectrum disorders. Diagnostic and interventional imaging 103(9): 408-417</p>	<p>- Secondary publication of an included study that does not provide any additional relevant information <i>Study includes same participants and data as already included study (Bourgioti 2021), and compares 1.5-T MRI with 3.0-T MRI</i></p>
<p><a href="#">Bouvier, A, Sentilhes, L, Thouveny, F et al. (2012) Planned caesarean in the interventional radiology cath lab to enable immediate uterine artery embolization for the conservative treatment of placenta accreta.</a> Clinical radiology 67(11): 1089-94</p>	<p>- Study design not relevant to this review protocol <i>Not a diagnostic accuracy study as this retrospective study only investigates the feasibility and efficacy of routine uterine artery embolization immediately for placenta accreta</i></p>
<p><a href="#">Bowman, Zachary S, Eller, Alexandra G, Kennedy, Anne M et al. (2014) Interobserver variability of sonography for prediction of placenta accreta.</a> Journal of ultrasound in medicine : official journal of the American Institute of Ultrasound in Medicine 33(12): 2153-8</p>	<p>- Study design not relevant to this review protocol <i>Case-control study that investigates the interobserver variability of sonography for prediction of placenta accreta</i></p>
<p><a href="#">Bowman, Zachary S, Eller, Alexandra G, Kennedy, Anne M et al. (2014) Accuracy of ultrasound for the prediction of placenta accreta.</a> American journal of obstetrics and gynecology 211(2): 177e1-7</p>	<p>- Study design not relevant to this review protocol <i>Case control study that investigates the accuracy of ultrasound for the prediction of accreta</i></p>
<p>Budorick, Nancy E, Figueroa, Reinaldo, Vizcarra, Michael et al. (2017) Another look at ultrasound</p>	<p>- Population not relevant to this review protocol <i>Only 53% of participants had placenta praevia</i></p>

Study	Code [Reason]
and magnetic resonance imaging for diagnosis of placenta accreta. The journal of maternal-fetal & neonatal medicine : the official journal of the European Association of Perinatal Medicine, the Federation of Asia and Oceania Perinatal Societies, the International Society of Perinatal Obstetricians 30(20): 2422-2427	
<a href="#">Cai, Sheng-Nan, Wu, Yan-Ting, Zeng, Li et al. (2022) Value of 3D ultrasound flow imaging combined with serum AFP, beta-hCG, sFlt-1 and CK in the diagnosis of placenta accreta. BMC women's health 22(1): 556</a>	- Population not relevant to this review protocol <i>Only 37% of participants had a placenta praevia</i>
<a href="#">Cali, G. and Giambanco, L. (2011) Abnormal placental adherence: An obstetrical arising complication. A proposal of early diagnostic work-up. Italian Journal of Gynaecology and Obstetrics 23(1): 9-18</a>	- Study not reported in English
Cali, G, Forlani, F, Lees, C et al. (2019) Prenatal ultrasound staging system for placenta accreta spectrum disorders. Ultrasound in obstetrics & gynecology : the official journal of the International Society of Ultrasound in Obstetrics and Gynecology 53(6): 752-760	- Data not reported in an extractable format or a format that can be analysed
Cali, G, Forlani, F, Timor-Tritsch, I E et al. (2017) Natural history of Cesarean scar pregnancy on prenatal ultrasound: the crossover sign. Ultrasound in obstetrics & gynecology : the official journal of the International Society of Ultrasound in Obstetrics and Gynecology 50(1): 100-104	- Study design not relevant to this review protocol <i>A case series investigating the natural history of caesarean scar pregnancy</i>
Cali, G, Giambanco, L, Puccio, G et al. (2013) Morbidly adherent placenta: evaluation of ultrasound diagnostic criteria and differentiation of placenta accreta from percreta. Ultrasound in obstetrics & gynecology : the official journal of the International Society of Ultrasound in Obstetrics and Gynecology 41(4): 406-12	- Outcome not relevant to this review protocol <i>Diagnostic accuracy of individual parameters but not overall diagnostic accuracy of their combination was reported</i>
Cali, G, Timor-Tritsch, I E, Forlani, F et al. (2020) Value of first-trimester ultrasound in prediction of third-trimester sonographic stage of placenta accreta spectrum disorder and surgical outcome. Ultrasound in obstetrics & gynecology : the official journal of the International Society of Ultrasound in Obstetrics and Gynecology 55(4): 450-459	- Population not relevant to this review protocol <i>Only 58% of participants had a placenta praevia</i>
Cali, Giuseppe, Labate, Francesco, Cucinella, Gaspare et al. (2022) Placenta accreta spectrum disorders in twin pregnancies as an under reported clinical entity: a case series and systematic review. The journal of maternal-fetal & neonatal medicine : the official journal of the European Association of Perinatal Medicine, the Federation of Asia and Oceania Perinatal	- Study design not relevant to this review protocol <i>A case series and systematic review that investigate placenta accreta spectrum in twin pregnancies</i>

Study	Code [Reason]
Societies, the International Society of Perinatal Obstetricians 35(25): 8848-8851	
Cavalli, Cecilia, Maggi, Claudia, Gambarini, Sebastiana et al. (2022) Ultrasound and magnetic resonance imaging in the diagnosis of clinically significant placenta accreta spectrum disorders. Journal of perinatal medicine 50(3): 277-285	- Population not relevant to this review protocol <i>Only 26% of participants had previous caesarean birth</i>
<a href="#">Chalubinski, K M, Pils, S, Klein, K et al. (2013) Prenatal sonography can predict degree of placental invasion.</a> Ultrasound in obstetrics & gynecology : the official journal of the International Society of Ultrasound in Obstetrics and Gynecology 42(5): 518-24	- Reference standard not relevant to this review protocol <i>Not all participants had reference standard as only 78% of participants had operative findings and histology reports</i>
<a href="#">Charemnjiratragul, K., Suntharasaj, T., Pranpanus, S. et al. (2023) Preoperative sonographic sliding sign for prediction of intra-abdominal adhesions before repeat cesarean delivery.</a> International Journal of Gynecology and Obstetrics 161(1): 250-254	- Outcome not relevant to this review protocol <i>The usefulness of the uterine sliding sign for predicting intra-abdominal adhesions was reported</i>
<a href="#">Chen, Eric, Mar, Winnie A, Horowitz, Jeanne M et al. (2019) Texture analysis of placental MRI: can it aid in the prenatal diagnosis of placenta accreta spectrum?.</a> Abdominal radiology (New York) 44(9): 3175-3184	- Population not relevant to this review protocol <i>No information on whether participants had a low-lying placenta or placenta praevia</i>
<a href="#">Chen, Shaoqi, Chen, Qingzi, Du, Xiya et al. (2020) Value of Crystal Vue technique in detecting the placenta accreta spectrum located in c-section scar area.</a> Medical ultrasonography 22(4): 438-444	- Data not reported in an extractable format or a format that can be analysed <i>Only index text positive cases were included</i>
<a href="#">Chen, Xin, Shan, Ruiqin, Song, Qingxu et al. (2020) Placenta percreta evaluated by MRI: correlation with maternal morbidity.</a> Archives of gynecology and obstetrics 301(3): 851-857	- Study design not relevant to this review protocol <i>Prognostic study that investigates the correlation between invasive topography and maternal outcomes</i>
<a href="#">Cho, Hee Young, Hwang, Han Sung, Jung, Inkyung et al. (2015) Diagnosis of Placenta Accreta by Uterine Artery Doppler Velocimetry in Patients With Placenta Previa.</a> Journal of ultrasound in medicine : official journal of the American Institute of Ultrasound in Medicine 34(9): 1571-5	- Population not relevant to this review protocol <i>Only 24% of participants had previous caesarean birth</i>
<a href="#">Chong, Yiwen, Zhang, Aiqing, Wang, Yan et al. (2018) An ultrasonic scoring system to predict the prognosis of placenta accreta: A prospective cohort study.</a> Medicine 97(35): e12111	- Population not relevant to this review protocol <i>Only 52% of participants had a previous caesarean birth</i>
<a href="#">Chu, Caiting, Liu, Ming, Zhang, Yuzhen et al. (2022) MRI-Based Radiomics Analysis for Intraoperative Risk Assessment in Gravid Patients at High Risk with Placenta Accreta Spectrum.</a> Diagnostics (Basel, Switzerland) 12(2)	- Population not relevant to this review protocol <i>Only 53% of participants had a previous caesarean birth</i>

Study	Code [Reason]
<p><a href="#">Chu, Caiting, Liu, Ming, Zhang, Yuzheng et al. (2021) Quantifying magnetic resonance imaging features to classify placenta accreta spectrum (PAS) in high-risk gravid patients.</a> Clinical imaging 80: 50-57</p>	<p>- Study design not relevant to this review protocol <i>Prognostic study that investigates MRI features to classify placenta accreta spectrum (severity), and only 53% of participants had previous caesarean birth</i></p>
<p><a href="#">Chu, Caiting, Zhao, Shuhui, Ding, Ming et al. (2019) Combining Clinical Characteristics and Specific Magnetic Resonance Imaging Features to Predict Placenta Accreta.</a> Journal of computer assisted tomography 43(5): 775-779</p>	<p>- Outcome not relevant to this review protocol <i>Diagnostic accuracy of individual parameters but not overall diagnostic accuracy of their combination was reported</i></p>
<p><a href="#">Collins, Sally L, Stevenson, Gordon N, Al-Khan, Abdulla et al. (2015) Three-Dimensional Power Doppler Ultrasonography for Diagnosing Abnormally Invasive Placenta and Quantifying the Risk.</a> Obstetrics and gynecology 126(3): 645-653</p>	<p>- Outcome not relevant to this review protocol <i>Diagnostic accuracy of an individual parameter was reported</i></p>
<p><a href="#">D'Antonio, F; Iacovella, C; Bhide, A (2013) Prenatal identification of invasive placentation using ultrasound: systematic review and meta-analysis.</a> Ultrasound in obstetrics &amp; gynecology : the official journal of the International Society of Ultrasound in Obstetrics and Gynecology 42(5): 509-17</p>	<p>- Systematic review, included studies checked for relevance <i>Included studies published before 2010</i></p>
<p>D'Antonio, F, Iacovella, C, Palacios-Jaraquemada, J et al. (2014) Prenatal identification of invasive placentation using magnetic resonance imaging: systematic review and meta-analysis. Ultrasound in obstetrics &amp; gynecology : the official journal of the International Society of Ultrasound in Obstetrics and Gynecology 44(1): 8-16</p>	<p>- Systematic review, included studies checked for relevance <i>Included studies published before 2010</i></p>
<p>D'Antonio, F, Timor-Tritsch, I E, Palacios-Jaraquemada, J et al. (2018) First-trimester detection of abnormally invasive placenta in high-risk women: systematic review and meta-analysis. Ultrasound in obstetrics &amp; gynecology : the official journal of the International Society of Ultrasound in Obstetrics and Gynecology 51(2): 176-183</p>	<p>- Systematic review, included studies checked for relevance <i>Included studies published before 2010</i></p>
<p><a href="#">Dahmarde, H.; Parooie, F.; Salarzaei, M. (2020) Prenatal Diagnosis of Placental Invasion: A Systematic Review and Meta-analysis on Accuracy of Ultrasonography and MRI in Diagnosis of Placental Invasion.</a> Journal of Diagnostic Medical Sonography 36(5): 446-461</p>	<p>- Population not relevant to this review protocol <i>Systematic review includes studies (for example, Balcacer 2016) that did not specify whether participants had a previous lower segment caesarean birth or uterus surgery</i></p>
<p>Dall'Asta, Andrea, Cali, Giuseppe, Forlani, Francesco et al. (2020) Evaluation of perioperative complications using a newly described staging system for placenta accreta spectrum. European journal of obstetrics, gynecology, and reproductive biology 250: 54-60</p>	<p>- Population not relevant to this review protocol <i>Only 45.5% of participants had a previous uterus surgery</i></p>
<p>Dall'Asta, Andrea, Forlani, Francesco, Shah, Harsha et al. (2022) Evaluation of the Tramline</p>	<p>- Outcome not relevant to this review protocol</p>

Study	Code [Reason]
Sign in the Prediction of Placenta Accreta Spectrum and Perioperative Outcomes in Anterior Placenta Previa. <i>Ultraschall in der Medizin</i> (Stuttgart, Germany : 1980) 43(6): e118-e124	<i>Diagnostic accuracy of an individual parameter was reported</i>
Dang, X., Fan, C., Cui, F. et al. (2022) Interactions between ultrasonographic cervical length and placenta accreta spectrum on severe postpartum hemorrhage in women with placenta previa. <i>International Journal of Gynecology and Obstetrics</i>	- Population not relevant to this review protocol <i>Only 47% of participants had previous caesarean birth</i>
De Oliveira Carniello, M, Oliveira Brito, L G, Sarian, L O et al. (2022) Diagnosis of placenta accreta spectrum in high-risk women using ultrasonography or magnetic resonance imaging: systematic review and meta-analysis. <i>Ultrasound in obstetrics &amp; gynecology : the official journal of the International Society of Ultrasound in Obstetrics and Gynecology</i> 59(4): 428-436	- Systematic review, included studies checked for relevance <i>Included studies (for example, Ayati 2017 and Budorick 2017) with less than 60% of participants with low lying placenta</i>
De Vita, Davide, Capobianco, Giampiero, Gerosolima, Giovanni et al. (2019) Clinical and Ultrasound Predictors of Placenta Accreta in Pregnant Women with Antepartum Diagnosis of Placenta Previa: A Multicenter Study. <i>Gynecologic and obstetric investigation</i> 84(3): 242-247	- Outcome not relevant to this review protocol <i>Diagnostic accuracy of individual parameters but not overall diagnostic accuracy of their combination was reported</i>
Del Negro, V., Aleksa, N., Galli, C. et al. (2020) Ultrasonographic diagnosis of placenta accreta spectrum (PAS) disorder: Ideation of an ultrasonographic score and correlation with surgical and neonatal outcomes. <i>Diagnostics</i> 11(1): 23	- Population not relevant to this review protocol <i>Only 25% of participants had a previous caesarean birth</i>
<a href="#">Delli Pizzi, Andrea, Tavoletta, Alessandra, Narciso, Roberta et al. (2019) Prenatal planning of placenta previa: diagnostic accuracy of a novel MRI-based prediction model for placenta accreta spectrum (PAS) and clinical outcome.</a> <i>Abdominal radiology (New York)</i> 44(5): 1873-1882	- Population not relevant to this review protocol <i>Only 39% of participants had a previous caesarean birth</i>
Derman, Anna Y, Nikac, Violeta, Haberman, Shoshana et al. (2011) MRI of placenta accreta: a new imaging perspective. <i>AJR. American journal of roentgenology</i> 197(6): 1514-21	- Population not relevant to this review protocol <i>Only 47% of participants had a placenta praevia</i>
DI Girolamo, Raffaella, Buca, Danilo, Galliani, Carmen et al. (2023) Systematic review and meta-analysis on placenta accreta spectrum disorders in twin pregnancies: risk factors, detection rate and histopathology. <i>Minerva obstetrics and gynecology</i> 75(1): 55-61	- Systematic review, included studies checked for relevance <i>Included studies with &lt;60% of participants with a previous caesarean birth or placenta praevia</i>
Dimitrova, Ivelina, Jauniaux, Eric, Zosmer, Nurit et al. (2019) Development of a training program for the ultrasound screening of placenta accreta spectrum disorders. <i>International journal of</i>	- Study design not relevant to this review protocol <i>Case-control study investigating the impact of a training program using a systematic protocol on ultrasound signs of placenta accreta spectrum</i>

Study	Code [Reason]
gynaecology and obstetrics: the official organ of the International Federation of Gynaecology and Obstetrics 147(1): 73-77	
<a href="#">Ding, Xiaoyan, Cao, Yingying, Sun, Fengtao et al. (2021) Clinical Analysis of Improved Particle Swarm Algorithm-Based Magnetic Resonance Imaging Diagnosis of Placenta Accreta.</a> Contrast media & molecular imaging 2021: 7373637	- Population not relevant to this review protocol <i>No information on whether participants had a previous lower segment caesarean birth or uterus surgery and a low-lying placenta or placenta praevia</i>
<a href="#">Do, Quyen N, Lewis, Matthew A, Xi, Yin et al. (2020) MRI of the Placenta Accreta Spectrum (PAS) Disorder: Radiomics Analysis Correlates With Surgical and Pathological Outcome.</a> Journal of magnetic resonance imaging : JMRI 51(3): 936-946	- Study design not relevant to this review protocol <i>Prognostic study that investigates textural analyses as the radiomics in MRI in predicting the placenta accreta spectrum requiring hysterectomy, and no information on how many participants had placenta praevia</i>
<a href="#">Doulaveris, Georgios, Ryken, Katherine, Papatthomas, Daphne et al. (2020) Early prediction of placenta accreta spectrum in women with prior cesarean delivery using transvaginal ultrasound at 11 to 14 weeks.</a> American journal of obstetrics & gynecology MFM 2(4): 100183	- Population not relevant to this review protocol <i>About 43% and 48% of participants had a previous caesarean birth or uterus surgery and a low-lying placenta or placenta praevia, respectively</i>
<a href="#">Duzyj, Christina M, Cooper, Anne, Mhatre, Mohak et al. (2019) Placenta Accreta: A Spectrum of Predictable Risk, Diagnosis, and Morbidity.</a> American journal of perinatology 36(10): 1031-1038	- Population not relevant to this review protocol <i>Only 31% of participants had placenta praevia</i>
<a href="#">Einerson, Brett D, Rodriguez, Christina E, Kennedy, Anne M et al. (2018) Magnetic resonance imaging is often misleading when used as an adjunct to ultrasound in the management of placenta accreta spectrum disorders.</a> American journal of obstetrics and gynecology 218(6): 618e1-618e7	- Reference standard not relevant to this review protocol <i>Not all participants had operative findings or post caesarean birth examination as participants without placenta praevia had vaginal birth</i>
<a href="#">El-Haieg, Dahlia O, Madkour, Nadia M, Basha, Mohammad Abd Alkhalik et al. (2021) An Ultrasound Scoring Model for the Prediction of Intrapartum Morbidly Adherent Placenta and Maternal Morbidity: A Cross-Sectional Study.</a> Ultraschall in der Medizin (Stuttgart, Germany : 1980) 42(1): e1-e8	- Outcome not relevant to this review protocol <i>Diagnostic accuracy of a scoring system was reported</i>
<a href="#">Elmaraghy, A.M., Mamdouh, A.M., Fayed, S.T. et al. (2023) Diagnostic Accuracy of Placental Thickness in Lower Uterine Segment Measured by Ultrasound in Prediction of Placenta Accreta Spectrum in Patients with Placenta Previa. A Diagnostic Test Accuracy Study.</a> International Journal of Women's Health 15: 311-320	- Outcome not relevant to this review protocol <i>Diagnostic accuracy of an individual parameter was reported</i>
<a href="#">Esakoff, T F, Sparks, T N, Kaimal, A J et al. (2011) Diagnosis and morbidity of placenta accreta.</a> Ultrasound in obstetrics & gynecology : the official journal of the International Society of	- Population not relevant to this review protocol <i>No information on whether participants had a previous caesarean birth or uterus surgery</i>



Study	Code [Reason]
Ultrasound in Obstetrics and Gynecology 37(3): 324-7	
Familiari, Alessandra, Liberati, Marco, Lim, Philip et al. (2018) Diagnostic accuracy of magnetic resonance imaging in detecting the severity of abnormal invasive placenta: a systematic review and meta-analysis. Acta obstetrica et gynecologica Scandinavica 97(5): 507-520	- Systematic review, included studies checked for relevance <i>Included studies published before 2010</i>
Fatima, S., Makhdoom, S.I., Phulpoto, S. et al. (2021) Diagnostic Role of Doppler Ultrasound in Morbidly Adherent Placenta (MAP). Pakistan Journal of Medical and Health Sciences 15(12): 3697-3699	- Population not relevant to this review protocol <i>No information on whether participants had a previous lower segment caesarean birth or uterus surgery</i>
Finazzo, F, D'antonio, F, Masselli, G et al. (2020) Interobserver agreement in MRI assessment of severity of placenta accreta spectrum disorders. Ultrasound in obstetrics & gynecology : the official journal of the International Society of Ultrasound in Obstetrics and Gynecology 55(4): 467-473	- Data not reported in an extractable format or a format that can be analysed <i>No sufficient data to calculate the outcomes</i>
<a href="#">Fishman, Shira G and Chasen, Stephen T (2011) Risk factors for emergent preterm delivery in women with placenta previa and ultrasound findings suspicious for placenta accreta.</a> Journal of perinatal medicine 39(6): 693-6	- Population not relevant to this review protocol <i>Only 23% of participants had previous uterus surgery</i>
<a href="#">Flores-Mendoza, Homero, Windrim, Rory C, Kingdom, John C et al. (2022) Improving Early Pregnancy Screening for Placenta Accreta Spectrum: Retrospective Analysis of Early Screening Candidates by Risk Assessment in Canada.</a> Journal of obstetrics and gynaecology Canada : JOGC = Journal d'obstetrique et gynecologie du Canada : JOGC 44(6): 704-706	- Study design not relevant to this review protocol <i>A case series investigates risk factors for placenta accreta spectrum disorder</i>
Fratelli, N, Prefumo, F, Maggi, C et al. (2022) Third-trimester ultrasound for antenatal diagnosis of placenta accreta spectrum in women with placenta previa: results from the ADoPAD study. Ultrasound in obstetrics & gynecology : the official journal of the International Society of Ultrasound in Obstetrics and Gynecology 60(3): 381-389	- Reference standard not relevant to this review protocol <i>Not all participants had operative findings or post caesarean birth examination</i>
<a href="#">Gao, S.; Liu, B.; Cao, Y. (2016) The comparison of MRI and Ultrasound in prenatal identification of invasive placentation: A meta-analysis based on 20 parallel control studies.</a> International Journal of Clinical and Experimental Medicine 9(6): 9932-9942	- Systematic review, included studies checked for relevance <i>Included studies conducted or published before 2010</i>
<a href="#">Gao, Yisu, Gao, Xuejiao, Cai, Jing et al. (2021) Prediction of placenta accreta spectrum by a scoring system based on maternal characteristics combined with ultrasonographic features.</a>	- Population not relevant to this review protocol <i>Only 31% of participants had a placenta praevia</i>

Study	Code [Reason]
Taiwanese journal of obstetrics & gynecology 60(6): 1011-1017	
Garofalo, Anna, Pilloni, Eleonora, Alemanno, Maria Grazia et al. (2019) Ultrasound accuracy in prenatal diagnosis of abnormal placentation of posterior placenta previa. European journal of obstetrics, gynecology, and reproductive biology 242: 86-91	- Population not relevant to this review protocol <i>Only 43% of participants had a previous uterine surgery</i>
Ghezzi, Caroline Lorenzoni Almeida, Silva, Cristiano Kohler, Casagrande, Aline Spader et al. (2021) Diagnostic performance of radiologists with different levels of experience in the interpretation of MRI of the placenta accreta spectrum disorder. The British journal of radiology 94(1128): 20210827	- Population not relevant to this review protocol <i>Only 41% of participants had a placenta praevia</i>
Gilboa, Yinon, Spira, Maya, Mazaki-Tovi, Shali et al. (2015) A novel sonographic scoring system for antenatal risk assessment of obstetric complications in suspected morbidly adherent placenta. Journal of ultrasound in medicine : official journal of the American Institute of Ultrasound in Medicine 34(4): 561-7	- Population not relevant to this review protocol <i>Only 56% of participants had placenta praevia</i>
<a href="#">Goergen, S K, Posma, E, Wrede, D et al. (2018) Interobserver agreement and diagnostic performance of individual MRI criteria for diagnosis of placental adhesion disorders.</a> Clinical radiology 73(10): 908e1-908e9	- Reference standard not relevant to this review protocol <i>No information on whether all participants had operative findings with/without histology reports/lab findings and post caesarean birth examination with histology</i>
<a href="#">Gouhar, G.K., Sadek, S.M., Siam, S. et al. (2012) Role of transperineal sonography in diagnosis of placenta previa/accreta: A prospective study.</a> Egyptian Journal of Radiology and Nuclear Medicine 43(4): 637-645	- Population not relevant to this review protocol <i>Previous caesarean birth or uterus surgery were not stated as inclusion criteria, and no information on whether participants without PAS had previous caesarean birth or uterus surgery</i>
Gulino, Ferdinando Antonio, Guardo, F Di, Zambrotta, E et al. (2018) Placenta accreta and balloon catheterization: the experience of a single center and an update of latest evidence of literature. Archives of gynecology and obstetrics 298(1): 83-88	- Population not relevant to this review protocol <i>Only 37% of participants had placenta praevia or praevia-accreta, and unclear whether participants without PAS had placenta praevia. No information on number of participants with previous caesarean birth, and this was not stated as an inclusion criterion</i>
<a href="#">Guo, Peng, Wu, Yuli, Yuan, Xiaoting et al. (2021) Clinical diagnostic value and analysis of MRI combined with ultrasound in prenatal pernicious placenta previa with placenta accreta.</a> Annals of palliative medicine 10(6): 6753-6759	- Population not relevant to this review protocol <i>No information on whether participants had a previous lower segment caesarean birth or uterus surgery</i>
Gupta, S., Sibia, P., Kaur, S. et al. (2021) Emerging role of prenatal magnetic resonance imaging in the diagnosis of placental adhesion disorders and its relation with intraoperative	- Data not reported in an extractable format or a format that can be analysed <i>Only index text positive cases were included</i>

Study	Code [Reason]
findings - A cross-sectional study. Journal of Clinical and Diagnostic Research 15(8): tc15-tc20	
Hamada, Shoko, Hasegawa, Junichi, Nakamura, Masamitsu et al. (2011) Ultrasonographic findings of placenta lacunae and a lack of a clear zone in cases with placenta previa and normal placenta. Prenatal diagnosis 31(11): 1062-5	- Study design not relevant to this review protocol <i>A case-control study investigating the frequencies of placenta lacunae and lack of a clear zone in women with placenta praevia, and only 8% of participants had a previous caesarean birth</i>
<a href="#">Hamisa, M., Mashaly, E., Fathy, S. et al. (2015) Role of Doppler US and MRI in diagnosis of placenta accreta.</a> Alexandria Journal of Medicine 51(3): 225-230	- Population not relevant to this review protocol <i>Only 3% of participants had a placenta praevia or low lying placenta</i>
<a href="#">Happe, Sarah K, Rac, Martha W F, Moschos, Elysia et al. (2020) Prospective First-Trimester Ultrasound Imaging of Low Implantation and Placenta Accreta Spectrum.</a> Journal of ultrasound in medicine : official journal of the American Institute of Ultrasound in Medicine 39(10): 1907-1915	- Reference standard not relevant to this review protocol <i>No information on whether all participants had operative findings with/without histology reports/lab findings and post caesarean birth examination with histology</i>
<a href="#">Happe, Sarah K, Yule, Casey S, Spong, Catherine Y et al. (2021) Predicting Placenta Accreta Spectrum: Validation of the Placenta Accreta Index.</a> Journal of ultrasound in medicine : official journal of the American Institute of Ultrasound in Medicine 40(8): 1523-1532	- Index test not relevant to this review protocol <i>Placenta accreta index that includes non-radiological parameter (that is, previous caesarean section) was used, and operative findings were not used for all participants</i>
<a href="#">Hasegawa, K., Ikenoue, S., Tanaka, Y. et al. (2023) Ultrasonographic Prediction of Placental Invasion in Placenta Previa by Placenta Accreta Index.</a> Journal of Clinical Medicine 12(3): 1090	- Index test not relevant to this review protocol <i>Placenta accreta index that includes non-radiological parameter (that is, previous caesarean section) was used, and no information on whether all participants had a previous lower segment caesarean birth or uterus surgery</i>
<a href="#">Hong, Shibin, Le, Yiping, Lio, Ka U et al. (2022) Performance comparison of ultrasonography and magnetic resonance imaging in their diagnostic accuracy of placenta accreta spectrum disorders: a systematic review and meta-analysis.</a> Insights into imaging 13(1): 50	- Systematic review, included studies checked for relevance <i>Included studies published before 2010</i>
<a href="#">Hou, Shunyu, Song, Ye, Wu, Jiahui et al. (2021) Comparison of Magnetic Resonance Imaging of the Lower Uterine Segment in Pregnant Women with Central Placenta Previa with and without Placenta Accreta Spectrum from a Single Center.</a> Medical science monitor : international medical journal of experimental and clinical research 27: e932759	- Study design not relevant to this review protocol <i>Case-control study design was used</i>
<a href="#">Hu, Yumin, Wang, Yi, Weng, Qiaoyou et al. (2022) Intraplacental T2-hypointense bands may help predict placental invasion depth and postpartum hemorrhage in placenta accrete spectrum disorders in high-risk gravid patients.</a> Magnetic resonance imaging 94: 73-79	- Outcome not relevant to this review protocol <i>Diagnostic accuracy of individual parameters but not overall diagnostic accuracy of their combination was reported</i>

Study	Code [Reason]
<p><a href="#">Huang, Fang, Lai, Qing-Quan, Wu, Hong et al. (2020) Application of Indirect Signs of Magnetic Resonance Imaging (MRI) in Prenatal Diagnosis of Abnormally Invasive Placenta.</a> Medical science monitor : international medical journal of experimental and clinical research 26: e923272</p>	<p>- Study design not relevant to this review protocol <i>A case-control study, and not all participants had operative findings with/without histology reports/lab findings and post caesarean birth examination with histology</i></p>
<p><a href="#">Ishibashi, Hiroki, Miyamoto, Morikazu, Shinmoto, Hiroshi et al. (2020) The use of magnetic resonance imaging to predict placenta previa with placenta accreta spectrum.</a> Acta obstetrica et gynecologica Scandinavica 99(12): 1657-1665</p>	<p>- Population not relevant to this review protocol <i>Only 15.8% of participants had a previous caesarean birth</i></p>
<p><a href="#">Ishibashi, Hiroki, Miyamoto, Morikazu, Shinmoto, Hiroshi et al. (2017) Cervical varicosities may predict placenta accreta in posterior placenta previa: a magnetic resonance imaging study.</a> Archives of gynecology and obstetrics 296(4): 731-736</p>	<p>- Population not relevant to this review protocol <i>Only 9.9% of participants had a caesarean birth</i></p>
<p><a href="#">Jariyawattananat, Watchaya, Thiravit, Shanigarn, Suvannarerg, Voraparee et al. (2023) Bladder involvement in placenta accreta spectrum disorder with placenta previa: MRI findings and outcomes correlation.</a> European journal of radiology 160: 110695</p>	<p>- Study design not relevant to this review protocol <i>A prognostic study investigating MRI parameters that predict bladder involvement, and no information on whether all participants had a previous caesarean birth or uterus surgery</i></p>
<p><a href="#">Jauniaux, Eric and Bhide, Amar (2017) Prenatal ultrasound diagnosis and outcome of placenta previa accreta after cesarean delivery: a systematic review and meta-analysis.</a> American journal of obstetrics and gynecology 217(1): 27-36</p>	<p>- Systematic review, included studies checked for relevance <i>Included studies published before 2010</i></p>
<p><a href="#">Jha, Priyanka, Rabban, Joseph, Chen, Lee-May et al. (2019) Placenta accreta spectrum: value of placental bulge as a sign of myometrial invasion on MR imaging.</a> Abdominal radiology (New York) 44(7): 2572-2581</p>	<p>- Reference standard not relevant to this review protocol <i>Not all participants have operative findings or post caesarean birth examination, and no information on whether participants had a placenta praevia or low-lying placenta</i></p>
<p>Juan-Clar, Miquel, Torrent, Marta, Santandreu, Pere et al. (2022) Effectiveness of Ultrasound Screening for a Placenta Accreta Spectrum Using Standard Ultrasound Criteria in a Secondary Care Setting. Fetal diagnosis and therapy 49(12): 52-59</p>	<p>- Population not relevant to this review protocol <i>Only 34% of participants had a previous caesarean birth or uterus surgery</i></p>
<p><a href="#">Kalsoom Nawab, Sadaf Naveed MK (2017) DIAGNOSTIC ACCURACY OF ULTRASOUND (U/S) AND MAGNETIC RESONANCE IMAGING (MRI) IN PRENATAL DIAGNOSIS OF PLACENTA ACCRETA TAKING OPERATIVE FINDINGS AS GOLD STANDARD.</a> Pakistan Journal of Radiology 27(4): 317-322</p>	<p>- Population not relevant to this review protocol <i>Only 24% of participants had placenta praevia, and inclusion criteria did not include placenta praevia or low-lying placenta</i></p>
<p><a href="#">Kamankesh, Rohangiz, Hanafi, Mohammad Ghasem, Bakhtiari, Zahra et al. (2020) Evaluation of the sensitivity and specificity of 2D and color Doppler sonography in the detection of placenta</a></p>	<p>- Population not relevant to this review protocol <i>No information on whether participants had a low-lying placenta or placenta praevia</i></p>

Study	Code [Reason]
<p><a href="#">accreta in pregnant women</a>. Journal of family medicine and primary care 9(2): 1009-1012</p>	
<p><a href="#">Karakoc, Gokhan, Yalcin, Serenat Eris, Yavuz, And et al. (2021) Delta Neutrophil Index as a Promising Biomarker for Placental Implantation Disorders</a>. Zeitschrift fur Geburtshilfe und Neonatologie 225(5): 412-417</p>	<p>- Index test not relevant to this review protocol <i>Non-radiological parameter (that is, delta neutrophil index) was used</i></p>
<p><a href="#">Kayem, Gilles, Deneux-Tharoux, Catherine, Sentilhes, Loic et al. (2013) PACCRETA: clinical situations at high risk of placenta ACCRETA/percreta: impact of diagnostic methods and management on maternal morbidity</a>. Acta obstetrica et gynecologica Scandinavica 92(4): 476-82</p>	<p>- Study design not relevant to this review protocol <i>A study protocol of diagnostic test accuracy study</i></p>
<p><a href="#">Khalid, D., Noreen, A., Javed, A.M. et al. (2016) Diagnostic accuracy of color doppler ultrasound in antenatal diagnosis of morbidly adherent placenta, taking operative findings of caesarean section as gold standard</a>. Pakistan Journal of Medical and Health Sciences 10(2): 478-481</p>	<p>- Population not relevant to this review protocol <i>No information on whether participants had a previous lower segment caesarean birth or uterus surgery</i></p>
<p>Khander, Amrin, Sharma, Nivita, Eroglu, Idil et al. (2022) Ultrasound detection rates of the placenta accreta spectrum with prior myomectomy. The journal of maternal-fetal &amp; neonatal medicine : the official journal of the European Association of Perinatal Medicine, the Federation of Asia and Oceania Perinatal Societies, the International Society of Perinatal Obstetricians 35(25): 8752-8755</p>	<p>- Population not relevant to this review protocol <i>Only 17% of participants had a placenta praevia</i></p>
<p><a href="#">Kliwer, Mark A, Bagley, Anjuli R, Sadowski, Elizabeth A et al. (2023) Placenta accreta spectrum: the pattern and character of intraplacental blood flow by color and spectral Doppler</a>. Abdominal radiology (New York) 48(1): 377-386</p>	<p>- Population not relevant to this review protocol <i>Only 43% of participants had placenta praevia</i></p>
<p><a href="#">Kliwer, Mark A, Bockoven, Crystal G, Reeder, Scott B et al. (2023) Ferumoxytol-enhanced MR demonstration of changes to internal placental structure in placenta accreta spectrum: Preliminary findings</a>. Placenta 134: 1-8</p>	<p>- Population not relevant to this review protocol <i>Only 50% of participants had a placenta praevia or low-lying placenta</i></p>
<p><a href="#">Knight, Jordan C, Lehnert, Stephen, Shanks, Anthony L et al. (2018) A comprehensive severity score for the morbidly adherent placenta: combining ultrasound and magnetic resonance imaging</a>. Pediatric radiology 48(13): 1945-1954</p>	<p>- Population not relevant to this review protocol <i>Only 56% of participants had a placenta praevia</i></p>
<p>Kohler Silva, Cristiano, Almeida Ghezzi, Caroline Lorenzoni, Vettori, Daniela Vanessa et al. (2023) Performance of magnetic resonance imaging to predict maternal outcomes in patients at high risk</p>	<p>- Population not relevant to this review protocol <i>Only 41% of participants had a placenta praevia</i></p>

Study	Code [Reason]
for placenta accreta spectrum disorder. The British journal of radiology 96(1144): 20220822	
<a href="#">Kumar, Ishan, Verma, Ashish, Jain, Shivi et al. (2016) Chemical Shift Artifact on Steady-State MRI Sequences for Detection of Vesical Wall Invasion in Placenta Percreta.</a> Journal of obstetrics and gynaecology of India 66(2): 101-6	- Study design not relevant to this review protocol <i>Study investigating diagnostic accuracy of an individual parameter</i>
<a href="#">Kumar, Ishan, Verma, Ashish, Ojha, Ritu et al. (2017) Invasive placental disorders: a prospective US and MRI comparative analysis.</a> Acta radiologica (Stockholm, Sweden : 1987) 58(1): 121-128	- Population not relevant to this review protocol <i>Placenta praevia or low-lying placenta were not stated as inclusion criteria. Only 36% of participants had placenta praevia, but unclear whether participants without PAS had these conditions.</i>
<a href="#">Lamrissi, A., Benjelloun, A.T., Harit, A. et al. (2022) Prenatal diagnosis and management of placenta accreta in a Moroccan high-level maternity.</a> International Journal of Surgery Open 43: 100497	- Study design not relevant to this review protocol <i>A case series investigating prenatal diagnosis and management of placenta accreta, and no information on whether participants had a previous lower segment caesarean birth or uterus surgery and a low-lying placenta or placenta praevia</i>
<a href="#">Leitch, Ka'Toria, Shahedi, Maysam, Dormer, James D et al. (2022) Placenta Accreta Spectrum and Hysterectomy Prediction Using MRI Radiomic Features.</a> Proceedings of SPIE--the International Society for Optical Engineering 12033	- Data not reported in an extractable format or a format that can be analysed
<a href="#">Li, Qiang, Zhou, Hang, Zhou, Kefeng et al. (2021) Development and validation of a magnetic resonance imaging-based nomogram for predicting invasive forms of placental accreta spectrum disorders.</a> The journal of obstetrics and gynaecology research 47(10): 3488-3497	- Index test not relevant to this review protocol <i>MRI-based nomogram that also includes non-radiological parameter (that is, previous caesarean section) was used</i>
<a href="#">Li, Yan, Choi, Hailey H, Goldstein, Ruth et al. (2021) Placental thickness correlates with placenta accreta spectrum (PAS) disorder in women with placenta previa.</a> Abdominal radiology (New York) 46(6): 2722-2728	- Outcome not relevant to this review protocol <i>Diagnostic accuracy of an individual parameter was reported</i>
Lin, Huien, Li, Li, Lin, Yi et al. (2022) Accuracy of Magnetic Resonance Imaging in Diagnosing Placenta Accreta: A Systematic Review and Meta-Analysis. Computational and mathematical methods in medicine 2022: 2751559	- Systematic review, included studies checked for relevance <i>Systematic review includes studies (for example, Ayati 2017) with less than 60% of participants with low lying placenta</i>
Lin, Q., Li, B., Chen, S. et al. (2022) Application of Scanning Magnetic Resonance Imaging in the Diagnosis of Prenatal Placental Implantation and Related Care. Scanning 2022: 4883989	- Reference standard not relevant to this review protocol <i>No information on whether all participants had operative findings with/without histology reports/lab findings and post caesarean birth examination with histology, and no information on study design (e.g., cohort study or cross-sectional study or case report)</i>

Study	Code [Reason]
Lin, R., Li, J., Ren, Y. et al. (2017) Ultrasound and MRI accordance and features in the prenatal diagnosis of placenta accreta. International Journal of Clinical and Experimental Medicine 10(6): 8917-8925	- Reference standard not relevant to this review protocol <i>46% of participants had vaginal birth and did not have operative findings or post caesarean birth examination</i>
<a href="#">Liu, Wen, Chen, Xin, Sun, Cong et al. (2018) Morphological evaluation of cervix using MRI at 32 to 36 weeks of gestation: Findings for predicting invasive placenta previa.</a> Medicine 97(49): e13375	- Outcome not relevant to this review protocol <i>Diagnostic accuracy of individual parameters but not overall diagnostic accuracy of their combination was reported</i>
Liu, Yan, Fan, Dazhi, Fu, Yao et al. (2018) Diagnostic accuracy of cystoscopy and ultrasonography in the prenatal diagnosis of abnormally invasive placenta. Medicine 97(15): e0438	- Population not relevant to this review protocol <i>No information on whether participants had a placenta praevia or low-lying placenta</i>
<a href="#">Liu, Zhen-Zhen, Wei, Yao, Wang, Ruo-Jiao et al. (2017) Antenatal Sonographic Diagnosis and Clinical Significance of Placenta Previa Accreta after Cesarean Section.</a> Zhongguo yi xue ke xue yuan xue bao. Acta Academiae Medicinae Sinicae 39(5): 693-698	- Study not reported in English
Lopes, Elisa Santos, Feitosa, Francisco Edson de Lucena, Brazil, Antonio Viana et al. (2019) Assessment of Sensitivity and Specificity of Ultrasound and Magnetic Resonance Imaging in the Diagnosis of Placenta Accreta. Revista brasileira de ginecologia e obstetricia : revista da Federacao Brasileira das Sociedades de Ginecologia e Obstetricia 41(1): 17-23	- Reference standard not relevant to this review protocol <i>Not all participants had operative findings or post caesarean birth examination</i>
<a href="#">Lu, M., Wang, Z.-J., Chen, C.-A. et al. (2016) Accuracy of ultrasound in the diagnosis of placenta accreta: An updated meta-analysis.</a> International Journal of Clinical and Experimental Medicine 9(6): 8887-8897	- Systematic review, included studies checked for relevance <i>Included studies conducted or published before 2010</i>
<a href="#">Lu, Tao, Li, Mou, Wang, Yishuang et al. (2023) Standard diffusion-weighted, diffusion kurtosis and intravoxel incoherent motion in differentiating invasive placentas.</a> Archives of gynecology and obstetrics	- Reference standard not relevant to this review protocol <i>No information on whether all participants had operative findings with/without histology reports/lab findings and post caesarean birth examination with histology</i>
Lu, Tao, Pu, Hong, Li, Kui-de et al. (2019) Can introvoxel incoherent motion MRI be used to differentiate patients with placenta accreta spectrum disorders?. BMC pregnancy and childbirth 19(1): 531	- Outcome not relevant to this review protocol <i>Diagnostic accuracy of individual parameters but not overall diagnostic accuracy of their combination was reported, and not all participants had operative findings</i>
<a href="#">Lu, Tao, Wang, Yishuang, Guo, Aiwon et al. (2022) Monoexponential, biexponential and diffusion kurtosis MR imaging models: quantitative biomarkers in the diagnosis of placenta accreta spectrum disorders.</a> BMC pregnancy and childbirth 22(1): 349	- Reference standard not relevant to this review protocol <i>59% of participants with normal placenta had vaginal birth and did not have operative findings or post caesarean birth examination</i>

Study	Code [Reason]
<p><a href="#">Lu, Tao, Wang, Yishuang, Guo, Aiwen et al. (2022) Correlation of placental thickness and PAS disorders: findings from MRI.</a> Abdominal radiology (New York) 47(3): 1150-1156</p>	<p>- Population not relevant to this review protocol <i>Only 52% of participants had a placenta praevia</i></p>
<p><a href="#">Lu, Tao, Wang, Yishuang, Guo, Aiwen et al. (2022) Correlation of placental thickness and placenta percreta in patients with placenta previa: findings from MRI.</a> Abdominal radiology (New York) 47(12): 4237-4244</p>	<p>- Outcome not relevant to this review protocol <i>Diagnostic accuracy of an individual parameter was reported</i></p>
<p><a href="#">Lu, Tao, Zhang, Tianyue, Wang, Yishuang et al. (2022) Radiomics analysis of T2 -weighted images for differentiating invasive placentas in women at high risks.</a> Magnetic resonance in medicine 88(6): 2621-2632</p>	<p>- Outcome not relevant to this review protocol <i>Diagnostic accuracy of an individual parameter was reported</i></p>
<p>Luo, Li, Sun, Qiulei, Ying, Demei et al. (2019) Scoring system for the prediction of the severity of placenta accrete spectrum in women with placenta previa: a prospective observational study. Archives of gynecology and obstetrics 300(3): 783-791</p>	<p>- Index test not relevant to this review protocol <i>Scoring system that includes non-radiological parameter (that is, caesarean section) was used</i></p>
<p><a href="#">Maged, Ahmed M, Abdelaal, Hoda, Salah, Emad et al. (2018) Prevalence and diagnostic accuracy of Doppler ultrasound of placenta accreta in Egypt.</a> The journal of maternal-fetal &amp; neonatal medicine : the official journal of the European Association of Perinatal Medicine, the Federation of Asia and Oceania Perinatal Societies, the International Society of Perinatal Obstetricians 31(7): 933-939</p>	<p>- Outcome not relevant to this review protocol <i>Diagnostic accuracy of individual parameters but not overall diagnostic accuracy of their combination was reported</i></p>
<p><a href="#">Mahalingam, H.V., Rangasami, R., Premkumar, J. et al. (2021) Placenta accreta scoring system (PASS)-assessment of a simplified clinico-radiological scoring system for antenatal diagnosis of placenta accreta.</a> Egyptian Journal of Radiology and Nuclear Medicine 52(1): 42</p>	<p>- Outcome not relevant to this review protocol <i>Diagnostic accuracy of individual parameters but not overall diagnostic accuracy of their combination was reported</i></p>
<p><a href="#">Marsoosi, Vajihah, Ghotbizadeh, Fahimeh, Hashemi, Neda et al. (2020) Development of a scoring system for prediction of placenta accreta and determine the accuracy of its results.</a> The journal of maternal-fetal &amp; neonatal medicine : the official journal of the European Association of Perinatal Medicine, the Federation of Asia and Oceania Perinatal Societies, the International Society of Perinatal Obstetricians 33(11): 1824-1830</p>	<p>- Outcome not relevant to this review protocol <i>Diagnostic accuracy of scoring system that includes non radiological feature (that is, previous caesarean section) was reported. Inclusion criteria did not include placenta praevia or low-lying placenta</i></p>
<p><a href="#">Masood, M.A. and Maqsood, B. (2020) Diagnostic accuracy of ultrasound and MRI in pregnant women at risk for placenta accreta.</a> Pakistan Journal of Medical and Health Sciences 14(3): 589-590</p>	<p>- Population not relevant to this review protocol <i>No information on whether participants had a previous lower segment caesarean birth or uterus surgery</i></p>



Study	Code [Reason]
Matsuzaki, Shinya, Okada, Aiko, Endo, Masayuki et al. (2019) Horizontal Cervix as a Novel Sign for Predicting Adhesions on the Posterior Extrauterine Wall in Cases of Placenta Previa. Journal of clinical medicine 8(12)	- Population not relevant to this review protocol <i>Only 43% of participants had a previous caesarean birth</i>
<a href="#">Maymon, R, Melcer, Y, Pekar-Zlotin, M et al. (2018) Bedside risk estimation of morbidly adherent placenta using simple calculator.</a> Archives of gynecology and obstetrics 297(3): 631-635	- Population not relevant to this review protocol <i>Only 10% of participants had placenta praevia</i>
McLean, Logan A, Heilbrun, Marta E, Eller, Alexandra G et al. (2011) Assessing the role of magnetic resonance imaging in the management of gravid patients at risk for placenta accreta. Academic radiology 18(9): 1175-80	- Population not relevant to this review protocol <i>Only 5% of participants had placenta praevia, and not all participants had operative findings as some participants had vaginal birth</i>
<a href="#">Meng, Xinyue; Xie, Limei; Song, Weiwei (2013) Comparing the diagnostic value of ultrasound and magnetic resonance imaging for placenta accreta: a systematic review and meta-analysis.</a> Ultrasound in medicine & biology 39(11): 1958-65	- Systematic review, included studies checked for relevance <i>Included studies published before 2010</i>
Millischer, A E, Deloison, B, Silvera, S et al. (2017) Dynamic contrast enhanced MRI of the placenta: A tool for prenatal diagnosis of placenta accreta?. Placenta 53: 40-47	- Secondary publication of an included study that does not provide any additional relevant information <i>Study includes same participants and data as already included study (Millischer 2017)</i>
<a href="#">Mohammadi, Afsaneh, Bouzari, Zinatossadat, Hajian-Tilaki, Karimollah et al. (2022) Role of scaling combination of risk factors in clinical and imaging findings during pregnancy in predicting placenta accreta spectrum.</a> Caspian journal of internal medicine 13(1): 10-15	- Population not relevant to this review protocol <i>Only 22% of participants had a previous caesarean birth</i>
<a href="#">Nagase, Y, Matsuzaki, S, Mizuta-Odani, C et al. (2020) In-vitro fertilisation-embryo-transfer complicates the antenatal diagnosis of placenta accreta spectrum using MRI: a retrospective analysis.</a> Clinical radiology 75(12): 927-933	- Population not relevant to this review protocol <i>Only 33% of participants had previous caesarean birth</i>
<a href="#">Nagenthran, G., Rangasami, R., Chandrasekharan, A. et al. (2019) Role of magnetic resonance imaging in pregnancy-associated obstetric and gynecological complications.</a> Egyptian Journal of Radiology and Nuclear Medicine 50(1): 98	- Population not relevant to this review protocol <i>No information on whether participants had a previous lower segment caesarean birth or uterus surgery and a low-lying placenta or placenta praevia</i>
<a href="#">Nasir, S.; Anwar, S.; Rehan, B. (2018) Detection of suspected placental invasion by MRI - A prospective study in a tertiary care hospital.</a> Medical Forum Monthly 29(8): 33-36	- Outcome not relevant to this review protocol <i>Diagnostic accuracy of individual parameters but not overall diagnostic accuracy of their combination was reported</i>
Nieto-Calvache, Albaro Jose, Benavides-Calvache, Juan Pablo, Hidalgo, Alejandra et al. (2022) Placenta Accreta Spectrum Prenatal	- Population not relevant to this review protocol <i>No information on whether participants had a previous caesarean birth or uterus surgery and a</i>

Study	Code [Reason]
<p>Diagnosis Performance: Are Ultrasound False-positive Results Acceptable in Limited-resources Settings?. Revista brasileira de ginecologia e obstetricia : revista da Federacao Brasileira das Sociedades de Ginecologia e Obstetricia 44(9): 838-844</p>	<p><i>low-lying placenta or placenta praevia, and these were not stated as inclusion criteria</i></p>
<p><a href="#">Noda, Yoshifumi, Kanematsu, Masayuki, Goshima, Satoshi et al. (2015) Prenatal MR imaging diagnosis of placental invasion.</a> Abdominal imaging 40(5): 1273-8</p>	<p>- Population not relevant to this review protocol <i>Only 35% of participants had previous caesarean birth</i></p>
<p>Pagani, Giorgio, Cali, Giuseppe, Acharya, Ganesh et al. (2018) Diagnostic accuracy of ultrasound in detecting the severity of abnormally invasive placentation: a systematic review and meta-analysis. Acta obstetrica et gynecologica Scandinavica 97(1): 25-37</p>	<p>- Systematic review, included studies checked for relevance <i>Included studies published before 2010</i></p>
<p><a href="#">Pain, Flore-Anne, Dohan, Anthony, Grange, Gilles et al. (2022) Percreta score to differentiate between placenta accreta and placenta percreta with ultrasound and MR imaging.</a> Acta obstetrica et gynecologica Scandinavica 101(10): 1135-1145</p>	<p>- Population not relevant to this review protocol <i>No information on whether participants had a low-lying placenta or placenta praevia</i></p>
<p>Palacios-Jaraquemada, Jose M, Basanta, Nicolas, Nieto-Calvache, Albaro et al. (2022) Comprehensive surgical staging for placenta accreta spectrum. The journal of maternal-fetal &amp; neonatal medicine : the official journal of the European Association of Perinatal Medicine, the Federation of Asia and Oceania Perinatal Societies, the International Society of Perinatal Obstetricians 35(26): 10660-10666</p>	<p>- Population not relevant to this review protocol <i>No information on whether participants had a previous lower segment caesarean birth or uterus surgery and a low-lying placenta or placenta praevia</i></p>
<p>Palacios-Jaraquemada, Jose M, D'Antonio, Francesco, Buca, Danilo et al. (2020) Systematic review on near miss cases of placenta accreta spectrum disorders: correlation with invasion topography, prenatal imaging, and surgical outcome. The journal of maternal-fetal &amp; neonatal medicine : the official journal of the European Association of Perinatal Medicine, the Federation of Asia and Oceania Perinatal Societies, the International Society of Perinatal Obstetricians 33(19): 3377-3384</p>	<p>- Systematic review, included studies checked for relevance <i>Included studies are case reports and case series</i></p>
<p><a href="#">Palacios-Jaraquemada, Jose Miquel; Bruno, Claudio Hernan; Martin, Eduardo (2013) MRI in the diagnosis and surgical management of abnormal placentation.</a> Acta obstetrica et gynecologica Scandinavica 92(4): 392-7</p>	<p>- Population not relevant to this review protocol <i>No information on whether participants had a previous caesarean birth or uterus surgery and a low-lying placenta or placenta praevia, and these were not stated as inclusion criteria</i></p>
<p><a href="#">Pekar-Zlotin, Marina, Maymon, Ron, Eliassi Revivo, Perry et al. (2022) Comparison between a prenatal sonographic scoring system and a clinical grading at delivery for Placenta Accreta Spectrum disorders.</a> The journal of maternal-fetal &amp; neonatal</p>	<p>- Population not relevant to this review protocol <i>Only 13% of participants had a low-lying placenta or placenta praevia</i></p>

Study	Code [Reason]
<p>medicine : the official journal of the European Association of Perinatal Medicine, the Federation of Asia and Oceania Perinatal Societies, the International Society of Perinatal Obstetricians 35(25): 8810-8816</p>	
<p>Peker, Nuri, Turan, Volkan, Ergenoglu, Mete et al. (2013) Assessment of total placenta previa by magnetic resonance imaging and ultrasonography to detect placenta accreta and its variants. Ginekologia polska 84(3): 186-92</p>	<p>- Population not relevant to this review protocol <i>Previous caesarean birth or uterus surgery were not stated as inclusion criteria, and no clear information on number of participants with these conditions</i></p>
<p><a href="#">Peng, Lulu, Zhang, Xiang, Liu, Jue et al. (2022) MRI-radiomics-clinical-based nomogram for prenatal prediction of the placenta accreta spectrum disorders.</a> European radiology 32(11): 7532-7543</p>	<p>- Reference standard not relevant to this review protocol <i>Not all participants have operative findings or post caesarean birth examination</i></p>
<p><a href="#">Philips, Jennifer, Gurganus, Margot, DeShields, Sarah et al. (2019) Prevalence of Sonographic Markers of Placenta Accreta Spectrum in Low-Risk Pregnancies.</a> American journal of perinatology 36(8): 733-780</p>	<p>- Population not relevant to this review protocol <i>Only 36% of participants had previous caesarean birth, and participants with placenta praevia were excluded</i></p>
<p>Pilloni, E, Alemanno, M G, Gaglioti, P et al. (2016) Accuracy of ultrasound in antenatal diagnosis of placental attachment disorders. Ultrasound in obstetrics &amp; gynecology : the official journal of the International Society of Ultrasound in Obstetrics and Gynecology 47(3): 302-7</p>	<p>- Population not relevant to this review protocol <i>Only 51% of participants had previous caesarean birth or uterus surgery</i></p>
<p>Polizio, Rodrigo Pamplona, Yamauchi, Fernando Ide, Mendes, Renata Franco Pimentel et al. (2022) Magnetic resonance imaging and previous cesarean section in placenta accrete spectrum disorder: Predictor model. Clinics (Sao Paulo, Brazil) 77: 100027</p>	<p>- Outcome not relevant to this review protocol <i>Diagnostic accuracy of individual parameters but not overall diagnostic accuracy of their combination was reported</i></p>
<p><a href="#">Pongroj paw, Densak, Chanthasenanont, Athita, Nanthakomon, Tongta et al. (2014) Prenatal diagnosis of placenta accreta by colour Doppler ultrasonography: 5-year review.</a> Journal of the Medical Association of Thailand = Chotmaihet thangphaet 97suppl8: 171-4</p>	<p>- Population not relevant to this review protocol <i>No information on whether participants had a low-lying placenta or placenta praevia</i></p>
<p><a href="#">Prakash, Adity, Kumar, Ishan, Verma, Ashish et al. (2023) Comparison of T2-weighted and diffusion-weighted imaging for the diagnosis of placenta accreta spectrum abnormality.</a> Acta radiologica (Stockholm, Sweden : 1987) 64(4): 1694-1701</p>	<p>- Population not relevant to this review protocol <i>Only 50% and 40% of participants had a previous caesarean birth and a placenta praevia, respectively</i></p>
<p><a href="#">Rac, Martha W F, Dashe, Jodi S, Wells, C Edward et al. (2015) Ultrasound predictors of placental invasion: the Placenta Accreta Index.</a> American journal of obstetrics and gynecology 212(3): 343e1-7</p>	<p>- Index test not relevant to this review protocol <i>Placenta accreta index that includes non-radiological parameter (that is, previous caesarean section) was used</i></p>

Study	Code [Reason]
<p><a href="#">Rac, Martha W F, McIntire, Donald D, Wells, C Edward et al. (2017) Cervical Length in Patients at Risk for Placenta Accreta.</a> Journal of ultrasound in medicine : official journal of the American Institute of Ultrasound in Medicine 36(7): 1431-1436</p>	<p>- Outcome not relevant to this review protocol <i>Diagnostic accuracy of an individual parameter was reported</i></p>
<p><a href="#">Rac, Martha W F, Moschos, Elysia, Wells, C Edward et al. (2016) Sonographic Findings of Morbidly Adherent Placenta in the First Trimester.</a> Journal of ultrasound in medicine : official journal of the American Institute of Ultrasound in Medicine 35(2): 263-9</p>	<p>- Outcome not relevant to this review protocol <i>Diagnostic accuracy of an individual parameter was reported</i></p>
<p><a href="#">Radhika, A.G., Bhaskaran, S., Singh, S. et al. (2022) Current Practices in Management of Placenta Accreta Spectrum in Low-resource Settings.</a> Journal of SAFOG 14(2): 172-178</p>	<p>- Reference standard not relevant to this review protocol <i>Not all participants had operative findings or post caesarean birth examination as some participants had vaginal birth</i></p>
<p><a href="#">Rahaim, N S A and Whitby, E H (2015) The MRI features of placental adhesion disorder and their diagnostic significance: systematic review.</a> Clinical radiology 70(9): 917-25</p>	<p>- Systematic review, included studies checked for relevance <i>Included studies published before 2010</i></p>
<p><a href="#">Rahimi-Sharbat, Fatemeh, Jamal, Ashraf, Mesdaghinia, Elaheh et al. (2014) Ultrasound detection of placenta accreta in the first trimester of pregnancy.</a> Iranian journal of reproductive medicine 12(6): 421-6</p>	<p>- Population not relevant to this review protocol <i>Only 53% of participants had a placenta praevia, and no information on whether all participants (or at least 60%) had a previous caesarean birth or uterus surgery</i></p>
<p><a href="#">Ramli, R., Kamaruddin, K.A., Him, L.J. et al. (2019) Morbidly adherent placenta: One-year case series in a tertiary hospital.</a> Medical Journal of Malaysia 74(2): 128-132</p>	<p>- Study design not relevant to this review protocol <i>A case series investigating the clinical characteristics of participants with morbidly adherent placenta</i></p>
<p><a href="#">Rekawek, Patricia, Liu, Lilly, Pan, Stephanie et al. (2022) The clinical utility of magnetic resonance imaging as an adjunct to ultrasound in the diagnosis of placenta accreta spectrum disorders.</a> The journal of maternal-fetal &amp; neonatal medicine : the official journal of the European Association of Perinatal Medicine, the Federation of Asia and Oceania Perinatal Societies, the International Society of Perinatal Obstetricians 35(25): 6008-6012</p>	<p>- Population not relevant to this review protocol <i>Only 56% of participants had placenta praevia</i></p>
<p><a href="#">Ren, Hainan, Mori, Naoko, Mugikura, Shunji et al. (2021) Prediction of placenta accreta spectrum using texture analysis on coronal and sagittal T2-weighted imaging.</a> Abdominal radiology (New York) 46(11): 5344-5352</p>	<p>- Population not relevant to this review protocol <i>Only 55% of participants had a placenta praevia or low-lying placenta</i></p>
<p><a href="#">Riteau, Anne-Sophie, Tassin, Mikael, Chambon, Guillemette et al. (2014) Accuracy of ultrasonography and magnetic resonance imaging in the diagnosis of placenta accreta.</a> PloS one 9(4): e94866</p>	<p>- Reference standard not relevant to this review protocol <i>Not all participants had operative findings or post caesarean birth examination as some participants had vaginal birth</i></p>

Study	Code [Reason]
Romeo, Valeria, Ricciardi, Carlo, Cuocolo, Renato et al. (2019) Machine learning analysis of MRI-derived texture features to predict placenta accreta spectrum in patients with placenta previa. <i>Magnetic resonance imaging</i> 64: 71-76	- Population not relevant to this review protocol <i>No information on whether participants had a previous lower segment caesarean birth or uterus surgery</i>
Ryo, E., Namai, S., Seto, M. et al. (2019) Intraoperative monitoring of placental blood flow after cesarean birth to diagnose placenta accreta spectrum disorder: A preliminary study. <i>International journal of gynaecology and obstetrics: the official organ of the International Federation of Gynaecology and Obstetrics</i>	- Population not relevant to this review protocol <i>Only 50% of participants had previous caesarean birth</i>
<a href="#">Saadat, M., Anjum, M.N., Farooq, F. et al. (2021) Sonographic association of placenta accreta spectrum in patients of placenta previa - A systematic review.</a> <i>Pakistan Journal of Medical and Health Sciences</i> 15(10): 2704-2707	- Systematic review, included studies checked for relevance <i>Included studies published before 2010</i>
<a href="#">Sadeghi Ardakani, Fatemeh, Tara, Fatemeh, Mahmoud Ahmadzade, Amir et al. (2023) Evaluation of the Relationship Between Quantitative Ultrasound Findings and Morbidly Adherent Placenta.</a> <i>Journal of ultrasonography</i> 23(92): 10-14	- Population not relevant to this review protocol <i>No information on whether participants had a low-lying placenta or placenta praevia</i>
<a href="#">Sahin, Erdem, Madendag, Yusuf, Eraslan Sahin, Mefkure et al. (2022) Evaluation of the diagnostic accuracy of a combination of first-trimester ultrasound and maternal demographic characteristics for detecting abnormally invasive placenta.</a> <i>European journal of obstetrics, gynecology, and reproductive biology</i> 268: 1-6	- Study design not relevant to this review protocol <i>Case-control study investigates diagnostic accuracy of Sahin Score (including non-radiological parameters), and no information on whether participants had a low-lying placenta or placenta praevia</i>
Salehgargari, S., Pooransari, P., Mirzamoradi, M. et al. (2021) A retrospective study of emergency obstetric hysterectomy in Iran for a period of 3 years abstract. <i>Pakistan Journal of Medical and Health Sciences</i> 15(4): 1525-1529	- Population not relevant to this review protocol <i>Only 58% of participants had placenta praevia</i>
Sannananja, Bhagya, Ellermeier, Anna, Hippe, Daniel S et al. (2018) Utility of diffusion-weighted MR imaging in the diagnosis of placenta accreta spectrum abnormality. <i>Abdominal radiology (New York)</i> 43(11): 3147-3156	- Population not relevant to this review protocol <i>Only 50% of participants had a placenta praevia</i>
<a href="#">Sargent, Will; Gerry, Stephen; Collins, Sally L (2023) A Risk-Prediction Model for Placenta Accreta Spectrum Severity From Standardized Ultrasound Markers.</a> <i>Ultrasound in medicine &amp; biology</i> 49(2): 512-519	- Data not reported in an extractable format or a format that can be analysed <i>No sufficient data to calculate the outcomes</i>
Sato, Tomomi, Mori, Naoko, Hasegawa, Osamu et al. (2017) Placental recess accompanied by a T2 dark band: a new finding for diagnosing placental invasion. <i>Abdominal radiology (New York)</i> 42(8): 2146-2153	- Population not relevant to this review protocol <i>Only 41% of participants had a previous caesarean birth</i>

Study	Code [Reason]
Sattar, A., Bashir, H., Rana, S. et al. (2020) Diagnostic value of Magnetic Resonance Imaging (MRI) in morbidly adherent placenta, taking surgical findings as gold standard. Medical Forum Monthly 31(8): 8-11	- Population not relevant to this review protocol <i>No information on whether participants had a previous lower segment caesarean birth or uterus surgery and a low-lying placenta or placenta praevia</i>
<a href="#">Shao, Qian, Xuan, Rongrong, Wang, Yutao et al. (2021) Deep learning and radiomics analysis for prediction of placenta invasion based on T2WI.</a> Mathematical biosciences and engineering : MBE 18(5): 6198-6215	- Reference standard not relevant to this review protocol <i>No information on whether all participants had operative findings with/without histology reports/lab findings and post caesarean birth examination with histology</i>
<a href="#">Shawky, M.; AbouBieh, E.; Masood, A. (2016) Gray scale and Doppler ultrasound in placenta accreta: Optimization of ultrasound signs.</a> Egyptian Journal of Radiology and Nuclear Medicine 47(3): 1111-1115	- Outcome not relevant to this review protocol <i>Diagnostic accuracy of individual parameters but not overall diagnostic accuracy of their combination was reported</i>
<a href="#">Shi, J., Yang, M., Cao, X. et al. (2023) Identification of circular RNAs as regulators and noninvasive biomarkers for placenta accreta spectrum.</a> Reproduction 165(4): 417-430	- Population not relevant to this review protocol <i>Only 50% of participants had previous caesarean birth</i>
<a href="#">Shih, Jin-Chung, Kang, Jessica, Tsai, Shang-Jie et al. (2021) The "rail sign": an ultrasound finding in placenta accreta spectrum indicating deep villous invasion and adverse outcomes.</a> American journal of obstetrics and gynecology 225(3): 292e1-292e17	- Outcome not relevant to this review protocol <i>Diagnostic accuracy of an individual parameter was reported</i>
<a href="#">Skupski, D W, Duzyj, C M, Scholl, J et al. (2022) Evaluation of classic and novel ultrasound signs of placenta accreta spectrum.</a> Ultrasound in obstetrics & gynecology : the official journal of the International Society of Ultrasound in Obstetrics and Gynecology 59(4): 465-473	- Population not relevant to this review protocol <i>Only 47% of participants had a previous caesarean birth or uterus surgery</i>
Stanzione, Arnaldo, Verde, Francesco, Cuocolo, Renato et al. (2022) Placenta Accreta Spectrum Disorders and Radiomics: Systematic review and quality appraisal. European journal of radiology 155: 110497	- Systematic review, included studies checked for relevance <i>Included studies (for example, Chen 2019) with no information on whether participants had a low-lying placenta or placenta praevia</i>
<a href="#">Stewart, Michael John, Richmond, Danielle, Mooney, Samantha et al. (2021) Diagnostic Utility of MRI Features of Placental Adhesion Disorder for Abnormal Placentation and Massive Postpartum Hemorrhage.</a> AJR. American journal of roentgenology 217(2): 378-388	- Population not relevant to this review protocol <i>No information on whether participants had a low-lying placenta or placenta praevia</i>
<a href="#">Stirnemann, Julien J, Mousty, Eve, Chalouhi, Gihad et al. (2011) Screening for placenta accreta at 11-14 weeks of gestation.</a> American journal of obstetrics and gynecology 205(6): 547e1-6	- Population not relevant to this review protocol <i>No information on whether participants had a low-lying placenta or placenta praevia</i>
<a href="#">Sun, Huaiqiang, Qu, Haibo, Chen, Lu et al. (2019) Identification of suspicious invasive placentation</a>	- Population not relevant to this review protocol

Study	Code [Reason]
<p><a href="#">based on clinical MRI data using textural features and automated machine learning.</a> European radiology 29(11): 6152-6162</p>	<p><i>No information on whether participants had a previous caesarean birth or uterus surgery</i></p>
<p><a href="#">Sun, Xue, Ren, Runrun, Yu, Xiaoqian et al. (2022) Application of Color Doppler Ultrasound Combined with Magnetic Resonance Imaging in Placenta Accreta.</a> Scanning 2022: 1050029</p>	<p>- Population not relevant to this review protocol <i>Only 55% of participants had a previous caesarean birth or uterus surgery</i></p>
<p><a href="#">Svanvik, Teresia; Jacobsson, Anna-Karin; Carlsson, Ylva (2022) Prenatal detection of placenta previa and placenta accreta spectrum: Evaluation of the routine mid-pregnancy obstetric ultrasound screening between 2013 and 2017.</a> International journal of gynaecology and obstetrics: the official organ of the International Federation of Gynaecology and Obstetrics 157(3): 647-653</p>	<p>- Study design not relevant to this review protocol <i>Not a diagnostic accuracy study</i></p>
<p>Tanimura, Kenji, Morizane, Mayumi, Deguchi, Masashi et al. (2018) A novel scoring system for predicting adherent placenta in women with placenta previa. Placenta 64: 27-33</p>	<p>- Population not relevant to this review protocol <i>Only 8% of participants had a previous uterus surgery, and no information on whether all participants (or at least 60%) had a previous caesarean birth</i></p>
<p><a href="#">Tanimura, Kenji, Yamasaki, Yui, Ebina, Yasuhiko et al. (2015) Prediction of adherent placenta in pregnancy with placenta previa using ultrasonography and magnetic resonance imaging.</a> European journal of obstetrics, gynecology, and reproductive biology 187: 41-4</p>	<p>- Population not relevant to this review protocol <i>No information on number of participants with previous caesarean birth or uterus surgery, and these were not stated as inclusion criteria</i></p>
<p><a href="#">Thiravit, Shanigarn, Lapatikarn, Sukanya, Muangsomboon, Kobkun et al. (2017) MRI of placenta percreta: differentiation from other entities of placental adhesive disorder.</a> La Radiologia medica 122(1): 61-68</p>	<p>- Study design not relevant to this review protocol <i>Prognostic study that investigates MRI features to classify placenta accreta spectrum (severity)</i></p>
<p><a href="#">Thiravit, Shanigarn, Ma, Kimberly, Goldman, Inessa et al. (2021) Role of Ultrasound and MRI in Diagnosis of Severe Placenta Accreta Spectrum Disorder: An Intraindividual Assessment With Emphasis on Placental Bulge.</a> AJR. American journal of roentgenology 217(6): 1377-1388</p>	<p>- Outcome not relevant to this review protocol <i>Study did not assess diagnostic accuracy of imaging for PAS as per protocol</i></p>
<p><a href="#">Tian, Gan, Liu, Zhaofa, Zhang, Dawei et al. (2022) Prospective comparative analysis for application and selection of FIESTA sequence and SSFSE sequence in MRI for prenatal diagnosis of placenta previa accreta.</a> Journal of obstetrics and gynaecology : the journal of the Institute of Obstetrics and Gynaecology 42(6): 2051-2057</p>	<p>- Population not relevant to this review protocol <i>No information on whether participants had a previous lower segment caesarean birth or uterus surgery</i></p>
<p>Tinari, S, Buca, D, Cali, G et al. (2021) Risk factors, histopathology and diagnostic accuracy in posterior placenta accreta spectrum disorders: systematic review and meta-analysis. Ultrasound in obstetrics &amp; gynecology : the official journal of</p>	<p>- Systematic review, included studies checked for relevance <i>Included studies published before 2010</i></p>

Study	Code [Reason]
the International Society of Ultrasound in Obstetrics and Gynecology 57(6): 903-909	
<a href="#">Tovbin, J, Melcer, Y, Shor, S et al. (2016) Prediction of morbidly adherent placenta using a scoring system.</a> Ultrasound in obstetrics & gynecology : the official journal of the International Society of Ultrasound in Obstetrics and Gynecology 48(4): 504-510	<p>- Outcome not relevant to this review protocol <i>Diagnostic accuracy of scoring system that includes non radiological parameter (that is, previous caesarean section) was reported, and presence of placenta praevia or low-lying placenta were not reported as inclusion criteria</i></p>
<a href="#">Ueno, Yoshiko, Kitajima, Kazuhiro, Kawakami, Fumi et al. (2014) Novel MRI finding for diagnosis of invasive placenta praevia: evaluation of findings for 65 patients using clinical and histopathological correlations.</a> European radiology 24(4): 881-8	<p>- Outcome not relevant to this review protocol <i>Diagnostic accuracy of individual parameters but not overall diagnostic accuracy of their combination was reported</i></p>
Ueno, Yoshiko, Maeda, Tetsuo, Tanaka, Utaru et al. (2016) Evaluation of interobserver variability and diagnostic performance of developed MRI-based radiological scoring system for invasive placenta praevia. Journal of magnetic resonance imaging : JMIR 44(3): 573-83	<p>- Population not relevant to this review protocol <i>Only 51% of participants had a previous caesarean birth or uterus surgery</i></p>
Valentini, Anna Lia, Gui, Benedetta, Ninivaggi, Valeria et al. (2017) The morbidly adherent placenta: when and what association of signs can improve MRI diagnosis? Our experience. Diagnostic and interventional radiology (Ankara, Turkey) 23(3): 180-186	<p>- Population not relevant to this review protocol <i>Only 51% of participants had a previous caesarean birth or uterus surgery</i></p>
<a href="#">Wang, Y-L, Duan, X-H, Han, X-W et al. (2017) Abnormal placentation: the role of MRI in diagnosis and therapeutic planning.</a> Clinical radiology 72(2): 176e9-176e14	<p>- Population not relevant to this review protocol <i>No information on whether participants had a previous lower segment caesarean birth or uterus surgery, and only 45% of participants had a placenta praevia</i></p>
<a href="#">Wang, Yan, Gao, Yan, Zhao, Yangyu et al. (2018) Ultrasonographic diagnosis of severe placental invasion.</a> The journal of obstetrics and gynaecology research 44(3): 448-455	<p>- Study design not relevant to this review protocol <i>A case-control study design was used, and not all participants had operative findings or post caesarean birth examination</i></p>
<a href="#">Woodring, T Casey, Klauser, Chad K, Bofill, James A et al. (2011) Prediction of placenta accreta by ultrasonography and color Doppler imaging.</a> The journal of maternal-fetal & neonatal medicine : the official journal of the European Association of Perinatal Medicine, the Federation of Asia and Oceania Perinatal Societies, the International Society of Perinatal Obstetricians 24(1): 118-21	<p>- Data not reported in an extractable format or a format that can be analysed <i>Only index text positive cases were included</i></p>
<a href="#">Xi, Yin, Shahedi, Maysam, Do, Quyen N et al. (2021) Assessing reproducibility in Magnetic Resonance (MR) Radiomics features between Deep-Learning segmented and Expert Manual segmented data and evaluating their diagnostic performance in Pregnant Women with suspected Placenta Accreta Spectrum (PAS).</a> Proceedings of	<p>- Population not relevant to this review protocol <i>No information on whether participants had a previous lower segment caesarean birth or uterus surgery and a low-lying placenta or placenta praevia</i></p>



Study	Code [Reason]
SPIE--the International Society for Optical Engineering 11597	
<a href="#">Xia, Hui, Ke, Shu-Cheng, Qian, Rong-Rong et al. (2020) Comparison between abdominal ultrasound and nuclear magnetic resonance imaging detection of placenta accreta in the second and third trimester of pregnancy.</a> <i>Medicine</i> 99(2): e17908	<p>- Reference standard not relevant to this review protocol <i>Not all participants had operative findings or post caesarean birth examination as some participants had vaginal birth</i></p>
<a href="#">Xuan, Rongrong, Li, Tao, Wang, Yutao et al. (2021) Prenatal prediction and typing of placental invasion using MRI deep and radiomic features.</a> <i>Biomedical engineering online</i> 20(1): 56	<p>- Population not relevant to this review protocol <i>No information on whether participants had a previous lower segment caesarean birth or uterus surgery and a low-lying placenta or placenta praevia</i></p>
Yan, Guohui, Liao, Yuhao, Li, Kui et al. (2022) Diffusion MRI Based Myometrium Tractography for Detection of Placenta Accreta Spectrum Disorder. <i>Journal of magnetic resonance imaging</i> : <i>JMRI</i> 55(1): 255-264	<p>- Population not relevant to this review protocol <i>No information on whether participants a low-lying placenta or placenta praevia, and only 51% of participants had a previous caesarean birth</i></p>
<a href="#">Yang, Ang, Xiao, Xue Hong, Wang, Zhi Long et al. (2018) T2-weighted balanced steady-state free procession MRI evaluated for diagnosing placental adhesion disorder in late pregnancy.</a> <i>European radiology</i> 28(9): 3770-3778	<p>- Outcome not relevant to this review protocol <i>Diagnostic accuracy of individual parameters but not overall diagnostic accuracy of their combination was reported</i></p>
<a href="#">Yang, Xiao; Chen, Zheng; Jia, Xiaozhou (2022) Deep Learning Algorithm-Based Ultrasound Image Information in Diagnosis and Treatment of Pernicious Placenta Previa.</a> <i>Computational and mathematical methods in medicine</i> 2022: 3452176	<p>- Index test not relevant to this review protocol <i>Scoring scale that includes non-radiological parameter (that is, previous caesarean section, prenatal bleeding and abortion) was used</i></p>
<a href="#">Yang, Xinrui, Zheng, Weiran, Yan, Jie et al. (2022) Comparison between placenta accreta scoring system, ultrasound staging, and clinical classification.</a> <i>Medicine</i> 101(46): e31622	<p>- Population not relevant to this review protocol <i>No information on whether participants had a previous lower segment caesarean birth or uterus surgery</i></p>
Ye, Caihong, Ling, Li, Li, Shuo et al. (2023) Comparisons of the diagnostic accuracy of the ultrasonic sign-score method and MRI for PA, PI and PP in high-risk gravid women: a retrospective study. <i>Annals of translational medicine</i> 11(2): 81	<p>- Study design not relevant to this review protocol <i>Prognostic study that investigates ultrasound scoring system that includes non radiological parameter (that is, previous caesarean section) and MRI features to classify placenta accreta spectrum (severity), and placenta praevia or low-lying placenta in current pregnancy were not reported as inclusion criteria</i></p>
<a href="#">Ye, Zhengjie, Xuan, Rongrong, Ouyang, Menglin et al. (2022) Prediction of placenta accreta spectrum by combining deep learning and radiomics using T2WI: a multicenter study.</a> <i>Abdominal radiology (New York)</i> 47(12): 4205-4218	<p>- Population not relevant to this review protocol <i>Only 40% and 14% of participants had placenta praevia and caesarean birth or curettage, respectively</i></p>
<a href="#">Yule, Casey S, Lewis, Matthew A, Do, Quyen N et al. (2021) Transvaginal Color Mapping Ultrasound in the First Trimester Predicts Placenta Accreta</a>	<p>- Population not relevant to this review protocol <i>Only 57% of participants had a previous caesarean birth</i></p>

Study	Code [Reason]
<p><a href="#">Spectrum: A Retrospective Cohort Study</a>. Journal of ultrasound in medicine : official journal of the American Institute of Ultrasound in Medicine 40(12): 2735-2743</p>	
<p><a href="#">Zawaideh, Jeries P, Freeman, Susan, Smith, Janette et al. (2022) Placental MRI: Identification of radiological features to predict placental attachment disease regardless of reader expertise</a>. European journal of radiology 149: 110203</p>	<p>- Population not relevant to this review protocol <i>No information on whether participants had a previous lower segment caesarean birth or uterus surgery</i></p>
<p><a href="#">Zhang, Jing and Dong, Pingping (2022) Clinical Utility of the Prenatal Ultrasound Score of the Placenta Combined with Magnetic Resonance Imaging in Diagnosis of Placenta Accreta during the Second and Third Trimester of Pregnancy</a>. Contrast media &amp; molecular imaging 2022: 9462139</p>	<p>- Population not relevant to this review protocol <i>Only 35% of participants had a previous caesarean birth</i></p>
<p><a href="#">Zhang, Junling, Li, Hezhou, Wang, Fang et al. (2018) Prenatal Diagnosis of Abnormal Invasive Placenta by Ultrasound: Measurement of Highest Peak Systolic Velocity of Subplacental Blood Flow</a>. Ultrasound in medicine &amp; biology 44(8): 1672-1678</p>	<p>- Outcome not relevant to this review protocol <i>Diagnostic accuracy of individual parameters but not overall diagnostic accuracy of their combination was reported</i></p>
<p><a href="#">Zhang, L. (2022) Application Value of Sonographic Scoring Method in the Diagnosis of Singleton Angular Pregnancy and Angular Villi or Placenta Accrete</a>. Clinical and Experimental Obstetrics and Gynecology 49(6): 125</p>	<p>- Data not reported in an extractable format or a format that can be analysed</p>
<p><a href="#">Zhang, S.-H., Zhang, J.-Y., Zhang, J. et al. (2019) Use of Postpartum Magnetic Resonance Imaging for Diagnosis and Classification of Retained Placenta Tissue</a>. Journal of Computer Assisted Tomography 43(1): 128-135</p>	<p>- Population not relevant to this review protocol <i>Only 9% and 50% of participants had a history of placenta praevia and caesarean birth, respectively</i></p>
<p><a href="#">Zhang, Xiaoyan; Liu, Fengfeng; Wang, Xiaoyan (2022) Application of Ultrasound Combined with Magnetic Resonance Imaging in the Diagnosis and Grading of Patients with Prenatal Placenta Accreta</a>. Scanning 2022: 1199210</p>	<p>- Population not relevant to this review protocol <i>No information on whether participants had a low-lying placenta or placenta praevia</i></p>
<p>Zheng, W., Zhang, H., Ma, J. et al. (2022) Validation of a scoring system for prediction of obstetric complications in placenta accreta spectrum disorders. Journal of Maternal-Fetal and Neonatal Medicine 35(21): 4149-4155</p>	<p>- Index test not relevant to this review protocol <i>A scoring system that includes non-radiological parameter (that is, previous caesarean section and abortion) was used</i></p>
<p><a href="#">Zheng, Xiaoxiao, Li, Xiaoqiong, Xu, Jinxia et al. (2021) Intelligent Recognition Algorithm-Based Color Doppler Ultrasound in the Treatment of Dangerous Placenta Previa</a>. Journal of healthcare engineering 2021: 9886521</p>	<p>- Data not reported in an extractable format or a format that can be analysed</p>

Study	Code [Reason]
Zhou, J, Li, J, Yan, P et al. (2014) Maternal plasma levels of cell-free beta-HCG mRNA as a prenatal diagnostic indicator of placenta accrete. <i>Placenta</i> 35(9): 691-5	- Outcome not relevant to this review protocol <i>Diagnostic accuracy of individual parameters but not overall diagnostic accuracy of their combination was reported</i>
<a href="#">Zhu, Hao, Yin, Xuan, Wang, Haijie et al. (2022) A computerized diagnostic model for automatically evaluating placenta accrete spectrum disorders based on the combined MR radiomics-clinical signatures.</a> <i>Scientific reports</i> 12(1): 10130	- Reference standard not relevant to this review protocol <i>19.3% of participants had vaginal birth, so they did not have operative findings or post caesarean birth examination, and only 22.5% of participants had a previous caesarean birth</i>
<a href="#">Zhu, Lingling and Xie, Limei (2019) Value of ultrasound scoring system for assessing risk of pernicious placenta previa with accreta spectrum disorders and poor pregnancy outcomes.</a> <i>Journal of medical ultrasonics</i> (2001) 46(4): 481-487	- Outcome not relevant to this review protocol <i>Diagnostic accuracy of a scoring system was reported</i>
<a href="#">Zosmer, Nurit, Jauniaux, Eric, Bunce, Catey et al. (2018) Interobserver agreement on standardized ultrasound and histopathologic signs for the prenatal diagnosis of placenta accreta spectrum disorders.</a> <i>International journal of gynaecology and obstetrics: the official organ of the International Federation of Gynaecology and Obstetrics</i> 140(3): 326-331	- Outcome not relevant to this review protocol <i>Diagnostic accuracy of individual parameters but not overall diagnostic accuracy of their combination was reported</i>
<a href="#">Zou, Lue, Wang, Pengyuan, Song, Zixuan et al. (2022) Effectiveness of a fetal magnetic resonance imaging scoring system for predicting the prognosis of pernicious placenta previa: A retrospective study.</a> <i>Frontiers in physiology</i> 13: 921273	- Reference standard not relevant to this review protocol <i>A scoring system that includes non-radiological parameter (that is, previous caesarean section) was used</i>

PAS: placenta accreta spectrum

### Excluded economic studies

No economic evidence was identified for this review.

## **Appendix K Research recommendations – full details**

**Research recommendations for review question: What is the accuracy of imaging techniques for diagnosis of a placenta accreta spectrum (PAS) in pregnant women who have had a previous caesarean birth and are currently diagnosed with placenta praevia?**

No research recommendations were made for this review question.