

Endometriosis

[A] Diagnosing endometriosis

NICE guideline number NG73 (update)

Evidence review underpinning recommendations 1.3.2, 1.5.1, 1.5.3, 1.5.4 and 1.5.9 to 1.5.13 and 1.5.15. in the NICE guideline

March 2024

Draft for consultation

Disclaimer

The recommendations in this guideline represent the view of NICE, arrived at after careful consideration of the evidence available. When exercising their judgement, professionals are expected to take this guideline fully into account, alongside the individual needs, preferences and values of their patients or service users. The recommendations in this guideline are not mandatory and the guideline does not override the responsibility of healthcare professionals to make decisions appropriate to the circumstances of the individual patient, in consultation with the patient and/or their carer or guardian.

Local commissioners and/or providers have a responsibility to enable the guideline to be applied when individual health professionals and their patients or service users wish to use it. They should do so in the context of local and national priorities for funding and developing services, and in light of their duties to have due regard to the need to eliminate unlawful discrimination, to advance equality of opportunity and to reduce health inequalities. Nothing in this guideline should be interpreted in a way that would be inconsistent with compliance with those duties.

NICE guidelines cover health and care in England. Decisions on how they apply in other UK countries are made by ministers in the [Welsh Government](#), [Scottish Government](#), and [Northern Ireland Executive](#). All NICE guidance is subject to regular review and may be updated or withdrawn.

Copyright

© NICE 2024. All rights reserved. Subject to [Notice of rights](#).

ISBN:

Contents

Diagnosing endometriosis	6
Review question	6
Introduction	6
Summary of protocol	6
Methods and process	7
Diagnostic evidence	7
Summary of included studies	10
Summary of the evidence	18
Summary of included economic evidence	25
Economic model	27
Unit costs	Error! Bookmark not defined.
Evidence statements	28
The committee’s discussion and interpretation of the evidence	28
Recommendations supported by this evidence review	33
References – included studies	34
Appendices	38
Appendix A Review protocols	38
Review protocol for review question: What is the accuracy of the following tests in diagnosing endometriosis:	38
Appendix B Literature search strategies	49
Literature search strategies for review question: What is the accuracy of the following tests in diagnosing endometriosis:	49
Appendix C Diagnostic evidence study selection	58
Study selection for: What is the accuracy of the following tests in diagnosing endometriosis:	58
Appendix D Evidence tables	59
Evidence tables for review question: What is the accuracy of the following tests in diagnosing endometriosis:	59
Appendix E Forest plots	153
Forest plots for review question: What is the accuracy of the following tests in diagnosing endometriosis:	153
Appendix F GRADE tables	158
GRADE tables for review question: What is the accuracy of the following tests in diagnosing endometriosis:	158
Appendix G Economic evidence study selection	180
Study selection for: Insert review question	180
Appendix H Economic evidence tables	181
Economic evidence tables for review question: insert review question	181
Appendix I Economic model	185
Economic model for review question: insert review question	185

Appendix J	Excluded studies	186
	Excluded studies for review question: What is the accuracy of the following tests in diagnosing endometriosis:	186
	Excluded diagnostic studies.....	186
Appendix K	Research recommendations – full details	203
	Research recommendations for review question: What is the accuracy of the following tests in diagnosing endometriosis:	203

1 Diagnosing endometriosis

2 Review question

3 What is the accuracy of the following tests in diagnosing endometriosis:

- 4 • imaging
- 5 • biomarkers
- 6 • surgical diagnosis (open surgery or laparoscopic surgery)?

7 Introduction

8 Endometriosis is a chronic inflammatory disease affecting up to 10% of women, defined as
9 the presence of endometrium-like tissue outside the uterus. Endometriosis can cause chronic
10 pain affecting daily activities and quality of life, particularly on a cyclical basis. It can also
11 cause heavy periods as well as urinary and gastrointestinal symptoms. However, some
12 women with endometriosis will not have any symptoms. A delay in the diagnosis of
13 endometriosis could lead to prolongation and exacerbation of symptoms and may also lead
14 to impaired fertility and damage to other organs such as the bowel and urinary system. Early
15 and accurate diagnosis of endometriosis is important to improve symptoms, for optimal
16 management and to slow or stop the progression of the disease. Diagnostic strategies for
17 endometriosis include ultrasound imaging, MRI, biomarker tests and surgery.

18 The aim of this review is to evaluate the accuracy of diagnostic tests for the diagnosis of
19 endometriosis in women with suspected endometriosis.

20 Summary of protocol

21 See Table 1 for a summary of the Population, Index tests, Reference standard and Target
22 condition (PIRT) characteristics of this review.

23 **Table 1: Summary of the protocol (PIRT table)**

Population	Symptomatic and asymptomatic women with suspected endometriosis Note: Post-menopausal women will be included. Women with scar tissue have anatomical distortion, so this population will not be excluded.
Index test	1. Ultrasound <ul style="list-style-type: none">• transabdominal• transvaginal• rectal scanning 2. MRI <ul style="list-style-type: none">• pelvic, thoracic and abdominal MRI• all types of MRI 3. Biomarkers <ul style="list-style-type: none">• CA-125• HE-4• PGP 9.5• microRNAs 4. Surgery <ul style="list-style-type: none">• surgical diagnosis without histological confirmation

	5. combination of tests
Reference standard	Surgical visualisation with histological confirmation
Target condition	Endometriosis
Outcome	Critical: <ul style="list-style-type: none">• Diagnostic test accuracy data• Sensitivity and specificity Decision thresholds are: sensitivity: high threshold $\geq 90\%$, low threshold $< 60\%$ specificity: high threshold $\geq 90\%$, low threshold $< 60\%$ Important: <ul style="list-style-type: none">• Diagnostic test accuracy data• Positive and negative predictive values

1 CA-125: cancer antigen 125; HE-4L Human epididymis protein 4; MRI: magnetic resonance imaging; PGP 9.5:
2 Protein Gene Product 9.5

3 For further details see the review protocol in appendix A.

4 **Methods and process**

5 This evidence review was developed using the methods and process described in
6 [Developing NICE guidelines: the manual](#). Methods specific to this review question are
7 described in the review protocol in appendix A.

8 Declarations of interest were recorded according to [NICE's conflicts of interest policy](#).

9 **Diagnostic evidence**

10 **Included studies**

11 Twenty nine studies were included for this review, 18 prospective studies (Alborzi 2018,
12 Barra 2021a, Barra 2021b, Bratila 2016, El-Maadawy 2021, Ferrero 2017, Ferrero 2019,
13 Goncalves 2021, Jiang 2017, Kamkarfar 2022, Montanari 2022, Puri 2022, Rokhgireh 2020,
14 Ros 2021, Shahbazi 2022, Siddiqui 2021, Zannoni 2017, Zhang 2019) and 11 retrospective
15 studies (Alborzi 2023, Asgari 2022, Barcellos 2016, Chen 2019, Di Giovanni 2022, Gratton
16 2022, Harth 2023, Hausmann 2021, Hernandez Gutierrez 2019, Roditis 2023,
17 Widschwendter 2022).

18 **Population**

19 All studies included women with suspected endometriosis. Twenty-four studies included
20 women with symptoms of endometriosis, such as pelvic pain, dyspareunia and
21 dysmenorrhea (Alborzi 2018, Alborzi 2023, Asgari 2022, Barcellos 2016, Barra 2021a, Barra
22 2021b, Bratila 2016, Chen 2019, Di Giovanni 2022, El-Maadawy 2021, Ferrero 2017, Ferrero
23 2019, Goncalves 2021, Gratton 2022, Harth 2023, Hernandez Gutierrez 2019, Jiang 2017,
24 Kamkarfar 2022, Montanari 2022, Roditis 2023, Rokhgireh 2020, Ros 2021, Widschwendter
25 2022, Zannoni 2017). Five studies did not report whether women were symptomatic or
26 asymptomatic (Hausmann 2021, Puri 2022, Shahbazi 2022, Siddiqui 2021 and Zhang 2019).

27 The studies were conducted in Australia, Austria, Brazil, Canada, China, Egypt, France,
28 Germany, Hungary, India, Iran, Italy, Pakistan, Romania, Spain and Switzerland.

29 There was variation across studies with regard to settings, with some reporting tertiary
30 centres and others not reporting whether centres were secondary or tertiary.

1 **Index tests**

2 Twenty studies investigated diagnostic test accuracy (DTA) of transvaginal ultrasound
3 (Alborzi 2018, Alborzi 2023, Asgari 2022, Barra 2021a, Barra 2021b, Bratila 2016, Chen
4 2019, Di Giovanni 2022, El-Maadawy 2021, Ferrero 2017, Ferrero 2019, Goncalves 2021,
5 Hernandez Gutierrez 2019, Jiang 2017, Kamkarfar 2022, Roditis 2023, Ros 2021, Shahbazi
6 2022, Zannoni 2017 and Zhang 2019). One study investigated transvaginal ultrasound with
7 3D (Barra 2021a). Three studies investigated DTA of transrectal ultrasound (Alborzi 2018,
8 Asgari 2022, Chen 2019). One study investigated DTA of transabdominal ultrasound (Puri
9 2022). One study investigated DTA of combined transvaginal and transrectal ultrasound
10 (Asgari 2022) and 1 study investigated DTA of combined transvaginal and transabdominal
11 ultrasound (Montanari 2022).

12 Ten studies investigated DTA of magnetic resonance imaging (MRI) (Alborzi 2018, Alborzi
13 2023, Chen 2019, Harth 2023, Hausmann 2021, Puri 2022, Roditis 2023, Shahbazi 2022,
14 Siddiqui 2021, Widschwendter 2022). Six studies investigated MRI with contrast (Alborzi
15 2018, Alborzi 2023, Chen 2019, Harth 2023, Hausmann 2021 and Siddiqui 2021). Four
16 studies did not report whether contrast was used or not (Barcellos 2016, Puri 2022, Roditis
17 2023 and Shahbazi 2022). One study reported that contrast was not used with MRI
18 (Widschwendter 2022). All types of MRI were considered as per the protocol.

19 Eight studies looked at more than 1 imaging technique (Alborzi 2018, Alborzi 2023, Asgari
20 2022, Chen 2019, Hernandez Gutierrez 2019, Puri 2022, Roditis 2023 and Shahbazi 2022).

21 Two studies investigated DTA of combined imaging, ultrasound with MRI (Barcellos 2016,
22 Roditis 2023).

23 One study investigated DTA of the biomarker cancer antigen 125 (CA-125) (Rokhgireh
24 2020). There was no evidence identified for the biomarkers human epididymis protein 4 (HE-
25 4), biomarkers in endometrial tissues (the nerve fibre marker Protein Gene Product 9.5 (PGP
26 9.5)) or microRNAs.

27 One study investigated DTA of laparoscopy without histology (Gratton 2022). There was no
28 evidence identified for open surgery or other operative procedures.

29 Most studies did not report the timing of the tests. Where reported, index tests were
30 performed from 2 weeks to 2 years before the reference standard.

31 Not all studies provided information on the healthcare professional who performed the
32 imaging index tests, and where reported there was variation with regard to their experience.
33 For ultrasound, the healthcare professional ranged from a gynaecologist with specialist
34 knowledge in endometriosis, to sonographers with a range of experience in gynaecological
35 imaging (some studies did not report the years of experience, and in other studies this
36 ranged from 3 up to 30 years of experience). For MRI imaging, where reported, the
37 healthcare professional was a radiologist with 3 to 7 years of experience.

38 **Reference standard**

39 All studies in the review used laparoscopy with histology as the reference standard.

40 **Target condition**

41 The target condition was endometriosis. Some studies reported deep endometriosis
42 separately and some reported both deep and superficial together.

43 **Outcome measures**

44 Sensitivity and specificity were prioritised in this review. Most studies reported the diagnostic
45 test accuracy (DTA) data, (that is, true positive, false positive, true negative, and false
46 negative) that allow calculation of sensitivity and specificity. Where the study did not report

1 DTA data, the sensitivity and specificity were extracted directly from the study (Montanari
2 2022). One study (Hernandez Gutierrez 2019) did not report DTA data, and reported
3 sensitivity and specificity. These data were extracted however they were not used in the
4 analysis as the confidence intervals were not reported by the study, and therefore it was not
5 possible to judge the imprecision of the data, and therefore the overall quality of the study.
6 Studies that only reported index test positive cases (that is, true positive and false positive)
7 were excluded as this does not allow accurate calculation of sensitivity and specificity.
8 Positive predictive values (PPV) and negative predictive values (NPV) were considered only
9 if sensitivity and specificity data were not available, but as the relevant studies provided
10 sensitivity and specificity data, PPV and NPV values were not extracted.

11 The following decision thresholds were used for sensitivity and specificity:

12 (1) low sensitivity or specificity (defined as <60%)

13 (2) moderate sensitivity or specificity (defined as ≥60% to <90%)

14 (3) high sensitivity or specificity (defined as ≥90%).

15 The evidence was downgraded by one level when the confidence interval around the point
16 estimate crossed one of the decision-making thresholds (0.60 or 0.90) and by two levels
17 when the confidence interval around the point estimate crossed both of the decision-making
18 thresholds. The upper threshold marked the point above which recommendations would be
19 possible, and the lower threshold marked the point below which the test would be regarded
20 as of no clinical use. Heterogeneity (inconsistency) was assessed by visual inspection of the
21 point estimates and confidence intervals of the included studies. The evidence was
22 downgraded if these varied widely between studies, for example, point estimates for some
23 studies lying outside the CIs of other studies. Weighted subjective judgement was used to
24 downgrade once or twice for heterogeneity (serious and very serious heterogeneity).
25 Random effect analysis was used in Winbugs meta-analysis.

26 **Analysis**

27 Meta-analysis was performed where possible (for example, if there were at least three
28 studies reporting the same index test) and where there was no excessive variation between
29 studies or very serious heterogeneity. For those where meta-analysis could not be
30 performed, the results for each individual study have been reported in the review. Where
31 meta-analysis was not performed because of very heterogenous results between studies,
32 reasons for heterogeneity in the individual studies was explored. The approach was taken to
33 explore heterogeneity separately for the individual measures for sensitivity and specificity.
34 Although these 2 measures are paired measures, they measure the index test ability in 2
35 separate populations, those with the target condition and those without the target condition.
36 Differences or similarities in one of these populations may not necessarily translate to the
37 other population, and therefore heterogeneity of sensitivity and specificity results have been
38 assessed separately and based on this it was decided if to meta-analyse or not.

39 In this review, studies were categorised and reported separately according to type of imaging
40 (ultrasound or MRI), surgery (laparoscopy) or biomarkers (CA-125). Different ultrasound
41 approaches were analysed and reported separately in the following groups: Transvaginal,
42 transrectal, transabdominal and any combinations of ultrasound approaches. All types of
43 MRI, that is with or without contrast, were analysed together. The data were also stratified by
44 site of the endometriosis, and then by the depth (either deep or superficial). In studies
45 reporting endometrioma, depth was not reported as this is not applicable for this site.

46 Most studies reported depth of invasion; however the depth of the endometriosis was unclear
47 in some instances and in such cases it has been noted as unspecified depth. Where studies
48 reported the site as rectum, or rectal wall, these sites were classified as rectosigmoid in the
49 review. In the event of heterogeneity, there was not enough evidence to perform sub-group
50 analysis by ethnicity, as stated in the protocol.

1 The new evidence identified from this review update was not pooled with evidence from
2 previous review versions due to differences in stratifications, as previous versions did not
3 consider depth of endometriosis (deep, superficial, both or unspecified). The ultrasound
4 approaches (transvaginal, transabdominal, transrectal etc) in the new evidence from this
5 review update were also analysed separately, whereas they were combined in previous
6 review versions.

7 The included studies are summarised in Table 2. See the literature search strategy in
8 appendix B and study selection flow chart in appendix C.

9 Excluded studies

10 Studies not included in this review are listed, and reasons for their exclusion are provided in
11 appendix J.

12 Summary of included studies

13 Summaries of the studies that were included in this review are presented in Table 2.

14 **Table 2: Summary of included studies.**

Study	Population	Index test(s)	Reference standard(s)	Outcomes
Alborzi 2018 Prospective cohort study Iran	N=317 symptomatic women Women with suspected endometriosis Age in years, mean (SD): 31 (5.4) Ethnicity not reported	1. Transvaginal ultrasound 2. Transrectal ultrasound 3. MRI (with and without contrast) Timing of tests not reported	Surgery with histology	Diagnosis of deep endometriosis in: Rectosigmoid, rectovaginal septum, uterosacral ligaments, bladder • Sensitivity • Specificity
Alborzi 2023 Retrospective cohort study Iran	N=555 symptomatic women Women who had surgery for suspected endometriosis Age in years, mean (range): Shaving: 34.13 (33.20 to 35.07) Disk resection: 34.80 (33.61 to 35.99) Segmental resection: 35.37 (34.67 to 36)	1. Transvaginal ultrasound 2. MRI (with and without contrast) Timing of tests not reported	Surgery with histology	Diagnosis of deep endometriosis in: Endometrioma, rectosigmoid, rectovaginal septum, uterosacral ligaments, bladder • Sensitivity • Specificity

Study	Population	Index test(s)	Reference standard(s)	Outcomes
	Ethnicity not reported			
Asgari 2022 Retrospective cohort study Iran	N=119 symptomatic women Women with suspected endometriosis Age in years, mean (SD): 33.8 (7.1) Ethnicity not reported	1. Transvaginal ultrasound 2. Transrectal ultrasound Timing of tests not reported	Surgery with histology	Diagnosis of deep endometriosis in: Rectosigmoid, rectovaginal septum, uterosacral ligaments, pouch of Douglas, bladder • Sensitivity • Specificity
Barcellos 2016 Retrospective cohort study Brazil	N=46 symptomatic women Women who underwent surgery for endometriosis Age in years: mean (SD): 34 (5.5) Ethnicity, n (%) White: 28 (60.9) Mixed race: 13 (28.3) Black: 4 (8.7) Non declared: 1 (2.1)	1. Combination ultrasound and MRI Scans were performed about 30 days before reference standard	Surgery with histology	Diagnosis of deep endometriosis in: Ovary, rectovaginal septum, uterosacral ligaments, intestine, bladder • Sensitivity • Specificity
Barra 2021a Prospective cohort study Italy	N=34 symptomatic women Women who underwent surgery for endometriosis Age in years: mean (SD): 34.9 (2.6) Ethnicity, n (%) Caucasian: 30 (94.1) African: 1 (4.4)	1. Transvaginal ultrasound 2. Transvaginal ultrasound with 3D Scans were performed 8 weeks before reference standard	Surgery with histology	Diagnosis of deep endometriosis in: bladder • Sensitivity • Specificity

Study	Population	Index test(s)	Reference standard(s)	Outcomes
Barra 2021b Prospective cohort study Italy	Asian: 1 (1.5) N=281 symptomatic women Women who were undergoing surgery for suspected endometriosis Age in years: mean (SD) 33.4 (5.8) Ethnicity, n (%): White: 264 (94.0) African: 12 (4.3) Asiatic: 5 (1.7)	1. Transvaginal ultrasound Scans were performed 3 months before reference standard	Surgery with histology	Diagnosis of deep endometriosis in: Vagina, rectosigmoid, uterosacral ligaments, • Sensitivity • Specificity
Bratila 2016 Prospective cohort study Romania	N=193 symptomatic women Women with suspected endometriosis Age in years: mean (SD): 32 (4.3) Ethnicity not reported	1. Transvaginal ultrasound Timing of tests not reported	Surgery with histology	Diagnosis of deep and superficial endometriosis in: Ovary, vagina, rectosigmoid, rectovaginal septum, uterosacral ligaments, pouch of Douglas, bladder • Sensitivity • Specificity
Chen 2019 Retrospective cohort study China	N=29 symptomatic women Women with suspected endometriosis Age in years: mean (range): 38 (29 to 53) Ethnicity not reported	1. Transvaginal ultrasound 2. Transrectal ultrasound Timing of tests not reported	Surgery with histology	Diagnosis of deep endometriosis in: Rectovaginal septum • Sensitivity • Specificity
Di Giovanni 2022 Retrospective	N=93 symptomatic participants	1. Transvaginal ultrasound Scans were	Surgery with histology	Diagnosis of deep endometriosis in:

Study	Population	Index test(s)	Reference standard(s)	Outcomes
cohort study Italy	Women who had an ultrasound before surgery for endometriosis Age in years: mean (SD): 37.3 (6.6) Ethnicity not reported	performed 3 months before reference standard		Ovary, vagina, uterosacral ligaments, bladder, ureters <ul style="list-style-type: none"> • Sensitivity • Specificity
El-Maadawy 2021 Prospective cohort study Egypt	N=101 symptomatic women Women with suspected endometriosis Age in years: mean (SD): 37.1 (6.2) Ethnicity not reported	1. Transvaginal ultrasound Scans were performed 4 weeks before reference standard	Surgery with histology	Diagnosis of deep endometriosis in: Rectovaginal septum, uterosacral ligaments, bladder, ureters <ul style="list-style-type: none"> • Sensitivity • Specificity
Ferrero 2017 Prospective cohort study Italy	N=70 symptomatic women Women with suspected endometriosis Age in years: mean (SD): 35.7 (5.1) Ethnicity not reported	1. Transvaginal ultrasound Timing of tests not reported	Surgery with histology	Diagnosis of deep endometriosis in: Rectosigmoid <ul style="list-style-type: none"> • Sensitivity • Specificity
Ferrero 2019 Prospective cohort study Italy	N=262 symptomatic women Women with suspected endometriosis Age in years: mean (SD): With rectosigmoid endometriosis: 33.0 (4.9) Without rectosigmoid endometriosis:	1. Transvaginal ultrasound Scans were performed 6 months before reference standard	Surgery with histology	Diagnosis of deep endometriosis in: Rectosigmoid <ul style="list-style-type: none"> • Sensitivity • Specificity

Study	Population	Index test(s)	Reference standard(s)	Outcomes
	32.1 (4.3) Ethnicity not reported			
Goncalves 2021 Prospective cohort study Brazil	N=120 symptomatic women Women due to have surgery for suspected endometriosis Age in years: mean (SD): With endometriosis: 33.6 (13.8) Without endometriosis: 45.3 (0.3) Ethnicity not reported	1. Transvaginal ultrasound Timing of tests not reported	Surgery with histology	Diagnosis of deep endometriosis in: Ovary, rectosigmoid, pouch of Douglas, bladder <ul style="list-style-type: none"> • Sensitivity • Specificity
Gratton 2022 Retrospective cohort study Canada	N=96 symptomatic women Women who had surgery for suspected endometriosis Age in years: mean (SD): 40 (7.2) Ethnicity not reported	1. Laparoscopy without surgery Index test and reference standard performed at the same time	Surgery with histology	Diagnosis of deep and superficial endometriosis in multiple sites <ul style="list-style-type: none"> • Sensitivity • Specificity
Harth 2023 Retrospective cohort study Germany	N=160 symptomatic women Women who had undergone MRI for endometriosis Age in years: mean (SD): 33 (7.2) Ethnicity not reported	1. MRI (with contrast) Scan performed maximum 12 months before surgery	Surgery with histology	Diagnosis of deep endometriosis in multiple sites <ul style="list-style-type: none"> • Sensitivity • Specificity
Hausmann	N=43 women, not	1. MRI (with	Surgery with	Diagnosis of

Study	Population	Index test(s)	Reference standard(s)	Outcomes
2021 Retrospective cohort study Switzerland	specified if symptomatic Women who had an MRI for endometriosis Age in years: mean (SD): 35.9 (6.4) Ethnicity not reported	contrast) Scan performed maximum 2 years before surgery	histology	deep endometriosis in: rectosigmoid • Sensitivity • Specificity
Hernandez Gutierrez 2019 Retrospective cohort study Spain	N=48 symptomatic women Women who had a scan for suspected endometriosis Age in years: mean (SD): 34 (6) Ethnicity not reported	1. Transvaginal ultrasound 2. MRI Scan performed maximum 2 months before surgery	Surgery with histology	Diagnosis of deep endometriosis in: Vagina, rectosigmoid, rectovaginal septum, uterosacral ligaments, bladder, ureters • Sensitivity • Specificity
Jiang 2017 Prospective cohort study China	N=198 symptomatic women Women with suspected endometriosis Age in years: mean (SD): 32.7 (4.9) Ethnicity not reported	1. Transvaginal ultrasound Scan performed 1 month before surgery	Surgery with histology	Diagnosis of deep endometriosis in the rectosigmoid • Sensitivity • Specificity
Kamkarfar 2022 Prospective cohort study Iran	N=80 symptomatic women Women with suspected endometriosis Age in years: mean (SD): 34.5 (5.9)	1. Transvaginal ultrasound Timing of tests not reported	Surgery with histology	Diagnosis of deep endometriosis in: Endometrioma uterosacral ligaments • Sensitivity • Specificity

Study	Population	Index test(s)	Reference standard(s)	Outcomes
	Ethnicity not reported			
Montanari 2022 Prospective cohort study Austria, Hungary, Brazil, Italy, German, Australia, Canada	N=745 symptomatic women Women who had surgery for endometriosis Age in years: mean (SD): 35 (6) Ethnicity not reported	1. Transvaginal and transabdominal ultrasound	Surgery with histology	Diagnosis of deep endometriosis in: Ovary, bladder, ureters <ul style="list-style-type: none"> • Sensitivity • Specificity
Puri 2022 Prospective cohort study India	N=40 women, not specified if all were symptomatic Women with suspected endometriosis Age in years: mean (SD): 31.5 (4.4) Ethnicity not reported	1. Transabdominal ultrasound 2. MRI (type, that is with or without contrast, unspecified) Timing of tests not reported	Surgery with histology	Diagnosis of deep endometriosis in: Ovary, uterosacral ligaments <ul style="list-style-type: none"> • Sensitivity • Specificity
Roditis 2023 Retrospective cohort study France	N=178 symptomatic women Women who had a scan for endometriosis Age in years: mean (range): 32.8 (19-49) Ethnicity not reported	1. Transvaginal ultrasound 2. MRI (type, that is with or without contrast, unspecified) 3. Combined ultrasound and MRI Scan performed up to 12 months before reference standard	Surgery with histology	Diagnosis of deep endometriosis in: Vagina, rectosigmoid, uterosacral ligaments, bladder <ul style="list-style-type: none"> • Sensitivity • Specificity
Rokhgireh 2020 Prospective cohort study Iran	N=115, some were symptomatic, not specified how many Women who were due to have laparoscopy	1. CA-125 Timing of tests not reported	Surgery with histology	Diagnosis of deep and superficial endometriosis in multiple sites <ul style="list-style-type: none"> • Sensitivity • Specificity

Study	Population	Index test(s)	Reference standard(s)	Outcomes
	Age in years: mean (SD): 32.4 (6.2) Ethnicity not reported			
Ros 2021 Prospective cohort study Spain	N=172 symptomatic women Women with suspected endometriosis Age in years: mean (SD): 38.3 (6.2) Ethnicity not reported	1. Transvaginal ultrasound Scan performed up to 4 weeks before reference standard	Surgery with histology	Diagnosis of deep endometriosis in: Vagina, uterosacral ligaments • Sensitivity • Specificity
Shahbazi 2022 Prospective cohort study Iran	N=20 women, not specified if symptomatic Women due to undergo surgery for endometriosis Age in years: mean (SD): 35 (8.8) Ethnicity not reported	1. Transvaginal ultrasound Performed 4 months before surgery 2. MRI Performed 2 months before surgery	Surgery with histology	Diagnosis of deep and superficial endometriosis in multiple sites • Sensitivity • Specificity
Siddiqui 2021 Prospective cohort study Pakistan	N=170 women, not specified if symptomatic Women due to have an MRI for endometriosis Age in years: mean (SD): 36.8 (10.4) (Ages 14 to 65 were included) Ethnicity not reported	1. MRI Timing of tests not reported	Surgery with histology	Diagnosis of endometriosis (unspecified depth) in: endometrioma • Sensitivity • Specificity
Widschwendter 2022	N=80 symptomatic women	1. MRI Timing of tests not	Surgery with histology	Diagnosis of deep endometriosis

Study	Population	Index test(s)	Reference standard(s)	Outcomes
Retrospective cohort study Germany	Women with suspected endometriosis Age in years: mean (range): 33 (15-55) Ethnicity not reported	reported		in: Rectosigmoid, uterosacral ligaments • Sensitivity • Specificity
Zannoni 2017 Prospective cohort study Italy	N=47 symptomatic women Women with suspected endometriosis Age in years: mean (SD): 37 (5.3) Ethnicity not reported	1. Transvaginal ultrasound Scan performed 1 month before surgery	Surgery with histology	Diagnosis of deep endometriosis in: Rectosigmoid, rectovaginal septum, uterosacral ligaments, ureters • Sensitivity • Specificity
Zhang 2019 Prospective cohort study China	N=118 women, not specified if symptomatic or asymptomatic Women due to have surgery for endometriosis Age in years: mean (SD): 35.2 (6.2) Ethnicity not reported	1. Transvaginal ultrasound Scan performed 2 weeks before surgery	Surgery with histology	Diagnosis of deep endometriosis in: uterosacral ligaments • Sensitivity • Specificity

1 *MRI: magnetic resonance imaging; SD: standard deviation*

2 See the full evidence tables in appendix D and the forest plots in appendix E.

3 **Summary of the evidence**

4 This section is a narrative summary of the findings of the review, as presented in the GRADE
5 tables in appendix F. For details of the committee's confidence in the evidence and how this
6 affected recommendations, see the section on the committee's discussion of the evidence.

7 Meta-analyses were conducted for the following index tests: transvaginal ultrasound for
8 endometriosis in the vagina, rectosigmoid, rectovaginal septum, uterosacral ligaments, right
9 uterosacral ligament, left uterosacral ligament, and bladder; MRI for endometriosis in the
10 rectosigmoid and uterosacral ligaments. Meta-analysis was conducted in Winbugs and the
11 pooled estimates from Winbugs analysis are reported in GRADE tables.

1 Results from individual studies have been reported for the following index tests as there were
2 insufficient studies for conducting a meta-analysis: transvaginal ultrasound for endometriosis
3 in the ovaries or endometrioma, pouch of Douglas, ureters, and multiple sites; transvaginal
4 ultrasound with 3D for endometriosis in the bladder; transrectal ultrasound for endometriosis
5 in rectosigmoid, rectovaginal septum, bladder; transabdominal ultrasound for endometriosis
6 in the ovary and uterosacral ligaments; combined transvaginal and transrectal for
7 endometriosis in left and right ovaries, rectosigmoid, right and left uterosacral ligaments, and
8 pouch of Douglas; combined transvaginal and transabdominal for endometriosis in the left
9 and right ovary, and ureters; MRI for endometriosis in the endometrioma, vagina,
10 rectovaginal septum, bladder, and in multiple sites; CA-125 biomarker for endometriosis in
11 multiple sites; laparoscopy without histology for endometriosis in multiple sites; combined
12 ultrasound and MRI for endometriosis in the ovary, vagina, rectosigmoid, rectovaginal
13 septum, uterosacral ligaments, intestine, and bladder.

14 The evidence was assessed as being very low to high quality. Studies were downgraded for
15 risk of bias as per QUADAS-2 (for example, bias due to lack of information on how
16 participants were selected, or lack of information about whether the index test results were
17 interpreted without knowledge of the results of the reference standard), inconsistency
18 (heterogeneity), and imprecision (95% confidence intervals crossing decision making
19 thresholds).

20 See the GRADE tables in appendix F for the certainty of the evidence for each individual
21 outcome.

22 **Ultrasound for the diagnosis of endometriosis in the ovary, including endometrioma** 23 **(deep and superficial)**

24 Transvaginal ultrasound

25 The evidence (1 study) showed that transvaginal ultrasound to identify deep and superficial
26 endometriosis in the ovaries was highly sensitive and highly specific. The evidence was
27 moderate quality for sensitivity and high quality for specificity.

28 The evidence (2 studies) showed that transvaginal ultrasound to identify deep endometriosis
29 in the ovaries was highly sensitive and highly specific. The evidence was moderate quality
30 for sensitivity and low to moderate for specificity.

31 The evidence (1 study) showed that transvaginal ultrasound to identify endometriosis in the
32 right ovary was moderately sensitive and highly specific. The evidence was high quality for
33 sensitivity and specificity.

34 The evidence (1 study) showed that transvaginal ultrasound to identify deep endometriosis in
35 the right ovary was highly sensitive and highly specific. The evidence was moderate quality
36 for sensitivity and high quality for specificity.

37 The evidence (1 study) showed that transvaginal ultrasound to identify deep endometriosis in
38 the left ovary was highly sensitive and highly specific. The evidence was high quality for
39 sensitivity and moderate quality for specificity.

40 Transabdominal ultrasound

41 The evidence (1 study) showed that transabdominal ultrasound to identify deep
42 endometriosis in the ovaries was highly sensitive and moderately specific. The evidence was
43 low quality for sensitivity and very low quality for specificity.

44 Transvaginal and transrectal ultrasound

45 The evidence (1 study) showed that transvaginal and transrectal ultrasound to identify deep
46 endometriosis in the left and the right ovary was moderately sensitive and moderately
47 specific. The evidence was moderate quality for sensitivity and specificity.

1 Transvaginal and transabdominal ultrasound

2 The evidence (1 study) showed that transvaginal and transabdominal ultrasound to identify
3 deep endometriosis in the right ovary was moderately sensitive and highly specific. The
4 evidence was moderate quality for sensitivity and high quality for specificity. The evidence (1
5 study) showed that transvaginal and transabdominal ultrasound to identify deep
6 endometriosis in the left ovary was highly sensitive and highly specific. The evidence was
7 moderate quality for sensitivity and high quality for specificity.

8 **Ultrasound for the diagnosis of endometriosis in the vagina (deep and superficial)**

9 Transvaginal ultrasound

10 The evidence (5 studies, not meta-analysed due to very serious heterogeneity) showed that
11 transvaginal ultrasound to identify deep endometriosis in the vagina had low to high
12 sensitivity. The evidence (5 studies, meta-analysis) showed that transvaginal ultrasound to
13 identify deep endometriosis in the vagina was highly specific. The evidence was very low to
14 low quality for sensitivity and low quality for specificity.

15 The evidence (1 study) showed that transvaginal ultrasound to identify deep and superficial
16 endometriosis in the vagina was low in sensitivity and highly specific. The evidence as
17 moderate quality for sensitivity and high quality for specificity.

18 **Ultrasound for the diagnosis of endometriosis in the rectosigmoid (deep)**

19 Transvaginal ultrasound

20 The evidence (10 studies, meta-analysis) showed that transvaginal ultrasound to identify
21 deep endometriosis in the rectosigmoid was moderately sensitive and highly specific. The
22 evidence was low quality for sensitivity and moderate quality for specificity. One other study,
23 not included in the meta-analysis, showed that transvaginal ultrasound was highly sensitive
24 and highly specific, and the quality was high for both sensitivity and specificity.

25 Transrectal ultrasound

26 The evidence (1 study) showed that transrectal ultrasound to identify deep endometriosis in
27 the rectosigmoid was moderately sensitive and highly specific. The evidence was moderate
28 quality for sensitivity and high quality for specificity.

29 Transvaginal and transrectal ultrasound

30 The evidence (1 study) showed that transvaginal and transrectal ultrasound to identify deep
31 endometriosis in the rectosigmoid was low in sensitivity and highly specific. The evidence
32 was moderate quality for sensitivity and moderate quality for specificity.

33 **Ultrasound for the diagnosis of endometriosis in the rectovaginal septum (deep)**

34 Transvaginal ultrasound

35 The evidence (5 studies, meta-analysis) showed that transvaginal ultrasound to identify deep
36 endometriosis in the rectovaginal septum was moderately sensitive and highly specific. The
37 evidence was low quality for sensitivity and moderate quality for specificity.

38 Transrectal ultrasound

39 The evidence (2 studies) showed that transrectal ultrasound to identify deep endometriosis in
40 the rectovaginal septum was moderately sensitive and moderately to highly specific. The
41 evidence was low to moderate quality for sensitivity and low to high quality for specificity.

42 **Ultrasound for the diagnosis of endometriosis in the uterosacral ligaments (deep and
43 superficial depth)**

44 Transvaginal ultrasound

45 The evidence (6 studies, meta-analysis) showed that transvaginal ultrasound to identify deep
46 endometriosis in the uterosacral ligaments was moderately sensitive and highly specific. The
47 evidence was low quality for sensitivity and moderate quality for specificity.

1 The evidence (1 study) showed that transvaginal ultrasound to identify deep and superficial
2 endometriosis in the uterosacral ligaments was moderately sensitive and highly specific. The
3 evidence was low quality for sensitivity and high quality for specificity.

4 The evidence (4 studies, not meta-analysed due to very serious heterogeneity) showed that
5 transvaginal ultrasound to identify deep endometriosis in the right uterosacral ligament
6 ranged from low to high sensitivity. The evidence (4 studies, meta-analysis) showed that
7 transvaginal ultrasound to identify deep endometriosis in the right uterosacral ligament was
8 highly specific. The evidence was very low to low quality for sensitivity and moderate quality
9 for specificity.

10 The evidence (3 studies, not meta-analysed due to very serious heterogeneity) showed that
11 transvaginal ultrasound to identify deep endometriosis in the left uterosacral ligament ranged
12 from low to high sensitivity. The evidence (3 studies, meta-analysis) showed that
13 transvaginal ultrasound to identify deep endometriosis in the left uterosacral ligament was
14 highly specific. The evidence was very low to low quality for sensitivity and very low quality
15 for specificity.

16 Transrectal ultrasound

17 The evidence (1 study) showed that transrectal ultrasound to identify deep endometriosis in
18 the uterosacral ligaments was moderately sensitive and highly specific. The evidence was
19 high quality for sensitivity and moderate quality for specificity.

20 Transabdominal ultrasound

21 The evidence (1 study) showed that transabdominal ultrasound to identify deep
22 endometriosis in the uterosacral ligaments was low in sensitivity and highly specific. The
23 evidence was low quality for both sensitivity and specificity.

24 Transvaginal and transrectal ultrasound

25 The evidence (1 study) showed that transvaginal and transrectal ultrasound to identify deep
26 endometriosis in the right uterosacral ligaments was moderately sensitivity and moderately
27 specific. The evidence was moderate quality for sensitivity and high quality for specificity.

28 The evidence (1 study) showed that transvaginal and transrectal ultrasound to identify deep
29 endometriosis in the left uterosacral ligaments was of low sensitivity and moderately specific.
30 The evidence was moderate quality for sensitivity and high quality for specificity.

31 **Ultrasound for the diagnosis of endometriosis in the pouch of Douglas (deep and** 32 **superficial)**

33 Transvaginal ultrasound

34 The evidence (1 study) showed that transvaginal ultrasound to identify deep endometriosis in
35 the pouch of Douglas was moderately sensitive and moderately specific. The evidence was
36 moderate quality for both sensitivity and specificity.

37 The evidence (1 study) showed that transvaginal ultrasound to identify deep and superficial
38 endometriosis in the pouch of Douglas was moderately sensitive and highly specific. The
39 evidence was moderate quality for both sensitivity and specificity.

40 Transvaginal and transrectal ultrasound

41 The evidence (1 study) showed that transvaginal ultrasound and transrectal ultrasound to
42 identify deep endometriosis in the pouch of Douglas was moderately sensitive and
43 moderately specific. The evidence was high quality for sensitivity and moderate quality for
44 specificity.

45 **Ultrasound for the diagnosis of endometriosis in the bladder (deep and superficial** 46 **depth)**

1 Transvaginal ultrasound

2 The evidence (6 studies, meta-analysis) showed that transvaginal ultrasound to identify deep
3 endometriosis in the bladder was moderately sensitive and highly specific. The evidence was
4 very low quality for sensitivity and high quality for specificity.

5 The evidence (1 study) showed that transvaginal ultrasound to identify deep and superficial
6 endometriosis in the bladder was moderately sensitive and highly specific. The evidence was
7 moderate quality for sensitivity and high quality for specificity.

8 Transvaginal ultrasound with 3D

9 The evidence (1 study) showed that transvaginal ultrasound with 3D to identify deep
10 endometriosis in the bladder was moderately sensitive and highly specific. The evidence was
11 moderate quality for sensitivity and for specificity.

12 Transrectal ultrasound

13 The evidence (1 study) showed that transrectal ultrasound to identify deep endometriosis in
14 the bladder was highly sensitive and highly specific. The evidence was low quality for
15 sensitivity and high quality for specificity.

16 **Ultrasound for the diagnosis of endometriosis in the ureters (deep)**

17 Transvaginal ultrasound

18 The evidence (1 study) showed that transvaginal ultrasound to identify deep endometriosis in
19 the ureters was moderately sensitive and highly specific. The evidence was low quality for
20 sensitivity and moderate quality for specificity.

21 The evidence (2 studies) showed that transvaginal ultrasound to identify deep endometriosis
22 in the right ureter was low to moderately sensitive and highly specific. The evidence was low
23 to high quality for sensitivity and moderate to high quality for specificity.

24 The evidence (2 studies) showed that transvaginal ultrasound to identify deep endometriosis
25 in the left ureter was low in sensitivity and highly specific. The evidence was low to high
26 quality for sensitivity and moderate to high quality for specificity.

27 Transvaginal ultrasound and transabdominal ultrasound

28 The evidence (1 study) showed that transvaginal ultrasound and transabdominal ultrasound
29 to identify deep endometriosis in the ureters was moderately sensitive and highly specific.
30 The evidence was high quality for both sensitivity and specificity.

31 **Ultrasound for the diagnosis of endometriosis in multiple sites (deep and superficial
32 depth)**

33 Transvaginal ultrasound

34 The evidence (1 study) showed that transvaginal ultrasound to identify deep endometriosis in
35 multiple sites (right and left uterosacral ligaments, right and left endometriomas, rectal wall,
36 vagina, bladder) was moderately sensitive and low in specificity. The evidence was high
37 quality for sensitivity and specificity.

38 The evidence (1 study) showed that transvaginal ultrasound to identify deep and superficial
39 endometriosis in multiple sites (sites were not reported) was moderately sensitivity and highly
40 specific. The evidence was very low quality for sensitivity and low quality for specificity.

41 **MRI for the diagnosis of endometrioma**

42 The evidence (1 study) showed that MRI with contrast to identify endometrioma was
43 moderately sensitivity and moderately specific. The evidence was moderate quality for
44 sensitivity and specificity.

1 The evidence (2 studies) showed that MRI with contrast or unspecified type, to identify right
2 endometrioma was low to highly sensitive and moderately to highly specific. The evidence
3 was low to moderate quality for sensitivity and very low to high quality for specificity.

4 **MRI for the diagnosis of endometriosis in the vagina (deep)**

5 The evidence (1 study) showed that MRI, unspecified whether contrast was used, to identify
6 deep endometriosis in the vagina was low in sensitivity and moderately specific. The
7 evidence was of moderate quality for both sensitivity and specificity.

8 **MRI for the diagnosis of endometriosis in the rectosigmoid (deep)**

9 The evidence (5 studies, not meta-analysed due to very serious heterogeneity showed that
10 MRI, with contrast or unspecified type, to identify deep endometriosis in the rectosigmoid
11 ranged from low to highly sensitive. The evidence (5 studies, meta-analysis) showed that
12 MRI, with contrast or unspecified type, to identify deep endometriosis in the rectosigmoid
13 was highly specific. The evidence was of very low to low quality for sensitivity and moderate
14 quality for specificity.

15 **MRI for the diagnosis of endometriosis in the rectovaginal septum (deep)**

16 The evidence (2 studies) showed that MRI, with contrast, to identify deep endometriosis in
17 the rectovaginal septum was moderately to highly sensitive and moderately to highly specific.
18 The evidence was of moderate quality for sensitivity and low to high quality for specificity.

19 **MRI for the diagnosis of endometriosis in the uterosacral ligaments (deep)**

20 The evidence (5 studies, not meta-analysed to due very serious heterogeneity) showed that
21 MRI, with contrast or unspecified type, to identify deep endometriosis in the uterosacral
22 ligaments ranged from low to highly sensitive. The evidence (5 studies, meta-analysis)
23 showed that MRI, with contrast or unspecified type, to identify deep endometriosis in the
24 uterosacral ligaments was moderately specific. The evidence was very low to low quality for
25 sensitivity and low quality for specificity.

26 **MRI for the diagnosis of endometriosis in the bladder (deep)**

27 The evidence (2 studies) showed that MRI, with contrast or unspecified type, to identify deep
28 endometriosis in the bladder was moderate to highly sensitive and highly specific. The
29 evidence was of low quality for sensitivity and high quality for specificity.

30 **MRI for the diagnosis of endometriosis in multiple sites (deep and superficial)**

31
32 The evidence (1 study) showed that MRI with contrast to identify deep endometriosis in
33 multiple sites (right and left uterosacral ligaments, right and left endometriomas, rectal wall,
34 vagina, bladder) was low in sensitivity and highly specific. The evidence was moderate
35 quality for sensitivity and high specificity.

36 The evidence (1 study) showed that MRI, unspecified whether contrast was used, to identify
37 deep and superficial endometriosis in multiple sites (sites were not reported) was moderately
38 sensitive and moderately specific. The evidence was very low quality for sensitivity and for
39 specificity.

40 **Biomarker CA-125 for the diagnosis of endometriosis in multiple sites (deep and**
41 **superficial)**

42 The evidence (1 study) showed that CA-125 to identify deep and superficial endometriosis in
43 multiple sites was moderately sensitive and moderately specific. The evidence was moderate
44 quality for both sensitivity and specificity.

1 **Laparoscopy without histopathology for the diagnosis of endometriosis in multiple**
2 **sites (deep and superficial)**

3 The evidence (1 study) showed that laparoscopy without histopathology to identify deep and
4 superficial endometriosis in multiple sites (endometrioma, posterior vaginal fornix,
5 rectovaginal septum, uterosacral ligaments, rectum, bladder) was highly sensitive and low in
6 specificity. The evidence was moderate quality for both sensitivity and for specificity.

7 **Combination of ultrasound and MRI for the diagnosis of endometriosis in the ovary**
8 **(deep)**

9 The evidence (1 study) showed that a combination of ultrasound and MRI for the diagnosis of
10 deep endometriosis in the ovary was highly sensitive and moderately specific. The evidence
11 was moderate quality for sensitivity and low quality for specificity.

12 **Combination of ultrasound and MRI for the diagnosis of endometriosis in the vagina**
13 **(deep)**

14 The evidence (1 study) showed that a combination of ultrasound and MRI for the diagnosis of
15 deep endometriosis in the vagina was low in sensitivity and highly specific. The evidence
16 was high quality for sensitivity and moderate quality for specificity.

17 **Combination of ultrasound and MRI for the diagnosis of endometriosis in the**
18 **rectosigmoid (deep)**

19 The evidence (1 study) showed that a combination of ultrasound and MRI for the diagnosis of
20 deep endometriosis in the rectosigmoid was moderately sensitive and highly specific. The
21 evidence was high quality for sensitivity and for specificity.

22 **Combination of ultrasound and MRI for the diagnosis of endometriosis in the**
23 **rectovaginal septum (deep)**

24 The evidence (1 study) showed that a combination of ultrasound and MRI for the diagnosis of
25 deep endometriosis in the rectovaginal septum was highly sensitive and highly specific. The
26 evidence was low quality for sensitivity and high quality for specificity.

27 **Combination of ultrasound and MRI for the diagnosis of endometriosis in the**
28 **uterosacral ligaments (deep)**

29 The evidence (2 studies) showed that a combination of ultrasound and MRI for the diagnosis
30 of deep endometriosis in the uterosacral ligaments was moderately to highly sensitive and
31 low to moderately specific. The evidence was moderate to high quality for sensitivity and low
32 quality for specificity.

33 **Combination of ultrasound and MRI for the diagnosis of endometriosis in the intestine**
34 **(deep)**

35 The evidence (1 study) showed that a combination of ultrasound and MRI for the diagnosis of
36 deep endometriosis in the intestine (unspecified if small or large intestine) was highly
37 sensitive and highly specific. The evidence was moderate quality for sensitivity and for
38 specificity.

39 **Combination of ultrasound and MRI for the diagnosis of endometriosis in the bladder**
40 **(deep)**

41 The evidence (2 studies) showed that a combination of ultrasound and MRI for the diagnosis
42 of deep endometriosis in the bladder was moderately to highly sensitive and highly specific.
43 The evidence was low to moderate quality for sensitivity and high quality for specificity.

- 1 **Economic evidence**
- 2 **Included studies**
- 3 Two economic studies were identified which were relevant to this question (Khan 2018 and
- 4 Ferrier 2023).
- 5 See the literature search strategy in **Error! Reference source not found.** and economic
- 6 study selection flow chart in **Error! Reference source not found.**
- 7 **Excluded studies**
- 8 Economic studies not included in this review are listed, and reasons for their exclusion are
- 9 provided in **Error! Reference source not found.**
- 10 **Summary of included economic evidence**
- 11 **See**

- 1
- 2 Table 3 for the economic evidence profile of the included study.

2 **Table 3: Economic evidence profile for economic evaluations of the diagnosis of endometriosis**

Study	Limitations	Applicability	Other comments	Incremental			Uncertainty
				Costs	Effect	Cost effectiveness	
Khan 2018	Potentially serious limitations ¹	Directly applicable ²	Decision analytic model Timeframe limited to 6-months to reflect the data collection period for quality-of-life data. This is unlikely to be sufficient to capture the full impact of diagnosis on costs and outcomes.	<i>Relative to no testing:</i> Laparoscopy (cut-off value of 6) £1,793	<i>Relative to no testing:</i> Laparoscopy (cut-off value of 6) 0.014 QALYs	<i>Relative to no testing:</i> Laparoscopy (cut-off value of 6) £116,618 per QALY	Probabilistic sensitivity analysis suggested that there was an approximately 70% chance that no testing was cost-effective for the base case analysis. Sensitivity analysis demonstrated the model conclusions to be sensitive to the timeframe of the analysis and the prevalence of structural causes among women with chronic pelvic pain
Ferrier 2023	Very serious limitations ^{3,4,5,6,7,8}	Partially applicable ⁹	Decision analytic model	With Endotest® valued at €750 Incremental costs not reported	Incremental outcomes not reported but incremental correct diagnoses relative to Strategy I: Strategy II: 0.24 Strategy III: 0.23 Strategy IV: 0.08	With Endotest® valued at €750 Strategy IV relative to Strategy I: -€896 (95% CI -€2,417 to -€184) Strategy III relative to	Costs of Endotest® were unknown and so results are presented for hypothetical costs. Model does not incorporate relationship between improvements correct diagnoses and improvements in health-related quality of life.

Study	Limitations	Applicability	Other comments	Incremental	Uncertainty
					Strategy IV: €473 (95% CI - €681 to €1,062) Strategy II relative to Strategy III: €4,715 (95% CI -€29,313 to €37,513)

- 1 ¹ Timeframe of the base case analysis is unlikely to be sufficient to capture all long-term differences in health-related quality of life and cost
- 2 ² NHS perspective and setting with QALYs derived using preferred NICE methods
- 3 ³ Outcome was correct diagnosis which is only a surrogate for the true outcome of interest, health-related quality of life.
- 4 ⁴ No cost-effectiveness threshold for cost per correct diagnosis and therefore impossible to determine the cost-effectiveness of non-dominated alternatives
- 5 ⁵ Costs were not presented per strategy, and this made it difficult to ascertain how ICERs were derived
- 6 ⁶ Cost of Endotest® were not known and therefore analysis is hypothetical
- 7 ⁷ It is not clear whether strategies to detect endometriosis should be compared with strategies to detect endometriomas
- 8 ⁸ The diagnostic accuracy for Endotest® used in the analysis was taken from a study that was included from the clinical review because it did not include an appropriate reference
- 9 standard
- 10 ⁹ French health care setting
- 11
- 12
- 13

1 **Economic model**

2 No economic modelling was undertaken for this review because surveillance had indicated
3 that new evidence could alter the strength of some recommendations, but major revision of
4 practice was not anticipated.

5 **Evidence statements**

6 **The committee's discussion and interpretation of the evidence**

7 **The outcomes that matter most**

8 The committee agreed that the diagnostic test accuracy outcomes of sensitivity and
9 specificity were critical in this review. They discussed that the sensitivity of the tests was
10 more important than specificity, as not identifying endometriosis had serious implications. A
11 lack of diagnosis means the woman may not receive appropriate treatment and so continuing
12 symptoms can impair quality of life and severely impact day to day life. A lack of a diagnosis
13 may also mean that endometriosis worsens, which in turn can damage organs, impair fertility
14 and lead to serious long-term consequences. However, the committee discussed that
15 specificity was also important as this may lead to the exclusion of endometriosis as a
16 diagnosis, and enable the woman to receive other investigations to identify the cause of their
17 symptoms.

18 **The quality of the evidence**

19 The overall quality of the evidence ranged from very low to high. For ultrasound, the
20 evidence for sensitivity ranged from very low to high quality, with the majority being moderate
21 quality and for specificity ranged from very low to high with the majority being high quality..
22 For MRI, the evidence for sensitivity ranged from very low to moderate quality with the
23 majority being very low quality, and for specificity it ranged from very low to high with the
24 majority being high quality. There were some concerns around risk of bias, where there was
25 limited information about whether index tests were performed without knowledge of the
26 reference standard. Some of the evidence was also downgraded for imprecision around the
27 diagnostic accuracy estimate, with some confidence intervals crossing the decision-making
28 thresholds (0.90 as the upper threshold and 0.60 as the lower threshold for both sensitivity
29 and specificity were used for assessing imprecision). Sub-group analysis could not be
30 conducted as there was insufficient information on sub-groups (ethnic groups) from the
31 studies. None of the evidence was conducted in the UK and the committee discussed that
32 the referral processes for the index scans and the operators performing the scans and
33 referral processes for the index scans may differ across the countries. However, the
34 committee discussed that there is also variability within the UK health system in terms of the
35 experience of the operators performing and interpreting the scans and so the evidence from
36 all countries was likely to show some variation. The committee therefore agreed that the
37 evidence from other countries could be extrapolated to the UK population, and therefore the
38 evidence in this review was applicable to the UK.

39 **Benefits and harms**

40 The committee discussed how the evidence on diagnostic tests for endometriosis in this
41 review could add to the evidence identified for the review when conducted previously for this
42 guideline. They discussed that the evidence in the review this time was stratified by both site
43 and depth of endometriosis (previously it was just by site), and that this may allow them to
44 expand on the detail of sites and depths included in the recommendations. The new
45 evidence was also stratified according to different ultrasound approaches (for example,
46 transvaginal, transabdominal, transrectal or combinations). The committee discussed that

1 overall, the quality of the evidence in this review was rated higher than the evidence the
2 existing recommendations were based on. They also noted that, generally, the sensitivity and
3 specificity of the ultrasound and MRI tests from this review were in agreement with the
4 sensitivity and specificity reported in the evidence informing existing recommendations, and
5 therefore this review provided an additional body of evidence to update the existing
6 recommendations.

7 The committee discussed the difficulties in current practice in diagnosing endometriosis, and
8 that on average a diagnosis of endometriosis takes 8 years ([Endometriosis APPG Report
9 Oct 2020.pdf](#)). They discussed that the existing guidance recommends that the first
10 investigation should be a pelvic or abdominal examination, but even if this was normal then
11 further investigations should be carried out using ultrasound or MRI. The committee then
12 went on to discuss the new, additional evidence for ultrasound, MRI and other diagnostic
13 techniques.

14 The committee discussed that the care pathway for the assessment, early treatment and
15 referral for suspected endometriosis was not clear in the current guideline and that it might
16 be considered that treatment and investigations should be carried out sequentially, whereas
17 people presenting with pain and symptoms should receive initial treatment while further
18 investigations or referrals were organised. The committee therefore reordered some of the
19 guideline recommendations and clarified that these processes could happen in parallel to
20 further speed up diagnosis.

21 Ultrasound

22 The committee discussed that the evidence in this review supported the use of transvaginal
23 ultrasound to diagnose endometriosis. They agreed that across many sites and depths of
24 endometriosis the evidence showed that transvaginal ultrasound showed moderate to high
25 sensitivity, with transvaginal ultrasound of the ovaries (including endometrioma) showing
26 high sensitivity in the majority of studies.

27 They noted, however, that some studies were heterogenous to others and showed low
28 sensitivity in some sites (vagina, and right and left uterosacral ligament) and wished to
29 identify if there were possible reasons for this heterogeneity. For one study (Alborzi 2023),
30 the authors describe the population as deep endometriosis in the rectosigmoid, but further
31 subclassify them as a superficial form of deep endometriosis, and a deep form of deep
32 endometriosis. The superficial form showed a low sensitivity, and the deep form showed a
33 high sensitivity, but as this review protocol did not specify further subclassification, the overall
34 sensitivity was included in the analysis. The committee discussed that the low sensitivity in
35 this instance may have been due to the combination of sub-types. The committee also
36 discussed that for one study (Zannoni 2017) the participants were described to have used
37 hormonal treatment pre-operatively. The paper described that hormonal treatment often
38 determines atrophy in deep endometriosis nodules making them less visible with the
39 methods of the study. The committee agreed that this could have been a potential reason for
40 the low sensitivity detected in this study. They also discussed that for one study (El-Maadawy
41 2021) the authors suggested that the characteristics of the vaginal probe used could be a
42 reason for the low sensitivity. Finally, they noted that for one study (Roditis 2023) the authors
43 did not mention a specific reason for low sensitivity that was relevant to the vagina only, but
44 suggested that the experience of the gynaecologist could have an impact.

45 The evidence for transrectal or transabdominal ultrasound generally showed moderate
46 sensitivity, and combinations of ultrasound techniques (for example transvaginal and
47 transrectal) did not show any greater sensitivity than the single techniques so the committee
48 did not recommend combinations.

49 The committee discussed that the new additional evidence for transvaginal ultrasound
50 showed moderate to high sensitivity across a range of sites and depths of endometriosis
51 (apart from some outlying studies which are discussed above), and that this was in line with

1 the evidence from the previous version of the review. They discussed that this supported
2 transvaginal ultrasound as a sensitive diagnostic tool. The committee noted that ultrasound is
3 thought to be particularly useful at identifying endometriomas, and this had been confirmed
4 by the evidence for this site which had shown high sensitivity in the majority of studies. The
5 committee also discussed that across the studies looking at ultrasound, the operators were
6 skilled or experienced in endometriosis and that this would have an impact on the sensitivity
7 of the ultrasound scan, and the committee agreed that transvaginal ultrasound, when done
8 by a skilled operator, can therefore be used as an option to diagnose deep endometriosis
9 and so included this in their recommendation for deep endometriosis in a specialist setting.

10 The committee discussed the use of non-specialist ultrasound, requested by a GP and
11 carried out by a non-specialist sonographer. They agreed that in this situation the sensitivity
12 and the specificity of the scan at diagnosing endometriosis may not be so high, but that a
13 sonographer would be able to identify endometriomas, and possibly some cases of deep
14 endometriosis. They discussed that they did not have concerns over the experience of the
15 sonographer for the detection of endometriomas, and agreed that the sensitivity and
16 specificity of the scan, as in the evidence, would still be high when performed by a
17 sonographer. They discussed from their experiential knowledge that endometriomas are
18 often associated with deep endometriosis. Therefore they agreed there was value in an
19 ultrasound carried out by a non-specialist sonographer. They also discussed that the value of
20 an early ultrasound scan would be to identify if there was other pathology that could be
21 causing the symptoms such as fibroids or a malignancy, and to aid the correct referral
22 pathway (if referral was necessary) as endometrioma or deep endometriosis would suggest
23 referral to a specialist endometriosis service, rather than to a general gynaecology service.
24 The committee therefore recommended that all women or people with suspected
25 endometriosis should be offered a transvaginal ultrasound scan by their GP. They discussed
26 that this change would increase the strength of the recommendation from a weak 'consider'
27 recommendation to a strong 'offer' recommendation but agreed that this was already current
28 good practice and that this early ultrasound should be part of the diagnostic work-up. They
29 agreed that the likely benefits of changing to a stronger recommendation would be that even
30 more women would be offered an early transvaginal ultrasound scan, and this would,
31 hopefully, reduce the average time taken to get a diagnosis of endometriosis.

32 The committee discussed that most of the evidence was for transvaginal ultrasound scans,
33 and that they had previously discussed that this approach may not be appropriate for some
34 groups of women such as those who had not been sexually active, had a traumatic sexual
35 experience or women with a history of female genital mutilation. They also discussed that a
36 transvaginal ultrasound could be very painful for some women. They noted that there was
37 much less evidence available to inform recommendations for other approaches such as
38 transabdominal ultrasound but agreed that the current recommendation to consider a
39 transabdominal ultrasound scan in cases where transvaginal scans were not appropriate was
40 still necessary to provide an alternative option.

41 The committee discussed that the existing guideline recommends that endometriosis should
42 not be excluded following a normal ultrasound. The committee discussed that this
43 recommendation still stands, as the specificity across sites using ultrasound was not
44 consistently 100%. Although the specificity was high for ultrasound in some instances, they
45 agreed that it was important to ensure endometriosis is not missed, as a correct diagnosis is
46 key to appropriate management and treatment of endometriosis.

47 CA-125

48 The committee discussed that there was only 1 new study of moderate quality contributing to
49 the evidence for the use of CA-125 to diagnose endometriosis which showed moderate
50 sensitivity and specificity. The committee considered that the evidence was insufficient to
51 change the existing recommendations on CA-125, which advised that it was not a suitable
52 tool to diagnose endometriosis.

1 The committee discussed the lack of evidence in this review on other types of biomarkers
2 [Human epididymis protein 4 (HE- 4), the nerve fibre marker Protein Gene Product 9.5 (PGP
3 9.5), microRNAs]. However, the committee did not make a research recommendation for
4 these biomarkers, as they were aware they were in early development and did not consider
5 them to be a priority for research recommendation.

6 The committee are aware of ongoing research on a new blood test called the Mitomic
7 Endometriosis Test (Investigation of the diagnostic accuracy of a new blood test for
8 endometriosis, compared with the current gold standard surgery for diagnosis). They
9 discussed that this could allow evidence-based recommendations on this test to be made in
10 future guideline updates.

11 MRI

12 The committee next discussed the new evidence for MRI scans to diagnose endometriosis.
13 They discussed that most of the evidence was in pelvic MRI and showed that MRI had
14 moderate to high sensitivity and specificity for diagnosing endometriosis at different depths
15 and at various sites.

16 As with ultrasound, the committee noted that there were a couple of studies (Alborzi 2023
17 and Widschwendter 2022) that were heterogenous to others and showed a low sensitivity in
18 some sites (right endometrioma, rectosigmoid, uterosacral ligaments) and they discussed the
19 potential reasons for this. They discussed that the same reasons as described above for low
20 sensitivity in ultrasound for Alborzi 2023, could apply for MRI (a population with combined
21 subtypes of deep endometriosis). They also discussed Widschwendter 2022 but they agreed
22 the paper did not provide enough information for them to identify potential reasons for the
23 heterogeneity. They discussed that it could be due to differences in MRI protocols, but
24 without a detailed description available from the study they were unable to confidently
25 provide a potential reason to explain the low sensitivity.

26 Apart from these exceptions the committee agreed that there was moderate to high
27 sensitivity across the rest of the evidence, and that MRI therefore had a role to play in the
28 diagnosis of endometriosis. However, MRI scans are less accessible than ultrasound scans
29 as GPs cannot refer people directly and people will therefore require a referral for a
30 gynaecology review, or review at a specialist endometriosis centre if deep endometriosis is
31 suspected. The committee agreed that, based on their experience of clinical practice, MRI
32 would not be a used as a primary investigation to diagnose endometriosis, and that
33 ultrasound would always be done first and so they amended the existing recommendation on
34 referral to make this pathway clear. As the committee agreed that MRI should still be
35 available as an option for the diagnosis of deep endometriosis, they agreed to retain the
36 recommendation for its use in this situation, as well as the amending the existing
37 recommendation to state that these pelvic MRI scans should be planned and interpreted by
38 an expert.

39 The committee discussed that either pelvic MRI or specialist ultrasound could be used for the
40 diagnosis of deep endometriosis, and that both should be available as options. They noted
41 that most of the evidence for the diagnosis of deep endometriosis with ultrasound was of
42 moderate sensitivity and high specificity, and similarly with MRI with mostly moderate
43 sensitivity and moderate to high specificity. They discussed that once deep endometriosis
44 was suspected, the role of scanning was important for planning before a laparoscopy and
45 noted that there was already a recommendation that stated this. As the evidence from this
46 review had included wider anatomical sites than the previous review, the committee agreed
47 that the recommendation could be generalised to all deep endometriosis and did not need to
48 list all of them.

49 The committee considered the lower cost of ultrasound, and better accessibility, and
50 discussed whether specialist ultrasound should be favoured over MRI considering the
51 sensitivity of the tests were similar. However, the committee agreed that both scans had

1 benefits ranging across sites. They discussed that endometriosis is a dynamic condition,
2 where the symptoms of the condition, the site and extent of the endometriosis could change
3 over time. They agreed that keeping options open for women would ensure that the pathway
4 of care does not mean women are excluded from a particular scan at any point during the
5 diagnosis and management of the condition.

6 Diagnostic laparoscopy

7 The committee discussed the limited but moderate quality new evidence for diagnostic
8 laparoscopy without histopathology, which showed high sensitivity but low specificity. They
9 agreed this reinforced the existing recommendations to consider diagnostic laparoscopy as it
10 may provide visual information to allow a diagnosis to be made. They made amendments to
11 the recommendations to ensure that women who had already received either ultrasound or
12 MRI would be considered for a diagnostic laparoscopy, even if the scans were negative, and
13 would not be excluded from the care pathway. They also agreed, based on knowledge and
14 experience, that results of the laparoscopy should be recorded at this stage with imaging,
15 such as photographs or video. They agreed that this would ensure that diagnostic
16 laparoscopies throughout a woman or person's care pathway would not be duplicated and
17 could be used to compare the disease progression at different timepoints. The committee
18 also discussed, based on their knowledge and experience, that a normal laparoscopy means
19 that endometriosis is unlikely, but does not rule it out completely as there could be
20 microscopic endometriosis causing symptoms. They amended the recommendations to
21 clarify that treatment for endometriosis could still be considered for symptom management.

22 Combinations of scans

23 The committee noted that there was some limited evidence for combinations with ultrasound
24 and MRI for diagnosing deep endometriosis at a variety of sites, that showed mostly high
25 sensitivity (although 1 study showed low, and 1 moderate sensitivity). They noted the quality
26 of the evidence was spread across low to high, with the majority moderate quality for
27 sensitivity and high quality for specificity. The committee agreed there was not enough
28 evidence to make a recommendation to suggest that all people had both types of scans but
29 that in clinical practice people would often (as their recommendations suggested) have an
30 ultrasound and then an MRI.

31 **Cost effectiveness and resource use**

32 The committee strengthened the existing recommendation that all women or people with
33 suspected endometriosis should be offered the option of an early ultrasound scan organised
34 by their GP. Whilst this could potentially lead to some increased use of transvaginal
35 ultrasound the committee believed that the recommendation aligned with much common
36 practice in the NHS. Where, practice currently differs from the new recommendation the
37 committee believed it would usually just expedite testing that would ultimately happen
38 anyway as part of investigation into ongoing symptomatology. Indeed it has been noted that
39 it takes an average of 8 years from onset of symptoms to a diagnosis of endometriosis
40 ([Endometriosis APPG Report Oct 2020.pdf](#)). Failure to undertake appropriate and timely
41 diagnostic intervention could result in more severe disease as well as some inefficient
42 resource use whilst people remain on an investigation pathway for a number of years, and so
43 earlier diagnosis and treatment may prevent more serious disease and subsequent costs.

44 The committee amended an existing recommendation so that either pelvic MRI or specialist
45 transvaginal ultrasound could be used to diagnose deep endometriosis and assess its extent.
46 Previously only pelvic MRI had been recommended to assess the extent of deep
47 endometriosis involving the bowel, bladder or ureter and therefore the committee considered
48 that their amendment would either be cost neutral or cost saving.

49 The committee noted that 2 studies (Khan 2018, Ferrier 2023) were included in the
50 systematic review of health economic literature for this review however they concluded that

1 the limitations of both studies meant that neither could be used as a basis to make
2 recommendations.

3 Khan (2018) found in their base case analysis that no testing was the most cost-effective
4 strategy, but this reflected the 6-months timeframe for their analysis which was chosen to
5 reflect the data collection period for health-related quality of life in the MEDAL study. A
6 sensitivity analysis using a longer timeframe suggested that the cost-effectiveness
7 conclusion was sensitive to this aspect of the model. Whilst the analysis did provide some
8 evidence to suggest that diagnostic laparoscopy could be cost-effective if a 3-year time
9 frame was considered, the authors concluded that MRI was not likely to be cost-effective
10 even in conditions, such as endometrioma, where it showed some benefit.

11 The quality assessment of Ferrier (2023) suggested that this analysis had very serious
12 limitations. First, the estimates of the diagnostic accuracy of Endotest® were taken from a
13 study that was excluded from the systematic clinical review undertaken for this guideline
14 because it did not include an appropriate reference test. Second, the cost of Endotest® was
15 not known at the time of writing and therefore the evaluation had used hypothetical values
16 with which to assess cost-effectiveness. Third, the costs of the different diagnostic strategies
17 were not provided and that made it difficult to assess whether the incremental analysis had
18 been correctly undertaken. Most importantly the analysis used cost per correct diagnosis as
19 the measure of cost-effectiveness. Such a measure does not distinguish between true
20 positives and true negatives, according to them equal weight but even more importantly it
21 does not provide a way of estimating how correct diagnosis will translate to improved health-
22 related quality of life, the ultimate outcome of interest. In the absence of a valuation the NHS
23 would place on a correct diagnosis (as opposed to QALYs) it is not possible to determine
24 cost-effectiveness for strategies that are more effective, in terms of correct diagnoses, but
25 more costly.

26 **Other factors the committee took into account**

27 The committee discussed that there may be additional barriers for people from black, Asian
28 and minority ethnic groups accessing a diagnosis for endometriosis ([Endometriosis APPG
29 Report Oct 2020.pdf](#)) but the evidence in this review did not provide data for ethnic minority
30 groups that allowed any separate recommendations to be made for these groups.

31 The committee noted that there were plans to develop women's health hubs and that in the
32 future the investigation of conditions such as endometriosis (such as early ultrasound scans)
33 may take place here, in which case a more specialised sonography service may be available
34 that could lead to improved diagnosis.

35 The committee also noted that the current guideline did not provide advice on the need to
36 take family history into account when diagnosing endometriosis, although it was well known
37 that the risk of endometriosis was increased in people with a first-degree relative who also
38 had endometriosis. The committee, therefore, based on their knowledge and experience,
39 added a recommendation to the guideline to advise that family history should be considered.

40 The committee considered the [evidence that informed the recommendations in the existing
41 guidance](#) to inform their discussions.

42 **Recommendations supported by this evidence review**

43 This evidence review supports recommendations 1.5.1, 1.5.3, 1.5.4, 1.5.9 to 1.5.13 and
44 1.5.15.

1 **References – included studies**

2 **Diagnostic**

3 **Alborzi 2018**

4 Alborzi, Saeed, Rasekhi, Alireza, Shomali, Zahra et al. (2018) Diagnostic accuracy of
5 magnetic resonance imaging, transvaginal, and transrectal ultrasonography in deep
6 infiltrating endometriosis. *Medicine* 97(8): e9536

7 **Alborzi 2023**

8 Alborzi, Saeed, Poordast, Tahereh, Askary, Elham et al. (2023) Evaluation and comparison
9 of the accuracy of transvaginal ultrasound and MRI for the diagnosis of deep rectal
10 endometriosis: A cross-sectional study. *International journal of gynaecology and obstetrics:*
11 *the official organ of the International Federation of Gynaecology and Obstetrics* 161(2): 586-
12 593

13 **Asgari 2022**

14 Asgari, Zahra, Hosseini, Reihaneh, Sepidarkish, Mahdi et al. (2022) Accuracy of transvaginal
15 and transrectal ultrasounds in the diagnosis of endometriosis: A retrospective cohort study.
16 *International journal of reproductive biomedicine* 20(5): 365-376

17 **Barcellos 2016**

18 Barcellos, Marcio Bezerra; Lasmar, Bernardo; Lasmar, Ricardo (2016) Agreement between
19 the preoperative findings and the operative diagnosis in patients with deep endometriosis.
20 *Archives of gynecology and obstetrics* 293(4): 845-50

21 **Barra 2021a**

22 Barra, Fabio, Alessandri, Franco, Scala, Carolina et al. (2021) Ultrasonographic 3D
23 Evaluation in the Diagnosis of Bladder Endometriosis: A Prospective Comparative Diagnostic
24 Accuracy Study. *Gynecologic and obstetric investigation* 86(3): 299-306

25 **Barra 2021b**

26 Barra, Fabio, Leone Roberti Maggiore, Umberto, Evangelisti, Giulio et al. (2021) A
27 prospective study comparing rectal water contrast-transvaginal ultrasonography with
28 sonovaginography for the diagnosis of deep posterior endometriosis. *Acta obstetrica et*
29 *gynecologica Scandinavica* 100(9): 1700-1711

30 **Bratila 2016**

31 Bratila, Elvira, Comandasu, Diana Elena, Coroleuca, Ciprian et al. (2016) Diagnosis of
32 endometriotic lesions by sonovaginography with ultrasound gel. *Medical ultrasonography*
33 18(4): 469-474

34 **Chen 2019**

35 Chen, Ying-Han; Wang, Dan-Bo; Guo, Cui-Shan (2019) Accuracy of Physical Examination,
36 Transvaginal Sonography, Magnetic Resonance Imaging, and Rectal Endoscopic
37 Sonography for Preoperative Evaluation of Rectovaginal Endometriosis. *Ultrasound quarterly*
38 35(1): 54-60

39 **Di Giovanni 2022**

40 Di Giovanni, Alessandra, Montanari, Eliana, Hudelist, Gernot et al. (2022) Comparison
41 Between Sonography-Based and Surgical Evaluation of Endometriotic Lesions Using the

- 1 Enzian Classification - A Retrospective Data Analysis. *Ultraschall in der Medizin* (Stuttgart,
2 Germany : 1980)
- 3 **El-Maadawy 2021**
- 4 El-Maadawy, S.M.; Alaaeldin, N.; Nagy, C.B. (2021) Role of preoperative ultrasound
5 mapping in the surgical management of deep infiltrating endometriosis: a prospective
6 observational study. *Egyptian Journal of Radiology and Nuclear Medicine* 52(1): 159
- 7 **Ferrero 2017**
- 8 Ferrero, S, Biscaldi, E, Vellone, V G et al. (2017) Computed tomographic colonography vs
9 rectal water- contrast transvaginal sonography in diagnosis of rectosigmoid endometriosis: a
10 pilot study. *Ultrasound in obstetrics & gynecology : the official journal of the International
11 Society of Ultrasound in Obstetrics and Gynecology* 49(4): 515-523
- 12 **Ferrero 2019**
- 13 Ferrero, S, Scala, C, Stabilini, C et al. (2019) Transvaginal sonography with vs without bowel
14 preparation in diagnosis of rectosigmoid endometriosis: prospective study. *Ultrasound in
15 obstetrics & gynecology : the official journal of the International Society of Ultrasound in
16 Obstetrics and Gynecology* 53(3): 402-409
- 17 **Goncalves 2021**
- 18 Goncalves, Manoel Orlando, Siufi Neto, Joao, Andres, Marina Paula et al. (2021) Systematic
19 evaluation of endometriosis by transvaginal ultrasound can accurately replace diagnostic
20 laparoscopy, mainly for deep and ovarian endometriosis. *Human reproduction* (Oxford,
21 England) 36(6): 1492-1500
- 22 **Gratton 2022**
- 23 Gratton, Sara-Michelle, Choudhry, Abdul Jamil, Vilos, George A et al. (2022) Diagnosis of
24 Endometriosis at Laparoscopy: A Validation Study Comparing Surgeon Visualization with
25 Histologic Findings. *Journal of obstetrics and gynaecology Canada : JOGC = Journal
26 d'obstetrique et gynecologie du Canada : JOGC* 44(2): 135-141
- 27 **Harth 2023**
- 28 Harth, Sebastian, Roller, Fritz C, Zeppernick, Felix et al. (2023) Deep Infiltrating
29 Endometriosis: Diagnostic Accuracy of Preoperative Magnetic Resonance Imaging with
30 Respect to Morphological Criteria. *Diagnostics* (Basel, Switzerland) 13(10)
- 31 **Hausmann 2021**
- 32 Hausmann, Daniel, Perignon, Vasiliki, Grabherr, Regula et al. (2021) Can Dynamic Contrast-
33 enhanced MRI Contribute to Improved Assessment of Rectosigmoid Involvement in Deep
34 Infiltrating Endometriosis?. *In vivo* (Athens, Greece) 35(4): 2217-2226
- 35 **Hernandez Gutierrez 2019**
- 36 Hernandez Gutierrez, Alicia, Spagnolo, Emanuela, Hidalgo, Paula et al. (2019) Magnetic
37 resonance imaging versus transvaginal ultrasound for complete survey of the pelvic
38 compartments among patients with deep infiltrating endometriosis. *International journal of
39 gynaecology and obstetrics: the official organ of the International Federation of Gynaecology
40 and Obstetrics* 146(3): 380-385
- 41 **Jiang 2017**

- 1 Jiang, Jipeng, Liu, Ying, Wang, Kun et al. (2017) Rectal water contrast transvaginal
2 ultrasound versus double-contrast barium enema in the diagnosis of bowel endometriosis.
3 *BMJ open* 7(9): e017216
- 4 **Kamkarfar 2022**
- 5 Kamkarfar, Pegah, Shahriyariipoor, Roya, Rokhgireh, Samaneh et al. (2022) Comparison of
6 diagnostic values of transvaginal sonography with laparoscopic and histological results in the
7 evaluation of uterosacral ligaments' involvement in endometriosis patients. *Caspian journal of*
8 *internal medicine* 13(4): 705-712
- 9 **Montanari 2022**
- 10 Montanari, E, Bokor, A, Szabo, G et al. (2022) Accuracy of sonography for non-invasive
11 detection of ovarian and deep endometriosis using Enzian classification: prospective
12 multicenter diagnostic accuracy study. *Ultrasound in obstetrics & gynecology : the official*
13 *journal of the International Society of Ultrasound in Obstetrics and Gynecology* 59(3): 385-
14 391
- 15 **Puri 2022**
- 16 Puri, S., Gupta, A., Sandhu, G.S. et al. (2022) Comparison between Ultrasonography and
17 Magnetic Resonance Imaging in Endometriosis: A Prospective Study in a Tertiary Hospital.
18 *Journal of SAFOG* 14(2): 85-90
- 19 **Roditis 2023**
- 20 Roditis, Alexis, Florin, Marie, Rousset, Pascal et al. (2023) Accuracy of combined physical
21 examination, transvaginal ultrasonography, and magnetic resonance imaging to diagnose
22 deep endometriosis. *Fertility and sterility* 119(4): 634-643
- 23 **Rokhgireh 2020**
- 24 Rokhgireh, Samaneh, Mehdizadeh Kashi, Abolfazl, Chaichian, Shahla et al. (2020) The
25 Diagnostic Accuracy of Combined Enolase/Cr, CA125, and CA19-9 in the Detection of
26 Endometriosis. *BioMed research international* 2020: 5208279
- 27 **Ros 2021**
- 28 Ros, C, de Guirior, C, Mension, E et al. (2021) Transvaginal ultrasound for diagnosis of deep
29 endometriosis involving uterosacral ligaments, torus uterinus and posterior vaginal fornix:
30 prospective study. *Ultrasound in obstetrics & gynecology : the official journal of the*
31 *International Society of Ultrasound in Obstetrics and Gynecology* 58(6): 926-932
- 32 **Shahbazi 2022**
- 33 Shahbazi, M., Poordast, T., Masoudi, N. et al. (2022) The potential role of radiolabeled red
34 blood cell scintigraphy in diagnosis of endometriosis. *Iranian Journal of Nuclear Medicine*
35 30(1): 26-32
- 36 **Siddiqui 2021**
- 37 Siddiqui, Saad and Bari, Vaqar (2021) Accuracy of MRI Pelvis in the Diagnosis of Ovarian
38 Endometrioma: Using Histopathology as Gold Standard. *Cureus* 13(12): e20650
- 39 **Widschwendter 2022**
- 40 Widschwendter, P, Kohler, M, Friedl, Twp et al. (2022) Diagnosis of presence and extent of
41 deep infiltrating endometriosis by preoperative MRI-improvement of staging accuracy by
42 expert training. *Journal of gynecology obstetrics and human reproduction* 51(1): 102236

- 1 **Zannoni 2017**
- 2 Zannoni, Letizia, Del Forno, Simona, Coppola, Francesca et al. (2017) Comparison of
3 transvaginal sonography and computed tomography-colonography with contrast media and
4 urographic phase for diagnosing deep infiltrating endometriosis of the posterior compartment
5 of the pelvis: a pilot study. *Japanese journal of radiology* 35(9): 546-554
- 6 **Zhang 2019**
- 7 Zhang, Yujuan, Xiao, Xiaojun, Xu, Fanhua et al. (2019) Evaluation of Uterosacral Ligament
8 Involvement in Deep Endometriosis by Transvaginal Ultrasonography. *Frontiers in*
9 *pharmacology* 10: 374
- 10 **Economic**
- 11 **Khan 2018**
- 12 Khan KS, Tryposkiadis K, Tirlapur SA, Middleton LJ, Sutton AJ, Priest L, et al. MRI versus
13 laparoscopy to diagnose the main causes of chronic pelvic pain in women: a test-accuracy
14 study and economic evaluation. *Health Technology Assessment* 2018;22(40).
- 15 **Ferrier 2023**
- 16 Ferrier C, Bendifallah S, Suisse S, Dabi Y, Touboul C, Puchar A, et al. Saliva microRNA
17 signature to diagnose endometriosis: A cost effectiveness evaluation of the Endotest®.
18 *British Journal of Obstetrics and Gynaecology*. 2023;130(4):396–406
- 19 **Other**
- 20 **APPG 2020**
- 21 All party parliamentary group on endometriosis. Endometriosis in the UK: time for change.
22 2020. [Endometriosis APPG Report Oct 2020.pdf \(endometriosis-uk.org\)](#). Accessed 14
23 December 2023

1 Appendices

2 Appendix A Review protocols

3 Review protocol for review question: What is the accuracy of the following tests in diagnosing endometriosis:

- 4 • imaging
5 • biomarkers
6 • surgical diagnosis (open surgery or laparoscopic surgery)?

7
8

ID	Field	Content
0.	PROSPERO registration number	CRD42023433810
1.	Review title	Diagnosis of endometriosis
2.	Review question	What is the accuracy of the following tests in diagnosing endometriosis: <ul style="list-style-type: none">• imaging• biomarkers• surgical diagnosis (open surgery or laparoscopic surgery)?
3.	Objective	To evaluate the accuracy of diagnostic tests for the diagnosis of endometriosis in women with suspected endometriosis. This evidence review will allow the committee to consider the evidence to update recs in section 1.5 in Endometriosis: diagnosis and management (NG 73).
4.	Searches	The following databases will be searched: <ul style="list-style-type: none">• Clinical Searches:• Cochrane Central Register of Controlled Trials (CENTRAL)• Cochrane Database of Systematic Reviews (CDSR)

ID	Field	Content
		<ul style="list-style-type: none"> • Embase • MEDLINE All • Epistemonikos <p>Economic search:</p> <ul style="list-style-type: none"> • MEDLINE ALL • Embase • International Network of Agencies for Health Technology Assessment (INAHTA) • HTA <p>An economic evaluation filter will be applied.</p> <p>Searches will be restricted by:</p> <ul style="list-style-type: none"> • English language • Human studies • Date limit: 29/11/2016 (last date searched) <p>The full search strategies will be published in the final review.</p>
5.	Condition or domain being studied	Endometriosis
6.	Population	<p>Inclusion:</p> <p>Symptomatic and asymptomatic women with suspected endometriosis</p> <p>Symptomatic (examples)</p> <ul style="list-style-type: none"> • deep dyspareunia (pain on intercourse)

ID	Field	Content
		<ul style="list-style-type: none"> • superficial dyspareunia (pain on entry)- note: may not be a primary symptom of endometriosis, could be due to other conditions. • dyschezia (pain on bowel actions) • rectal bleeding • cyclical non-uterine bleeding e.g. nose bleed • dysmenorrhea/painful periods • cyclical/non-cyclical symptoms • c-birth scar nodule • respiratory symptoms • diaphragmatic pain • pelvic pain • women who have an appendicitis removed (or any other abdominal surgery) with the finding of an endometrioma or endometriosis • women presenting with symptoms similar to IBS • bladder symptoms -bleeding, dysuria, urinary retention • fatigue <p>Asymptomatic: (examples)</p> <ul style="list-style-type: none"> • women who have a scan for other reasons with the finding of an endometrioma or endometriosis • women who have a ureteric obstruction • infertility investigations that raise suspicion of endometriosis <p>Note: Post-menopausal women will be included. Women with scar tissue have anatomical distortion, so this population will not be excluded.</p> <p>Exclusion: None identified.</p>
7.	Test	Ultrasound (visual):

ID	Field	Content
		<ul style="list-style-type: none"> • transabdominal • transvaginal • rectal scanning <p>MRI:</p> <ul style="list-style-type: none"> • pelvic, thoracic and abdominal MRI <p>(There may be new types of MRI –these will be included)</p> <p>Biomarkers:</p> <ul style="list-style-type: none"> • biomarker cancer antigen 125 (CA-125, cut-off ≥ 35U/ml) • biomarker Human epididymis protein 4 (HE- 4) (note-only available in specialist centres). • biomarkers in endometrial tissues (the nerve fibre marker Protein Gene Product 9.5 (PGP 9.5)) • microRNAs in endometriosis (type of biomarker in blood and saliva) <p>Surgery:</p> <p>Surgical diagnosis without histological confirmation:</p> <ul style="list-style-type: none"> -open surgery or other operative or diagnostic procedures (incidental findings) anywhere in the body -diagnostic laparoscopy and other laparoscopic surgery <p>Combinations of tests.</p>
8.	Reference standard	<p>Surgical visualisation with histological confirmation:</p> <ul style="list-style-type: none"> -open surgery or other operative or diagnostic procedures (incidental findings) anywhere in the body -diagnostic laparoscopy and other laparoscopic surgery.

ID	Field	Content
9.	Types of study to be included	<p>Cross-sectional studies</p> <p>Cohort studies (prospective and retrospective). Retrospective cohort studies will only be included if there are insufficient prospective cohort studies.</p> <p>Systematic reviews and meta-analyses of the above</p>
10.	Other exclusion criteria	<p>Non-English language studies.</p> <p>Conference abstracts will be excluded as it is expected there will be sufficient full text published studies available.</p>
11.	Context	<p>This review question will partly update the following: Endometriosis: diagnosis and management (NG 73)</p>
12.	Primary outcomes (critical outcomes)	<p>Diagnosis of endometriosis</p> <p>Diagnostic test accuracy data (i.e. TP, FP, TN, FN) that allows calculation of</p> <ul style="list-style-type: none"> • sensitivity and specificity <p>Two decision thresholds for each measure, a value above which the test could be recommended and a value below which the test would be considered of no use.</p> <p>Decision thresholds are:</p> <ul style="list-style-type: none"> • sensitivity: high threshold 90%, low threshold 60% • specificity: high threshold 90%, low threshold 60% <p>Which is more important sensitivity or specificity?</p> <p>Sensitivity is considered to be more important as there are severe consequences of not diagnosing the condition.</p>
13.	Secondary	<p>Diagnostic test accuracy data (i.e. TP, FP, TN, FN) that allows calculation of</p>

ID	Field	Content
	outcomes (important outcomes)	<ul style="list-style-type: none"> Positive and negative predictive values <p>PPV and NPV values will be included only if sensitivity/specificity data are not available from the studies. Decision making thresholds for positive and negative predictive values have not been defined a priori. Imprecision and importance of positive and negative predictive values will be assessed qualitatively during committee discussions and documented in the committee's discussion and interpretation of the evidence.</p>
14.	Data extraction (selection and coding)	<p>All references identified by the searches and from other sources will be uploaded into EPPI and de-duplicated. Titles and abstracts of the retrieved citations will be screened to identify studies that potentially meet the inclusion criteria outlined in the review protocol.</p> <p>Dual sifting will be performed on at least 10% of records; 90% agreement is required. Disagreements will be resolved via discussion between the two reviewers, and consultation with senior staff if necessary.</p> <p>Full versions of the selected studies will be obtained for assessment. Studies that fail to meet the inclusion criteria once the full version has been checked will be excluded at this stage. Each study excluded after checking the full version will be listed, along with the reason for its exclusion.</p> <p>A standardised form will be used to extract data from studies. The following data will be extracted: study details (reference, country where study was carried out, type and dates), participant characteristics, inclusion and exclusion criteria, details of the interventions if relevant, setting and follow-up, relevant outcome data and source of funding. One reviewer will extract relevant data into a standardised form, and this will be quality assessed by a senior reviewer.</p>
15.	Risk of bias (quality) assessment	<p>Quality assessment of individual studies will be performed using the following checklists:</p> <p>ROBIS tool for systematic reviews of diagnostic test accuracy studies</p> <p>QUADAS-2 for diagnostic accuracy studies</p> <p>The quality assessment will be performed by one reviewer and this will be quality assessed by a senior reviewer.</p>
16.	Strategy for data synthesis	<p>Diagnostic review:</p> <p>Depending on the availability of the evidence, the findings will be summarised narratively or quantitatively. Where appropriate, meta-analysis of diagnostic test accuracy will be performed using Winbugs and Cochrane Review Manager software.</p> <p>Sensitivity, specificity, and positive and negative predictive values with 95% CIs will be used as outcomes for diagnostic test accuracy. These diagnostic accuracy parameters will be obtained from the studies or calculated by the technical team using data from the studies.</p> <p>The confidence in the findings across all available evidence will be evaluated for each outcome using an adaptation of the 'Grading of Recommendations Assessment, Development and Evaluation (GRADE) toolbox' developed by the international GRADE working group: http://www.gradeworkinggroup.org/</p>

ID	Field	Content
		<p>Please note, this is an update of NG73. The novel evidence identified from this review update will not be pooled with evidence from previous review versions due to differences in stratifications. Previous versions did not consider depth of endometriosis (deep, superficial, both or unspecified). The ultrasound approaches (transvaginal, transabdominal, transrectal etc) were combined in previous review versions, whereas in the new evidence from this review update all ultrasound approaches will be kept separate.</p>
17.	Analysis of sub-groups	<p>No population stratification based on symptoms, as symptoms are not co-related with the stage of endometriosis.</p> <p>Strata based on site:</p> <ul style="list-style-type: none"> • pelvic • thoracic • ovary (including endometriomas) [Endometriomas are cysts that can form when tissue from the lining of the uterus grows in the ovaries] • vagina • rectosigmoid • rectovaginal septum • uterosacral ligaments • pouch of Douglas (pouch of Douglas is a small area in the female human body between the uterus and the rectum) • bowel • bladder <p>Strata based on extent of involvement:</p> <ul style="list-style-type: none"> • superficial • deep <p>Evidence will be sub-grouped by the following only in the event that there is significant heterogeneity in outcomes:</p> <p>Ethnicity</p> <ul style="list-style-type: none"> • white • Asian/Asian British (Asian British/Black British will be for studies in the UK. For studies outside the UK we will look for the relevant ethnicities as specified.)

ID	Field	Content		
		<ul style="list-style-type: none"> • Black/African/Caribbean/Black British • mixed/multiple ethnic groups • other ethnic group <p>Where evidence is stratified or sub-grouped the committee will consider on a case-by-case basis if separate recommendations should be made for distinct groups. Separate recommendations may be made where there is evidence of a differential effect of interventions in distinct groups. If there is a lack of evidence in one group, the committee will consider, based on their experience, whether it is reasonable to extrapolate and assume the interventions will have similar effects in that group compared with others.</p>		
18.	Type and method of review	<input type="checkbox"/>	Intervention	
		<input checked="" type="checkbox"/>	Diagnostic	
		<input type="checkbox"/>	Prognostic	
		<input type="checkbox"/>	Qualitative	
		<input type="checkbox"/>	Epidemiologic	
		<input type="checkbox"/>	Service Delivery	
		<input type="checkbox"/>	Other (please specify)	
19.	Language	English		
20.	Country	England		
21.	Anticipated or actual start date	July 2023		
22.	Anticipated completion date	March 2023		
23.	Stage of review at time of this	Review stage	Started	Completed
		Preliminary searches	<input type="checkbox"/>	<input type="checkbox"/>

ID	Field	Content															
	submission	<table border="1"> <tr> <td>Piloting of the study selection process</td> <td><input type="checkbox"/></td> <td><input type="checkbox"/></td> </tr> <tr> <td>Formal screening of search results against eligibility criteria</td> <td><input type="checkbox"/></td> <td><input type="checkbox"/></td> </tr> <tr> <td>Data extraction</td> <td><input type="checkbox"/></td> <td><input type="checkbox"/></td> </tr> <tr> <td>Risk of bias (quality) assessment</td> <td><input type="checkbox"/></td> <td><input type="checkbox"/></td> </tr> <tr> <td>Data analysis</td> <td><input type="checkbox"/></td> <td><input type="checkbox"/></td> </tr> </table>	Piloting of the study selection process	<input type="checkbox"/>	<input type="checkbox"/>	Formal screening of search results against eligibility criteria	<input type="checkbox"/>	<input type="checkbox"/>	Data extraction	<input type="checkbox"/>	<input type="checkbox"/>	Risk of bias (quality) assessment	<input type="checkbox"/>	<input type="checkbox"/>	Data analysis	<input type="checkbox"/>	<input type="checkbox"/>
Piloting of the study selection process	<input type="checkbox"/>	<input type="checkbox"/>															
Formal screening of search results against eligibility criteria	<input type="checkbox"/>	<input type="checkbox"/>															
Data extraction	<input type="checkbox"/>	<input type="checkbox"/>															
Risk of bias (quality) assessment	<input type="checkbox"/>	<input type="checkbox"/>															
Data analysis	<input type="checkbox"/>	<input type="checkbox"/>															
24.	Named contact	<p>5a. Named contact National Guideline Alliance developer team at National Institute for Health and Care Excellence (NICE)</p> <p>5b Named contact e-mail Endodiagnosis@nice.org.uk</p> <p>5e Organisational affiliation of the review National Institute for Health and Care Excellence (NICE)</p>															
25.	Review team members	National Guideline Alliance developer team at National Institute for Health and Care Excellence (NICE)															
26.	Funding sources/sponsor	This systematic review is being completed by NICE.															
27.	Conflicts of interest	All guideline committee members and anyone who has direct input into NICE guidelines (including the evidence review team and expert witnesses) must declare any potential conflicts of interest in line with NICE's code of practice for declaring and dealing with conflicts of interest. Any relevant interests, or changes to interests, will also be declared publicly at the start of each guideline committee meeting. Before each meeting, any potential conflicts of interest will be considered by the guideline committee Chair and a senior member of the development team. Any decisions to exclude a person from all or part of a meeting will be documented. Any changes to a member's declaration of interests will be recorded in the minutes of the															

ID	Field	Content
		meeting. Declarations of interests will be published with the final guideline.
28.	Collaborators	Development of this systematic review will be overseen by an advisory committee who will use the review to inform the development of evidence-based recommendations in line with section 3 of Developing NICE guidelines: the manual . Members of the guideline committee are available on the NICE website: https://www.nice.org.uk/guidance/indevelopment/gid-ng10392
29.	Other registration details	
30.	Reference/URL for published protocol	Prospero registration number CRD42023433810
31.	Dissemination plans	NICE may use a range of different methods to raise awareness of the guideline. These include standard approaches such as: notifying registered stakeholders of publication publicising the guideline through NICE's newsletter and alerts issuing a press release or briefing as appropriate, posting news articles on the NICE website, using social media channels, and publicising the guideline within NICE.
32.	Keywords	[Give words or phrases that best describe the review.]
33.	Details of existing review of same topic by same authors	Update of review from NICE guidance NG73
34.	Current review status	<input checked="" type="checkbox"/> Ongoing
		<input type="checkbox"/> Completed but not published
		<input type="checkbox"/> Completed and published
		<input type="checkbox"/> Completed, published and being updated
		<input type="checkbox"/> Discontinued
35..	Additional information	[Provide any other information the review team feel is relevant to the registration of the review.]
36.	Details of final	www.nice.org.uk

ID	Field	Content
	publication	

1 CA-125: cancer antigen-125; CDSR: Cochrane Database of Systematic Reviews; CENTRAL: Cochrane Central Register of Controlled Trials; CI: confidence interval; FN: false
 2 negative; FP: false positive; GRADE: Grading of Recommendations Assessment, Development and Evaluation; HE-4: Human epididymis protein 4; HTA: Health Technology
 3 Assessment; IBS: irritable bowel syndrome; INAHTA: International Network of Agencies for Health Technology Assessment; MRI: magnetic resonance imaging; NPV: negative
 4 predictive value; PGP 9.5: Protein Gene Product 9.5; PPV: positive predictive value; PROSPERO: The International Prospective Register of Systematic Reviews; QUADAS:
 5 Quality Assessment of Diagnostic Accuracy Studies; ROBIS: Risk of Bias in Systematic Reviews; TN: true negative; TP: true positive

1 Appendix B Literature search strategies

2 Literature search strategies for review question: What is the accuracy of the 3 following tests in diagnosing endometriosis:

- 4 • imaging
- 5 • biomarkers
- 6 • surgical diagnosis (open surgery or laparoscopic surgery)?

7
8 Database: Ovid Medline

9 Date of last search: 06/06/2023

#	Searches
1	Endometriosis/
2	(endometriosis or endometrioma).ti,ab,kf.
3	or/1-2
4	exp Ultrasonography/
5	(ultrasono\$ or ultra-sono\$ or echo\$ or sono\$ or TVUS or "TRUS").ti,ab,kf.
6	((abdom\$ or transabdom\$ or vagina\$ or transvagina\$ or rect\$ or transrect\$) adj2 (US or USS or scan\$)).ti,ab,kf.
7	exp Magnetic Resonance Imaging/
8	(MRI or NMRI or FMRI).ti,ab,kf.
9	((magnetic resonance or MR or MTC or MT or NMR or magneti#ation transfer or spin or chemical shift) adj2 (imag\$ or tomogra\$)).ti,ab,kf.
10	Biomarkers/
11	Biomarkers, Tumor/
12	CA-125 Antigen/
13	exp Epididymal Secretory Proteins/
14	(CA 125 or CA125 or "mucin 16" or "cancer antigen 125").ti,ab,kf.
15	((human epididymis or human epididymal) adj2 (protein E4 or protein 4 or protein four)) or "HE 4" or HE4).ti,ab,kf.
16	("WAP four disulphide core domain" or "WAP four disulfide core domain" or WCFCD2 or WFDC2).ti,ab,kf.
17	((Protein gene product or PGP) adj2 "9.5").ti,ab,kf.
18	(MicroRNA\$ or miRNA\$).ti,ab,kf.
19	exp Biopsy/
20	exp Nerve Fibers/pa [Pathology]
21	biops\$.ti,ab,kf.
22	((nerve or neural) adj2 (fiber? or fibre?)).ti,ab,kf.
23	Minimally Invasive Surgical Procedures/
24	Laparoscopes/
25	Laparotomy/
26	Laparoscopy/
27	Gynecologic Surgical Procedures/
28	Cystoscopy/
29	exp Colonoscopy/
30	((Laparoscop\$ or celioscop\$ or peritoneoscop\$ or Laparot\$ or minilaparotom\$ or Cystoscop\$ or Colonoscop\$ or Sigmoidoscop\$) adj4 Diagnos\$).ti,ab,kf.
31	((Surg\$ adj3 Diagnos\$) or "incidental findings").ti.
32	exp Histology/
33	exp Histological Techniques/
34	((Histolog\$ or Histopath\$) adj3 (Diagnos\$ or Confirm\$)).ti,ab,kf.
35	or/4-34
36	exp "sensitivity and specificity"/
37	(sensitivity or specificity).ti,ab.
38	((pre test or pretest or post test) adj probability).ti,ab.
39	(predictive value* or PPV or NPV).ti,ab.
40	likelihood ratio*.ti,ab.
41	likelihood function/
42	((area under adj4 curve) or AUC).ti,ab.
43	(receive* operat* characteristic* or receive* operat* curve* or ROC curve*).ti,ab.
44	(diagnos* adj2 (performance* or accurac* or utilit* or value* or efficien* or effectiveness)).ti,ab.
45	gold standard.ab.
46	or/36-45
47	meta-analysis/

#	Searches
48	meta-analysis as topic/
49	(meta analy* or metanaly* or metaanaly*).ti,ab.
50	((systematic* or evidence*) adj2 (review* or overview*)).ti,ab.
51	(reference list* or bibliograph* or hand search* or manual search* or relevant journals).ab.
52	(search strategy or search criteria or systematic search or study selection or data extraction).ab.
53	(search* adj4 literature).ab.
54	(medline or pubmed or cochrane or embase or psychlit or psyclit or psychinfo or psycinfo or cinahl or science citation index or bids or cancerlit).ab.
55	cochrane.jw.
56	or/47-55
57	Observational Studies as Topic/
58	Observational Study/
59	Epidemiologic Studies/
60	exp Case-Control Studies/
61	exp Cohort Studies/
62	Cross-Sectional Studies/
63	Controlled Before-After Studies/
64	Historically Controlled Study/
65	Interrupted Time Series Analysis/
66	Comparative Study.pt.
67	case control\$.tw.
68	case series.tw.
69	(cohort adj (study or studies)).tw.
70	cohort analy\$.tw.
71	(follow up adj (study or studies)).tw.
72	(observational adj (study or studies)).tw.
73	longitudinal.tw.
74	prospective.tw.
75	retrospective.tw.
76	cross sectional.tw.
77	or/57-76
78	3 and 35
79	78 and (46 or 56 or 77)
80	*Endometriosis/di, pa [Diagnosis, Pathology]
81	35 and 80
82	Endometriosis/
83	*diagnostic imaging/ or "*diagnostic techniques, obstetrical and gynecological"/ or *diagnostic techniques, Surgical/
84	82 and 83
85	79 or 81 or 84
86	limit 85 to english language
87	letter/
88	editorial/
89	news/
90	exp historical article/
91	Anecdotes as topic/
92	comment/
93	case reports/
94	(letter or comment*).ti.
95	or/87-94
96	randomized controlled trial/ or random*.ti,ab.
97	95 not 96
98	animals/ not humans/
99	exp Animals, Laboratory/
100	exp Animal Experimentation/
101	exp Models, Animal/
102	exp Rodentia/
103	(rat or rats or rodent* or mouse or mice).ti.
104	or/97-103
105	86 not 104
106	limit 105 to yr="2016 -Current"

1

2 Database: Ovid Embase

1 Date of last search: 06/06/2023

#	Searches
1	Endometriosis/
2	(endometriosis#s or endometrioma?).ti,ab,kf.
3	or/1-2
4	exp echography/
5	(ultraso\$ or ultra-so\$ or echo\$ or sono\$ or TVUS or "TRUS").ti,ab,kf.
6	((abdom\$ or transabdom\$ or vagina\$ or transvagina\$ or rect\$ or transrect\$) adj2 (US or USS or scan\$)).ti,ab,kf.
7	exp nuclear magnetic resonance imaging/
8	(MRI or NMRI or FMRI).ti,ab,kf.
9	((magnetic resonance or MR or MTC or MT or NMR or magneti#ation transfer or spin or chemical shift) adj2 (imag\$ or tomogra\$)).ti,ab,kf.
10	biological marker/
11	tumor marker/
12	CA-125 Antigen/
13	Human epididymis protein 4/
14	Epididymal Secretory Protein/
15	(CA 125 or CA125 or "mucin 16" or "cancer antigen 125").ti,ab,kf.
16	((human epididymis or human epididymal) adj2 (protein E4 or protein 4 or protein four)) or "HE 4" or HE4).ti,ab,kf.
17	("WAP four disulphide core domain" or "WAP four disulfide core domain" or WCFC2 or WFDC2).ti,ab,kf.
18	((Protein gene product or PGP) adj2 "9.5").ti,ab,kf.
19	(MicroRNA\$ or miRNA\$).ti,ab,kf.
20	endometrium biopsy/
21	biopsy/ and nerve fiber/
22	biops\$.ti,ab,kf.
23	((nerve or neural) adj2 (fiber? or fibre?)).ti,ab,kf.
24	*minimally invasive surgery/
25	*laparoscope/
26	*laparotomy/
27	*laparoscopy/
28	*gynecologic surgery/
29	*cystoscopy/
30	*colonoscopy/
31	*sigmoidoscopy/
32	((Laparoscop\$ or celioscop\$ or peritoneoscop\$ or Laparot\$ or minilaparotom\$ or Cystoscop\$ or Colonoscop\$ or Sigmoidoscop\$) adj4 Diagnos\$).ti,ab,kf.
33	((Surg\$ adj3 Diagnos\$) or "incidental findings").ti.
34	exp *histology/
35	((Histolog\$ or Histopath\$) adj3 (Diagnos\$ or Confirm\$)).ti,ab,kf.
36	or/4-35
37	exp "sensitivity and specificity"/
38	(sensitivity or specificity).ti,ab.
39	((pre test or pretest or post test) adj probability).ti,ab.
40	(predictive value* or PPV or NPV).ti,ab.
41	likelihood ratio*.ti,ab.
42	((area under adj4 curve) or AUC).ti,ab.
43	(receive* operat* characteristic* or receive* operat* curve* or ROC curve*).ti,ab.
44	diagnostic accuracy/
45	diagnostic test accuracy study/
46	gold standard.ab.
47	exp diagnostic error/
48	(false positiv* or false negativ*).ti,ab.
49	differential diagnosis/
50	(diagnos* adj3 (performance* or accurac* or utilit* or value* or efficien* or effectiveness or precision or validat* or validity or differential or error*)).ti,ab.
51	or/37-50
52	Clinical study/
53	Case control study/
54	Family study/
55	Longitudinal study/
56	Retrospective study/
57	comparative study/
58	Prospective study/
59	Randomized controlled trials/

#	Searches
60	58 not 59
61	Cohort analysis/
62	cohort analy\$.tw.
63	(Cohort adj (study or studies)).tw.
64	(Case control\$ adj (study or studies)).tw.
65	(follow up adj (study or studies)).tw.
66	(observational adj (study or studies)).tw.
67	(epidemiologic\$ adj (study or studies)).tw.
68	(cross sectional adj (study or studies)).tw.
69	case series.tw.
70	prospective.tw.
71	retrospective.tw.
72	or/52-57,60-71
73	systematic review/
74	meta-analysis/
75	(meta analy* or metanaly* or metaanaly*).ti,ab.
76	((systematic or evidence) adj2 (review* or overview*)).ti,ab.
77	(reference list* or bibliograph* or hand search* or manual search* or relevant journals).ab.
78	(search strategy or search criteria or systematic search or study selection or data extraction).ab.
79	(search* adj4 literature).ab.
80	(medline or pubmed or cochrane or embase or psychlit or psyclit or psychinfo or psycinfo or cinahl or science citation index or bids or cancerlit).ab.
81	((pool* or combined) adj2 (data or trials or studies or results)).ab.
82	cochrane.jw.
83	or/73-82
84	3 and 36
85	84 and (51 or 72 or 83)
86	*endometriosis/di [Diagnosis]
87	36 and 86
88	Endometriosis/
89	*DIAGNOSTIC IMAGING/ or *GYNECOLOGICAL examination/
90	88 and 89
91	85 or 87 or 90
92	limit 91 to english language
93	letter.pt. or letter/
94	note.pt.
95	editorial.pt.
96	case report/ or case study/
97	(letter or comment*).ti.
98	or/93-97
99	randomized controlled trial/ or random*.ti,ab.
100	98 not 99
101	animal/ not human/
102	nonhuman/
103	exp Animal Experiment/
104	exp Experimental Animal/
105	animal model/
106	exp Rodent/
107	(rat or rats or rodent* or mouse or mice).ti.
108	or/100-107
109	92 not 108
110	limit 109 to yr="2016 -Current"

1

2 **Databases: Cochrane Database of Systematic Reviews (CDSR); Cochrane Central Register of**
3 **Controlled Trials (CENTRAL) - Wiley**

4 **Date of last search: 06/06/2023**

ID	Search
#1	MeSH descriptor: [Endometriosis] explode all trees
#2	(endometriosis#s or endometrioma?):ti,ab
#3	#1 or #2
#4	MeSH descriptor: [Ultrasonography] explode all trees

ID	Search
#5	(ultraso* or ultra-so* or echo* or sono* or TVUS or "TRUS"):ti,ab
#6	((abdom* or transabdom* or vagina* or transvagina* or rect* or transrect*) near/2 (US or USS or scan*)):ti,ab
#7	MeSH descriptor: [Magnetic Resonance Imaging] explode all trees
#8	(MRI or NMRI or FMRI):ti,ab
#9	((magnetic resonance or MR or MTC or MT or NMR or magneti?ation transfer or spin or chemical shift) near/2 (imag* or tomogra*)):ti,ab
#10	MeSH descriptor: [Biomarkers] explode all trees
#11	MeSH descriptor: [Biomarkers, Tumor] explode all trees
#12	MeSH descriptor: [CA-125 Antigen] explode all trees
#13	MeSH descriptor: [Epididymal Secretory Proteins] explode all trees
#14	(CA 125 or CA125 or "mucin 16" or "cancer antigen 125"):ti,ab
#15	((human epididymis or human epididymal) near/2 (protein E4 or protein 4 or protein four)) or "HE 4" or HE4):ti,ab
#16	("WAP four disulphide core domain" or "WAP four disulfide core domain" or WCFCD2 or WFDC2):ti,ab
#17	((Protein gene product or PGP) near/2 "9.5"):ti,ab
#18	(MicroRNA* or miRNA*):ti,ab
#19	MeSH descriptor: [Biopsy] explode all trees
#20	MeSH descriptor: [Nerve Fibers] explode all trees and with qualifier(s): [pathology - PA]
#21	biops*:ti,ab
#22	((nerve or neural) near/2 (fiber? or fibre?)):ti,ab
#23	MeSH descriptor: [Minimally Invasive Surgical Procedures] this term only
#24	MeSH descriptor: [Laparoscopes] this term only
#25	MeSH descriptor: [Laparotomy] this term only
#26	MeSH descriptor: [Laparoscopy] this term only
#27	MeSH descriptor: [Gynecologic Surgical Procedures] this term only
#28	MeSH descriptor: [Cystoscopy] this term only
#29	MeSH descriptor: [Colonoscopy] explode all trees
#30	((Laparoscop* or celioscop* or peritoneoscop* or Laparot* or minilaparotom* or Cystoscop* or Colonoscop* or Sigmoidoscop*) near/4 Diagnos*):ti,ab
#31	((Surg* near/3 Diagnos*) or "incidental findings"):ti
#32	MeSH descriptor: [Histology] explode all trees
#33	MeSH descriptor: [Histological Techniques] explode all trees
#34	((Histolog* or Histopath*) near/3 (Diagnos* or Confirm*)):ti,ab
#35	{or #4-#34}
#36	MeSH descriptor: [Endometriosis] this term only and with qualifier(s): [pathology - PA, diagnosis - DI]
#37	#35 and #36
#38	MeSH descriptor: [Endometriosis] this term only
#39	MeSH descriptor: [Diagnostic Imaging] this term only
#40	MeSH descriptor: [Diagnostic Techniques, Obstetrical and Gynecological] this term only
#41	MeSH descriptor: [Diagnostic Techniques, Surgical] this term only
#42	#38 and {or #39-#41}
#43	#3 and #35
#44	#37 or #42 or #43 with Cochrane Library publication date Between Nov 2016 and Jul 2023
#45	conference:pt or (clinicaltrials or trialsearch):so
#46	#44 not #45

1

2 **Database: Epistemonikos**

3 **Date of last search: 06/06/2023**

#	Search
1	(title:((title:(endometriosis OR endometrioses OR endometrioma*) OR abstract:(endometriosis OR endometrioses OR endometrioma*))) OR abstract:((title:(endometriosis OR endometrioses OR endometrioma*) OR abstract:(endometriosis OR endometrioses OR endometrioma*))))
2	(title:((ultraso* OR ultra-so* OR echo* OR sono* OR TVUS OR "TRUS")) OR abstract:((ultraso* OR ultra-so* OR echo* OR sono* OR TVUS OR "TRUS"))) OR (title:(((abdom* OR transabdom* OR vagina* OR transvagina* OR rect* OR transrect*) AND (US OR USS OR scan*))) OR abstract:(((abdom* OR transabdom* OR vagina* OR transvagina* OR rect* OR transrect*) AND (US OR USS OR scan*)))) OR (title:((MRI OR NMRI OR FMRI)) OR abstract:((MRI OR NMRI OR FMRI))) OR (title:(((magnetic resonance OR MR OR MTC OR MT OR NMR OR magnetisation transfer OR spin OR chemical shift) AND (imag* OR tomogra*))) OR abstract:(((magnetic resonance OR MR OR MTC OR MT OR NMR OR magnetisation transfer OR spin OR chemical shift) AND (imag* OR tomogra*))) OR (title:((CA 125 OR CA125 OR "mucin 16" OR "cancer antigen 125")) OR abstract:((CA 125 OR CA125 OR "mucin 16" OR "cancer antigen 125"))) OR (title:((((human epididymis OR human epididymal) AND (protein E4 OR protein 4 OR protein four)) OR "HE 4" OR HE4)) OR

#	Search
	abstract:(((human epididymis OR human epididymal) AND (protein E4 OR protein 4 OR protein four)) OR "HE 4" OR HE4))) OR (title:(("WAP four disulphide core domain" OR "WAP four disulfide core domain" OR WCFCD2 OR WFDC2)) OR abstract:(("WAP four disulphide core domain" OR "WAP four disulfide core domain" OR WCFCD2 OR WFDC2))) OR (title:(((Protein gene product OR PGP) AND "9.5")) OR abstract:(((Protein gene product OR PGP) AND "9.5"))) OR (title:(MicroRNA* OR miRNA*)) OR abstract:(MicroRNA* OR miRNA*)) OR (title:(biops*) OR abstract:(biops*)) OR (title:(((nerve OR neural) AND (fiber* OR fibre*))) OR abstract:(((nerve OR neural) AND (fiber* OR fibre*)))) OR (title:(((Laparoscop* OR celioscop* OR peritoneoscop* OR Laparot* OR minilaparotom* OR Cystoscop* OR Colonoscop* OR Sigmoidoscop*) AND Diagnos*)) OR abstract:(((Laparoscop* OR celioscop* OR peritoneoscop* OR Laparot* OR minilaparotom* OR Cystoscop* OR Colonoscop* OR Sigmoidoscop*) AND Diagnos*)) OR title:(((Surg* AND Diagnos*) OR "incidental findings") OR (title:(((Histolog* OR Histopath*) AND (Diagnos* OR Confirm*))) OR abstract:(((Histolog* OR Histopath*) AND (Diagnos* OR Confirm*))))
3	1 and 2, Limit to 2016-2023, No Cochrane, Systematic Reviews

1

2 **Economic Search Strategies:**

3

4 **Database: Ovid MEDLINE**

5

6 **Date of last search: 06/06/2023**

7

1	Endometriosis/
2	(endometriosis\$ or endometrioma?).ti,ab,kf.
3	or/1-2
4	exp Ultrasonography/
5	(ultrason\$ or ultra-son\$ or echo\$ or sono\$ or TVUS or "TRUS").ti,ab,kf.
6	((abdom\$ or transabdom\$ or vagina\$ or transvagina\$ or rect\$ or transrect\$) adj2 (US or USS or scan\$)).ti,ab,kf.
7	exp Magnetic Resonance Imaging/
8	(MRI or NMRI or FMRI).ti,ab,kf.
9	((magnetic resonance or MR or MTC or MT or NMR or magneti#ation transfer or spin or chemical shift) adj2 (imag\$ or tomogra\$)).ti,ab,kf.
10	Biomarkers/
11	Biomarkers, Tumor/
12	CA-125 Antigen/
13	exp Epididymal Secretory Proteins/
14	(CA 125 or CA125 or "mucin 16" or "cancer antigen 125").ti,ab,kf.
15	(((human epididymis or human epididymal) adj2 (protein E4 or protein 4 or protein four)) or "HE 4" or HE4).ti,ab,kf.
16	("WAP four disulphide core domain" or "WAP four disulfide core domain" or WCFCD2 or WFDC2).ti,ab,kf.
17	((Protein gene product or PGP) adj2 "9.5").ti,ab,kf.
18	(MicroRNA\$ or miRNA\$).ti,ab,kf.
19	exp Biopsy/
20	exp Nerve Fibers/pa [Pathology]
21	biops\$.ti,ab,kf.
22	((nerve or neural) adj2 (fiber? or fibre?)).ti,ab,kf.
23	Minimally Invasive Surgical Procedures/
24	Laparoscopes/
25	Laparotomy/
26	Laparoscopy/
27	Gynecologic Surgical Procedures/
28	Cystoscopy/
29	exp Colonoscopy/
30	((Laparoscop\$ or celioscop\$ or peritoneoscop\$ or Laparot\$ or minilaparotom\$ or Cystoscop\$ or Colonoscop\$ or Sigmoidoscop\$) adj4 Diagnos\$).ti,ab,kf.
31	((Surg\$ adj3 Diagnos\$) or "incidental findings").ti.
32	exp Histology/
33	exp Histological Techniques/
34	((Histolog\$ or Histopath\$) adj3 (Diagnos\$ or Confirm\$)).ti,ab,kf.
35	or/4-34
36	*Endometriosis/di, pa [Diagnosis, Pathology]
37	35 and 36
38	Endometriosis/
39	*diagnostic imaging/ or "*diagnostic techniques, obstetrical and gynecological"/ or *diagnostic techniques, Surgical/

40	38 and 39
41	letter/
42	editorial/
43	news/
44	exp historical article/
45	Anecdotes as topic/
46	comment/
47	case reports/
48	(letter or comment*).ti.
49	or/41-48
50	randomized controlled trial/ or random*.ti,ab.
51	49 not 50
52	animals/ not humans/
53	exp Animals, Laboratory/
54	exp Animal Experimentation/
55	exp Models, Animal/
56	exp Rodentia/
57	(rat or rats or rodent* or mouse or mice).ti.
58	or/51-57
59	3 and 35
60	37 or 40 or 59
61	60 not 58
62	Economics/
63	Value of life/
64	exp "Costs and Cost Analysis"/
65	exp Economics, Hospital/
66	exp Economics, Medical/
67	Economics, Nursing/
68	Economics, Pharmaceutical/
69	exp "Fees and Charges"/
70	exp Budgets/
71	budget*.ti,ab.
72	cost*.ti.
73	(economic* or pharmaco?economic*).ti.
74	(price* or pricing*).ti,ab.
75	(cost* adj2 (effective* or utilit* or benefit* or minimi* or unit* or estimat* or variable*)).ab.
76	(financ* or fee or fees).ti,ab.
77	(value adj2 (money or monetary)).ti,ab.
78	or/62-77
79	61 and 78
80	limit 79 to english language
81	limit 80 to yr="2016 -Current"

1
2
3
4

Database: Ovid Embase

5 **Date of last search: 06/06/2023**

#	Searches
1	Endometriosis/
2	(endometriosis#s or endometrioma?).ti,ab,kf.
3	or/1-2
4	exp echography/
5	(ultraso\$ or ultra-so\$ or echo\$ or sono\$ or TVUS or "TRUS").ti,ab,kf.
6	((abdom\$ or transabdom\$ or vagina\$ or transvagina\$ or rect\$ or transrect\$) adj2 (US or USS or scan\$)).ti,ab,kf.
7	exp nuclear magnetic resonance imaging/
8	(MRI or NMRI or FMRI).ti,ab,kf.
9	((magnetic resonance or MR or MTC or MT or NMR or magneti#ation transfer or spin or chemical shift) adj2 (imag\$ or tomogra\$)).ti,ab,kf.
10	biological marker/
11	tumor marker/
12	CA-125 Antigen/
13	Human epididymis protein 4/
14	Epididymal Secretory Protein/
15	(CA 125 or CA125 or "mucin 16" or "cancer antigen 125").ti,ab,kf.

#	Searches
16	((human epididymis or human epididymal) adj2 (protein E4 or protein 4 or protein four)) or "HE 4" or HE4).ti,ab,kf.
17	("WAP four disulphide core domain" or "WAP four disulfide core domain" or WCFCD2 or WFDC2).ti,ab,kf.
18	((Protein gene product or PGP) adj2 "9.5").ti,ab,kf.
19	(MicroRNA\$ or miRNA\$).ti,ab,kf.
20	endometrium biopsy/
21	biopsy/ and nerve fiber/
22	biops\$.ti,ab,kf.
23	((nerve or neural) adj2 (fiber? or fibre?)).ti,ab,kf.
24	*minimally invasive surgery/
25	*laparoscope/
26	*laparotomy/
27	*laparoscopy/
28	*gynecologic surgery/
29	*cystoscopy/
30	*colonoscopy/
31	*sigmoidoscopy/
32	((Laparoscop\$ or celioscop\$ or peritoneoscop\$ or Laparot\$ or minilaparotom\$ or Cystoscop\$ or Colonoscop\$ or Sigmoidoscop\$) adj4 Diagnos\$).ti,ab,kf.
33	((Surg\$ adj3 Diagnos\$) or "incidental findings").ti.
34	exp *histology/
35	((Histolog\$ or Histopath\$) adj3 (Diagnos\$ or Confirm\$)).ti,ab,kf.
36	or/4-35
37	*endometriosis/di [Diagnosis]
38	36 and 37
39	Endometriosis/
40	*DIAGNOSTIC IMAGING/ or *GYNECOLOGICAL examination/
41	39 and 40
42	letter.pt. or letter/
43	note.pt.
44	editorial.pt.
45	case report/ or case study/
46	(letter or comment*).ti.
47	or/42-46
48	randomized controlled trial/ or random*.ti,ab.
49	47 not 48
50	animal/ not human/
51	nonhuman/
52	exp Animal Experiment/
53	exp Experimental Animal/
54	animal model/
55	exp Rodent/
56	(rat or rats or rodent* or mouse or mice).ti.
57	or/49-56
58	(conference abstract or conference paper).pt.
59	3 and 36
60	38 or 41 or 59
61	60 not 57
62	limit 61 to english language
63	62 not 58
64	health economics/
65	exp economic evaluation/
66	exp health care cost/
67	exp fee/
68	budget/
69	funding/
70	budget*.ti,ab.
71	cost*.ti.
72	(economic* or pharmaco?economic*).ti.
73	(price* or pricing*).ti,ab.
74	(cost* adj2 (effective* or utilit* or benefit* or minimi* or unit* or estimat* or variable*)).ab.
75	(financ* or fee or fees).ti,ab.
76	(value adj2 (money or monetary)).ti,ab.
77	or/64-76
78	63 and 77
79	limit 78 to yr="2016 -Current"

1 **Database: Health Technology Assessment (HTA)**

2 **Date of last search: 06/06/2023**

#	Search
1	MeSH DESCRIPTOR Endometriosis EXPLODE ALL TREES
2	((endometriosis OR endometrioses OR endometrioma*))
3	#1 OR #2
4	(#1 OR #2) IN HTA
5	(#1 OR #2) IN HTA FROM 2016 TO 2023

3

4 **Database: INAHTA International HTA Database**

5 **Date of last search: 06/06/2023**

#	Search
	("Endometriosis"[mh]) OR (endometriosis or endometrioses or endometrioma*), limit 2016-2023

6

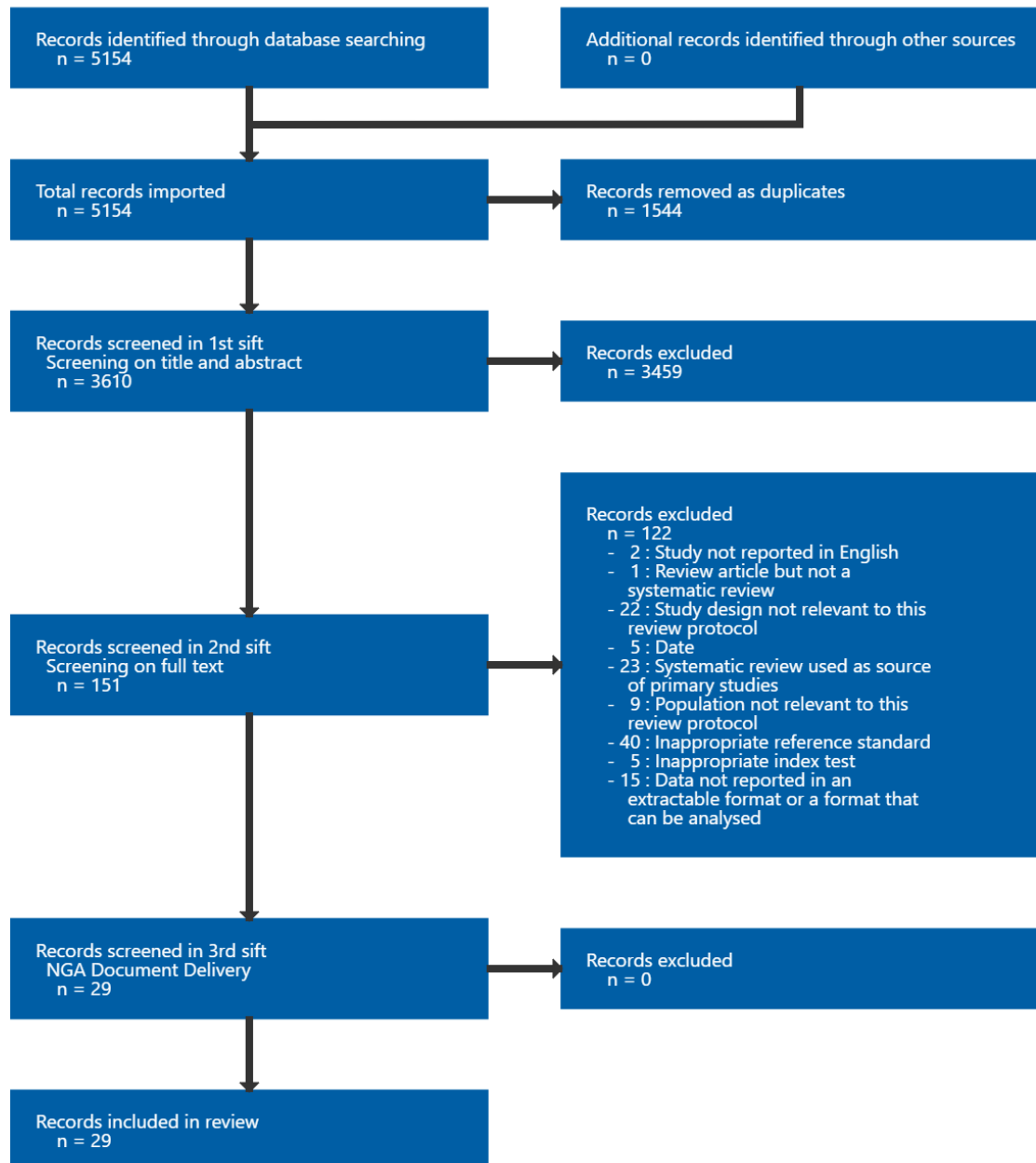
7

1 Appendix C Diagnostic evidence study selection

2 Study selection for: What is the accuracy of the following tests in diagnosing 3 endometriosis:

- 4 • imaging
- 5 • biomarkers
- 6 • surgical diagnosis (open surgery or laparoscopic surgery)?

Figure 1: Study selection flow chart



7

8

9

1 Appendix D Evidence tables

2 Evidence tables for review question: What is the accuracy of the following tests in diagnosing endometriosis:

- 3 • imaging
- 4 • biomarkers
- 5 • surgical diagnosis (open surgery or laparoscopic surgery)?

6 Alborzi, 2018

Bibliographic Reference Alborzi, Saeed; Rasekhi, Alireza; Shomali, Zahra; Madadi, Gooya; Alborzi, Mahshid; Kazemi, Mahboobeh; Hosseini Nohandani, Azam; Diagnostic accuracy of magnetic resonance imaging, transvaginal, and transrectal ultrasonography in deep infiltrating endometriosis.; Medicine; 2018; vol. 97 (no. 8); e9536

7

8 Study details

Country/ies where study was carried out	Iran
Study type	Prospective cohort study
Study dates	March 2013 to February 2015
Inclusion criteria	<ul style="list-style-type: none"> • Suspected endometriosis based on: • clinical symptoms (chronic pelvic pain, dyspareunia and dysmenorrhea) • and physical examination findings (localized tenderness in the posterior cul-de-sac or uterosacral ligament; palpable tender nodules in retrocervical position; tender enlarged adnexal mass).
Exclusion criteria	<ul style="list-style-type: none"> • Claustrophobia • renal failure or any other contraindication for gadolinium contrast medium injection • malignancy • history of any metallic implants, or prostheses preventing MRI study • structural anomalies of the reproductive system • pregnancy

	<ul style="list-style-type: none"> • refusal, or lack of compliance with TVS or TRS • virgin subjects as these could not undergo TVS.
Patient characteristics	<p>N=317 symptomatic participants</p> <p><u>Age, year - mean (SD):</u> 31 (5.4)</p> <p><u>Endometriosis location, number (%):</u> Uterosacral ligament: 151 (43.1) Ovarian fossa: 59 (16.9) Rectal wall: 52 (14.9) Rectovaginal septum: 44 (12.6) Bladder: 4 (1.1)</p> <p>Ethnicity not reported</p> <p>Tertiary healthcare centre.</p>
Index test(s)	<p><u>Transvaginal sonography (TVS)</u></p> <ul style="list-style-type: none"> • Performed by a gynaecologic ultrasonologist with 30 years experience • 7.5 MHz probe used • evaluation done on non-menstrual days of the cycle • bladder was semi-filled and bowel prepped • interpretations were done in real-time. • examination protocol consisted of visualisation compartments, of the peritoneum and structures in the anterior and posterior as well as the uterus and ovaries. • Nodular, hypo-echoic solid lesions with and without cystic components, in different structures of the pelvic cavity were considered highly suggestive for deep infiltration endometriosis (DIE). • Hyper-echogenic abnormal thickening of the peritoneum was considered as a sign of DIE. <p><u>Transrectal sonography (TRS)</u></p> <ul style="list-style-type: none"> • Performed by the same operator as TVS 2 weeks after TVS. • 7.5 MHz probe used • bowel was prepped (participants had a soft diet on the day and 2 spoonful milk of magnesium syrup orally after lunch)

	<ul style="list-style-type: none"> and 2 suppositories of 10 mg bisacodyl at 6pm and 12 midnight on the day before the procedure. procedure performed with an empty bladder interpretation was done in real time and the protocol was similar to TVS and the same diagnostic criteria applied. <p><u>Magnetic resonance imaging (MRI)</u></p> <ul style="list-style-type: none"> Performed after 4 hours of fasting with semi-filled bladder before and after the injection of contract medium. Performed by board-certified radiologist with MRI fellowship. Endometriomas were characterized by high signal in T1- and low signal in T2-weighted images. DIE was low signal or signal void in T2-weighted images. Thickening of the walls were in favour of involvements.
Reference standard(s)	<p><u>Laparoscopy with histology</u></p> <ul style="list-style-type: none"> Performed by the same gynaecologist after whole bowel prep under general anaesthesia. Lesions were excised and sent to histopathological examination. All biopsies were studied in the laboratory after hematoxylin and eosin staining by the pathologist who was unaware of clinical and imaging findings. Diagnosis was confirmed for all resected tissue samples after evaluating both glands and stroma.
Duration of follow-up	Not reported
Sources of funding	Not industry funded
Target condition	Deep infiltrating endometriosis (DIE)
Results	<p>N=317</p> <p>Site: Uterosacral ligaments TVS: TP 107; FP 12; FN 44; TN 154 TRS: TP 125; FP 17; FN 26; TN 149 MRI: TP 96; FP 10; FN 55; TN 156</p>

<p>Site: rectovaginal septum TVS: TP 38; FP 14; FN 6; TN 259 TRS: TP 37; FP 17; FN 7; TN 256 MRI: TP 32; FP 13; FN 12; TN 260</p> <p>Site: rectal wall (classified as rectosigmoid in review analysis) TVS: TP 46; FP 3; FN 6; TN 262 TRS: TP 45; FP 6; FN 7; TN 259 MRI: TP 40; FP 9; FN 12; TN 256</p> <p>Site: bladder TVS: TP 4; FP 1; FN 0; TN 312 TRS: TP 4; FP 1; FN 0; TN 312 MRI: TP 4; FP 1; FN 0; TN 312</p> <p>All DIE lesions (categorised as multiple sites) TVS: TP 210; FP 35; FN 42; TN 30 TRS: TP 203; FP 53; FN 49; TN 12 MRI: TP 228; FP 22; FN 24; TN 43</p>

1 Critical appraisal – NGA Critical appraisal – QUADAS-2

Section	Question	Answer
Patient selection: risk of bias	Could the selection of patients have introduced bias?	Low <i>(Participants not consecutively or randomly enrolled, however those with suspicious history of endometriosis were enrolled and there were no inappropriate exclusions.)</i>
Patient selection: applicability	Are there concerns that included patients do not match the review question?	Low
Index tests: risk of bias	Could the conduct or interpretation of the index test have introduced bias?	Low
Index tests:	Are there concerns that the index test, its conduct,	Low

Section	Question	Answer
applicability	or interpretation differ from the review question?	
Reference standard: risk of bias	Could the reference standard, its conduct, or its interpretation have introduced bias?	Low
Reference standard: applicability	Is there concern that the target condition as defined by the reference standard does not match the review question?	Low
Flow and timing: risk of bias	Could the patient flow have introduced bias?	Unclear (<i>Unclear time between tests.</i>)

1

2 **Alborzi, 2023****Bibliographic Reference**

Alborzi, Saeed; Poordast, Tahereh; Askary, Elham; Javedanmehr, Masoomeh; Shahraki, Mahboobeh Hamed; Alborzi, Soroosh; Abadi, Alimohammad Keshtvarz Hesam; Evaluation and comparison of the accuracy of transvaginal ultrasound and MRI for the diagnosis of deep rectal endometriosis: A cross-sectional study.; International journal of gynaecology and obstetrics: the official organ of the International Federation of Gynaecology and Obstetrics; 2023; vol. 161 (no. 2); 586-593

3

4 **Study details**

Country/ies where study was carried out	Iran
Study type	Retrospective cohort study
Study dates	March 2015 to March 2021

Inclusion criteria	<ul style="list-style-type: none"> • Age 18 to 55 • endometriosis-related pain without response to medication • involvement of tubes in case of infertility • conditions where use of hormonal drugs was not possible • more than 2 unsuccessful in vitro fertilisation attempts • need for pathology samples.
Exclusion criteria	<ul style="list-style-type: none"> • Previous bowel surgery • contraindications for MRI (such as kidney disease) • pregnancy • refusal or intolerance to transvaginal ultrasound or MRI.
Patient characteristics	<p>N=555 symptomatic participants</p> <p>Participants were categorised according to resection methods (shaving, disk and segmental)</p> <p><u>Age, year – mean (range):</u> Shaving: 34.13 (33.20 to 35.07) Disk resection: 34.80 (33.61 to 35.99) Segmental resection: 35.37 (34.67 to 36)</p> <p>Ethnicity not reported.</p> <p><u>Score of endometriosis according to American Society for Reproductive Medicine classification:</u> Shaving: 103.51 (98.22 to 108.81) Disk resection: 111.40 (104.5 to 118.3) Segmental resection: 111.62 (107.46 to 115.78)</p> <p><u>Location of deep infiltrating endometriosis (DIE). Number (%):</u> Right uterosacral ligament: 459 (82.7) Left uterosacral ligament: 445 (80.2) Right endometrioma: 336 (60.7) Left endometrioma: 315 (56.8) Rectal wall: 534 (95.8) Vagina: 17 (3.1)</p>

	Bladder: 11 (2)
	Hospital setting - secondary or tertiary centre not reported.
Index test(s)	<p><u>Transvaginal ultrasound:</u></p> <ul style="list-style-type: none"> • 7.5-MHz probe used • evaluation carried out following bowel preparation with a semi-filled bladder (based on International Deep Endometriosis Analysis consensus) <p><u>MRI:</u></p> <ul style="list-style-type: none"> • Examination of the pelvis using a 1.5-Tesla scanner before and after the intravascular injection of gadolinium contrast agent at a dose of 0.01mmol/kg, with use of internal vaginal coil. • Performed 4 hours after fasting with a semi-filled bladder. • MRI evaluations were reported by a board-certified radiologist with MRI fellowship. • Uterosacral ligaments and rectal wall were evaluated in the coronal and axial T2 weighted images. • DIE was the low signal or signal void in T2 weight images. • Bowel involvement was identified when the retractable nodular formations were found adhered to the rectosigmoid wall, with a strong hypo signal in T2. <p>Time between tests not reported.</p>
Reference standard(s)	<p><u>Laparoscopy with histology</u></p> <ul style="list-style-type: none"> • Surgeries performed according to the guideline protocols (European Society of Human Reproduction and Embryology 2022). • Superficial DIE lesions of the bowel were removed through the shaving method. • Deep DIE lesions between 1 to 3 cm were treated with disk excision method. • Multiple nodules or large lesions (>3cm) or with more than 50% involvement of the bowel loop circumference were removed using segmental bowel resection.
Duration of follow-up	Not reported

Sources of funding	Not reported
Target condition	Deep infiltrating endometriosis (DIE)
Results	<p>Site: Rectal endometriosis (classified as rectosigmoid in review analysis) Transvaginal ultrasound: Calculated (using prevalence 534/555=0.96): TP 368; FP 2; FN 165; TN 20; MRI: Calculated (using prevalence 534/555=0.96): TP 272; FP 5; FN 261; TN 18;</p> <p>Site: Endometrioma Transvaginal ultrasound: Calculated using prevalence for right endometrioma (336/555=0.6): TP 233; FP 13; FN 100; TN 209 MRI: Calculated using prevalence for right endometrioma (336/555=0.6): TP 189; FP 7; FN 144; TN 215</p> <p>Site: Uterosacral ligament Transvaginal ultrasound: Calculated using prevalence for right uterosacral ligament (459/555=0.83): TP 244; FP 15; FN 217; TN 79 MRI: Calculated using prevalence for right uterosacral ligament (459/555=0.83): TP 179; FP 23; FN 281; TN 72</p> <p>Strata by extent for rectal endometriosis (prevalence not available to calculate 2x2 table):</p> <p><u>Superficial:</u> Transvaginal ultrasound: Sensitivity % (95% CI): 54.5 (49.2 to 59.8) Specificity % (95% CI): 100 (78.2 to 100) MRI: Sensitivity % (95% CI): 29.3 (24.6 to 34.3) Specificity % (95% CI): 80 (51.9 to 95.7)</p> <p><u>Deep:</u></p>

Transvaginal ultrasound:
Sensitivity % (95% CI): 98.88 (96 to 99.9)
Specificity % (95% CI): 77.8 (40 to 97.2)
MRI:
Sensitivity % (95% CI): 94.97 (90.7 to 97.7)
Specificity % (95% CI): 77.8 (40 to 97.2)

1 Critical appraisal - NGA Critical appraisal - QUADAS-2

Section	Question	Answer
Patient selection: risk of bias	Could the selection of patients have introduced bias?	Low <i>(Participants not consecutively or randomly enrolled, however those with suspicious history of endometriosis were enrolled and there were no inappropriate exclusions.)</i>
Patient selection: applicability	Are there concerns that included patients do not match the review question?	Low
Index tests: risk of bias	Could the conduct or interpretation of the index test have introduced bias?	Low <i>(Index test was performed before the reference standard and threshold was pre-specified.)</i>
Index tests: applicability	Are there concerns that the index test, its conduct, or interpretation differ from the review question?	Low
Reference standard: risk of bias	Could the reference standard, its conduct, or its interpretation have introduced bias?	Low <i>(Samples for histology were studied without knowledge of the index test.)</i>
Reference standard: applicability	Is there concern that the target condition as defined by the reference standard does not match the review question?	Low
Flow and timing: risk of bias	Could the patient flow have introduced bias?	Unclear <i>(The time between tests is unclear.)</i>

1

2 **Asgari, 2022****Bibliographic Reference**

Asgari, Zahra; Hosseini, Reihaneh; Sepidarkish, Mahdi; Nabati, Azar; Accuracy of transvaginal and transrectal ultrasounds in the diagnosis of endometriosis: A retrospective cohort study.; International journal of reproductive biomedicine; 2022; vol. 20 (no. 5); 365-376

3

4 **Study details**

Country/ies where study was carried out	Iran
Study type	Retrospective cohort study
Study dates	May 2018 to March 2020
Inclusion criteria	<ul style="list-style-type: none"> • Age >18 years • diagnosis of endometriosis based on the symptoms and clinical examination.
Exclusion criteria	<ul style="list-style-type: none"> • History of gynecological surgery or cancer, • structural anomalies of the reproductive system • pregnancy • lack of compliance with transvaginal ultrasound (TVUS) or transrectal ultrasound (TRUS).
Patient characteristics	<p>N=119 symptomatic participants <u>Age, year - mean (SD):</u> 33.76 (7.10)</p> <p><u>Presenting symptoms, number (%)</u> Dysmenorrhea 109 (91.59) Dyspareunia 62 (52.10) Dyschezia 34 (28.57)</p>

	<p>Dysuria 7 (5.88) Chronic pelvic pain 13 (10.92)</p> <p><u>Location of endometriosis and histopathologic findings, number (%)</u> Endometrioma (right): 75 (63.02) Endometrioma (left): 85 (71.42) Ovarian fossa (right): 62 (52.10) Ovarian fossa (left): 63 (52.94) Uterosacral ligaments (right): 55 (46.21) Uterosacral ligaments (left): 62 (52.10) Pouch of Douglas: 68 (57.14) Vagina: 1 (0.84) Rectosigmoid: 34 (28.57) Bladder: 2 (1.68)</p> <p>Hospital setting – secondary or tertiary not reported</p>
Index test(s)	<p><u>Transvaginal ultrasound TVUS</u></p> <ul style="list-style-type: none"> • Performed by gynaecologist • technique based on the International Deep Endometriosis Analysis group protocol • the review protocol included viewing compartments, peritoneum, and structures in the anterior and posterior parts as well as the uterus and ovaries • 5-9 MHz probe used • the evaluation was conducted on the non-menstrual days of the cycle • the participants were asked to have a semi-filled bladder and were submitted to a simple rectal enema (fleet enema) 1 hr prior to the procedure. • interpretations were done in real-time • TVUS diagnosis of endometriosis based on the presence of regular or irregular hypoechogenic nodular structure or hypoechogenic linear thickening with regular or irregular margins. <p><u>Transrectal ultrasound TRUS</u></p> <ul style="list-style-type: none"> • Performed by gynaecologist using 5-9-MHz probe for transrectal visualization of the rectosigmoid wall layers • the evaluation was done in non-menstrual days of the cycle • Participants were asked to I) have a soft diet on the day before sonography; II) skip breakfast on the day of the procedure; III) have 2 spoonfuls of milk of magnesium syrup orally after lunch; and IV) take 2 suppositories of 10 mg

	<p>bisacodyl at 6 PM and 12 midnight on the day before the procedure</p> <ul style="list-style-type: none"> the participants were asked to have a semi-filled bladder and were submitted to a simple rectal enema (fleet enema) 1 hr prior to the procedure. TRUS diagnosis of endometriosis based on the presence of regular or irregular hypoechoic nodular structure or hypoechoic linear thickening with regular or irregular margins.
Reference standard(s)	<p><u>Laparoscopy, radical resection of endometriosis, and histology</u></p> <ul style="list-style-type: none"> 2 gynaecologists performed the laparoscopy. Deep infiltrating endometriosis was defined as subperitoneal endometriotic infiltration of tissues > 5 mm. All the biopsies were transferred onto a glass slide and stained by hematoxylin and eosin, An experienced pathologist performed the diagnosis of endometriosis for all resected tissue samples after evaluating both glands and stroma.
Duration of follow-up	Not reported
Sources of funding	Not reported
Target condition	Deep infiltrating endometriosis (DIE)
Results	<p>Transvaginal and transrectal</p> <p>Site: Endometrioma (right) 75/119 TP 64; FP 11; FN 11; TN 33</p> <p>Site: Endometrioma (left) 85/119 TP 72; FP 4; FN 13; TN 30</p> <p>Site: Uterosacral ligaments (right) 55/119 TP 35; FP 16; FN 20; TN 48</p> <p>Site: Uterosacral ligaments (left) 62/119</p>

TP 34; FP 14; FN 28; TN 43
Site: Pouch of Douglas 68/119 TP 51; FP 16; FN 17; TN 35
Site: Rectosigmoid 34/119 TP 18; FP 5; FN 16; TN 80
Endometriosis was histologically confirmed in 117/119 women.

1 Critical appraisal - NGA Critical appraisal - QUADAS-2

Section	Question	Answer
Patient selection: risk of bias	Could the selection of patients have introduced bias?	Low <i>(Participants not consecutively or randomly enrolled, however time period specified and there were no inappropriate exclusions.)</i>
Patient selection: applicability	Are there concerns that included patients do not match the review question?	Low
Index tests: risk of bias	Could the conduct or interpretation of the index test have introduced bias?	Low
Index tests: applicability	Are there concerns that the index test, its conduct, or interpretation differ from the review question?	Low
Reference standard: risk of bias	Could the reference standard, its conduct, or its interpretation have introduced bias?	Low <i>(Histological confirmation was performed by a pathologist who was blinded to index test results.)</i>
Reference standard: applicability	Is there concern that the target condition as defined by the reference standard does not match the review question?	Low
Flow and timing: risk	Could the patient flow have introduced bias?	Unclear <i>(Timing between tests was unknown.)</i>

Section	Question	Answer
of bias		
1		
2	Barcellos, 2016	
Bibliographic Reference	Barcellos, Marcio Bezerra; Lasmar, Bernardo; Lasmar, Ricardo; Agreement between the preoperative findings and the operative diagnosis in patients with deep endometriosis.; Archives of gynecology and obstetrics; 2016; vol. 293 (no. 4); 845-50	
3	Study details	
Country/ies where study was carried out	Brazil	
Study type	Retrospective cohort study and prospective	
Study dates	March 2011 to November 2014	
Inclusion criteria	All patients who underwent surgery for deep endometriosis during study dates. Surgical indication: disabling pain; unsatisfactory response or contraindication to drug treatment.	
Exclusion criteria	<ul style="list-style-type: none"> • Those who had previously undergone surgery for endometriosis • those who did not accept the surgical procedure • those lost to follow-up • malformations of pelvic organs. 	

Patient characteristics	<p>N=46 symptomatic participants</p> <p><u>Age, years - mean (SD)</u> 34 (5.5)</p> <p><u>Ethnicity, n (%)</u> White: 28 (60.9) Mixed race: 13 (28.3) Black: 4 (8.7) Non declared: 1 (2.1)</p> <p><u>Symptoms of those undergoing surgery, n (%)</u> Dysmenorrhea: 43 (93.5) Dyspareunia: 27 (58.7) Infertility: 23 (50.0) Menorrhagia: 18 (39.1) Chronic pelvic pain: 17 (37.0) Disquezia: 14 (30.4) Urinary symptoms: 5 (10.9)</p> <p>Hospital setting – secondary or tertiary not reported</p>
Index test(s)	<p><u>Combination ultrasound and MRI</u></p> <ul style="list-style-type: none"> • Pelvic transabdominal or transvaginal ultrasound (TA-US or TV-US) • and/or magnetic resonance imaging of the pelvis (MRI)
Reference standard(s)	<p><u>Laparoscopy with histology</u></p> <p>Performed about 30 days after imaging</p>
Duration of follow-up	Not reported
Sources of funding	Not reported

Target condition	Deep endometriosis
Results	<p>Outcome: deep endometriosis</p> <p>Site: Uterosacral ligaments (2x2 calculated using prevalence: 39/46=0.85) TP 38; FP 3; FN 1; TN 4</p> <p>Site: Rectovaginal septum (2x2 calculated using prevalence: 2/46=0.04) TP 2; FP 0; FN 0; TN 44</p> <p>Site: Ovary (2x2 calculated using prevalence: 31/46=0.67) TP 28; FP 3; FN 3; TN 12</p> <p>Site: Intestine (2x2 calculated using prevalence: 25/46=0.54) TP 23; FP 1; FN 2; TN 20</p> <p>Site Bladder (2x2 calculated using prevalence: 6/46=0.13) TP 6; FP 0; FN 0; TN 40</p>

1 Critical appraisal - NGA Critical appraisal - QUADAS-2

Section	Question	Answer
Patient selection: risk of bias	Could the selection of patients have introduced bias?	Low <i>(Participants not consecutively or randomly enrolled, however inclusion criteria were specified and there were no inappropriate exclusions.)</i>
Patient selection: applicability	Are there concerns that included patients do not match the review question?	Low
Index tests: risk of bias	Could the conduct or interpretation of the index test have introduced bias?	Low
Index tests: applicability	Are there concerns that the index test, its conduct, or interpretation differ from the review question?	Low

Section	Question	Answer
Reference standard: risk of bias	Could the reference standard, its conduct, or its interpretation have introduced bias?	Unclear (<i>Knowledge of index test can introduce bias to the reference standard as it could affect the location the surgeon looks for lesions.</i>)
Reference standard: applicability	Is there concern that the target condition as defined by the reference standard does not match the review question?	Low
Flow and timing: risk of bias	Could the patient flow have introduced bias?	Low (<i>Surgery was performed about 30 days after imaging.</i>)

1

2 **Barra, 2021a****Bibliographic Reference**

Barra, Fabio; Alessandri, Franco; Scala, Carolina; Ferrero, Simone; Ultrasonographic 3D Evaluation in the Diagnosis of Bladder Endometriosis: A Prospective Comparative Diagnostic Accuracy Study.; Gynecologic and obstetric investigation; 2021; vol. 86 (no. 3); 299-306

3

4 **Study details**

Country/ies where study was carried out	Italy
Study type	Prospective cohort study
Study dates	March 2016 to March 2020
Inclusion criteria	<ul style="list-style-type: none"> • Premenopausal • underwent surgery for clinical suspicion of bladder endometriosis

Exclusion criteria	<ul style="list-style-type: none"> • Previous surgical or radiological diagnosis of bladder endometriosis • history of vesical surgery • previous bilateral oophorectomy • psychiatric disorders
Patient characteristics	<p>N=34 symptomatic participants</p> <p><u>Age, years - mean \pm SD</u> 34.9\pm2.6</p> <p><u>Ethnicity, number (%)</u> Caucasian: 30 (94.1) African: 1 (4.4) Asian: 1 (1.5)</p> <p><u>Symptoms, number (%)</u> Lower urinary symptoms: 7 (21.9) Dysmenorrhea: 11 (34.4) Dyspareunia: 18 (56.3) Chronic pelvic pain: 17 (53.3) Dyschezia: 4 (12.5)</p> <p>Tertiary or secondary centre not reported.</p>
Index test(s)	<p><u>Transvaginal ultrasound (TVS) (with or without 3D modality)</u></p> <ul style="list-style-type: none"> • TVS without 3D: endometriosis lesions appear as a filling defect of the posterior wall; variable protrusion into the lumen; iso/hypoechoic aspect sometimes visible with small transonic formations that usually are not vascularized. • 3D: BE lesions can be visualized as intraluminal spiculated nodules, with a retracting line all around the nodule. • Experience sonographer performed TVS without 3D and another sonographer blinded to previous scan performed 3D TVS.
Reference standard(s)	<p><u>Surgery with histology</u></p> <ul style="list-style-type: none"> • Performed 8 weeks after ultrasound.

	<ul style="list-style-type: none"> Performer not reported.
Duration of follow-up	Not reported
Sources of funding	Not industry funded
Target condition	Bladder endometriosis
Results	<p>TVS: TP 28; TN 147; FN 6; FP 13</p> <p>TVS+3D: TP 29; TN 144; FN 5; FP 16</p>

1 Critical appraisal - NGA Critical appraisal - QUADAS-2

Section	Question	Answer
Patient selection: risk of bias	Could the selection of patients have introduced bias?	Low <i>(Consecutive enrolment and inappropriate exclusions were avoided.)</i>
Patient selection: applicability	Are there concerns that included patients do not match the review question?	Low
Index tests: risk of bias	Could the conduct or interpretation of the index test have introduced bias?	Low <i>(Reference standard was performed 8 weeks after index test and threshold was pre-specified)</i>
Index tests: applicability	Are there concerns that the index test, its conduct, or interpretation differ from the review question?	Low
Reference standard: risk of	Could the reference standard, its conduct, or its interpretation have introduced bias?	Unclear <i>(No information on who performed the reference standard and whether they were blinded. Knowledge of index test can introduce bias to the reference)</i>

Section	Question	Answer
bias		<i>standard as it could affect the location the surgeon looks for lesions.)</i>
Reference standard: applicability	Is there concern that the target condition as defined by the reference standard does not match the review question?	Low
Flow and timing: risk of bias	Could the patient flow have introduced bias?	Low

1

2 **Barra, 2021b****Bibliographic Reference**

Barra, Fabio; Leone Roberti Maggiore, Umberto; Evangelisti, Giulio; Scala, Carolina; Alessandri, Franco; Vellone, Valerio Gaetano; Stabilini, Cesare; Ferrero, Simone; A prospective study comparing rectal water contrast-transvaginal ultrasonography with sonovaginography for the diagnosis of deep posterior endometriosis.; *Acta obstetrica et gynecologica Scandinavica*; 2021; vol. 100 (no. 9); 1700-1711

3

4 **Study details**

Country/ies where study was carried out	Italy
Study type	Prospective cohort study
Study dates	November 2017 to January 2020
Inclusion criteria	Women undergoing surgical treatment due to pain and intestinal symptoms suggestive of posterior compartment deep endometriosis.
Exclusion criteria	<ul style="list-style-type: none"> • Previous surgical diagnosis of deep endometriosis • previous radiological diagnosis of deep endometriosis • history of colorectal surgery (except appendectomy)

	<ul style="list-style-type: none"> • contraindications to bowel preparation or distending the rectosigmoid (such as rectal malformations) • previous bilateral ovariectomy • psychiatric disorders.
Patient characteristics	<p>N=281 symptomatic participants</p> <p><u>Age, years (mean ± SD):</u> 33.4 ± 5.8</p> <p><u>Ethnicity, n (%):</u> White: 264 (94.0) African: 12 (4.3) Asiatic: 5 (1.7)</p> <p><u>Symptoms, n (%)</u> Dysmenorrhea: 51/78 (65.4) (all other participants were using hormonal therapies that caused amenorrhea) Deep dyspareunia: 146/237 (61.6) (7 participants were not sexually active) Non-menstrual pelvic pain: 132 (47.0) Dyschezia: 98 (34.9) Diarrhea: 44 (15.7) Constipation: 38 (13.5) Abdominal bloating: 62 (22.1) Intestinal cramping: 67 (23.8) Passage of mucus: 51 (19.2)</p> <p>Tertiary or secondary centre not reported.</p>
Index test(s)	<p><u>Rectal water contrast–transvaginal sonography (RWC-TVS) and Sonovaginography (SVG)</u></p> <ul style="list-style-type: none"> • Performed by 2 gynaecological ultrasonologists. • Participants underwent RWC-TVS first, and sonovaginography 1 week to 2 months after. • Number, size and anatomical localization of posterior DE nodules were described according to IDEA criteria. • Uterosacral ligament: deep endometriosis nodules characterized by regular or irregular margins and often hyperechoic points, or a linear hypoechoic thickening with regular or irregular margins. • Rectovaginal septum: appears as lesions below a horizontal plane that passes along the lower margin of the posterior lip of the cervix, under the peritoneum.

	<ul style="list-style-type: none"> • Vagina: posterior vaginal fornix is thickened, with or without surrounding cystic anechoic areas. • Rectosigmoid: hypoechoic thickening of bowel muscularis propria, eventually characterized by hyperechoic foci with blurred margins.
Reference standard(s)	<p><u>Laparoscopy with histology</u></p> <ul style="list-style-type: none"> • Laparoscopy performed 3 months after final ultrasound • bowel specimens were sent unfixed for pathological analysis • specimens were prepared and stained for histological examination • endometriosis was identified by the presence of endometrial-like epithelium and stroma.
Duration of follow-up	Not reported
Sources of funding	Not reported
Target condition	Deep endometriosis
Results	<p>Site: Rectosigmoid (prevalence $n=88/281=0.31$) RWC-TVS: TP 83; FP 1; FN 4; TN 193 SVG: TP 71; FP 3; FN 16; TN 191</p> <p>Site: Vagina (prevalence $n=21/281=0.07$) RWC-TVS: TP 18; FP 4; FN 3; TN 256 SVG: TP 20; FP 1; FN 1; TN 259</p> <p>Site: uterosacral ligaments (prevalence $n=156/281=0.56$) RWC-TVS: TP 125; FP 9; FN 31; TN 116 SVG:</p>

	<p>TP 121; FP 14; FN 35; TN 111</p> <p>(SVG prioritised for analysis over RWC-TVS)</p> <p>2x2 calculated using prevalence and specificity/sensitivity</p>
--	---

1 **Critical appraisal - NGA Critical appraisal - QUADAS-2**

Section	Question	Answer
Patient selection: risk of bias	Could the selection of patients have introduced bias?	Low <i>(Participants were enrolled consecutively and no inappropriate exclusions)</i>
Patient selection: applicability	Are there concerns that included patients do not match the review question?	Low
Index tests: risk of bias	Could the conduct or interpretation of the index test have introduced bias?	Low <i>(Reference standard was performed after the index test and threshold was specified)</i>
Index tests: applicability	Are there concerns that the index test, its conduct, or interpretation differ from the review question?	Low
Reference standard: risk of bias	Could the reference standard, its conduct, or its interpretation have introduced bias?	Unclear <i>(Knowledge of index test can introduce bias to the reference standard as it could affect the location the surgeon looks for lesions.)</i>
Reference standard: applicability	Is there concern that the target condition as defined by the reference standard does not match the review question?	Low
Flow and timing: risk of bias	Could the patient flow have introduced bias?	Low <i>(Surgery took place within 3 months of imaging.)</i>

2

3 **Bratila, 2016**

Bibliographic Reference Bratila, Elvira; Comandasu, Diana Elena; Coroleuca, Ciprian; Cirstoiu, Monica Mihaela; Berceanu, Costin; Mehedintu, Claudia; Bratila, Petre; Vladareanu, Simona; Diagnosis of endometriotic lesions by sonovaginography with ultrasound gel.; Medical ultrasonography; 2016; vol. 18 (no. 4); 469-474

1

2 **Study details**

Country/ies where study was carried out	Romania
Study type	Prospective cohort study
Study dates	January 2011 to May 2015
Inclusion criteria	<p>Patients of reproductive age with symptoms suggestive of endometriosis.</p> <p>Consent for transvaginal sonography (TVS) and sonovaginography (SVG) with gel, and laparoscopic surgery.</p> <p>Symptoms:</p> <ul style="list-style-type: none"> • chronic pelvic pain • infertility • dysmenorrhoea • dyspareunia • dyschezia
Exclusion criteria	<ul style="list-style-type: none"> • Malignant pathology. • Pregnancy,
Patient characteristics	<p>N=193 symptomatic participants</p> <p><u>Age, mean (SD):</u></p>

	<p>32 (4.3)</p> <p><u>Symptoms, n (%):</u> Chronic pelvic pain: 183 (94.8) Dysmenorrhoea: 193 (100) Dyspareunia: 147 (76.1) Dyschezia: 48 (24.8) Infertility: 120 (62.1)</p> <p>Ethnicity not reported</p> <p>Hospital setting - tertiary or secondary centre not reported</p>
Index test(s)	<p><u>TVS and SVG with gel</u></p> <p>TVS and SVG with gel were performed successively by two sonographers with experience in endometriosis diagnosis.</p> <p>Sonographic changes suggestive of endometriosis included:</p> <ul style="list-style-type: none"> • hypoechoic linear thickening • asymmetry of the uterosacral ligaments and nodules • hypoechoic tumour masses with regular or irregular contour <p>Ovarian endometriomas were diagnosed through the presence of single or multiple cystic formations, with a homogenous and hypoechoic content.</p> <p>Vagina involvement was identified in the presence of thickenings and/or cystic or non-cystic nodular lesions with hypoechoic aspect in the posterior vaginal wall.</p>
Reference standard(s)	<p><u>Laparoscopy with histology</u></p> <p>During laparoscopy the surgeon evaluated all the areas investigated by sonography. Lesions were excised and examined by histology.</p>
Duration of follow-up	Not reported

Sources of funding	Not reported
Target condition	Deep and superficial endometriosis
Results	<p>Site: Ovaries 90/204 TVS: TP 85; FP 5; FN 5; TN 109 SVG with gel: TP 86; FP 3; FN 4; TN 111</p> <p>Site: Urinary bladder 18/204 TVS: TP 12; FP 3; FN 6; TN 183 SVG with gel: TP 12; FP 6; FN 6; TN 180</p> <p>Site: Uterosacral ligaments 10/204 TVS: TP 7; FP 10; FN 3; TN 184 SVG with gel: TP 8; FP 8; FN 2; TN 186</p> <p>Site: Vagina 12/204 TVS: TP 7; FP 2; FN 5; TN 190 SVG with gel: TP 9; FP 2; FN 3; TN 190</p> <p>Site: Rectovaginal septum 12/204 TVS: TP 8; FP 1; FN 4; TN 191 SVG with gel: TP 11; FP 6; FN 1; TN 186</p> <p>Site: Pouch of Douglas 48/204 TVS: TP 39; FP 12 FN 9; TN 154 SVG with gel: TP 39; FP 3; FN 9; TN 153</p> <p>Site: Recto-sigmoid 14/204 TVS: TP 13; FP 6; FN 1; TN 184 SVG with gel: TP 13; FP 9; FN 1; TN 181</p>

1 **Critical appraisal - NGA Critical appraisal - QUADAS-2**

Section	Question	Answer
---------	----------	--------

Section	Question	Answer
Patient selection: risk of bias	Could the selection of patients have introduced bias?	Low <i>(Participants were consecutively enrolled and inappropriate exclusions were avoided.)</i>
Patient selection: applicability	Are there concerns that included patients do not match the review question?	Low
Index tests: risk of bias	Could the conduct or interpretation of the index test have introduced bias?	Low <i>(Index test was performed before the reference standard so results were unknown.)</i>
Index tests: applicability	Are there concerns that the index test, its conduct, or interpretation differ from the review question?	Low
Reference standard: risk of bias	Could the reference standard, its conduct, or its interpretation have introduced bias?	Unclear <i>(Knowledge of index test results can introduce bias to the reference standard as it could affect the location the surgeon looks for lesions.)</i>
Reference standard: applicability	Is there concern that the target condition as defined by the reference standard does not match the review question?	Low
Flow and timing: risk of bias	Could the patient flow have introduced bias?	Unclear <i>(The time between tests is unclear.)</i>

1

2 **Chen, 2019****Bibliographic Reference**

Chen, Ying-Han; Wang, Dan-Bo; Guo, Cui-Shan; Accuracy of Physical Examination, Transvaginal Sonography, Magnetic Resonance Imaging, and Rectal Endoscopic Sonography for Preoperative Evaluation of Rectovaginal Endometriosis.; *Ultrasound quarterly*; 2019; vol. 35 (no. 1); 54-60

3

1 Study details

Country/ies where study was carried out	China
Study type	Retrospective cohort study
Study dates	March 2010 and May 2017
Inclusion criteria	<ul style="list-style-type: none"> • Clinical suspicion or clinical evidence of rectovaginal endometriosis (RVE) based on symptoms • symptoms include: deep dyspareunia, chronic pelvic pain, dyschezia, rectal bleeding.
Exclusion criteria	None specified
Patient characteristics	<p>N=29 symptomatic participants</p> <p><u>Age, mean (range)</u> 38 (29 to 53)</p> <p><u>Symptoms, n (%)</u> Infertility: 5 (17.2) Dysmenorrhea: 26 (89.7) Deep dyspareunia: 10 (34.5) Painful defecation: 7 (24.1) Rectorrhagia: 3 (10.3) Diarrhoea and/or constipation: 11 (37.9)</p> <p>Tertiary centre</p>
Index test(s)	<p><u>Transvaginal sonography (TVS)</u></p> <ul style="list-style-type: none"> • Performed by physicians or ultrasound technologists with at least 10 years experience in gynaecological imaging. • Thickening or the presence of an irregular hypoechoic cystic or noncystic mass within the retrocervical area or the rectovaginal septum was considered positive for rectovaginal endometriosis.

	<p><u>Magnetic Resonance Imaging (MRI)</u></p> <ul style="list-style-type: none"> • 3.0 T whole body MRI device. • Rectovaginal endometriosis was defined by the identification of irregular thickness or a spiculated nodule in the rectovaginal septum, with a hypointense signal on T1- and T2-weighted images. <p><u>Rectal endoscopic sonography (RES)</u></p> <ul style="list-style-type: none"> • Performed by physicians experienced in endoscopic sonography for diseases of female low genital tract. • Rectal muscularis invasion was identified by the appearance of a hypoechoogenic nodular formation with a blurred border and a diffuse muscular thickening. • Submucosal/mucosal involvement was characterized by discontinuity of the hyperechoogenic line.
Reference standard(s)	<p><u>Laparoscopy with histology</u></p> <ul style="list-style-type: none"> • Surgeries were performed by a gynaecological and colorectal surgeons with experience in pelvic cavity operation. • Histological diagnosis was made by pathologist experienced in identifying endometriosis who were blinded to imaging results.
Duration of follow-up	Not reported
Sources of funding	Not reported
Target condition	Rectovaginal deep endometriosis
Results	<p>Prevalence: 21/29</p> <p>TVS: TP 9; FP 1; FN 12; TN 7 MRI: TP 19; FP 1; FN 2; TN 7 RES: TP 17; FP 2; FN 4; TN 6</p> <p>*Rectal endoscopic sonography is also known as transrectal ultrasonography</p>

1 **Critical appraisal - NGA Critical appraisal - QUADAS-2**

Section	Question	Answer
Patient selection: risk of bias	Could the selection of patients have introduced bias?	Low <i>(Participants were enrolled consecutively and inappropriate exclusions were avoided.)</i>
Patient selection: applicability	Are there concerns that included patients do not match the review question?	Low
Index tests: risk of bias	Could the conduct or interpretation of the index test have introduced bias?	Low <i>(Reference standard was performed after the index test and thresholds were prespecified.)</i>
Index tests: applicability	Are there concerns that the index test, its conduct, or interpretation differ from the review question?	Low
Reference standard: risk of bias	Could the reference standard, its conduct, or its interpretation have introduced bias?	Low <i>(Pathologists were blinded to the imaging results.)</i>
Reference standard: applicability	Is there concern that the target condition as defined by the reference standard does not match the review question?	Low
Flow and timing: risk of bias	Could the patient flow have introduced bias?	Unclear <i>(Time interval between tests is unclear.)</i>

2

3 **Di Giovanni, 2022****Bibliographic Reference**

Di Giovanni, Alessandra; Montanari, Eliana; Hudelist, Gernot; Malzoni, Mario; Keckstein, Joerg; Comparison Between Sonography-Based and Surgical Evaluation of Endometriotic Lesions Using the #Enzian Classification - A Retrospective Data Analysis.; *Ultraschall in der Medizin* (Stuttgart, Germany : 1980); 2022

4

5 Study details

Country/ies where study was carried out	Italy
Study type	Retrospective cohort study
Study dates	January 1 2019 to December 31 2019
Inclusion criteria	<ul style="list-style-type: none"> • Women aged 18 or older • Those who had a transvaginal sonography (TVS) 3 months before surgery for deep endometriosis
Exclusion criteria	<ul style="list-style-type: none"> • Diagnosed or suspected malignancy • previous colorectal surgery • previous surgery for deep endometriosis included vaginal resection, full thickness bowel resection, or excision of deep endometriosis lesions.
Patient characteristics	<p>N=93 symptomatic participants</p> <p><u>Age, mean (SD)</u> 37.3 (6.6)</p> <p><u>Preoperative symptoms %:</u> Dysmenorrhea: 95 Dyspareunia: 96 Dyschezia: 88 Dysuria: 32 Infertility: 43 Constipation: 75 Diarrhoea: 33 Rectal bleeding: 5</p> <p>Ethnicity not reported</p> <p>Tertiary centre</p>

Index test(s)	<p><u>Transvaginal sonography</u></p> <ul style="list-style-type: none"> • Carried out by a gynecologist with experience in endometriosis • Enzian compartment categorisation was used.
Reference standard(s)	<p><u>Surgery with histology</u></p> <ul style="list-style-type: none"> • Performed by a pelvic surgeon and gynaecological surgeons with experience in minimally invasive surgery. • The surgeons were not blinded to the TVS examination.
Duration of follow-up	Not reported
Sources of funding	Not reported
Target condition	Deep endometriosis
Results	<p>Site: urinary bladder 7/93 TP 6; FP 0; FN 1; TN 86</p> <p>Site: vagina (retrocervical area) 72/93 TP 70; FP 6; FN 2; TN 15</p> <p>Site: Left uterosacral ligaments 70/93 TP 68; FP 7; FN 2; TN 16</p> <p>Site: Right uterosacral ligaments 71/93 TP 71; FP 2; FN 0; TN 20</p> <p>Site: left ovary 39/93 TP 39; FP 2; FN 0; TN 52</p> <p>Site: right ovary 31/93</p>

	TP 31; FP 0; FN 0; TN 62
	Site: ureters 13/93 TP: 10; FP 4; FN 3; TN 76

1 **Critical appraisal - NGA Critical appraisal - QUADAS-2**

Section	Question	Answer
Patient selection: risk of bias	Could the selection of patients have introduced bias?	Low <i>(Unclear if consecutive or random sample, however all women fitting inclusion criteria in a given time period included, and no inappropriate exclusions.)</i>
Patient selection: applicability	Are there concerns that included patients do not match the review question?	Low
Index tests: risk of bias	Could the conduct or interpretation of the index test have introduced bias?	Low <i>(Index test was performed before the reference standard and the threshold was pre-specified.)</i>
Index tests: applicability	Are there concerns that the index test, its conduct, or interpretation differ from the review question?	Low
Reference standard: risk of bias	Could the reference standard, its conduct, or its interpretation have introduced bias?	Unclear <i>(Knowledge of index test results can introduce bias to the reference standard as it could affect the location the surgeon looks for lesions.)</i>
Reference standard: applicability	Is there concern that the target condition as defined by the reference standard does not match the review question?	Low
Flow and timing: risk of bias	Could the patient flow have introduced bias?	Low <i>(Surgery had to take place within 3 months of the imaging scan.)</i>

2

1 El-Maadawy, 2021

Bibliographic Reference

El-Maadawy, S.M.; Alaaeldin, N.; Nagy, C.B.; Role of preoperative ultrasound mapping in the surgical management of deep infiltrating endometriosis: a prospective observational study; Egyptian Journal of Radiology and Nuclear Medicine; 2021; vol. 52 (no. 1); 159

2

3 Study details

Country/ies where study was carried out	Egypt
Study type	Prospective cohort study
Study dates	October 2018 to December 2020
Inclusion criteria	<ul style="list-style-type: none"> • Premenopausal women with suspected deep infiltrating endometriosis (DIE) • willing to undergo transvaginal sonography (TVS) or transrectal sonography (TRS) for virgins followed by laparoscopy.
Exclusion criteria	<ul style="list-style-type: none"> • Patients who refused TVS or TRS • those who performed ultrasound at an outside facility or did only MRI • patients not eligible for surgery, or refused surgery, or did not provide informed consent.
Patient characteristics	<p>N=101 symptomatic participants</p> <p><u>Age, years – mean (SD)</u> 37.1 (6.2)</p> <p><u>Symptoms, number (%)</u> Dysmenorrhea: 100 (101) Dyschezia: 39 (38.6) Dysuria/frequency: 12 (11.9) Infertility: 22 (21.8)</p>

	<p>Incomplete rectal emptying: 19 (18.8) Constipation: 69 (68.3) Diarrhoea: 9 (8.9)</p> <p>Ethnicity not reported</p> <p>Tertiary or secondary centre not reported.</p>
Index test(s)	<p><u>Ultrasound</u></p> <ul style="list-style-type: none"> • All ultrasounds were transvaginal apart from 4 which were transrectal. • Performed by 2 radiologists with experience in the field in particular TVS assessment of DIE. • Ovaries evaluated for endometriomas with low-grade echoes of 'ground glass' appearance. • Sliding sign is used to detect pouch of Douglas obliteration. • Involvement of rectal wall appears as hypoechoic thickening of the bowel wall.
Reference standard(s)	<p><u>Laparoscopy with histology</u></p> <ul style="list-style-type: none"> • Performed 4 weeks after ultrasound • Performed by the same surgeon who had specific training in managing difficult deep endometriosis cases by laparoscopy. • Some cases carried out in collaboration with a colorectal surgeon and urologist. • Following surgery all specimens were sent to the same laboratory for histopathological confirmation.
Duration of follow-up	Not reported
Sources of funding	Not industry funded
Target condition	Deep endometriosis
Results	<p>Site: Rectovaginal septum (prevalence 19.8%) TP 14; FP 1; FN 6; TN 80</p> <p>Site: Vaginal (prevalence 12.9%)</p>

	TP 7; FP 1; FN 6; TN 87
	Site: Right uterosacral ligament (prevalence 42.6%) TP 36; FP 1; FN 7; TN 57
	Site: Left uterosacral ligament (prevalence 40.6%) TP 33; FP 3; FN 8; TN 57
	Site: Bladder (prevalence 3%) TP 3; FP 0; FN 0; TN 98
	Site: right ureter (prevalence 5%) TP 3; FP 1; FN 2; TN 95
	Site: left ureter (prevalence 4%) TP 2; FP 1; FN 2; TN 96

1 Critical appraisal – NGA Critical appraisal – QUADAS-2

Section	Question	Answer
Patient selection: risk of bias	Could the selection of patients have introduced bias?	Low <i>(Enrolment was consecutive and inappropriate exclusions were avoided)</i>
Patient selection: applicability	Are there concerns that included patients do not match the review question?	Low
Index tests: risk of bias	Could the conduct or interpretation of the index test have introduced bias?	Low <i>(Reference standard was performed 4 weeks after ultrasound and threshold was prespecified)</i>
Index tests: applicability	Are there concerns that the index test, its conduct, or interpretation differ from the review question?	Low
Reference standard:	Could the reference standard, its conduct, or its	Unclear <i>(Knowledge of index test results can introduce bias to the</i>

Section	Question	Answer
risk of bias	interpretation have introduced bias?	<i>reference standard as it could affect the location the surgeon looks for lesions.)</i>
Reference standard: applicability	Is there concern that the target condition as defined by the reference standard does not match the review question?	Low
Flow and timing: risk of bias	Could the patient flow have introduced bias?	Low

1

2 **Ferrero, 2017**

Bibliographic Reference

Ferrero, S; Biscaldi, E; Vellone, V G; Venturini, P L; Leone Roberti Maggiore, U; Computed tomographic colonography vs rectal water- contrast transvaginal sonography in diagnosis of rectosigmoid endometriosis: a pilot study.; *Ultrasound in obstetrics & gynecology : the official journal of the International Society of Ultrasound in Obstetrics and Gynecology*; 2017; vol. 49 (no. 4); 515-523

3

4 **Study details**

Country/ies where study was carried out	Italy
Study type	Prospective cohort study
Study dates	October 2013 and August 2015
Inclusion criteria	<ul style="list-style-type: none"> • Patients of reproductive age • scheduled for laparoscopy with suspicion of intestinal endometriosis based on symptoms and clinical examination.

Exclusion criteria	<ul style="list-style-type: none"> • Previous surgical or radiological diagnosis of intestinal endometriosis • previous bilateral ovariectomy • contraindications to bowel preparation or computed tomographic colonography • psychiatric disorder.
Patient characteristics	<p>N=70 symptomatic participants</p> <p><u>Age, years – mean (SD):</u> 35.7 (5.1)</p> <p><u>Symptoms, n (%):</u> Dysmenorrhea: 64 (91.4) Non-menstrual pelvic pain: 55 (78.6) Dyspareunia: 52 (74.3) Dyschezia: 44 (62.9) Persistent constipation: 25 (35.7) Constipation during menstruation: 14 (20.0) Diarrhea: 20 (28.6) Diarrhea during menstruation: 22 (31.4) Intestinal cramping: 40 (57.1) Abdominal bloating: 43 (61.4) Feeling of incomplete evacuation: 23 (32.9) Passage of mucus: 27 (38.6) Cyclical rectal bleeding: 11 (15.7)</p> <p>Hospital setting. Tertiary or secondary centre not reported.</p>
Index test(s)	<p><u>Transvaginal sonography (TVS)</u></p> <ul style="list-style-type: none"> • Performed by a sonographer with experience in diagnosis of intestinal endometriosis. • Rectal water-contrast transvaginal sonography (RWC-TVS) performed. • Rectosigmoid endometriotic nodules appear on TVS as a thickening of the hypoechoic muscularis propria or as hypoechoic nodules with or without hyperechoic foci with blurred margins.

Reference standard(s)	<p><u>Surgery and histological evaluation</u></p> <ul style="list-style-type: none"> • Imaging reports were evaluated before laparoscopy but diagnosis based on laparoscopic findings. • The same pathologist examined all specimens excised at surgery.
Duration of follow-up	Not reported
Sources of funding	Not reported
Target condition	Rectosigmoid endometriosis
Results	Site: rectosigmoid endometriosis (prevalence: 40/70) TP 37; FP 1; FN 3; TN 29

1 Critical appraisal – NGA Critical appraisal – QUADAS-2

Section	Question	Answer
Patient selection: risk of bias	Could the selection of patients have introduced bias?	Low <i>(Method of enrolment not reported but inclusion criteria specified and no inappropriate exclusions.)</i>
Patient selection: applicability	Are there concerns that included patients do not match the review question?	Low
Index tests: risk of bias	Could the conduct or interpretation of the index test have introduced bias?	Low <i>(Reference test was performed after the index test and the threshold was prespecified.)</i>
Index tests: applicability	Are there concerns that the index test, its conduct, or interpretation differ from the review question?	Low
Reference standard: risk of bias	Could the reference standard, its conduct, or its interpretation have introduced bias?	Unclear <i>(Knowledge of index test results can introduce bias to the reference standard as it could affect the location the surgeon looks for lesions.)</i>

Section	Question	Answer
Reference standard: applicability	Is there concern that the target condition as defined by the reference standard does not match the review question?	Low
Flow and timing: risk of bias	Could the patient flow have introduced bias?	Unclear (Time between index and reference standard not reported.)

1

2 **Ferrero, 2019****Bibliographic Reference**

Ferrero, S; Scala, C; Stabilini, C; Vellone, V G; Barra, F; Leone Roberti Maggiore, U; Transvaginal sonography with vs without bowel preparation in diagnosis of rectosigmoid endometriosis: prospective study.; *Ultrasound in obstetrics & gynecology : the official journal of the International Society of Ultrasound in Obstetrics and Gynecology*; 2019; vol. 53 (no. 3); 402-409

3

4 **Study details**

Country/ies where study was carried out	Italy
Study type	Prospective cohort study
Study dates	October 2016 to April 2018
Inclusion criteria	<ul style="list-style-type: none"> Patients of reproductive age referred for the first time due to symptom of pelvic pain of more than 6 months duration, and/or suspicion of endometriosis.
Exclusion criteria	<ul style="list-style-type: none"> Previous diagnosis of colorectal endometriosis previous intestinal surgery (other than appendectomy) previous hysterectomy or bilateral ovariectomy intact hymen

	<ul style="list-style-type: none"> those who transvaginal ultrasound could not be performed.
Patient characteristics	<p>N=262 symptomatic participants</p> <p><u>Age, years – mean (SD)</u> With rectosigmoid endometriosis: 33.0 (4.9) Without rectosigmoid endometriosis: 32.1 (4.3)</p> <p><u>Symptoms</u> <u>With rectosigmoid endometriosis, number (%)</u> Prevalence of dysmenorrhea: 75 (92.6) Prevalence of deep dyspareunia: 88 (74.6) Prevalence of non-menstrual pelvic pain: 92 (78.0) Dyschezia: 67 (56.8) Constipation: 43 (36.4) Diarrhea: 33 (28.0) Intestinal cramping: 68 (57.6) Abdominal bloating: 74 (62.7) Feeling of incomplete evacuation: 42 (35.6) Passage of mucus: 38 (32.2) Rectal bleeding: 17 (14.4)</p> <p><u>Without rectosigmoid endometriosis, number (%)</u> Prevalence of dysmenorrhea: 106 (93.0) Prevalence of deep dyspareunia: 104 (72.2) Prevalence of non-menstrual pelvic pain: 110 (76.4) Dyschezia: 70 (48.6) Constipation: 34 (23.6) Diarrhea: 32 (22.2) Intestinal cramping: 77 (53.5) Abdominal bloating: 83 (57.6) Feeling of incomplete evacuation: 20 (13.9) Passage of mucus: 23 (16.0) Rectal bleeding: 6 (4.2)</p>

	Tertiary or secondary centre not reported.
Index test(s)	<p><u>Transvaginal sonography (TVS) with or without bowel preparation</u></p> <ul style="list-style-type: none"> • Participants underwent a TVS without bowel prep and 1 to 3 months later TVS with bowel prep. • Laparoscopy was performed within 6 months of second TVS. • Examinations performed by 2 gynaecologists with experience in sonographic diagnosis of endometriosis. • The presence of rectosigmoid endometriosis was defined as endometriotic lesions reaching at least the intestinal muscularis propria • Rectosigmoid nodules categorised as a thickening of the hypoechoic muscularis propria or as hypoechoic nodules, with or without hyperechoic foci with blurred margins. • Location of nodules was classified according to IDEA groups.
Reference standard(s)	<p><u>Laparoscopy with histology</u></p> <ul style="list-style-type: none"> • Surgery performed by experience laparoscopic surgeon. • Colorectal surgeon participated when bowel surgery was required. • Surgeons were aware of imaging findings. • Nodules were excised and sent for evaluation in the pathology laboratory.
Duration of follow-up	Not reported
Sources of funding	Not reported
Target condition	Rectosigmoid endometriosis
Results	<p>N=262 Prevalence: 118/262</p> <p>Site: rectosigmoid</p> <p>TVS without bowel preparation: TP 104; FP 6; TN 138; FN 14</p>

*Only results for without bowel preparation are reported.

1 Critical appraisal – NGA Critical appraisal – QUADAS-2

Section	Question	Answer
Patient selection: risk of bias	Could the selection of patients have introduced bias?	Low <i>(Participants were enrolled consecutively and the study avoided inappropriate exclusions)</i>
Patient selection: applicability	Are there concerns that included patients do not match the review question?	Low
Index tests: risk of bias	Could the conduct or interpretation of the index test have introduced bias?	Low <i>(Index test was performed before the reference standard and threshold described)</i>
Index tests: applicability	Are there concerns that the index test, its conduct, or interpretation differ from the review question?	Low
Reference standard: risk of bias	Could the reference standard, its conduct, or its interpretation have introduced bias?	Unclear <i>(Knowledge of index test results can introduce bias to the reference standard as it could affect the location the surgeon looks for lesions.)</i>
Reference standard: applicability	Is there concern that the target condition as defined by the reference standard does not match the review question?	Low
Flow and timing: risk of bias	Could the patient flow have introduced bias?	Low

2

3 Goncalves, 2021

Bibliographic Reference Goncalves, Manoel Orlando; Siufi Neto, Joao; Andres, Marina Paula; Siufi, Daniela; de Mattos, Leandro Accardo; Abrao, Mauricio S; Systematic evaluation of endometriosis by transvaginal ultrasound can accurately replace diagnostic laparoscopy,

mainly for deep and ovarian endometriosis.; Human reproduction (Oxford, England); 2021; vol. 36 (no. 6); 1492-1500

1

2 **Study details**

Country/ies where study was carried out	Brazil
Study type	Prospective cohort study
Study dates	March 2017 to September 2019
Inclusion criteria	Indication for laparoscopy due to: <ul style="list-style-type: none"> • dysmenorrhea • deep dyspareunia • acyclic pelvic pain • cyclic dychezia • cyclic dysuria • infertility
Exclusion criteria	<ul style="list-style-type: none"> • Menopausal participants • participants with no previous sexual activity • those who had previous pelvic surgery • pregnancy • pelvic or abdominal cancers.
Patient characteristics	<p>N=120 symptomatic participants</p> <p><u>Age, years – mean (SD):</u> With endometriosis: 33.6 (13.8) Without endometriosis: 45.3 (0.3)</p> <p><u>Site of endometriosis, number (%):</u></p>

	<p>Ovarian: 19 (15.8) Deep endometriosis: 94 (79.1) Retrocervical: 83 (87.4) Rectosigmoid: 53 (55.8) Bladder: 4 (4.2)</p> <p>Tertiary or secondary centre not reported.</p>
Index test(s)	<p><u>Transvaginal ultrasound (TVUS)</u></p> <ul style="list-style-type: none"> Performed by experienced radiologists with more than 10 years experience with TVUS with bowel prep (TVUS-BP). Mapping and staging according to American Society for Reproductive Medicine (ASRM) classification. Deep peritoneal lesions were hypoechoic irregular nodules or thickness in the pelvic with our without retractions to adjacent structures. Ovarian endometriosis characterised by presence of homogenous cyst with low hypoechoic points. <p><u>Laparoscopy</u></p> <ul style="list-style-type: none"> Indicated in cases of refusal of medical treatment, contraindication or failure of hormonal treatment. All were performed by the same surgeon who had 30 years of experience in endometriosis surgery.
Reference standard(s)	<p><u>Histology following laparoscopy</u></p> <p>No further details provided</p>
Duration of follow-up	Not reported
Sources of funding	Not industry funded
Target condition	Deep endometriosis
Results	<p>Site: Pouch of Douglas obliteration (prevalence 56/120) TP 47; FP 7; FN 9; TN 57;</p> <p>Site: Ovarian (prevalence 19/120)</p>

	TP 18; FP 5; FN 1; TN 96;
	Site: Rectosigmoid (prevalence 53/120) TP 51; FP 1; FN 2; TN 66;
	Site: Bladder (prevalence 4/120) TP 3; FP 1; FN 1; TN 115;

1 Critical appraisal – NGA Critical appraisal – QUADAS-2

Section	Question	Answer
Patient selection: risk of bias	Could the selection of patients have introduced bias?	Low <i>(Participants were enrolled consecutively and inappropriate exclusions were avoided)</i>
Patient selection: applicability	Are there concerns that included patients do not match the review question?	Low
Index tests: risk of bias	Could the conduct or interpretation of the index test have introduced bias?	Low <i>(Reference standard was performed after the index test and the threshold was pre-specified.)</i>
Index tests: applicability	Are there concerns that the index test, its conduct, or interpretation differ from the review question?	Low
Reference standard: risk of bias	Could the reference standard, its conduct, or its interpretation have introduced bias?	Unclear <i>(Knowledge of index test results can introduce bias to the reference standard as it could affect the location the surgeon looks for lesions.)</i>
Reference standard: applicability	Is there concern that the target condition as defined by the reference standard does not match the review question?	Low
Flow and timing: risk of bias	Could the patient flow have introduced bias?	Unclear <i>(Time between tests is unclear)</i>

1

2 **Gratton, 2022****Bibliographic Reference**

Gratton, Sara-Michelle; Choudhry, Abdul Jamil; Vilos, George A; Vilos, Angelos; Baier, Kristina; Holubeshen, Simonne; Medor, Maria Cassandra; Mercier, Stephanie; Nguyen, Vincent; Chen, Innie; Diagnosis of Endometriosis at Laparoscopy: A Validation Study Comparing Surgeon Visualization with Histologic Findings.; Journal of obstetrics and gynaecology Canada : JOGC = Journal d'obstetrique et gynecologie du Canada : JOGC; 2022; vol. 44 (no. 2); 135-141

3

4 **Study details**

Country/ies where study was carried out	Canada
Study type	Retrospective cohort study
Study dates	April 2016 to March 2017
Inclusion criteria	<ul style="list-style-type: none"> Had a laparoscopy for suspected endometriosis and a biopsy for histopathological diagnosis.
Exclusion criteria	Not specified
Patient characteristics	<p>N=96 symptomatic participants</p> <p><u>Age, years – mean (SD)</u> 40 (7.2)</p> <p><u>Symptoms, number (%)</u> Abdominal and pelvic pain: 40 (41.7) Pelvic and perineal pain: 30 (31.3) Dysmenorrhea: 28 (29.2) Dyspareunia: 8 (8.3) Dyschezia: 3 (3.1) Female infertility: 8 (8.3)</p>

	Heavy or irregular menstrual bleeding: 39 (40.6)
	Tertiary centre
Index test(s)	<u>Laparoscopy</u> <ul style="list-style-type: none"> • Surgeon performed. • American Society for Reproductive Medicine classification system followed.
Reference standard(s)	<u>Histopathology following laparoscopy</u> <ul style="list-style-type: none"> • Diagnosis of endometriosis made when at least 2 of the following were present: endometrial type stroma, endometrial type glands, or chronic haemorrhage in the form of hemosiderin deposition.
Duration of follow-up	Not reported
Sources of funding	Not reported
Target condition	Deep and superficial endometriosis
Results	Sites: multiple sites, deep and superficial including endometrioma, posterior vaginal fornix, rectovaginal septum, uterosacral ligaments, rectum, bladder TP 64; FP 15; FN 7; TN 10

1 Critical appraisal – NGA Critical appraisal – QUADAS-2

Section	Question	Answer
Patient selection: risk of bias	Could the selection of patients have introduced bias?	Low (Consecutive recruitment. Exclusion criteria not reported but study reports only those with ineligible procedures or no histopathology report were excluded.)
Patient selection:	Are there concerns that included patients do not	Low

Section	Question	Answer
applicability	match the review question?	
Index tests: risk of bias	Could the conduct or interpretation of the index test have introduced bias?	Low <i>(Not reported whether index test was performed without knowledge of reference standard but it is unlikely as the reference standard would have taken place after. Threshold was prespecified.)</i>
Index tests: applicability	Are there concerns that the index test, its conduct, or interpretation differ from the review question?	Low
Reference standard: risk of bias	Could the reference standard, its conduct, or its interpretation have introduced bias?	Unclear <i>(Knowledge of index test results can introduce bias to the reference standard as it could affect the location the surgeon looks for lesions.)</i>
Reference standard: applicability	Is there concern that the target condition as defined by the reference standard does not match the review question?	Low
Flow and timing: risk of bias	Could the patient flow have introduced bias?	Low <i>(Tests performed at the same time.)</i>

1

2 **Harth, 2023****Bibliographic Reference**

Harth, Sebastian; Roller, Fritz C; Zeppernick, Felix; Meinhold-Heerlein, Ivo; Krombach, Gabriele A; Deep Infiltrating Endometriosis: Diagnostic Accuracy of Preoperative Magnetic Resonance Imaging with Respect to Morphological Criteria.; Diagnostics (Basel, Switzerland); 2023; vol. 13 (no. 10)

3

4 **Study details**

Country/ies where	Germany
--------------------------	---------

study was carried out	
Study type	Retrospective cohort study
Study dates	October 2018 to December 2020
Inclusion criteria	<ul style="list-style-type: none"> Participants who had undergone MRI for evaluation of pelvic endometriosis after clinical examination and transvaginal ultrasound had a laparoscopy within 12 months of the MRI.
Exclusion criteria	<ul style="list-style-type: none"> If the surgery report did not have Enzian score.
Patient characteristics	<p>N=160 symptomatic participants</p> <p><u>Age, years – mean (SD)</u> 33 (7.2)</p> <p><u>Clinical symptoms, n/N (%)</u> Chronic pelvic pain: 138/160 (86) Dysmenorrhea: 87/160 (54) Dyspareunia: 47/160 (29) Infertility: 38/160 (24) Constipation/diarrhoea: 11/160 (7) Dyschezia: 28/160 (18) Dysuria: 20/160 (13) Abnormal uterine bleeding: 19/160 (12)</p> <p>Tertiary centre.</p>
Index test(s)	<p><u>MRI</u></p> <ul style="list-style-type: none"> Images were reviewed by a radiologist with 7 years experience in pelvic MRI (blind to results of surgery and histopathology) Enzian criteria used.

Reference standard(s)	<p><u>Surgery with histopathology</u></p> <ul style="list-style-type: none"> Performed by experienced senior surgeon MRI results were available surgeons. Performed within 12 months of MRI.
Duration of follow-up	Not reported
Sources of funding	Not industry funded.
Target condition	Deep infiltrating endometriosis (DIE)
Results	<p>Sites: multiple sites including ovary, vagina, rectovaginal space, rectum</p> <p>MR-: 0; MR+:1–3 TP 47; FP 14; FN 23; TN 76</p> <p>MR-: 0-1; MR+: 2-3 TP 33; FP 6; FN 23; TN 98</p> <p>MR-: 0-2; MR+: 3 (strict criteria used for review analysis) TP 16; FP 0; FN 22; TN 122</p>

1 Critical appraisal – NGA Critical appraisal – QUADAS-2

Section	Question	Answer
Patient selection: risk of bias	Could the selection of patients have introduced bias?	Low (<i>Enrolment was consecutive and inappropriate exclusions were avoided.</i>)
Patient selection: applicability	Are there concerns that included patients do not match the review question?	Low

Section	Question	Answer
Index tests: risk of bias	Could the conduct or interpretation of the index test have introduced bias?	Low <i>(Radiologist interpreted the results blinded to the results of the reference standard.)</i>
Index tests: applicability	Are there concerns that the index test, its conduct, or interpretation differ from the review question?	Low
Reference standard: risk of bias	Could the reference standard, its conduct, or its interpretation have introduced bias?	Unclear <i>(Knowledge of index test results can introduce bias to the reference standard as it could affect the location the surgeon looks for lesions.)</i>
Reference standard: applicability	Is there concern that the target condition as defined by the reference standard does not match the review question?	Low
Flow and timing: risk of bias	Could the patient flow have introduced bias?	Low <i>(Tests were performed within 12 months of each other.)</i>

1

2 **Hausmann, 2021**

Bibliographic Reference

Hausmann, Daniel; Perignon, Vasiliki; Grabherr, Regula; Weiland, Elisabeth; Nickel, Marcel Dominik; Murer, Maurus; Bosshard, Lars; Prummer, Michael; Kubik-Huch, Rahel A; Can Dynamic Contrast-enhanced MRI Contribute to Improved Assessment of Rectosigmoid Involvement in Deep Infiltrating Endometriosis?.; In vivo (Athens, Greece); 2021; vol. 35 (no. 4); 2217-2226

3

4 **Study details**

Country/ies where study was carried out	Switzerland
--	-------------

Study type	Retrospective cohort study
Study dates	May 24 th 2018 to December 4 th 2019
Inclusion criteria	<ul style="list-style-type: none"> Those who had an MRI of the pelvis during May 2018 and December 2019 for endometriosis. Had undergone a surgical procedure after the MRI.
Exclusion criteria	Not specified
Patient characteristics	<p>N=43 participants (not specified if symptomatic)</p> <p><u>Age, years – mean (SD)</u> 35.9 (6.4)</p> <p><u>Tertiary or secondary centre not reported.</u></p>
Index test(s)	<p><u>MRI</u></p> <ul style="list-style-type: none"> Performed by 2 radiologists. One with 20 and the other 2 years of experience in female imaging. Unaware of the histology results. If 2 readers reached a different conclusion, then a 3rd reader with 10 years experience evaluated the images. T2-weighted BLADE (BLADE), and T2W-BLADe with prototypical contrast-enhanced, dynamic, compressed-sensing–accelerated volume-interpolated breath-hold examination (csVIBE) used (BLADE/csVIBE). Mushroom cap sign used to indicate the presence of extensive rectal infiltration.
Reference standard(s)	<p><u>Surgery with histopathology</u></p> <ul style="list-style-type: none"> Surgical procedure performed after MRI examination by February 2020 (possible there was a maximum 2 years between tests).
Duration of follow-up	Not reported

Sources of funding	Not reported
Target condition	Deep infiltrating endometriosis (DIE)
Results	Site: rectal N=43 MRI BLADE: TP 22; FP 5; FN 1; TN 15 MRI BLADE/csVIBE: TP 22; FP 3; FN 1; TN 17

1 **Critical appraisal – NGA Critical appraisal – QUADAS-2**

Section	Question	Answer
Patient selection: risk of bias	Could the selection of patients have introduced bias?	Low <i>(Method of enrolment not specified however participants meeting inclusion criteria in a given time period were enrolled and no inappropriate exclusions.)</i>
Patient selection: applicability	Are there concerns that included patients do not match the review question?	Low
Index tests: risk of bias	Could the conduct or interpretation of the index test have introduced bias?	Low <i>(Imaging were performed without the knowledge of histology results.)</i>
Index tests: applicability	Are there concerns that the index test, its conduct, or interpretation differ from the review question?	Low
Reference standard: risk of bias	Could the reference standard, its conduct, or its interpretation have introduced bias?	Unclear <i>(Knowledge of index test results can introduce bias to the reference standard as it could affect the location the surgeon looks for lesions.)</i>
Reference standard:	Is there concern that the target condition as defined by the reference standard does not match the review	Low

Section	Question	Answer
applicability	question?	
Flow and timing: risk of bias	Could the patient flow have introduced bias?	Low

1

2 **Hernandez Gutierrez, 2019**

Bibliographic Reference Hernandez Gutierrez, Alicia; Spagnolo, Emanuela; Hidalgo, Paula; Lopez, Ana; Zapardiel, Ignacio; Rodriguez, Roberto; Magnetic resonance imaging versus transvaginal ultrasound for complete survey of the pelvic compartments among patients with deep infiltrating endometriosis.; International journal of gynaecology and obstetrics: the official organ of the International Federation of Gynaecology and Obstetrics; 2019; vol. 146 (no. 3); 380-385

3

4 **Study details**

Country/ies where study was carried out	Spain
Study type	Retrospective cohort study
Study dates	April 2012 to December 2014
Inclusion criteria	<ul style="list-style-type: none"> • Clinical objectivity at gynaecologic examination • indication to undergo transvaginal ultrasound (TVU) and magnetic resonance imaging (MRI) and surgical treatment.
Exclusion criteria	<ul style="list-style-type: none"> • Previous hysterectomy • bowel resection • urinary tract surgery (partial cystectomy or ureter reimplantation).

Patient characteristics	<p>N=48 symptomatic participants <u>Mean age, years – mean (SD)</u> 34 (6)</p> <p><u>Symptoms, n (%)</u> Dysmenorrhea: 32 (67%) Chronic pelvic pain: 13 (27%) Dyspareunia: 35 (73%) Dysuria: 10 (21%)</p> <p>Tertiary or secondary centre not reported.</p>
Index test(s)	<p>TVU</p> <ul style="list-style-type: none"> • Performed by a gynaecologist who was an expert in gynaecological ultrasound. • Enzian classification used to report the localisation of DIE. • Endometriotic lesion was described when there was a regular or irregular nodular hypoechoic thickening. • Rectovaginal endometriosis was visible as a solid nodular hypoechoic thickening. <p>MRI</p> <ul style="list-style-type: none"> • Performed by a radiologist skilled in abdominal and pelvic radiology for endometriosis. • Blinded to TVU results. • Diagnosis of DIE based on a hypointense signal of nodules on a T2 weighted image, eventually hyperintense signal on fatty saturation T1 weighted image (typical of bladder and recto-sigmoid nodule).
Reference standard(s)	Laparoscopy with histology
Duration of follow-up	Not reported
Sources of funding	Not reported
Target condition	Deep endometriosis

Results	<p>N=48 (endometriosis confirmed in all 48, however prevalence by area not available therefore 2x2 table cannot be calculated)</p> <p>Site: Rectovaginal space</p> <p><u>TVU</u> Sensitivity: 65% Specificity: 88%</p> <p><u>MRI</u> Sensitivity: 74% Specificity: 64%</p> <p>Site: Vaginal</p> <p><u>TVU</u> Sensitivity: 67% Specificity: 96%</p> <p><u>MRI</u> Sensitivity: 33% Specificity: 93%</p> <p>Site: Utero-sacral ligaments</p> <p><u>TVU</u> Sensitivity: 59% Specificity: 43%</p> <p><u>MRI</u> Sensitivity: 67% Specificity: 43%</p> <p>Site: Rectosigmoid</p> <p><u>TVU</u> Sensitivity: 81% Specificity: 62%</p> <p><u>MRI</u> Sensitivity: 69% Specificity: 87%</p>
----------------	---

<p>Site: Bladder</p> <p><u>TVU</u> Sensitivity: 50% Specificity: 98%</p> <p><u>MRI</u> Sensitivity: 67% Specificity: 100%</p> <p>Site: Ureter</p> <p><u>TVU</u> Sensitivity: 50% Specificity: 95%</p> <p><u>MRI</u> Sensitivity: 33% Specificity: 98%</p>

1 Critical appraisal – NGA Critical appraisal – QUADAS-2

Section	Question	Answer
Patient selection: risk of bias	Could the selection of patients have introduced bias?	Low <i>(Participants meeting inclusion criteria in a given time period were included and there were no inappropriate exclusions.)</i>
Patient selection: applicability	Are there concerns that included patients do not match the review question?	Low
Index tests: risk of bias	Could the conduct or interpretation of the index test have introduced bias?	Low <i>(Index tests were performed before the reference standard.)</i>
Index tests: applicability	Are there concerns that the index test, its conduct, or interpretation differ from the review question?	Low
Reference standard: risk of bias	Could the reference standard, its conduct, or its interpretation have introduced bias?	Unclear <i>(Unclear if the reference standard results were interpreted without knowledge of the index test. Knowledge of index test results can introduce bias to the</i>

bias		<i>reference standard as it could affect the location the surgeon looks for lesions.)</i>
Reference standard: applicability	Is there concern that the target condition as defined by the reference standard does not match the review question?	Low
Flow and timing: risk of bias	Could the patient flow have introduced bias?	Low <i>(There was a maximum of 2 months between imaging and surgery.)</i>

1

2 **Jiang, 2017****Bibliographic Reference**

Jiang, Jipeng; Liu, Ying; Wang, Kun; Wu, Xixiang; Tang, Ying; Rectal water contrast transvaginal ultrasound versus double-contrast barium enema in the diagnosis of bowel endometriosis.; BMJ open; 2017; vol. 7 (no. 9); e017216

3

4 **Study details**

Country/ies where study was carried out	China
Study type	Prospective cohort study
Study dates	May 2021 to August 2016
Inclusion criteria	<ul style="list-style-type: none"> • Reproductive age • suspicious deep pelvic endometriosis • gastrointestinal symptoms • desire for complete surgical endometriosis excision.
Exclusion criteria	<ul style="list-style-type: none"> • Previous bilateral ovariectomy • radiological diagnosis of bowel endometriosis • examination of barium radiology • colorectal surgery,

	<ul style="list-style-type: none"> • hepatic or renal failure • intolerance for iodinated contrast medium • psychiatric disorders • refused double contrast barium enema.
Patient characteristics	<p>N=198 symptomatic participants</p> <p><u>Age, years – mean (SD)</u> 32.7 (4.9)</p> <p><u>Symptoms, n (%)</u> Dysmenorrhoea: 171 (86.4) Deep dyspareunia: 127 (64.1) Non-menstrual pelvic pain: 145 (73.2) Dyschezia: 93 (47) Diarrhoea-predominant IBS: 63 (31.8) Constipation-predominant IBS: 87 (43.9) Passage of mucus: 42 (21.2) Rectal bleeding: 19 (9.6) Intestinal cramping: 98 (49.5) Abdominal bloating: 119 (60.1)</p> <p>Ethnicity not reported</p> <p>Tertiary or secondary centre not reported.</p>
Index test(s)	<p><u>Rectal water contract transvaginal ultrasound (RWC-TVS)</u></p> <ul style="list-style-type: none"> • Performed by 2 physicians • Bowel endometriosis was shown as solid, hypoechoic, nodular lesions, adjacent to or penetrating the wall of the intestine.
Reference standard(s)	<p><u>Laparoscopy and histological assessment</u></p> <ul style="list-style-type: none"> • Surgeons examined the images from the RWC-TVS.

	<ul style="list-style-type: none"> Surgeons were colorectal and gynaecological surgeons with experience in bowel endometriosis and pelvic treatment. All visible lesions excised and assessed by histology.
Duration of follow-up	Not reported
Sources of funding	Not reported
Target condition	Deep bowel endometriosis
Results	Prevalence: 110/198 TP 97; FP 2; FN 13; TN 86

1 Critical appraisal – NGA Critical appraisal – QUADAS-2

Section	Question	Answer
Patient selection: risk of bias	Could the selection of patients have introduced bias?	Low <i>(Participants meeting inclusion criteria in a given time period included and no inappropriate exclusions.)</i>
Patient selection: applicability	Are there concerns that included patients do not match the review question?	Low
Index tests: risk of bias	Could the conduct or interpretation of the index test have introduced bias?	Low <i>(Index test was performed before the reference standard and a threshold was pre-specified.)</i>
Index tests: applicability	Are there concerns that the index test, its conduct, or interpretation differ from the review question?	Low
Reference standard: risk of bias	Could the reference standard, its conduct, or its interpretation have introduced bias?	Unclear <i>(Knowledge of index test results can introduce bias to the reference standard as it could affect the location the surgeon looks for lesions.)</i>

Section	Question	Answer
Reference standard: applicability	Is there concern that the target condition as defined by the reference standard does not match the review question?	Low
Flow and timing: risk of bias	Could the patient flow have introduced bias?	Low (Tests were performed 1 month apart.)

1

2 **Kamkarfar, 2022****Bibliographic Reference**

Kamkarfar, Pegah; Shahriyariipoor, Roya; Rokhgireh, Samaneh; Mostafavi, Seyed Reza Saadat; Chaichian, Shahla; Mehdizadeh Kashi, Abolfazl; Comparison of diagnostic values of transvaginal sonography with laparoscopic and histological results in the evaluation of uterosacral ligaments' involvement in endometriosis patients.; Caspian journal of internal medicine; 2022; vol. 13 (no. 4); 705-712

3

4 **Study details**

Country/ies where study was carried out	Iran
Study type	Prospective cohort study
Study dates	2019-2020
Inclusion criteria	<ul style="list-style-type: none"> Patients with clinical suspicion of endometriosis aged 18-49.
Exclusion criteria	<ul style="list-style-type: none"> Virginity, or any other condition where transvaginal ultrasound or laparoscopic surgery was not possible.

Patient characteristics	<p>N=80 symptomatic participants</p> <p><u>Age, mean (SD):</u> 34.47 (5.94)</p> <p><u>Symptoms, n (%)</u> Menstrual pain: 77 (96.2) Pelvic pain: 40 (50) Dyspareunia: 45 (56.2)</p> <p>Ethnicity not reported</p> <p>Tertiary or secondary centre not reported.</p>
Index test(s)	<p><u>Transvaginal ultrasound</u></p> <ul style="list-style-type: none"> • Radiologist with expertise in endometriosis diagnosis performed ultrasound • Diagnosis made on the following findings: nodular aggregations or the presence of irregular hypoechoic nodules, thickening of the wall, or retractable masses and hypoechoic points.
Reference standard(s)	<p><u>Laparoscopy and histology</u></p> <ul style="list-style-type: none"> • Left and right uterosacral ligaments (USLs) were examined laparoscopically and resection performed. • Samples sent to pathology. • In the absence of visible lesions, a biopsy of the USL was taken,
Duration of follow-up	Not reported
Sources of funding	No funding obtained
Target condition	Endometriosis
Results	<p>Threshold: thickness on ultrasound</p> <p>Site: Uterosacral ligaments (prevalence 61/80)</p>

	TP 57; FP 7; FN 4; TN 12
	Threshold: nodules on ultrasound (used for analysis) Site: uterosacral ligaments (65/80) TP 53; FP 0; FN 12; TN 15
	Endometrioma in ovaries (67/80) TP 67; FP 0; FN 0; TN 13

1 Critical appraisal – NGA Critical appraisal – QUADAS-2

Section	Question	Answer
Patient selection: risk of bias	Could the selection of patients have introduced bias?	Low <i>(Participants were randomly enrolled and inappropriate exclusions were avoided.)</i>
Patient selection: applicability	Are there concerns that included patients do not match the review question?	Low
Index tests: risk of bias	Could the conduct or interpretation of the index test have introduced bias?	Unclear <i>(Study suggests that the reference standard was performed after the index test but it is unclear.)</i>
Index tests: applicability	Are there concerns that the index test, its conduct, or interpretation differ from the review question?	Low
Reference standard: risk of bias	Could the reference standard, its conduct, or its interpretation have introduced bias?	Unclear <i>(Knowledge of index test results can introduce bias to the reference standard as it could affect the location the surgeon looks for lesions.)</i>
Reference standard: applicability	Is there concern that the target condition as defined by the reference standard does not match the review question?	Low
Flow and timing: risk	Could the patient flow have introduced bias?	Unclear <i>(Time between tests is unclear.)</i>

Section	Question	Answer
of bias		

1

2 **Montanari, 2022****Bibliographic Reference**

Montanari, E; Bokor, A; Szabo, G; Kondo, W; Trippia, C H; Malzoni, M; Di Giovanni, A; Tinneberg, H R; Oberstein, A; Rocha, R M; Leonardi, M; Condous, G; Alsalem, H; Keckstein, J; Hudelist, G; Accuracy of sonography for non-invasive detection of ovarian and deep endometriosis using #Enzian classification: prospective multicenter diagnostic accuracy study.; *Ultrasound in obstetrics & gynecology : the official journal of the International Society of Ultrasound in Obstetrics and Gynecology*; 2022; vol. 59 (no. 3); 385-391

3

4 **Study details**

Country/ies where study was carried out	Austria, Hungary, Brazil, Italy, German, Australia, Canada
Study type	Prospective cohort study
Study dates	January 2020 to May 2021
Inclusion criteria	Women aged 18 or older who had a preoperative sonographic evaluation with surgical treatment for deep endometriosis (DE).
Exclusion criteria	<ul style="list-style-type: none"> • Suspected or diagnosed malignancy • history of colorectal surgery • surgery for deep endometriosis including: vaginal resection, full-thickness bowel resection, or excision of DE in bladder.
Patient characteristics	N= 745 symptomatic participants <u>Age, mean (SD):</u>

	<p>35 (6)</p> <p><u>Preoperative symptoms, n (%):</u> Dysmenorrhea: 720 (97) Dyschezia: 406 (54) Dyspareunia: 437 (59) Infertility: 319 (43) Rectal bleeding: 47 (6) Constipation: 234 (31) Diarrhea: 183 (25)</p> <p>Tertiary centre.</p>
Index test(s)	<p><u>Transvaginal sonography with transabdominal sonography</u></p> <ul style="list-style-type: none"> • Scan was performed 3 months before surgery by a gynaecologist or a radiologist with extensive experience in gynaecologic sonography in particular endometriosis. • Enzian classification.
Reference standard(s)	<p><u>Surgery with histology</u></p> <ul style="list-style-type: none"> • Performed by gynaecological surgeons with extensive experience in minimally invasive surgery for DE. • The surgeons were not blinded to scan results, and results were used to plan surgery. • All women underwent resection of all visible endometriotic lesions followed by histology.
Duration of follow-up	Not reported
Sources of funding	Not reported
Target condition	Deep endometriosis
Results	<p>Site: Left ovary: Sensitivity 0.9 (0.86 to 0.94); Specificity 0.96 (0.94 to 0.98) Site: Right ovary:</p>

Sensitivity 0.89 (0.84 to 0.92); Specificity 0.98 (0.96 to 0.99)
 Site: Rectum (classified as rectosigmoid in review analysis)
 Sensitivity 0.93 (0.90 to 0.95); Specificity 0.95 (0.92 to 0.98)
 Site: Urinary bladder:
 Sensitivity 0.94 (0.87 to 0.98); Specificity 1 (0.99 to 1)
 Site: Ureters:
 Sensitivity: 0.78 (0.63 to 0.89); Specificity 1 (0.99 to 1)

1

2 **Critical appraisal – NGA Critical appraisal – QUADAS-2**

Section	Question	Answer
Patient selection: risk of bias	Could the selection of patients have introduced bias?	Low <i>(Participants were consecutively enrolled.)</i>
Patient selection: applicability	Are there concerns that included patients do not match the review question?	Low
Index tests: risk of bias	Could the conduct or interpretation of the index test have introduced bias?	Low <i>(Index test was performed before the reference standard.)</i>
Index tests: applicability	Are there concerns that the index test, its conduct, or interpretation differ from the review question?	Low
Reference standard: risk of bias	Could the reference standard, its conduct, or its interpretation have introduced bias?	Unclear <i>(Reference standard was performed with knowledge of the index test results. Knowledge of index test results can introduce bias to the reference standard as it could affect the location the surgeon looks for lesions.)</i>
Reference standard: applicability	Is there concern that the target condition as defined by the reference standard does not match the review question?	Low

Section	Question	Answer
Flow and timing: risk of bias	Could the patient flow have introduced bias?	Low (Surgery was performed within 3 months after index test.)

1

2 **Puri, 2022****Bibliographic Reference**

Puri, S.; Gupta, A.; Sandhu, G.S.; Mohi, J.K.; Comparison between Ultrasonography and Magnetic Resonance Imaging in Endometriosis: A Prospective Study in a Tertiary Hospital; Journal of SAFOG; 2022; vol. 14 (no. 2); 85-90

3

4 **Study details**

Country/ies where study was carried out	India
Study type	Prospective cohort study
Study dates	November 2018 to November 2020
Inclusion criteria	<ul style="list-style-type: none"> Patients with clinically suspected endometriosis referred to the radiology department.
Exclusion criteria	<ul style="list-style-type: none"> Those with contraindications for MRI
Patient characteristics	<p>N=40 participants (unclear if all symptomatic)</p> <p><u>Age, years – mean (SD)</u> 31.45 (4.44)</p> <p>Tertiary centre.</p>

Index test(s)	<p><u>Transabdominal ultrasound</u></p> <ul style="list-style-type: none"> • Endometriotic cysts detected by the presence of unilocular or multilocular cystic lesions filled with homogenous low-level internal echoes and no internal vascularity on colour Doppler flow. • Detected also by hypoechoic nodules. <p><u>Magnetic resonance imaging (MRI)</u></p> <ul style="list-style-type: none"> • Imaging sequences included T1 and T2 weighted images, and fat-saturated T1 weighting image. • Diagnosis made by the presence of hyperintense signal on T1 weighted and fat saturated T1, and by the presence of T2 shading.
Reference standard(s)	<p><u>Laparoscopy with histopathology</u></p> <ul style="list-style-type: none"> • Results of ultrasound and MRI were compared with histopathology after laparoscopic surgery was done in these patients
Duration of follow-up	Not reported
Sources of funding	Not reported
Target condition	Endometriosis
Results	<p>Ultrasound:</p> <p>Site: Ovaries (32/40) TP 29; FP 2; FN 3; TN 6 Site: uterosacral ligaments – deep (4/40) TP 1; FP 1; FN 3; TN 35</p> <p>MRI:</p> <p>Site: Ovaries (32/40)</p>

TP 30; FP 1; FN 2; TN 7
 Site: uterosacral ligaments – deep (4/40)
 TP 3; FP 0; FN 1; TN 36

1 Critical appraisal – NGA Critical appraisal – QUADAS-2

Section	Question	Answer
Patient selection: risk of bias	Could the selection of patients have introduced bias?	Unclear <i>(Method of enrolment unclear. Specific number of participants selected, not all participants in a given time period. Inappropriate exclusions avoided.)</i>
Patient selection: applicability	Are there concerns that included patients do not match the review question?	Low
Index tests: risk of bias	Could the conduct or interpretation of the index test have introduced bias?	Low <i>(Index test was performed before the reference standard with pre-specified threshold.)</i>
Index tests: applicability	Are there concerns that the index test, its conduct, or interpretation differ from the review question?	Low
Reference standard: risk of bias	Could the reference standard, its conduct, or its interpretation have introduced bias?	Unclear <i>(Knowledge of index test results can introduce bias to the reference standard as it could affect the location the surgeon looks for lesions.)</i>
Reference standard: applicability	Is there concern that the target condition as defined by the reference standard does not match the review question?	Low
Flow and timing: risk of bias	Could the patient flow have introduced bias?	Unclear <i>(Time between tests unclear.)</i>

2

3 Roditis, 2023

Bibliographic Reference Roditis, Alexis; Florin, Marie; Rousset, Pascal; Touboul, Cyril; Bendifallah, Sofiane; Bazot, Marc; Thomassin-Naggara, Isabelle; Accuracy of combined physical examination, transvaginal ultrasonography, and magnetic resonance imaging to diagnose deep endometriosis.; Fertility and sterility; 2023; vol. 119 (no. 4); 634-643

1

2 Study details

Country/ies where study was carried out	France
Study type	Retrospective cohort study
Study dates	January 1, 2016 and August 31, 2020.
Inclusion criteria	<ul style="list-style-type: none"> Women who underwent physical examination (PE), transvaginal ultrasound (TVUS), and pelvic magnetic resonance imaging (MRI) for deep infiltrating endometriosis (DIE) up to 12 months before surgery between the study dates.
Exclusion criteria	<ul style="list-style-type: none"> Age <18 years no TVUS or MRI performed within 1 year before surgery missing documents (surgical reports, MRI, and TVUS findings).
Patient characteristics	<p>N=178 symptomatic participants</p> <p><u>Age, years – mean (range)</u> 32.8 (19–49)</p> <p><u>Symptoms, n (%)</u> Dysmenorrhea: 146 (82) Dyspareunia: 110 (61.8) Non-cyclic pain: 59 (33.1) Dyschezia: 50 (28.1) Dysuria: 34 (19.1) Infertility: 36 (20.2)</p>

	<p>Ethnicity not reported</p> <p>Tertiary or secondary centre not reported.</p>
Index test(s)	<p><u>Transvaginal ultrasonography (TVUS)</u></p> <ul style="list-style-type: none"> • Performed by experienced radiologists with more than 3 years of experience in TVUS for endometriosis. • A location was considered positive when mentioned in the radiology report. • Sites were considered involved with the following criteria: <ul style="list-style-type: none"> • uterosacral ligament (USL): presence of nodule or hypoechogenic linear thickening with regular or irregular margins • vagina: posterior vaginal fornix was thickened, with or without round cystic anechoic areas • rectosigmoid: irregular hypoechogenic mass, with or without hypoechogenic or hyperechogenic foci • bladder: hypo- or isoechogenic nodule and/or cystic lesion of the bladder wall. <p><u>Magnetic resonance imaging (MRI)</u></p> <ul style="list-style-type: none"> • MRI sequences were acquired at 1.5 T or 3T. • The findings were interpreted by experienced radiologists with >3 years of experience in gynecologic imaging. • Sites were considered involved with the following criteria <ul style="list-style-type: none"> • USL: On 2 perpendicular planes: spiculated thickening; nodular thickening; smooth thickening >5mm; high T1 weighted implants • vagina: Obliteration of the hypointense signal of the posterior vaginal wall on T2-weighted images • rectosigmoid: disappearance of the fat tissue plane between the uterus, rectum and sigmoid colon; disappearance of the hypointense signal of the anterior wall of the rectum and sigmoid colon on T2-weighted MR images; presence of a tissue mass extending on the anterior wall of the rectum and the inferior wall of the sigmoid colon showing contrast enhancement on T1-weighted MR images • bladder: nodule or mass at the level of the vesico-uterine pouch and obliteration of the hypointense signal of the wall on T2W images.
Reference standard(s)	<p><u>Surgery and histopathology</u></p> <ul style="list-style-type: none"> • performed by leading surgeon • diagnosis of deep infiltrating endometriosis (DIE) was confirmed when 1 or more location was histologically identified.

Duration of follow-up	Not reported
Sources of funding	Not reported
Target condition	Deep infiltrating endometriosis (DIE)
Results	<p>TVUS:</p> <p>Site: USL (169/178) TP: 130; FP 1; FN 39; TN 8</p> <p>Site: vagina (36/178) TP 16; FP 12; FN 20; TN 130</p> <p>Site: rectosigmoid (61/178) TP 51; FP 8; FN 10; TN 109</p> <p>Site: bladder (13/178) TP 8; FP 1; FN 5; TN 164</p> <p>MRI:</p> <p>Site: USL TP 159; FP 3; FN 10; TN 6</p> <p>Site: vagina TP 20; FP 22; FN 16; TN 120</p> <p>Site: rectosigmoid TP 53; FP 5; FN 8; TN 112</p> <p>Site: bladder TP 11; FP 1; FN 2; TN 164</p> <p>TVUS + MRI</p> <p>Site: USL TP 126; FP 1; FN 43; TN 8</p> <p>Site: vagina TP 11; FP 8; FN 25; TN 134</p> <p>Site: rectosigmoid</p>

TP 47; FP 1; FN 14; TN 116

Site: bladder

TP 8; FP 1; FN 5; TN 164

1 Critical appraisal – NGA Critical appraisal – QUADAS-2

Section	Question	Answer
Patient selection: risk of bias	Could the selection of patients have introduced bias?	Low <i>(All participants meeting inclusion criteria in a given period were included. Inappropriate exclusions were avoided.)</i>
Patient selection: applicability	Are there concerns that included patients do not match the review question?	Low
Index tests: risk of bias	Could the conduct or interpretation of the index test have introduced bias?	Low <i>(Index test was performed before reference standard.)</i>
Index tests: applicability	Are there concerns that the index test, its conduct, or interpretation differ from the review question?	Low
Reference standard: risk of bias	Could the reference standard, its conduct, or its interpretation have introduced bias?	Unclear <i>(Knowledge of index test results can introduce bias to the reference standard as it could affect the location the surgeon looks for lesions.)</i>
Reference standard: applicability	Is there concern that the target condition as defined by the reference standard does not match the review question?	Low
Flow and timing: risk of bias	Could the patient flow have introduced bias?	Low

2

3 Rokhgireh, 2020

Bibliographic Reference Rokhgireh, Samaneh; Mehdizadeh Kashi, Abolfazl; Chaichian, Shahla; Delbandi, Ali-Akbar; Allahqoli, Leila; Ahmadi-Pishkuhi, Mahin; Khodaverdi, Sepideh; Alkatout, Ibrahim; The Diagnostic Accuracy of Combined Enolase/Cr, CA125, and CA19-9 in the Detection of Endometriosis.; BioMed research international; 2020; vol. 2020; 5208279

1

2 Study details

Country/ies where study was carried out	Iran
Study type	Prospective cohort study
Study dates	April 2015 to April 2018
Inclusion criteria	<ul style="list-style-type: none"> • Women who were candidates for diagnostic or operative laparoscopy due to ovarian cysts, pelvic pain, infertility, suspicious endometriosis or abnormal uterine bleeding • age 15-45 years • no use of hormones or gonadotropin-releasing hormone agonists (GnRHa) in the last 3 months • no underlying diseases such as infection, autoimmune disease, or cardiovascular conditions.
Exclusion criteria	<ul style="list-style-type: none"> • Diagnosed with gynecological diseases other than endometriosis (adenomyosis, malignancy, uterine polyp, acute or chronic inflammatory condition, endometrial hyperplasia) during surgery.
Patient characteristics	<p>N=115 (31 had a pathology of malignancy, adenomyosis, a uterine polyp, or chronic inflammation and were excluded) Some symptomatic participants (proportions not given)</p> <p><u>Age, years – mean (SD):</u> Endometriosis: 32.4 (6.2) Control: 32.1 (7.3)</p> <p>Ethnicity and symptoms not reported.</p>

	Tertiary centre
Index test(s)	<p>CA125</p> <ul style="list-style-type: none"> • Blood sample taken and centrifuged for 5 minutes • Serum withdrawn and frozen at -80°C until analysis. • All experiments were performed in one laboratory. • 35 IU/ml used as the cut-off for diagnosis.
Reference standard(s)	<p>Laparoscopy with histology</p> <ul style="list-style-type: none"> • All patients underwent laparoscopic surgery. • Suspicious endometriotic lesions were excised and patients were assigned to the endometriosis group or the control group after histological confirmation. • The stage of endometriosis was determined according to the revised classification of the American Society of Reproductive of Medicine.
Duration of follow-up	Not reported
Sources of funding	Not industry funded
Target condition	Deep and superficial endometriosis
Results	<p>multiple sites (deep and superficial)</p> <p>prevalence 47/84 TP 33; FP 5; FN 14; TN 32</p>

1 Critical appraisal – NGA Critical appraisal – QUADAS-2

Section	Question	Answer
Patient selection: risk of bias	Could the selection of patients have introduced bias?	Low (Participants meeting inclusion criteria for a given time period were included. Inappropriate exclusions were avoided.)

Section	Question	Answer
Patient selection: applicability	Are there concerns that included patients do not match the review question?	Low
Index tests: risk of bias	Could the conduct or interpretation of the index test have introduced bias?	Low
Index tests: applicability	Are there concerns that the index test, its conduct, or interpretation differ from the review question?	Low
Reference standard: risk of bias	Could the reference standard, its conduct, or its interpretation have introduced bias?	Low <i>(Knowledge of the index test would not have affected surgery or histology.)</i>
Reference standard: applicability	Is there concern that the target condition as defined by the reference standard does not match the review question?	Low
Flow and timing: risk of bias	Could the patient flow have introduced bias?	Unclear <i>(Time between tests is unclear.)</i>

1

2 Ros, 2021

Bibliographic Reference

Ros, C; de Guirior, C; Mension, E; Rius, M; Valdes-Bango, M; Tortajada, M; Matas, I; Martinez-Zamora, M A; Gracia, M; Carmona, F; Transvaginal ultrasound for diagnosis of deep endometriosis involving uterosacral ligaments, torus uterinus and posterior vaginal fornix: prospective study.; *Ultrasound in obstetrics & gynecology : the official journal of the International Society of Ultrasound in Obstetrics and Gynecology*; 2021; vol. 58 (no. 6); 926-932

3

4 Study details

Country/ies where study was carried	Spain
--	-------

out	
Study type	Prospective cohort study
Study dates	January 2018 to December 2019
Inclusion criteria	<ul style="list-style-type: none"> • Women with clinically suspected pelvic endometriosis scheduled for laparoscopy.
Exclusion criteria	<ul style="list-style-type: none"> • Suspected malignancy • aged less than years • postmenopausal • pregnant • any previous surgery for endometriosis in the posterior compartment.
Patient characteristics	<p>N=172 symptomatic participants</p> <p><u>Age, years – mean (SD)</u> 38.3 (6.2)</p> <p><u>Symptoms and signs, n (%)</u> Dysmenorrhea: 109 (63.4) Dyspareunia: 58 (33.7) Dysuria: 13 (7.6) Non-cyclic pelvic pain: 50 (29.1) Dyschezia: 51 (29.7) Rectorrhagia: 17 (9.9) Haematuria: 2 (1.2)</p> <p>Tertiary centre</p>
Index test(s)	<p><u>Transvaginal ultrasound (TVUS)</u></p> <ul style="list-style-type: none"> • Performed by 2 expert sonographers up to 4 weeks before surgery. • Sonographers were blinded to previous clinical examinations, reports of severity and previous surgical reports. • Performed according to IDEA group recommendations and nomenclature for describing the location and extent of endometriosis within the pelvis.

	<ul style="list-style-type: none"> • Diagnosis made in the presence of hypoechoic lesions.
Reference standard(s)	<p><u>Laparoscopy with histology</u></p> <ul style="list-style-type: none"> • Performed by 1 of 3 experienced surgeons • Presence of deep endometriosis was determined visually and confirmed histologically when infiltration was greater than 5 mm.
Duration of follow-up	Not reported
Sources of funding	Not reported
Target condition	Deep endometriosis
Results	<p>Site: Uterosacral ligaments TP 85; FP 15; FN 3; TN 69</p> <p>Site: posterior vaginal fornix (classified as vaginal in review analysis) TP 73; FP 9; FN 14; TN 76</p>

1 Critical appraisal – NGA Critical appraisal – QUADAS-2

Section	Question	Answer
Patient selection: risk of bias	Could the selection of patients have introduced bias?	Low
Patient selection: applicability	Are there concerns that included patients do not match the review question?	Low
Index tests: risk of bias	Could the conduct or interpretation of the index test have introduced bias?	Low <i>(Index test was performed before the reference standard.)</i>

Section	Question	Answer
Index tests: applicability	Are there concerns that the index test, its conduct, or interpretation differ from the review question?	Low
Reference standard: risk of bias	Could the reference standard, its conduct, or its interpretation have introduced bias?	Unclear <i>(Knowledge of index test results can introduce bias to the reference standard as it could affect the location the surgeon looks for lesions.)</i>
Reference standard: applicability	Is there concern that the target condition as defined by the reference standard does not match the review question?	Low
Flow and timing: risk of bias	Could the patient flow have introduced bias?	Low

1

2 Shahbazi, 2022

Bibliographic Reference

Shahbazi, M.; Poordast, T.; Masoudi, N.; Haghigatafshar, M.; The potential role of radiolabeled red blood cell scintigraphy in diagnosis of endometriosis; Iranian Journal of Nuclear Medicine; 2022; vol. 30 (no. 1); 26-32

3

4 Study details

Country/ies where study was carried out	Iran
Study type	Prospective cohort study
Study dates	Not reported

Inclusion criteria	<ul style="list-style-type: none"> • Candidate for laparoscopy to diagnosis endometriosis.
Exclusion criteria	<ul style="list-style-type: none"> • History of: claustrophobia gastrointestinal bleeding or GI telangiectasia.
Patient characteristics	<p>N=20 participants (symptomatic or asymptomatic unclear)</p> <p><u>Age, years – mean (SD)</u> 35 (8.79)</p> <p>Symptoms and ethnicity not reported.</p> <p>Tertiary or secondary centre not reported.</p>
Index test(s)	<p><u>Transvaginal ultrasound (TVUS)</u></p> <ul style="list-style-type: none"> • Performed 4 months before surgery <p><u>Magnetic resonance imaging (MRI)</u></p> <ul style="list-style-type: none"> • Performed 2 months before surgery
Reference standard(s)	Laparoscopy with histology
Duration of follow-up	Not reported
Sources of funding	Not reported
Target condition	Deep and superficial endometriosis
Results	<p>Multiple sites (deep and superficial)</p> <p>TVUS (results available for 20 patients, prevalence (11/20))</p>

	TP 8; FP 0; FN 3; TN 9
	MRI (results available for 14 patients, prevalence (9/14) TP 7; FP 1; FN 2; TN 4

1

2

3 **Critical appraisal – NGA Critical appraisal – QUADAS-2**

Section	Question	Answer
Patient selection: risk of bias	Could the selection of patients have introduced bias?	Unclear <i>(Inappropriate exclusions were avoided but a specific number of participants were included and it is unclear how.)</i>
Patient selection: applicability	Are there concerns that included patients do not match the review question?	Low
Index tests: risk of bias	Could the conduct or interpretation of the index test have introduced bias?	Low <i>(Index test was performed before the reference standard.)</i>
Index tests: applicability	Are there concerns that the index test, its conduct, or interpretation differ from the review question?	Low
Reference standard: risk of bias	Could the reference standard, its conduct, or its interpretation have introduced bias?	Unclear <i>(Unclear if index test result was known. Knowledge of index test can introduce bias to the reference standard as it could affect the location the surgeon looks for lesions.)</i>
Reference standard: applicability	Is there concern that the target condition as defined by the reference standard does not match the review question?	Low
Flow and timing: risk of bias	Could the patient flow have introduced bias?	Low

1

2 **Siddiqui, 2021****Bibliographic Reference**

Siddiqui, Saad; Bari, Vaqar; Accuracy of MRI Pelvis in the Diagnosis of Ovarian Endometrioma: Using Histopathology as Gold Standard.; Cureus; 2021; vol. 13 (no. 12); e20650

3

4 **Study details**

Country/ies where study was carried out	Pakistan
Study type	Prospective cohort study
Study dates	Not reported
Inclusion criteria	<ul style="list-style-type: none"> • Aged 14 to 65 years • referred for MRI pelvis for evaluation of endometriosis • pre-menopausal and post-menopausal patients.
Exclusion criteria	<ul style="list-style-type: none"> • History of biopsy proven endometriosis • patients who did not have final histopathology results.
Patient characteristics	<p>N=170 participants (symptomatic or asymptomatic unclear)</p> <p><u>Age, years – mean (SD)</u> 36.8 (10.4)</p> <p>Symptoms and ethnicity not reported</p> <p>Tertiary centre.</p>
Index test(s)	<u>Magnetic resonance imaging</u>

	<ul style="list-style-type: none"> The sequences included T1- and T2-weighted, and T1-weighted with fat suppression, diffusion-weighted imaging and apparent diffusion coefficient maps. Images were reported by radiologist. MRI features of endometrioma: hyperintense on T1 and T1 fat suppressed images, hypointense on T2-weighted images, and following signal characteristics of blood products on DWI and ADC map. (Labelled as MRI positive).
Reference standard(s)	<p><u>Histopathology</u></p> <ul style="list-style-type: none"> Positive if 2 of 3 features were present in resection ovarian lesions: endometrial glands, endometrial stroma, or haemorrhage on microscopy. Histopathology negative if resected lesions did not fulfil 2 of 3 lesions.
Duration of follow-up	Not reported
Sources of funding	Not reported
Target condition	endometrioma (endometriosis in ovaries)
Results	MRI: TP 85; FP: 13; FN 13; TN 59

1

2

3 **Critical appraisal – NGA Critical appraisal – QUADAS-2**

Section	Question	Answer
Patient selection: risk of bias	Could the selection of patients have introduced bias?	Low
Patient selection: applicability	Are there concerns that included patients do not match the review question?	Low

Section	Question	Answer
Index tests: risk of bias	Could the conduct or interpretation of the index test have introduced bias?	Low <i>(Index test was performed before the reference standard.)</i>
Index tests: applicability	Are there concerns that the index test, its conduct, or interpretation differ from the review question?	Low
Reference standard: risk of bias	Could the reference standard, its conduct, or its interpretation have introduced bias?	Unclear <i>(Unclear if reference standard was performed without knowledge of index test result. Knowledge of index test result can introduce bias to the reference standard as it could affect the location the surgeon looks for lesions.)</i>
Reference standard: applicability	Is there concern that the target condition as defined by the reference standard does not match the review question?	Low
Flow and timing: risk of bias	Could the patient flow have introduced bias?	Unclear <i>(Time between tests unclear)</i>

1

2 **Widschwendter, 2022**

Bibliographic Reference Widschwendter, P; Kohler, M; Friedl, Twp; Ammann, B; Janni, W; Rhomberg, C; Karner, M; Beer, M; De Gregorio, A; Polasik, A; Diagnosis of presence and extent of deep infiltrating endometriosis by preoperative MRI-improvement of staging accuracy by expert training.; Journal of gynecology obstetrics and human reproduction; 2022; vol. 51 (no. 1); 102236

3

4 **Study details**

Country/ies where study was carried out	Germany
--	---------

Study type	Retrospective cohort study
Study dates	2015 and 2018
Inclusion criteria	<ul style="list-style-type: none"> • Patients with suspected deep infiltrating endometriosis (by rectovaginal palpation and TVUS) • treated with surgery (at least diagnostic laparoscopy) • complete dataset including MRI and histopathological report.
Exclusion criteria	None specified
Patient characteristics	<p>N=80 symptomatic participants</p> <p><u>Age, years – median (range)</u> 33 (15-55)</p> <p><u>Main symptoms, n (%)</u> Dysmenorrhoea: 73 (91.3) Dyspareunia: 56 (70) Dysuria: 20 (25) Dyschezia: 6 (7.5)</p> <p>Ethnicity not reported</p> <p>Tertiary or secondary centre not reported.</p>
Index test(s)	<p><u>Magnetic resonance imaging (MRI)</u></p> <ul style="list-style-type: none"> • Performed with the only information that DIE was suspected • 3T scanner • T2-weighted sequences and T1- weighted fat saturated images.
Reference standard(s)	<p><u>Surgery:</u></p> <ul style="list-style-type: none"> • Laparoscopy: ranged from diagnostic laparoscopy only without subsequent therapeutic surgery to complete resection

	<ul style="list-style-type: none"> • or, robotic-assisted laparoscopy • or, laparotomy. <p>Histopathological report available for all patients.</p>
Duration of follow-up	Not reported
Sources of funding	No funding
Target condition	Deep endometriosis
Results	<p>Site: sacro-uterine ligaments Prevalence 47/80 TP 27; FP 5; FN 20; TN 28;</p> <p>Site: rectum Prevalence 22/80 TP 11; FP 6; FN 11; TN 52</p>

1

2

3

Critical appraisal – NGA Critical appraisal – QUADAS-2

Section	Question	Answer
Patient selection: risk of bias	Could the selection of patients have introduced bias?	Low <i>(All participants meeting inclusion criteria in a given time period included. No inappropriate exclusions.)</i>
Patient selection: applicability	Are there concerns that included patients do not match the review question?	Low
Index tests: risk of bias	Could the conduct or interpretation of the index test have introduced bias?	Low <i>(Index test was performed before the reference standard.)</i>

Section	Question	Answer
Index tests: applicability	Are there concerns that the index test, its conduct, or interpretation differ from the review question?	Low
Reference standard: risk of bias	Could the reference standard, its conduct, or its interpretation have introduced bias?	Unclear (Unclear if the index test was known. Knowledge of index test can introduce bias to the reference standard as it could affect the location the surgeon looks for lesions.)
Reference standard: applicability	Is there concern that the target condition as defined by the reference standard does not match the review question?	Low
Flow and timing: risk of bias	Could the patient flow have introduced bias?	Unclear (Time between tests is unclear.)

1

2 **Zannoni, 2017****Bibliographic Reference**

Zannoni, Letizia; Del Forno, Simona; Coppola, Francesca; Papadopoulos, Dimitris; Valerio, Domenico; Golfieri, Rita; Caprara, Giacomo; Paradisi, Roberto; Seracchioli, Renato; Comparison of transvaginal sonography and computed tomography-colonography with contrast media and urographic phase for diagnosing deep infiltrating endometriosis of the posterior compartment of the pelvis: a pilot study.; Japanese journal of radiology; 2017; vol. 35 (no. 9); 546-554

3

4 **Study details**

Country/ies where study was carried out	Italy
Study type	Prospective cohort study

Study dates	May 2011 and May 2013
Inclusion criteria	<ul style="list-style-type: none"> • Suspicion of posterior deep infiltrating endometriosis (DIE) • pain score • clinical objectivity at gynaecological examination • childbearing age • indication for transvaginal ultrasonography (TVS) and computed tomography–colonography with contrast media and urographic phase • willing to undergo surgical treatment.
Exclusion criteria	<ul style="list-style-type: none"> • Previous surgery for endometriosis • previous radical surgery of the bowel or of the urinary tract • previous bilateral oophorectomy • previous radiological studies for the diagnosis of intestinal or urinary tract endometriosis • intolerance to iodinated contrast • renal or hepatic failure.
Patient characteristics	<p>N=47 symptomatic participants</p> <p><u>Age, years – mean (SD)</u> 37 (5.3)</p> <p><u>Symptoms, n (%)</u> Dysmenorrhea: 36 (76.6) Chronic pelvic pain: 30 (63.8) Dyspareunia: 31 (65.9) Dyschezia: 33 (70.2) Dysuria: 13 (27.6)</p> <p>Tertiary or secondary centre not reported.</p>
Index test(s)	<p><u>Transvaginal ultrasonography (TVS)</u></p> <ul style="list-style-type: none"> • Performed by one gynaecologist with more than 5 years experience in gynaecological ultrasound.

	<ul style="list-style-type: none"> Images evaluated by 2 radiologists with more than 10 years experience in abdominal radiology.
Reference standard(s)	<p><u>Surgery and histology</u></p> <ul style="list-style-type: none"> Performed within 1 month from diagnostic tests. All surgeries were performed by the same surgeon. The confirmation of DIE was based on the endometrial glands and stroma associated with fibrosis, hyperplasia and hypertrophy of smooth muscle cells.
Duration of follow-up	Not reported
Sources of funding	Not reported
Target condition	Deep endometriosis
Results	<p>TVS</p> <p>Site: rectovaginal septum (25/47) TP 12; FP 3; FN 13; TN 19</p> <p>Site: rectosigmoid junction (23/47) TP 12; FP 5; FN 11; TN 19</p> <p>Site: right uterosacral ligament (9/47) TP 0; FP 2; FN 9; TN 36</p> <p>Site: left uterosacral ligament (19/47) TP 5; FP 1; FN 14; TN 27</p> <p>Site: right ureter (10/47) TP 1; FP 2; FN 9; TN 35</p> <p>Site: left ureter (21/47) TP 6; FP 1; FN 15; TN 25</p>

1 **Critical appraisal - NGA Critical appraisal - QUADAS-2**

Section	Question	Answer
Patient selection: risk of bias	Could the selection of patients have introduced bias?	Low <i>(Eligible participants in a given time period were included and there were no inappropriate exclusions.)</i>
Patient selection: applicability	Are there concerns that included patients do not match the review question?	Low
Index tests: risk of bias	Could the conduct or interpretation of the index test have introduced bias?	Low
Index tests: applicability	Are there concerns that the index test, its conduct, or interpretation differ from the review question?	Low
Reference standard: risk of bias	Could the reference standard, its conduct, or its interpretation have introduced bias?	Unclear <i>(Unclear if the index test was known. Knowledge of index test can introduce bias to the reference standard as it could affect the location the surgeon looks for lesions.)</i>
Reference standard: applicability	Is there concern that the target condition as defined by the reference standard does not match the review question?	Low
Flow and timing: risk of bias	Could the patient flow have introduced bias?	Low

2

3 **Zhang, 2019****Bibliographic Reference**

Zhang, Yujuan; Xiao, Xiaojun; Xu, Fanhua; Lin, Qi; Xu, Jinfeng; Du, Bo; Evaluation of Uterosacral Ligament Involvement in Deep Endometriosis by Transvaginal Ultrasonography.; *Frontiers in pharmacology*; 2019; vol. 10; 374

4

1 **Study details**

Country/ies where study was carried out	China
Study type	Prospective cohort study
Study dates	October 2013 to October 2017
Inclusion criteria	<ul style="list-style-type: none"> • Deep infiltrating endometriosis (DIE) diagnosed clinically. • Patients needing surgical treatment.
Exclusion criteria	<ul style="list-style-type: none"> • Withdrawal for personal reasons • pregnancy • those who have not previously undergone surgery for any reasons.
Patient characteristics	<p>N=118 participants (symptomatic or asymptomatic unclear)</p> <p><u>Age, years - mean (SD):</u> 35.2 (6.2)</p> <p>Ethnicity and symptoms not reported.</p> <p>Tertiary or secondary centre not reported.</p>
Index test(s)	<p><u>Transvaginal sonography (TVS)</u></p> <ul style="list-style-type: none"> • Performed by one examiner who had received professional training. • They were blinded to the physical examination and previous imaging but aware investigations were for chronic pelvic pain and suspected endometriosis. • Performed within 2 weeks of surgery. • Echogenicity, shapes changes, thickness and size of uterosacral ligaments were recorded.

Reference standard(s)	<u>Surgery and histopathology</u> No further details provided
Duration of follow-up	Not reported
Sources of funding	Clinical Research Project of Shenzhen Health and Family Planning Commission in China Shenzhen People's Hospital Young and Middle-aged Research Funds Cultivation Fund Guangdong Medical Science and Technology Research Fund
Target condition	Deep infiltrating endometriosis (DIE)
Results	Site: uterosacral ligaments (85/118) TP 81; FP 3; FN 4; TN 30

1

2 **Critical appraisal - NGA Critical appraisal - QUADAS-2**

Section	Question	Answer
Patient selection: risk of bias	Could the selection of patients have introduced bias?	Low <i>(Participants who met inclusion criteria in a given time period were included. There were no inappropriate exclusions.)</i>
Patient selection: applicability	Are there concerns that included patients do not match the review question?	Low
Index tests: risk of bias	Could the conduct or interpretation of the index test have introduced bias?	Low
Index tests: applicability	Are there concerns that the index test, its conduct, or interpretation differ from the review question?	Low

Reference standard: risk of bias	Could the reference standard, its conduct, or its interpretation have introduced bias?	Unclear <i>(Unclear if the index test was known. Knowledge of index test can introduce bias to the reference standard as it could affect the location the surgeon looks for lesions.)</i>
Reference standard: applicability	Is there concern that the target condition as defined by the reference standard does not match the review question?	Low
Flow and timing: risk of bias	Could the patient flow have introduced bias?	Low

1
2
3
4
5
6
7
8

AUC: area under curve; BE: bladder endometriosis; CA-125: cancer antigen-125; CI: confidence interval; DE: deep endometriosis; DIE: deep infiltrating endometriosis; FP: false positive; FN: false negative; GnRHa: gonadotropin-releasing hormone agonists; MRI: magnetic resonance imaging; PE: physical examination; QUADAS: Quality Assessment of Diagnostic Accuracy Studies; RES: rectal endoscopic sonography; RWC-TVS: rectal water contrast-transvaginal sonography; RVE: rectovaginal endometriosis; SD: standard deviation; SVG: sonovaginography; TAUS: transabdominal ultrasound; TN: true negative; TP: true positive; TRS: transrectal sonography; TRUS: transrectal ultrasound; TVS: transvaginal sonography; TVU: transvaginal ultrasound; TVUS: transvaginal ultrasound; USL: uterosacral ligament

1 Appendix E Forest plots

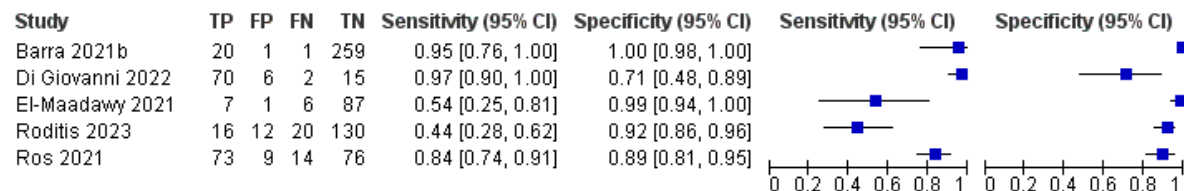
2 Forest plots for review question: What is the accuracy of the following tests in diagnosing endometriosis:

- 3 • imaging
4 • biomarkers
5 • surgical diagnosis (open surgery or laparoscopic surgery)?

6 This section includes forest plots only for outcomes that are meta-analysed. Meta-analysis was conducted in Winbugs and the pooled estimates
7 from Winbugs analysis are reported in GRADE tables. Outcomes from single studies are not presented here; the quality assessment for such
8 outcomes is provided in the GRADE profiles in appendix F.

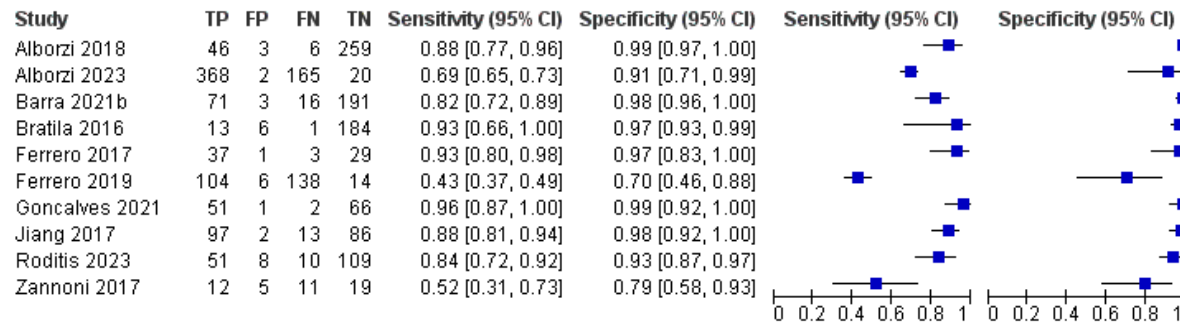
9 Ultrasound for diagnosis of endometriosis

Figure 2: Transvaginal US – vagina (deep depth) (surgery from 4 to 12 months after US)



Sensitivity not pooled due to very serious heterogeneity

Figure 3: Transvaginal US – rectosigmoid (deep depth) (surgery from 1 to 12 months after US)



1
2

Figure 4: Transvaginal US – rectovaginal septum (deep depth) (surgery within 1 months after US)

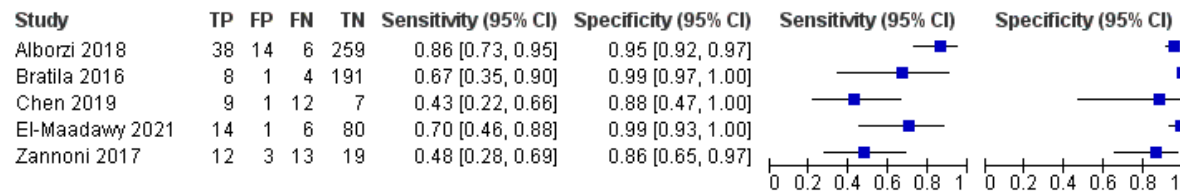
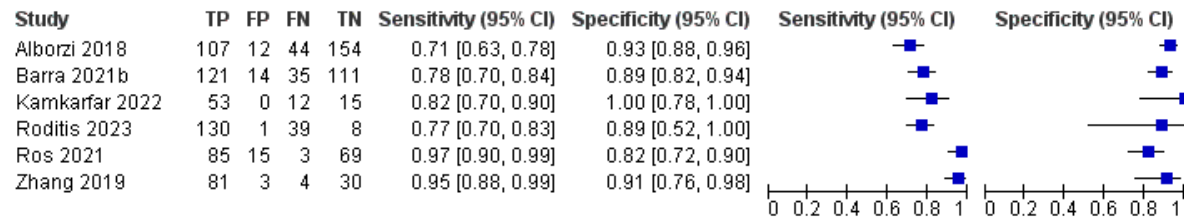


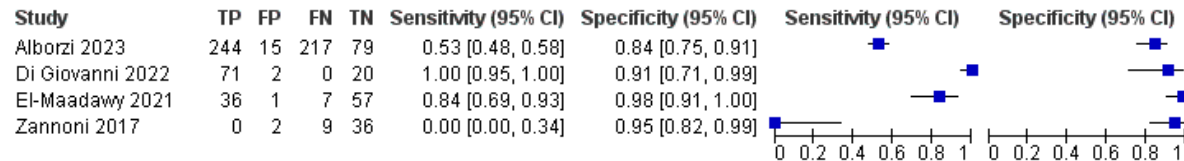
Figure 5: Transvaginal US – uterosacral ligaments (deep depth) (surgery from 2 weeks to 1 year after US)



1

1

Figure 6: Transvaginal US – right uterosacral ligament (deep depth) (surgery from 1 to 3 months after US)



2 Sensitivity not pooled due to very serious heterogeneity

Figure 7: Transvaginal US – left uterosacral ligament (deep depth) (surgery from 1 to 3 months after US)

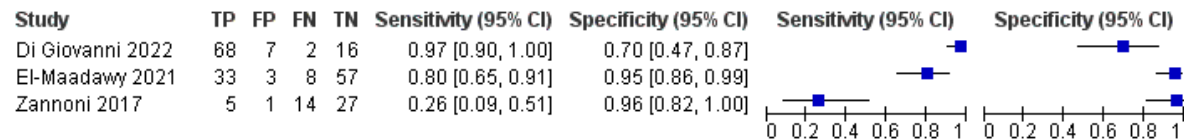
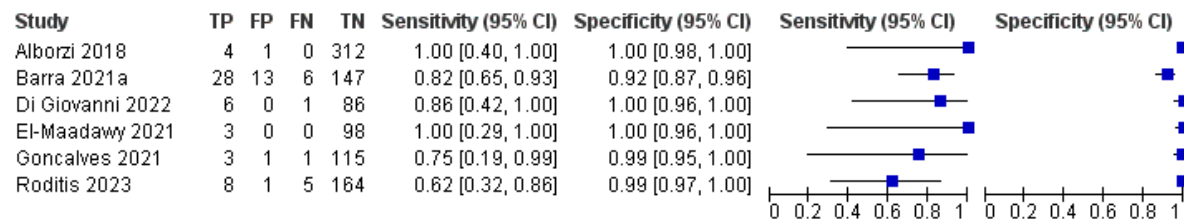


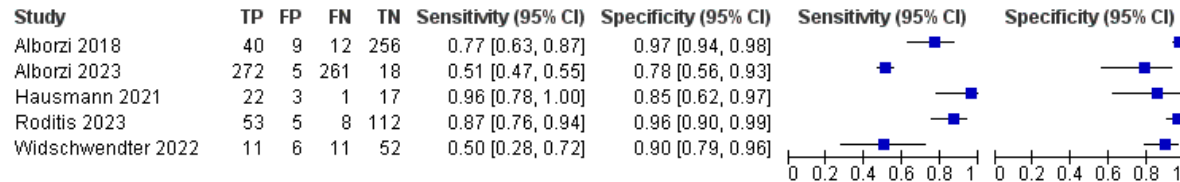
Figure 8: Transvaginal US – bladder (deep depth) (surgery from 4 weeks to 1 year after US)



3

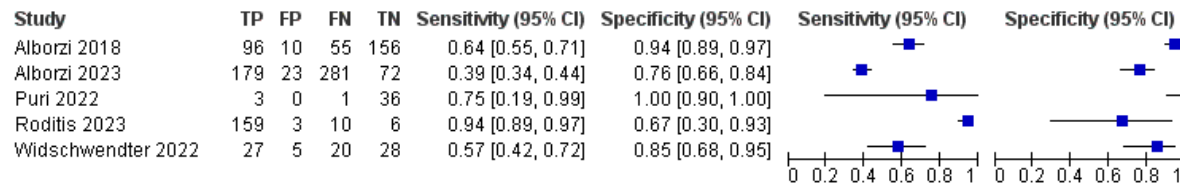
4 **Magnetic Resonance Imaging**

Figure 9: MRI - with contrast or type unspecified – rectosigmoid (deep depth) (up to 12 months after MRI)



Sensitivity not pooled due to very serious heterogeneity

Figure 10: MRI – with contrast or type unspecified - uterosacral ligaments (deep depth) (surgery up to 12 months after scan)



1 Sensitivity not pooled due to very serious heterogeneity

2

3

1 Appendix F GRADE tables

2 **GRADE tables for review question: What is the accuracy of the following tests in diagnosing endometriosis:**

- 3 • **imaging**
4 • **biomarkers**
5 • **surgical diagnosis (open surgery or laparoscopic surgery)?**

6 Ultrasound

7 **Table 4: Ultrasound - ovary including endometrioma [deep or superficial depth]**

No of studies	Study details	No of participants	Diagnostic accuracy estimate (95% CI)	Risk of bias	Inconsistency	Indirectness	Imprecision	Quality of evidence
Transvaginal US – ovaries (deep and superficial depth) (timing of imaging tests not reported)								
1 (Bratila 2016)	Population: Women who were due to have a transvaginal scan before surgery for endometriosis	N=204	Sensitivity: 0.94 (0.88 to 0.98)	No risk of bias	No serious inconsistency	No serious indirectness	Serious ¹	MODERATE
			Specificity: 0.96 (0.90 to 0.99)	No risk of bias	No serious inconsistency	No serious indirectness	No serious imprecision	HIGH
Transvaginal US – ovaries (deep depth) (timing of imaging tests not reported)								
1 (Kamkarfar 2022)	Population: Women who were due to have a transvaginal scan before surgery for endometriosis	N=80	Sensitivity: 1 (0.95 to 1)	Serious ²	No serious inconsistency	No serious indirectness	No serious imprecision	MODERATE
			Specificity: 1 (0.75 to 1)	Serious ²	No serious inconsistency	No serious indirectness	Serious ¹	LOW
1 (Goncalves 2021)		N=120	Sensitivity: 0.95 (0.74 to 1)	No risk of bias	No serious inconsistency	No serious indirectness	Serious ¹	MODERATE
			Specificity: 0.95 (0.89 to 0.98)	No risk of bias	No serious inconsistency	No serious indirectness	Serious ¹	MODERATE
Transvaginal US – right endometrioma (time of imaging test not reported)								
1 (Alborzi 2023)	Population: Women who had a transvaginal scan before surgery for deep endometriosis	N=555	Sensitivity: 0.70 (0.65 to 0.75)	No serious risk of bias	No serious inconsistency	No serious indirectness	No serious imprecision	HIGH
			Specificity: 0.94 (0.90 to 0.97)	No serious risk of bias	No serious inconsistency	No serious indirectness	No serious imprecision	HIGH

No of studies	Study details	No of participants	Diagnostic accuracy estimate (95% CI)	Risk of bias	Inconsistency	Indirectness	Imprecision	Quality of evidence
Transvaginal US – right ovary (deep depth) (surgery within 3 months after US)								
1 (Di Giovanni 2022)	Population: Women who has a transvaginal scan before surgery for deep endometriosis	N=93	Sensitivity: 1 (0.89 to 1)	No risk of bias	No serious inconsistency	No serious indirectness	Serious ¹	MODERATE
			Specificity: 1 (0.94 to 1)	No risk of bias	No serious inconsistency	No serious indirectness	No serious imprecision	HIGH
Transvaginal US – left ovary (deep depth) (surgery within 3 months after US)								
1 (Di Giovanni 2022)	Population: Women who had a transvaginal scan before surgery for deep endometriosis	N=93	Sensitivity: 1 (0.91 to 1)	No serious risk of bias	No serious inconsistency	No serious indirectness	No serious imprecision	HIGH
			Specificity: 0.96 (0.87 to 1)	No serious risk of bias	No serious inconsistency	No serious indirectness	Serious ¹	MODERATE
Transabdominal US – ovaries (deep depth) (timing of imaging tests not reported)								
1 (Puri 2022)	Population: Women who were due to have a transvaginal scan before surgery for deep endometriosis	N=40	Sensitivity: 0.91 (0.75 to 0.98)	Serious ²	No serious inconsistency	No serious indirectness	Serious ¹	LOW
			Specificity: 0.75 (0.35 to 0.97)	Serious ²	No serious inconsistency	No serious indirectness	Very serious ³	VERY LOW
Transvaginal and transrectal US – right ovary (deep depth) (timing of imaging tests not reported)								
1 (Asgari 2022)	Population: Women who had a transvaginal scan before surgery for deep endometriosis	N=119	Sensitivity: 0.85 (0.75 to 0.92)	No risk of bias	No serious inconsistency	No serious indirectness	Serious ¹	MODERATE
			Specificity: 0.75 (0.60 to 0.87)	No risk of bias	No serious inconsistency	No serious indirectness	Serious ¹	MODERATE
Transvaginal and transrectal US – left ovary (deep depth) (timing of imaging tests not reported)								
1 (Asgari 2022)	Population: Women who had a transvaginal scan before surgery	N=119	Sensitivity: 0.85 (0.75 to 0.92)	No risk of bias	No serious inconsistency	No serious indirectness	Serious ¹	MODERATE

No of studies	Study details	No of participants	Diagnostic accuracy estimate (95% CI)	Risk of bias	Inconsistency	Indirectness	Imprecision	Quality of evidence
	for deep endometriosis		Specificity: 0.88 (0.73 to 0.97)	No risk of bias	No serious inconsistency	No serious indirectness	Serious ¹	MODERATE
Transvaginal and transabdominal US – right ovary (deep depth) (surgery within 3 months after US)								
1 (Montanari 2022)	Population: Women who were due to have a transvaginal scan before surgery for deep endometriosis	N=745	Sensitivity: 0.89 (0.84 to 0.92) ⁴	No risk of bias	No serious inconsistency	No serious indirectness	Serious ¹	MODERATE
			Specificity: 0.98 (0.96 to 0.99) ⁴	No risk of bias	No serious inconsistency	No serious indirectness	No serious imprecision	HIGH
Transvaginal and transabdominal US – left ovary (deep depth) (surgery within 3 months after US)								
1 (Montanari 2022)	Population: Women who were due to have a transvaginal scan before surgery for deep endometriosis	N=745	Sensitivity: 0.90 (0.86 to 0.94) ⁴	No risk of bias	No serious inconsistency	No serious indirectness	Serious ¹	MODERATE
			Specificity: 0.96 (0.94 to 0.98) ⁴	No risk of bias	No serious inconsistency	No serious indirectness	No serious imprecision	HIGH

- 1 CI: confidence interval; US: ultrasound
- 2 1 95% CI crosses 1 decision making threshold (0.60 to 0.90)
- 3 2 Serious risk of bias as assessed by QUADAS-2
- 4 3 95% CI crosses 2 decision making thresholds (0.60 to 0.90)
- 5 4 Sensitivity and specificity taken from the study as 2x2 data not available

6 **Table 5: Ultrasound – vagina [deep and superficial depth]**

No of studies	Study details	No of participants	Diagnostic accuracy estimate (95% CI)	Risk of bias	Inconsistency	Indirectness	Imprecision	Quality of evidence
Transvaginal US – vagina (deep depth) (surgery from 4 to 12 months after US)								
1 (Barra 2021b)	Population: Women who had or were due to have a transvaginal scan before surgery for deep endometriosis	N=281	Sensitivity: 0.95 (0.76 to 1)	No serious risk of bias	Very serious ¹	No serious indirectness	Serious ²	VERY LOW
1 (Di Giovanni 2022)		N=93	Sensitivity: 0.97 (0.90 to 1)	No serious risk of bias		No serious indirectness	No serious imprecision	LOW
1 (El-Maadawy)		N=101	Sensitivity: 0.54 (0.25 to 0.83)	No serious risk		No serious indirectness	Serious ²	VERY LOW

No of studies	Study details	No of participants	Diagnostic accuracy estimate (95% CI)	Risk of bias	Inconsistency	Indirectness	Imprecision	Quality of evidence
2021)			0.81)	of bias		indirectness		
1 (Roditis 2023)		N=178	Sensitivity: 0.44 (0.28 to 0.62)	No serious risk of bias		No serious indirectness	Serious ²	VERY LOW
1 (Ros 2021)		N=172	Sensitivity: 0.84 (0.74 to 0.91)	No serious risk of bias		No serious indirectness	Serious ²	VERY LOW
5 (Barra 2021b; Di Giovanni 2022; El-Maadawy 2021; Roditis 2023; Ros 2021)	Population: Women who had or were due to have a transvaginal scan before surgery for deep endometriosis	N=825	Specificity: 0.95 (0.77 to 0.99)	No serious risk of bias	Serious ³	No serious indirectness	Serious ²	LOW
Transvaginal US – vagina (deep and superficial depth) (timing of imaging tests not reported)								
1 (Bratila 2016)	Population: Women who were due to have a transvaginal scan before surgery for endometriosis	N=204	Sensitivity: 0.58 (0.28 to 0.85)	No serious risk of bias	No serious inconsistency	No serious indirectness	Serious ²	MODERATE
			Specificity: 0.99 (0.96 to 1)	No serious risk of bias	No serious inconsistency	No serious indirectness	No serious imprecision	HIGH

1 CI: confidence interval; US: ultrasound

2 1 Very serious heterogeneity (assessed by visual inspection of point estimates and confidence intervals). Meta-analysis was not performed where there was very serious heterogeneity.

3 2 95% CI crosses 1 decision making threshold (0.60 to 0.90)

4 3 Serious heterogeneity (assessed by visual inspection of point estimates and confidence intervals). Random effect analysis used in Winbugs analysis. Sub-group analysis could not be conducted as there was no sufficient information on sub-groups from the studies.

7 **Table 6: Ultrasound – rectosigmoid [deep depth]**

No of studies	Study details	No of participants	Diagnostic accuracy estimate (95% CI)	Risk of bias	Inconsistency	Indirectness	Imprecision	Quality of evidence
Transvaginal US – rectosigmoid (deep depth) (surgery from 1 to 12 months after US)								
10 (Alborzi 2018; Alborzi 2023; Barra	Population: Women who had or were due	N=2229	Sensitivity: 0.82 (0.68 to 0.91)	No serious risk of bias	Serious ¹	No serious indirectness	Serious ²	LOW

No of studies	Study details	No of participants	Diagnostic accuracy estimate (95% CI)	Risk of bias	Inconsistency	Indirectness	Imprecision	Quality of evidence
2021b; Bratila 2016; Goncalves 2021; Ferrero 2017; Ferrero 2019; Jiang 2017; Roditis 2023; Zannoni 2017)	to have a transvaginal scan before surgery for deep endometriosis		Specificity: 0.96 (0.90 to 0.98)	No serious risk of bias	No serious inconsistency	No serious indirectness	No serious imprecision	MODERATE
1 (Montanari 2022)	Population: Women who were due to have a transvaginal scan before surgery for deep endometriosis	N=745	Sensitivity: 0.93 (0.90 to 0.95) ³	No serious risk of bias	No serious inconsistency	No serious indirectness	No serious imprecision	HIGH
			Specificity 0.95 (0.92 to 0.98) ³	No serious risk of bias	No serious inconsistency	No serious indirectness	No serious imprecision	HIGH
Transrectal US – rectosigmoid (deep depth) (timing of imaging tests not reported)								
1 (Alborzi 2018)	Population: Women who were due to have a transvaginal scan before surgery for deep endometriosis	N=317	Sensitivity: 0.87 (0.74 to 0.94)	No serious risk of bias	No serious inconsistency	No serious indirectness	Serious ²	MODERATE
			Specificity: 0.98 (0.95 to 0.99)	No serious risk of bias	No serious inconsistency	No serious indirectness	No serious imprecision	HIGH
Transvaginal and transrectal US – rectosigmoid (deep depth) (timing of imaging tests not reported)								
1 (Asgari 2022)	Population: Women who had a transvaginal scan before surgery for deep endometriosis	N=119	Sensitivity: 0.53 (0.35, 0.70)	No serious risk of bias	No serious inconsistency	No serious indirectness	Serious ²	MODERATE
			Specificity: 0.94 (0.87 to 0.98)	No serious risk of bias	No serious inconsistency	No serious indirectness	Serious ²	MODERATE

1
2
3

CI: confidence interval; US: ultrasound

1 Serious heterogeneity (assessed by visual inspection of point estimates and confidence intervals). Random effect analysis used in Winbugs analysis. Sub-group analysis could not be conducted as there was no sufficient information on sub-groups from the studies.

- 1 2 95% CI crosses 1 decision making threshold (0.60 to 0.90)
- 2 3 Sensitivity and specificity taken from the study as 2x2 data not available.

3 **Table 7: Ultrasound – rectovaginal septum [deep depth]**

No of studies	Study details	No of participants	Diagnostic accuracy estimate (95% CI)	Risk of bias	Inconsistency	Indirectness	Imprecision	Quality of evidence
Transvaginal US – rectovaginal septum (deep depth) (surgery within 1 months after US)								
5 (Alborzi 2018; Bratila 2016; Chen 2019; El-Maadawy 2021; Zannoni 2017)	Population: Women who had or were due to have a transvaginal scan before surgery for deep endometriosis	N=698	Sensitivity: 0.65 (0.40 to 0.85)	No serious risk of bias	Serious ¹	No serious indirectness	Serious ²	LOW
			Specificity: 0.97 (0.87 to 0.99)	No serious risk of bias	No serious inconsistency	No serious indirectness	Serious ²	MODERATE
Transrectal US – rectovaginal septum (deep depth) (timing of imaging tests not reported)								
1 (Alborzi 2018)	Population: Women who had or were due to have a transvaginal scan before surgery for deep endometriosis	N=317	Sensitivity: 0.84 (0.70 to 0.93)	No serious risk of bias	No serious inconsistency	No serious indirectness	Serious ²	MODERATE
			Specificity: 0.94 (0.90 to 0.96)	No serious risk of bias	No serious inconsistency	No serious indirectness	No serious imprecision	HIGH
1 (Chen 2019)		N=29	Sensitivity: 0.81 (0.58 to 0.95)	No serious risk of bias	No serious inconsistency	No serious indirectness	Very serious ³	LOW
			Specificity: 0.75 (0.35 to 0.97)	No serious risk of bias	No serious inconsistency	No serious indirectness	Very serious ³	LOW

- 4 *CI: confidence interval; US: ultrasound*
- 5 1 Serious heterogeneity (assessed by visual inspection of point estimates and confidence intervals). Random effect analysis used in Winbugs analysis. Sub-group analysis could
- 6 not be conducted as there was no sufficient information on sub-groups from the studies.
- 7 2 95% CI crosses 1 decision making threshold (0.60 to 0.90)
- 8 3 95% CI crosses 2 decision making thresholds (0.60 to 0.90)

9

1

2 **Table 8: Ultrasound - uterosacral ligaments [deep and superficial depth]**

No of studies	Study details	No of participants	Diagnostic accuracy estimate (95% CI)	Risk of bias	Inconsistency	Indirectness	Imprecision	Quality of evidence
Transvaginal US – uterosacral ligaments (deep depth) (surgery from 2 weeks to 1 year after US)								
6 (Alborzi 2018; Barra 2021b; Kamkarfar 2022; Roditis 2023; Ros 2021; Zhang 2019)	Population: Women who had or were due to have a transvaginal scan before surgery for deep endometriosis	N=1146	Sensitivity: 0.86 (0.70 to 0.95)	No serious risk of bias	Serious ¹	No serious indirectness	Serious ²	LOW
			Specificity: 0.90 (0.82 to 0.95)	No serious risk of bias	Serious ¹	No serious indirectness	Serious ²	MODERATE
Transvaginal US – uterosacral ligaments (deep and superficial depth) (timing of imaging tests not reported)								
1 (Bratila 2016)	Population: Women who were due to have a transvaginal scan before surgery for endometriosis	N=204	Sensitivity: 0.7 (0.35 to 0.93)	No serious risk of bias	No serious inconsistency	No serious indirectness	Very serious ³	LOW
			Specificity: 0.95 (0.91 to 0.98)	No serious risk of bias	No serious inconsistency	No serious indirectness	No serious imprecision	HIGH
Transvaginal US – right uterosacral ligament (deep depth) (surgery from 1 to 3 months after US)⁴								
1 (Alborzi 2023)	Population: Women who had or were due to have a transvaginal scan before surgery for deep endometriosis	N=555	Sensitivity: 0.53 (0.48 to 0.58)	No serious risk of bias	Very serious ⁵	No serious indirectness	No serious imprecision	LOW
1 (Di Giovanni 2022)		N=93	Sensitivity: 1 (0.95 to 1)	No serious risk of bias		No serious indirectness	No serious imprecision	LOW
1 (El-Maadawy 2021)		N=101	Sensitivity: 0.84 (0.69 to 0.93)	No serious risk of bias		No serious indirectness	Serious ²	VERY LOW
1 (Zannoni 2017)		N=47	Sensitivity: 0.00 (0.00 to 0.34)	No serious risk of bias		No serious indirectness	No serious imprecision	LOW

No of studies	Study details	No of participants	Diagnostic accuracy estimate (95% CI)	Risk of bias	Inconsistency	Indirectness	Imprecision	Quality of evidence
4 (Alborzi 2023; Di Giovanni 2022; El-Maadawy 2021; Zannoni 2017)	Population: Women who had or were due to have a transvaginal scan before surgery for deep endometriosis	N=796	Specificity: 0.93 (0.68 to 0.99)	No serious risk of bias	No serious inconsistency	No serious indirectness	Serious ²	MODERATE
Transvaginal US – left uterosacral ligament (deep depth) (surgery from 1 to 3 months after US)⁴								
1 (Di Giovanni 2022)	Population: Women who had or were due to have a transvaginal scan before surgery for deep endometriosis	N=93	Sensitivity: 0.97 (0.90 to 1)	No serious risk of bias	Very serious ⁵	No serious indirectness	No serious imprecision	LOW
1 (El-Maadawy 2021)		N=101	Sensitivity: 0.80 (0.65 to 0.91)	No serious risk of bias		No serious indirectness	Serious ²	VERY LOW
1 (Zannoni 2017)		N=47	Sensitivity: 0.26 (0.09 to 0.51)	No serious risk of bias		No serious indirectness	No serious imprecision	LOW
3 (Di Giovanni 2022; El-Maadawy 2021; Zannoni 2017)		N=241	Specificity: 0.92 (0.51 to 1)	No serious risk of bias	Serious ¹	No serious indirectness	Very serious ³	VERY LOW
Transrectal US – uterosacral ligaments (deep depth) (timing of imaging tests not reported)								
1 (Alborzi 2018)	Population: Women who were due to have a transvaginal scan before surgery for deep endometriosis	N=317	Sensitivity: 0.83 (0.76 to 0.88)	No serious risk of bias	No serious inconsistency	No serious indirectness	No serious imprecision	HIGH
			Specificity: 0.90 (0.84 to 0.94)	No serious risk of bias	No serious inconsistency	No serious indirectness	Serious ²	MODERATE
Transabdominal US – uterosacral ligaments (deep depth) (timing of imaging tests not reported)								
1 (Puri 2022)	Population: Women who were	N=40	Sensitivity: 0.25 (0.01 to 0.81)	Serious ⁶	No serious inconsistency	No serious indirectness	Serious ²	LOW

No of studies	Study details	No of participants	Diagnostic accuracy estimate (95% CI)	Risk of bias	Inconsistency	Indirectness	Imprecision	Quality of evidence
	due to have a transvaginal scan before surgery for deep endometriosis		Specificity: 0.97 (0.85 to 1)	Serious ⁶	No serious inconsistency	No serious indirectness	Serious ²	LOW
Transvaginal and transrectal US – right uterosacral ligament (deep depth) (timing of imaging tests not reported)								
1 (Asgari 2022)	Population: Women who had a transvaginal scan before surgery for deep endometriosis	N=119	Sensitivity: 0.64 (0.50 to 0.76)	No serious risk of bias	No serious inconsistency	No serious indirectness	Serious ²	MODERATE
			Specificity: 0.75 (0.63 to 0.85)	No serious risk of bias	No serious inconsistency	No serious indirectness	No serious imprecision	HIGH
Transvaginal and transrectal US – left uterosacral ligament (deep depth) (timing of imaging tests not reported)								
1 (Asgari 2022)	Population: Women who had a transvaginal scan before surgery for deep endometriosis	N=119	Sensitivity: 0.55 (0.42 to 0.68)	No serious risk of bias	No serious inconsistency	No serious indirectness	Serious ²	MODERATE
			Specificity: 0.75 (0.62 to 0.86)	No serious risk of bias	No serious inconsistency	No serious indirectness	No serious imprecision	HIGH

1 CI: confidence interval; US: ultrasound
 2 1 Serious heterogeneity (assessed by visual inspection of point estimates and confidence intervals). Random effect analysis used in Winbugs analysis. Sub-group analysis could
 3 not be conducted as there was no sufficient information on sub-groups from the studies.
 4 2 95% CI crosses 1 decision making threshold (0.60 to 0.90)
 5 3 95% CI crosses 2 decision making thresholds (0.60 to 0.90)
 6 4 Sensitivity was not pooled due to very serious heterogeneity. Sensitivity for individual studies reported.
 7 5 Very serious heterogeneity (assessed by visual inspection of point estimates and confidence intervals). Meta-analysis was not performed where there was very serious
 8 heterogeneity.
 9 6 Serious risk of bias in the evidence contributing to outcomes as per QUADAS-2

10

1 **Table 9: Ultrasound – pouch of Douglas [deep and superficial depth]**

No of studies	Study details	No of participants	Diagnostic accuracy estimate (95% CI)	Risk of bias	Inconsistency	Indirectness	Imprecision	Quality of evidence
Transvaginal US – pouch of Douglas (deep depth) (timing of imaging tests not reported)								
1 (Goncalves 2021)	Population: Women who were due to have surgery for endometriosis	N=120	Sensitivity: 0.84 (0.72 to 0.92)	No serious risk of bias	No serious inconsistency	No serious indirectness	Serious ¹	MODERATE
			Specificity: 0.89 (0.79 to 0.95)	No serious risk of bias	No serious inconsistency	No serious indirectness	Serious ¹	MODERATE
Transvaginal US – pouch of Douglas (deep and superficial depth) (timing of imaging tests not reported)								
1 (Bratila 2016)	Population: Women who were due to have a transvaginal scan before surgery for endometriosis	N=214	Sensitivity: 0.81 (0.67 to 0.91)	No serious risk of bias	No serious inconsistency	No serious indirectness	Serious ¹	MODERATE
			Specificity: 0.93 (0.88 to 0.96)	No serious risk of bias	No serious inconsistency	No serious indirectness	Serious ¹	MODERATE
Transvaginal and transrectal US – pouch of Douglas (deep depth) (timing of imaging tests not reported)								
1 (Asgari 2022)	Population: Women who had a transvaginal scan before surgery for deep endometriosis	N=119	Sensitivity: 0.75 (0.63 to 0.85)	No serious risk of bias	No serious inconsistency	No serious indirectness	No serious imprecision	HIGH
			Specificity: 0.69 (0.54 to 0.81)	No serious risk of bias	No serious inconsistency	No serious indirectness	Serious ¹	MODERATE

2 *CI: confidence interval; US: ultrasound*
3 *1 95% CI crosses 1 decision making threshold (0.60 to 0.90)*

4

5

6

7 **Table 10: Ultrasound – bladder [deep and superficial depth]**

No of studies	Study details	No of participants	Diagnostic accuracy estimate (95% CI)	Risk of bias	Inconsistency	Indirectness	Imprecision	Quality of evidence
Transvaginal US – bladder (deep depth) (surgery from 4 weeks to 1 year after US)								
6 (Alborzi 2018;	Population: Women	N=1003	Sensitivity: 0.78 (0.57 to 0.91)	No serious risk of	Serious ¹	No serious	Very serious ²	VERY LOW

No of studies	Study details	No of participants	Diagnostic accuracy estimate (95% CI)	Risk of bias	Inconsistency	Indirectness	Imprecision	Quality of evidence
Barra 2021a; Di Giovanni 2022; El-Maadawy 2021; Goncalves 2021; Reditis 2023)	who had or were due to have a transvaginal scan before surgery for deep endometriosis			bias		indirectness		
			Specificity: 0.99 (0.96 to 1)	No serious risk of bias	No serious inconsistency	No serious indirectness	No serious imprecision	HIGH
Transvaginal US – bladder (deep and superficial depth) (timing of imaging tests not reported)								
1 (Bratila 2016)	Population: Women who were due to have a transvaginal scan before surgery for endometriosis	N=204	Sensitivity: 0.67 (0.41 to 0.87)	No serious risk of bias	No serious inconsistency	No serious indirectness	Serious ³	MODERATE
			Specificity: 0.98 (0.95 to 1)	No serious risk of bias	No serious inconsistency	No serious indirectness	No serious imprecision	HIGH
Transvaginal US with 3D – bladder (deep depth) (surgery 8 weeks after US)								
1 (Barra 2021a)	Population: Women who were due to have a transvaginal scan before surgery for endometriosis	N=194	Sensitivity: 0.85 (0.69 to 0.95)	No serious risk of bias	No serious inconsistency	No serious indirectness	Serious ³	MODERATE
			Specificity: 0.9 (0.84 to 0.94)	No serious risk of bias	No serious inconsistency	No serious indirectness	Serious ³	MODERATE
Transrectal US – bladder (deep depth) (timing of imaging test not reported)								
1 (Alborzi 2018)	Population: Women who were due to have a transvaginal scan before surgery for deep endometriosis	N=317	Sensitivity: 1 (0.40 to 1)	No serious risk of bias	No serious inconsistency	No serious indirectness	Very serious ³	LOW
			Specificity: 1 (0.98 to 1)	No serious risk of bias	No serious inconsistency	No serious indirectness	No serious imprecision	HIGH

1 CI: confidence interval; US: ultrasound
 2 1 Serious heterogeneity (assessed by visual inspection of point estimates and confidence intervals). Random effect analysis used in Winbugs analysis. Sub-group analysis could
 3 not be conducted as there was no sufficient information on sub-groups from the studies
 4 2 95% CI crosses 2 decision making thresholds (0.60 and 0.90)
 5 3 95% CI crosses 1 decision making threshold (0.60 and 0.90)

6

1 **Table 11: Ultrasound - ureters [deep depth]**

No of studies	Study details	No of participants	Diagnostic accuracy estimate (95% CI)	Risk of bias	Inconsistency	Indirectness	Imprecision	Quality of evidence
Transvaginal US – ureter (deep depth) (surgery 3 months after scan)								
1 (DiGiovanni 2022)	Population: Women were due to have a transvaginal scan before surgery for deep endometriosis	N=93	Sensitivity: 0.77 (0.46 to 0.95)	No risk of bias	No serious inconsistency	No serious indirectness	Very serious ¹	LOW
			Specificity: 0.95 (0.88 to 0.99)	No risk of bias	No serious inconsistency	No serious indirectness	Serious ²	MODERATE
Transvaginal US – right ureter (deep depth) (surgery 4 weeks after scan)								
1 (El-Maadawy 2021)	Population: Women who were due to have a transvaginal scan before surgery for endometriosis	N=101	Sensitivity: 0.60 (0.15 to 0.95)	No risk of bias	No serious inconsistency	No serious indirectness	Very serious ¹	LOW
			Specificity: 0.99 (0.94 to 1)	No risk of bias	No serious inconsistency	No serious indirectness	No serious imprecision	HIGH
1 (Zannoni 2017)		N=47	Sensitivity: 0.10 (0 to 0.45)	No risk of bias	No serious inconsistency	No serious indirectness	No serious imprecision	HIGH
			Specificity: 0.95 (0.82 to 0.99)	No risk of bias	No serious inconsistency	No serious indirectness	Serious ²	MODERATE
Transvaginal US – left ureter (deep depth) (surgery 4 weeks after scan)								
1 (El-Maadawy 2021)	Population: Women who were due to have a transvaginal scan before surgery for endometriosis	N=101	Sensitivity: 0.50 (0.07 to 0.93)	No risk of bias	No serious inconsistency	No serious indirectness	Very serious ¹	LOW
			Specificity: 0.99 (0.94 to 1)	No risk of bias	No serious inconsistency	No serious indirectness	No serious imprecision	HIGH
1 (Zannoni 2017)		N=47	Sensitivity: 0.29 (0.11 to 0.52)	No risk of bias	No serious inconsistency	No serious indirectness	No serious imprecision	HIGH
			Specificity: 0.96 (0.80 to 1)	No risk of bias	No serious inconsistency	No serious indirectness	Serious ¹	MODERATE
Transvaginal and transabdominal US – ureters (deep depth) (surgery 3 months after scan)								
1 (Montanari 2022)	Population: Women who were due to have a transvaginal scan before surgery for deep endometriosis	N=745	Sensitivity: 0.78 (0.63 to 0.89) ³	No risk of bias	No serious inconsistency	No serious indirectness	No serious imprecision	HIGH
			Specificity: 1 (0.99 to 1) ³	No risk of bias	No serious	No serious	No serious	HIGH

No of studies	Study details	No of participants	Diagnostic accuracy estimate (95% CI)	Risk of bias	Inconsistency	Indirectness	Imprecision	Quality of evidence
					inconsistency	indirectness	imprecision	

- 1 *CI: confidence interval; US: ultrasound*
- 2 *1 95% CI crosses 2 decision making thresholds (0.60 to 0.90)*
- 3 *2 95 % CI crosses 1 decision making threshold (0.60 to 0.90)*
- 4 *3 Sensitivity and specificity taken from the study as 2x2 data not available*

5 **Table 12: Ultrasound - multiple sites [deep and superficial depth]**

No of studies	Study details	No of participants	Diagnostic accuracy estimate (95% CI)	Risk of bias	Inconsistency	Indirectness	Imprecision	Quality of evidence
Transvaginal US – multiple sites (right and left USL, right and left endometriomas, rectal wall, vagina, bladder) (deep depth) (timing of imaging tests not reported)								
1 (Alborzi 2018)	Population: Women who were due to have a transvaginal scan before surgery for deep endometriosis	N=317	Sensitivity: 0.83 (0.78 to 0.88)	No serious risk of bias	No serious inconsistency	No serious indirectness	No serious imprecision	HIGH
			Specificity: 0.46 (0.34 to 0.59)	No serious risk of bias	No serious inconsistency	No serious indirectness	No serious imprecision	HIGH
Transvaginal US – multiple sites (sites not specified) (deep and superficial depth) (surgery 4 months after US)								
1 (Shahbazi 2022)	Population: Women who were due to have a transvaginal scan before surgery for endometriosis	N=20	Sensitivity: 0.73 (0.39 to 0.94)	Serious ¹	No serious inconsistency	No serious indirectness	Very serious ²	VERY LOW
			Specificity: 1 (0.66 to 1)	Serious ¹	No serious inconsistency	No serious indirectness	Serious ³	LOW

- 6 *CI: confidence interval; USL: uterosacral ligaments; US: ultrasound*
- 7 *1 Serious risk of bias in the evidence contributing to outcomes as per QUADAS-2*
- 8 *2 95% CI crosses 2 decision making thresholds (0.60 to 0.90)*
- 9 *3 95% CI crosses 1 decision making threshold (0.60 to 0.90)*

10 **Magnetic Resonance Imaging (MRI)**

11 **Table 13: Magnetic Resonance Imaging – endometrioma**

No of studies	Study details	No of participants	Diagnostic accuracy estimate (95% CI)	Risk of bias	Inconsistency	Indirectness	Imprecision	Quality of evidence
MRI - with contrast – endometrioma (timing of imaging tests not reported)								
1 (Siddiqui 2021)	Population: Women due to have an MRI scan before surgery for	N=170	Sensitivity: 0.87 (0.78 to 0.93)	No risk of bias	No serious inconsistency	No serious indirectness	Serious ¹	MODERATE

No of studies	Study details	No of participants	Diagnostic accuracy estimate (95% CI)	Risk of bias	Inconsistency	Indirectness	Imprecision	Quality of evidence
	endometriosis		Specificity: 0.82 (0.71 to 0.90)	No risk of bias	No serious inconsistency	No serious indirectness	Serious ¹	MODERATE
MRI – type unspecified – right endometrioma (timing of imaging tests not reported)								
1 (Alborzi 2023)	Population: Women due to have, or had, an MRI scan before surgery for endometriosis	N=555	Sensitivity: 0.57 (0.51 to 0.62)	No risk of bias	No serious inconsistency	No serious indirectness	Serious ¹	MODERATE
			Specificity: 0.97 (0.94 to 0.99)	No risk of bias	No serious inconsistency	No serious indirectness	No serious imprecision	HIGH
1 (Puri 2022) ²		N=40	Sensitivity: 0.94 (0.79 to 0.99)	Serious ³	No serious inconsistency	No serious indirectness	Serious ¹	LOW
			Specificity: 0.88 (0.47 to 1)	Serious ³	No serious inconsistency	No serious indirectness	Very serious ⁴	VERY LOW

- 1 *CI: confidence interval; MRI: magnetic resonance imaging*
2 *1 95% CI crosses 1 decision making threshold (0.60 to 0.90)*
3 *2 Type of MRI (that is with or without contrast) was unspecified for Puri 2022)*
4 *3 Serious risk of bias in the evidence contributing to outcomes as per QUADAS-2*
5 *4 95% CI crosses 2 decision making thresholds (0.60 to 0.90)*

6

7 **Table 14: Magnetic Resonance Imaging – vagina [deep depth]**

No of studies	Study details	No of participants	Diagnostic accuracy estimate (95% CI)	Risk of bias	Inconsistency	Indirectness	Imprecision	Quality of evidence
MRI - type unspecified¹ – vagina (deep depth) (surgery 2 to 12 months after MRI)								
1 (Roditis 2023)	Population: Women who had an MRI scan before surgery for endometriosis	N=178	Sensitivity: 0.56 (0.38 to 0.72)	No risk of bias	No serious inconsistency	No serious indirectness	Serious ²	MODERATE
			Specificity: 0.85 (0.77 to 0.90)	No risk of bias	No serious inconsistency	No serious indirectness	Serious ²	MODERATE

- 8 *CI: confidence interval; MRI: magnetic resonance imaging*
9 *1 Type of MRI (that is with or without contrast) was unspecified*
10 *2 95% CI crosses 1 decision making threshold (0.60 to 0.90)*

11

1 **Table 15: Magnetic Resonance Imaging – rectosigmoid [deep depth]**

No of studies	Study details	No of participants	Diagnostic accuracy estimate (95% CI)	Risk of bias	Inconsistency	Indirectness	Imprecision	Quality of evidence
MRI - with contrast or type unspecified – rectosigmoid (deep depth) (up to 12 months after MRI)¹								
1 (Alborzi 2018)	Population: Women due to have, or had, an MRI scan before surgery for endometriosis	N=317	Sensitivity: 0.77 (0.63 to 0.87)	No risk of bias	Very serious ²	No serious indirectness	No serious imprecision	LOW
1 (Alborzi 2023)		N=556	Sensitivity: 0.51 (0.47 to 0.55)	No risk of bias		No serious indirectness	No serious imprecision	LOW
1 (Hausmann 2021)		N=43	Sensitivity: 0.96 (0.78 to 1)	No risk of bias		No serious indirectness	Serious ³	VERY LOW
1 (Roditis 2023) ⁴		N=178	Sensitivity: 0.87 (0.76 to 0.94)	No risk of bias		No serious indirectness	Serious ³	VERY LOW
1 (Widschwendter 2022)		N=80	Sensitivity: 0.50 (0.28 to 0.72)	No risk of bias		No serious indirectness	Serious ³	VERY LOW
5 (Alborzi 2018; Alborzi 2023; Hausmann 2021; Roditis 2023 ³ ; Widschwendter 2022)		N=1174	Specificity: 0.92 (0.81 to 0.97)	No risk of bias	No serious inconsistency	No serious indirectness	Serious ³	MODERATE

- 2 *CI: confidence interval; MRI: magnetic resonance imaging*
 3 *1 Sensitivity was not pooled due to very serious heterogeneity. Sensitivity for individual studies reported.*
 4 *2 Very serious heterogeneity (assessed by visual inspection of point estimates and confidence intervals).*
 5 *3 95% CI crosses 1 decision making threshold (0.60 to 0.90)*
 6 *4 Type of MRI (that is with or without contrast) was unspecified for Roditis 2023*

7

8 **Table 16: Magnetic Resonance Imaging – rectovaginal septum [deep depth]**

No of studies	Study details	No of participants	Diagnostic accuracy estimate (95% CI)	Risk of bias	Inconsistency	Indirectness	Imprecision	Quality of evidence
MRI – with contrast - rectovaginal septum (deep depth) (timing of tests not reported)								
1 (Alborzi 2018)	Population: Women due to have, or had, an MRI scan before surgery for endometriosis	N=317	Sensitivity: 0.73 (0.57 to 0.85)	No risk of bias	No serious inconsistency	No serious indirectness	Serious ¹	MODERATE
			Specificity: 0.95 (0.92 to 0.97)	No risk of bias	No serious inconsistency	No serious indirectness	No serious imprecision	HIGH

No of studies	Study details	No of participants	Diagnostic accuracy estimate (95% CI)	Risk of bias	Inconsistency	Indirectness	Imprecision	Quality of evidence
1 (Chen 2019)		N=29	Sensitivity: 0.90 (0.70 to 0.99)	No risk of bias	No serious inconsistency	No serious indirectness	Serious ¹	MODERATE
			Specificity: 0.88 (0.47 to 1.00)	No risk of bias	No serious inconsistency	No serious indirectness	Very serious ²	LOW

1 *CI: confidence interval; MRI: magnetic resonance imaging*
2 *1 95% CI crosses 1 decision making threshold (0.60 to 0.90)*
3 *2 95 % CI crosses 2 decision making thresholds (0.60 to 0.90)*

4
5

6 **Table 17: Magnetic Resonance Imaging – uterosacral ligaments [deep depth]**

No of studies	Study details	No of participants	Diagnostic accuracy estimate (95% CI)	Risk of bias	Inconsistency	Indirectness	Imprecision	Quality of evidence
MRI – with contrast or type unspecified - uterosacral ligaments (deep depth) (surgery up to 12 months after scan)¹								
1 (Alborzi 2018)	Population: Women due to have, or had, an MRI scan before surgery for endometriosis	N=317	Sensitivity: 0.64 (0.55 to 0.71)	No risk of bias	Very serious ²	No serious indirectness	Serious ³	VERY LOW
1 (Alborzi 2023)		N=555	Sensitivity: 0.39 (0.34 to 0.44)	No risk of bias		No serious indirectness	No serious imprecision	LOW
1 (Puri 2022) ⁴		N=40	Sensitivity: 0.75 (0.19 to 0.99)	No risk of bias		No serious indirectness	Very serious ⁵	VERY LOW
1 (Roditis 2023) ⁴		N=178	Sensitivity: 0.94 (0.89 to 0.97)	No risk of bias		No serious indirectness	Serious ³	VERY LOW
1 (Widschwendter 2022)		N=80	Sensitivity: 0.57 (0.42 to 0.72)	No risk of bias		No serious indirectness	Serious ³	VERY LOW
5 (Alborzi 2018; Alborzi 2023; Puri 2022; Roditis 2023; Widschwendter 2022) ⁴		N=1170	Specificity: 0.88 (0.69 to 0.96)	No risk of bias	Serious ⁶	No serious indirectness	Serious ³	LOW

7 *CI: confidence interval; MRI: magnetic resonance imaging*
8 *1 Sensitivity not pooled due to very serious heterogeneity. Sensitivity for individual studies reported*
9 *2 Very serious heterogeneity (assessed by visual inspection of forest plots and confidence intervals).*
10 *3 95% CI crosses 1 decision making threshold*

4 Type of MRI (that is with or without contrast) was unspecified for Puri 2022 and Roditis 2023

5 95% CI crosses 2 decision making thresholds⁶ Serious heterogeneity (assessed by visual inspection of forest plots and confidence intervals). Random effect analysis used in

3 Winbugs analysis. Sub-group analysis could not be conducted as there was no sufficient information on sub-groups from the studies

5 **Table 18: Magnetic Resonance Imaging – bladder [deep depth]**

No of studies	Study details	No of participants	Diagnostic accuracy estimate (95% CI)	Risk of bias	Inconsistency	Indirectness	Imprecision	Quality of evidence
MRI – with contrast or type unspecified - bladder (deep depth) (timing of test not reported)								
1 (Alborzi 2018)	Population: Women due to have, or had, an MRI scan before surgery for endometriosis	N=317	Sensitivity: 1 (0.40 to 1)	No risk of bias	No serious inconsistency	No serious indirectness	Very serious ²	LOW
			Specificity: 1 (0.98 to 1)	No risk of bias	No serious inconsistency	No serious indirectness	No serious imprecision	HIGH
1 (Roditis 2023) ¹		N=178	Sensitivity: 0.85 (0.55 to 0.98)	No risk of bias	No serious inconsistency	No serious indirectness	Very serious ²	LOW
			Specificity: 0.99 (0.97 to 1)	No risk of bias	No serious inconsistency	No serious indirectness	No serious imprecision	HIGH

6 CI: confidence interval; MRI: magnetic resonance imaging

7 1 Type of MRI (that is with or without contrast) was unspecified for Roditis 2023

8 2 95% CI crosses 2 decision making thresholds (0.60 to 0.90)

10 **Table 19: Magnetic Resonance Imaging – multiple sites [deep and superficial depth]**

No of studies	Study details	No of participants	Diagnostic accuracy estimate (95% CI)	Risk of bias	Inconsistency	Indirectness	Imprecision	Quality of evidence
MRI -with contrast – multiple sites (including ovary, vagina, rectovaginal space, rectum) (deep depth) (surgery 12 months after scan)								
1 (Harth 2023)	Population: Women who had an MRI scan before surgery for endometriosis	N=160	Sensitivity: 0.42 (0.26 to 0.59)	No risk of bias	No serious inconsistency	No serious indirectness	Serious ¹	MODERATE
			Specificity: 1 (0.97 to 1)	No risk of bias	No serious inconsistency	No serious indirectness	No serious imprecision	HIGH
MRI – type unspecified - multiple sites (sites not reported) (deep and superficial depth) (surgery 2 months after scan)								

No of studies	Study details	No of participants	Diagnostic accuracy estimate (95% CI)	Risk of bias	Inconsistency	Indirectness	Imprecision	Quality of evidence
1 (Shahbazi 2022) ²	Population: Women who were due to have an MRI scan before surgery for endometriosis	N=14	Sensitivity: 0.78 (0.40 to 0.97)	Serious ³	No serious inconsistency	No serious indirectness	Very serious ⁴	VERY LOW
			Specificity: 0.80 (0.28 to 0.99)	Serious ³	No serious inconsistency	No serious indirectness	Very serious ⁴	VERY LOW

- 1 *CI: confidence interval; MRI: magnetic resonance imaging*
- 2 *1 95% CI crosses 1 decision making threshold (0.60 to 0.90)*
- 3 *2 Type of MRI (that is with or without contrast) was unspecified*
- 4 *3 Serious risk of bias in the evidence contributing to outcomes as per QUADAS-2*
- 5 *4 95% CI crosses 2 decision making thresholds (0.60 to 0.90)*

6

7 **Biomarkers**

8 **Table 20: CA-125 – multiple sites [deep and superficial depth]**

No of studies	Study details	No of participants	Diagnostic accuracy estimate (95% CI)	Risk of bias	Inconsistency	Indirectness	Imprecision	Quality of evidence
CA-125 – multiple sites (deep and superficial depth) (timing of test not reported)								
1 (Rokhgireh 2020)	Population: Women who were due to have an MRI scan before surgery for endometriosis	N=84	Sensitivity: 0.70 (0.55 to 0.83)	No risk of bias	No serious inconsistency	No serious indirectness	Serious ¹	MODERATE
			Specificity: 0.86 (0.71 to 0.95)	No risk of bias	No serious inconsistency	No serious indirectness	Serious ¹	MODERATE

- 9 *CI: confidence interval*
- 10 *1 95% CI crosses 1 decision making threshold (0.60 to 0.90)*

11 **Surgery**

12 **Table 21: Laparoscopy without histopathology – multiple sites [deep and superficial depth]**

No of studies	Study details	No of participants	Diagnostic accuracy estimate (95% CI)	Risk of bias	Inconsistency	Indirectness	Imprecision	Quality of evidence
---------------	---------------	--------------------	---------------------------------------	--------------	---------------	--------------	-------------	---------------------

No of studies	Study details	No of participants	Diagnostic accuracy estimate (95% CI)	Risk of bias	Inconsistency	Indirectness	Imprecision	Quality of evidence
Laparoscopy – multiple sites (including endometrioma, posterior vaginal fornix, rectovaginal septum, uterosacral ligaments, rectum, bladder) (deep and superficial depth) (index tests and reference standard conducted at the same time)								
1 (Gratton 2022)	Population: Women who had a laparoscopy and biopsy for endometriosis	N=96	Sensitivity: 0.90 (0.81 to 0.96)	No risk of bias	No serious inconsistency	No serious indirectness	Serious ¹	MODERATE
			Specificity: 0.40 (0.21 to 0.61)	No risk of bias	No serious inconsistency	No serious indirectness	Serious ¹	MODERATE

1 *CI: confidence interval*
2 *1 95% CI crosses 1 decision making threshold (0.60 to 0.90)*

3

4 **Combination of tests**

5 **Table 22: US and MRI – ovary [deep depth]**

No of studies	Study details	No of participants	Diagnostic accuracy estimate (95% CI)	Risk of bias	Inconsistency	Indirectness	Imprecision	Quality of evidence
US (TV or TA) and MRI (unspecified type) – ovary (deep depth) (surgery performed 30 days after scan)								
1 (Barcellos 2016) ¹	Population: Women who had undergone surgery and imaging for endometriosis	N=46	Sensitivity: 0.90 (0.74 to 0.98)	No risk of bias	No serious inconsistency	No serious indirectness	Serious ²	MODERATE
			Specificity: 0.80 (0.52 to 0.96)	No risk of bias	No serious inconsistency	No serious indirectness	Very serious ³	LOW

6 *CI: confidence interval; MRI: magnetic resonance imaging; TA: transabdominal; TV: transvaginal; US: ultrasound*
7 *1 Type of MRI (that is with or without contrast) was unspecified*
8 *2 95% CI crosses 1 decision making threshold (0.60 to 0.90)*
9 *3 95% CI crosses 2 decision making thresholds (0.60 to 0.90)*

10 **Table 23: US and MRI – vagina [deep depth]**

No of studies	Study details	No of participants	Diagnostic accuracy estimate (95% CI)	Risk of bias	Inconsistency	Indirectness	Imprecision	Quality of evidence
US (TV or TA) and MRI (unspecified type) – vagina (deep depth) (surgery performed up to 12 months after scan)								
1 (Roditis 2023) ¹	Population: Women who had undergone surgery and imaging	N=178	Sensitivity: 0.31 (0.16 to 0.48)	No risk of bias	No serious inconsistency	No serious indirectness	No serious imprecision	HIGH

No of studies	Study details	No of participants	Diagnostic accuracy estimate (95% CI)	Risk of bias	Inconsistency	Indirectness	Imprecision	Quality of evidence
	for endometriosis		Specificity: 0.94 (0.89 to 0.98)	No risk of bias	No serious inconsistency	No serious indirectness	Serious ²	MODERATE

1 *CI: confidence interval; MRI: magnetic resonance imaging; TA: transabdominal; TV: transvaginal; US: ultrasound*

2 *1 Type of MRI (that is with or without contrast) was unspecified*

3 *2 95% CI crosses 1 decision making threshold (0.60 to 0.90)*

4 **Table 24: US and MRI – rectosigmoid [deep depth]**

No of studies	Study details	No of participants	Diagnostic accuracy estimate (95% CI)	Risk of bias	Inconsistency	Indirectness	Imprecision	Quality of evidence
US (TV or TA) and MRI (unspecified type) – rectosigmoid (deep depth) (surgery performed up to 12 months after scan)								
1 (Roditis 2023) ¹	Population: Women who had undergone surgery and imaging for endometriosis	N=178	Sensitivity: 0.77 (0.65 to 0.87)	No risk of bias	No serious inconsistency	No serious indirectness	No serious imprecision	HIGH
			Specificity: 0.99 (0.95 to 1)	No risk of bias	No serious inconsistency	No serious indirectness	No serious imprecision	HIGH

5 *CI: confidence interval; MRI: magnetic resonance imaging; TA: transabdominal; TV: transvaginal; US: ultrasound*

6 *1 Type of MRI (that is with or without contrast) was unspecified*

7

8

9 **Table 25: US and MRI – rectovaginal septum [deep depth]**

No of studies	Study details	No of participants	Diagnostic accuracy estimate (95% CI)	Risk of bias	Inconsistency	Indirectness	Imprecision	Quality of evidence
US (TV or TA) and MRI (unspecified type) – rectovaginal septum (deep depth) (surgery performed 30 days after scan)								
1 (Barcellos 2016) ¹	Population: Women who had undergone surgery and imaging for endometriosis	N=46	Sensitivity: 1 (0.16 to 1)	No risk of bias	No serious inconsistency	No serious indirectness	Very serious ²	LOW
			Specificity: 1 (0.92 to 1)	No risk of bias	No serious inconsistency	No serious indirectness	No serious imprecision	HIGH

10 *CI: confidence interval; MRI: magnetic resonance imaging; TA: transabdominal; TV: transvaginal; US: ultrasound*

11 *1 Type of MRI (that is with or without contrast) was unspecified*

12 *2 95% CI crosses 2 decision making thresholds (0.60 to 0.90)*

13

1 **Table 26: US and MRI – uterosacral ligaments [deep depth]**

No of studies	Study details	No of participants	Diagnostic accuracy estimate (95% CI)	Risk of bias	Inconsistency	Indirectness	Imprecision	Quality of evidence
US (TV or TA) and MRI (unspecified type) – uterosacral ligaments (deep depth) (surgery performed from 30days to 12 months after scan)								
1 (Barcellos 2016) ¹	Population: Women who had undergone surgery and imaging for endometriosis	N=46	Sensitivity: 0.97 (0.87 to 1)	No risk of bias	No serious inconsistency	No serious indirectness	Serious ²	MODERATE
			Specificity: 0.57 (0.18 to 0.90)	No risk of bias	No serious inconsistency	No serious indirectness	Very serious ³	LOW
1 (Roditis 2023) ¹		N=178	Sensitivity: 0.75 (0.67 to 0.81)	No risk of bias	No serious inconsistency	No serious indirectness	No serious imprecision	HIGH
			Specificity: 0.89 (0.52 to 1)	No risk of bias	No serious inconsistency	No serious indirectness	Very serious ³	LOW

2 *CI: confidence interval; MRI: magnetic resonance imaging; TA: transabdominal; TV: transvaginal; US: ultrasound*

3 *1 Type of MRI (that is with or without contrast) was unspecified*

4 *2 95% CI crosses 1 decision making threshold (0.60 to 0.90)*

5 *3 95% CI crosses 2 decision making thresholds (0.60 to 0.90)*

6 **Table 27: US and MRI – intestine [deep depth]**

No of studies	Study details	No of participants	Diagnostic accuracy estimate (95% CI)	Risk of bias	Inconsistency	Indirectness	Imprecision	Quality of evidence
US (TV or TA) and MRI (unspecified type) – intestine (small or large not specified) (deep depth) (surgery performed 30 days after scan)								
1 (Barcellos 2016) ¹	Population: Women who had undergone surgery and imaging for endometriosis	N=46	Sensitivity: 0.92 (0.74 to 0.99)	No risk of bias	No serious inconsistency	No serious indirectness	Serious ²	MODERATE
			Specificity: 0.95 (0.76 to 1)	No risk of bias	No serious inconsistency	No serious indirectness	Serious ²	MODERATE

7 *CI: confidence interval; MRI: magnetic resonance imaging; TA: transabdominal; TV: transvaginal; US: ultrasound*

8 *1 95% CI crosses 1 decision making threshold (0.60 to 0.90)*

9 **Table 28: US and MRI – bladder [deep depth]**

No of studies	Study details	No of participants	Diagnostic accuracy estimate (95% CI)	Risk of bias	Inconsistency	Indirectness	Imprecision	Quality of evidence
US (TV or TA) and MRI (unspecified type) – bladder (deep depth) (surgery performed from 30 days to 12 months after scan)								
1 (Barcellos 2016)	Population: Women who had undergone surgery and imaging	N=46	Sensitivity: 1 (0.54 to 1)	No risk of bias	No serious inconsistency	No serious indirectness	Very serious ¹	LOW

No of studies	Study details	No of participants	Diagnostic accuracy estimate (95% CI)	Risk of bias	Inconsistency	Indirectness	Imprecision	Quality of evidence
	for endometriosis		Specificity: 1 (0.91 to 1)	No risk of bias	No serious inconsistency	No serious indirectness	No serious imprecision	HIGH
1 (Roditis 2023)		N=178	Sensitivity: 0.62 (0.32 to 0.86)	No risk of bias	No serious inconsistency	No serious indirectness	Serious ²	MODERATE
			Specificity: 0.99 (0.97 to 1)	No risk of bias	No serious inconsistency	No serious indirectness	No serious imprecision	HIGH

1 *CI: confidence interval; MRI: magnetic resonance imaging; TA: transabdominal; TV: transvaginal; US: ultrasound*

2 *1 95% CI crosses 1 decision making threshold (0.60 to 0.90)*

3 *2 95% CI crosses 2 decision making thresholds (0.60 to 0.90)*

4

5

6

7

8

9

10

11

12

13

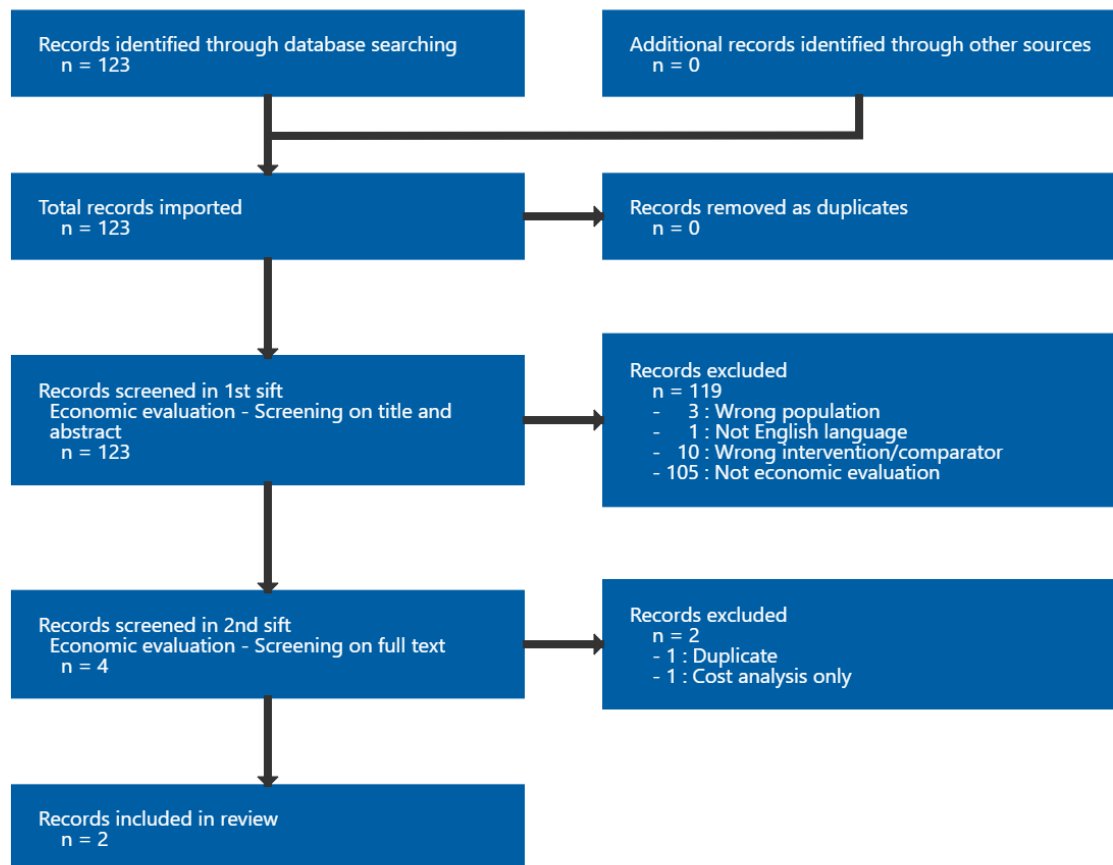
1 Appendix G Economic evidence study selection

2 Study selection for: What is the accuracy of the following tests in diagnosing 3 endometriosis:

- 4 • imaging
- 5 • biomarkers
- 6 • surgical diagnosis (open surgery or laparoscopic surgery)?

7 Of 123 studies, 4 were assessed at full text level and of those 2 were included for this review.

Figure 11: Study selection flow chart



8

9

10

1 Appendix H Economic evidence tables

2 Economic evidence tables for review question: What is the accuracy of the following tests in diagnosing endometriosis:

- 3 • imaging
4 • biomarkers
5 • surgical diagnosis (open surgery or laparoscopic surgery)?

6 Table 29: Economic evidence tables for

Study country and type	Intervention and comparator	Study population, design and data sources	Costs and outcomes (descriptions and values)	Results	Comments
<p>Author and year: Khan 2018</p> <p>Country: UK</p> <p>Type of economic analysis: CUA</p> <p>Source of funding: Health Technology Assessment programme of NIHR</p>	<p>Intervention in detail: Pelvic MRI (12 ROC cut-off values)</p> <p>Diagnostic laparoscopy (12 ROC cut-off values)</p> <p>Comparator in detail: No testing</p> <p>A total of 25 strategies</p>	<p>Population characteristics: Women with chronic pelvic pain</p> <p>Modelling approach/alongside an RCT</p> <p>Source of baseline data: MEDAL study</p> <p>Source of effectiveness data: MEDAL study</p> <p>Source of cost data: Nodes of decision tree developed for the</p>	<p>Costs: NHS perspective</p> <p>Restricted to non-dominated strategies</p> <p>Mean cost per participant:</p> <p>Intervention: Laparoscopy (cut-off value of 6) £1,793</p> <p>Control: No testing £166</p> <p>Difference: £1,627</p>	<p>ICERs:</p> <p>Laparoscopy (cut-off value of 6) relative to no testing: £116,618 per QALY</p> <p>Probability of being cost effective: No testing has approximately 70% probability of being cost-effective at a cost-effectiveness threshold of £20,000 per QALY</p> <p>Sensitivity analysis:</p> <p><i>3-year time horizon:</i> Laparoscopy (cut-off</p>	<p>Currency: GBP</p> <p>Cost year: 2013</p> <p>Time horizon: 6-months timeframe</p> <p>Discounting: N/A</p> <p>Applicability: Applicable</p> <p>Limitations: Potentially serious</p> <p>Other comments: The timeframe of 6</p>

Study country and type	Intervention and comparator	Study population, design and data sources	Costs and outcomes (descriptions and values)	Results	Comments
		<p>evaluation reflecting diagnostic and treatment pathways</p> <p>Source of unit cost data: NHS Reference Costs (2013–14) were used to attribute costs to the resource use.</p> <p>The Unit Costs of Health and Social Care (PSSRU 2014) were used for staff time costs</p>	<p>Primary measure of outcome: QALYs Elicited using EQ-5D-3L questionnaire</p> <p>Mean outcome per participant:</p> <p>Intervention: Laparoscopy (cut-off value of 6) 0.3235 QALYs</p> <p>Control: No testing 0.3095 QALYs</p> <p>Difference: 0.014 QALYs</p>	<p>value of 6) relative to no testing: £16,654 per QALY</p> <p>Other sensitivity analysis found that cost-effectiveness results were sensitive to the prevalence of structural causes among women with chronic pelvic pain</p>	<p>months reflected the period for data collection of health state utility data, but benefits of treatments will ordinarily be much longer lasting and therefore QALY gains from treatment will be under reported</p>
<p>Author and year: Ferrier 2023</p> <p>Country: France</p> <p>Type of economic analysis:</p>	<p>Intervention in detail Strategy II - Endotest®</p> <p>Strategy III – Ultrasound to detect endometrioma with Endotest® if negative</p>	<p>Population characteristics Women with chronic pelvic pain</p> <p>Modelling approach/alongside an RCT Decision tree model</p>	<p>Costs: Healthcare perspective</p> <p>Mean cost per correct diagnosis (cost per participant not reported): With Endotest®</p>	<p>ICERs: Strategy IV relative to Strategy I: -€896 (95% CI -€2,417 to -€184)</p> <p>Strategy III relative to Strategy IV: €473 (95% CI -€681)</p>	<p>Currency: Euros</p> <p>Cost year: 2022</p> <p>Time horizon: 1-year timeframe</p>

Study country and type	Intervention and comparator	Study population, design and data sources	Costs and outcomes (descriptions and values)	Results	Comments
<p>CEA</p> <p>Source of funding: None – although one of the authors is employed by Ziwig Health who make Endotest®</p>	<p>Strategy IV - Ultrasound to detect endometrioma with pelvic MRI if ultrasound negative and Endotest® if pelvic MRI negative</p> <p>Comparator in detail Strategy I – current French algorithm for diagnosis of endometriosis</p>	<p>based on data from literature</p> <p>Source of baseline data: Diagnostic test accuracy was estimated from the literature</p> <p>Source of effectiveness data: Diagnostic test accuracy was estimated from the literature</p> <p>Source of cost data: Diagnostic tests under evaluation and additional consultations consistent with French guidelines</p> <p>Source of unit cost data: Costs reimbursed by French healthcare system. A range of costs were used for Endotest® as the cost was not known</p>	<p>valued at €750</p> <p>Strategy I: €1,542</p> <p>Strategy II: €990</p> <p>Strategy III: €919</p> <p>Strategy IV: €1,000</p> <p>Primary measure of outcome: Diagnostic accuracy rate</p> <p>Mean outcome per participant:</p> <p>Strategy I: 0.71 (Undiagnosed 0.13)</p> <p>Strategy II: 0.96</p> <p>Strategy III: 0.97</p> <p>Strategy IV: 0.79</p>	<p>to €1,062)</p> <p>Strategy II relative to Strategy III: €4,715 (95% CI - €29,313 to €37,513)</p> <p>Probability of being cost effective: CEAC reported showing probability of being cost-effective according to willingness to pay for a correct diagnosis</p> <p>Sensitivity analysis: The analysis was repeated for Endotest® cost of €500 and €1,000</p>	<p>Discounting: N/A</p> <p>Applicability: Partially</p> <p>Limitations: Very serious</p> <p>Other comments: Costs were not reported per participant and therefore it was not clear how the reported ICERs were derived.</p> <p>Strategy III and Strategy IV are limited to detection of endometriomas and therefore it seems unlikely that they are comparable to Strategy I and Strategy II.</p> <p>Outcomes are not assessed in QALYs, and correct diagnoses of positives and</p>

Study country and type	Intervention and comparator	Study population, design and data sources	Costs and outcomes (descriptions and values)	Results	Comments
					<p>negatives are considered equally without justification.</p> <p>The cost of Endotest® is not known and therefore the analysis is hypothetical.</p> <p>Furthermore, without a decision maker cost-effectiveness threshold for correct diagnosis it was not possible to determine the cost-effective strategy in an NHS context</p>

1 CEA = cost-effectiveness analysis; CI = confidence interval; CUA = cost-utility analysis; GBP = British pound; NIHR = National Institute for Health Research; MRI = magnetic
 2 resonance imaging; PSSRU = Personal Social Services Research Unit; QALYs = quality adjusted life years

3
 4
 5

1 **Appendix I Economic model**

2 **Economic model for review question: What is the accuracy of the following**
3 **tests in diagnosing endometriosis:**

- 4 • **imaging**
- 5 • **biomarkers**
- 6 • **surgical diagnosis (open surgery or laparoscopic surgery)?**

7 No economic analysis was conducted for this review question.

1
2 **Appendix J Excluded studies**

3 **Excluded studies for review question: What is the accuracy of the following**
4 **tests in diagnosing endometriosis:**

- 5 • **imaging**
6 • **biomarkers**
7 • **surgical diagnosis (open surgery or laparoscopic surgery)?**

8 **Excluded diagnostic studies**

Study	Code [Reason]
<p>Acimovic, Milena, Vidakovic, Snezana, Milic, Natasa et al. (2016) Survivin and VEGF as Novel Biomarkers in Diagnosis of Endometriosis. Journal of medical biochemistry 35(1): 63-68</p>	<p>- Inappropriate reference standard <i>Reference standard (laparoscopy without histology) does not match the review protocol</i></p>
<p>Allegre, Lucie, Aristizabal, Patrick, Nyangoh Timoh, Krystel et al. (2018) Comparison of 3-Tesla to 1.5-Tesla Magnetic Resonance Enterography to assess multifocal and multicentric bowel endometriosis: Results in routine practice. European journal of obstetrics, gynecology, and reproductive biology 230: 172-177</p>	<p>- Inappropriate index test <i>MRE test is the index test. Participants had an MRI prior to the MRE</i></p>
<p>Asgari, Zahra, Farzadi, Sara, Hosseini, Reihaneh et al. (2022) Assessing The Role and Accuracy of Ultrasonographic Imaging in The Diagnosis of Deep Infiltrating Endometriosis: A Cross-Sectional Study. International journal of fertility & sterility 16(4): 263-267</p>	<p>- Inappropriate reference standard <i>Some participants did not receive the reference standard (27%) - they only received ultrasound and were excluded if findings on ultrasound were negative</i></p>
<p>Baggio, Silvia, Zecchin, Alessandro, Pomini, Paola et al. (2016) The Role of Computed Tomography Colonography in Detecting Bowel Involvement in Women With Deep Infiltrating Endometriosis: Comparison With Clinical History, Serum Ca125, and Transvaginal Sonography. Journal of computer assisted tomography 40(6): 886-891</p>	<p>- Data not reported in an extractable format or a format that can be analysed <i>No sufficient information to calculate 2x2 table.</i></p>
<p>Barra, Fabio, Biscaldi, Ennio, Scala, Carolina et al. (2020) A Prospective Study Comparing Three-Dimensional Rectal Water Contrast Transvaginal Ultrasonography and Computed Tomographic Colonography in the Diagnosis of Rectosigmoid Endometriosis. Diagnostics (Basel, Switzerland) 10(4)</p>	<p>- Inappropriate reference standard <i>Those without endometriosis on scan did not receive laparoscopy with histology.</i></p>
<p>Bartirromo, Ludovica, Schimberni, Matteo, Villanacci, Roberta et al. (2022) A Systematic</p>	<p>- Data not reported in an extractable format or a format that can be analysed</p>

Study	Code [Reason]
Review of Atypical Endometriosis-Associated Biomarkers . International journal of molecular sciences 23(8)	<i>Systematic review - included studies do not report diagnostic accuracy outcomes</i>
Bartlett, David J, Burkett, Brian J, Burnett, Tatnai L et al. (2020) Comparison of routine pelvic US and MR imaging in patients with pathologically confirmed endometriosis . Abdominal radiology (New York) 45(6): 1670-1679	<ul style="list-style-type: none"> - Data not reported in an extractable format or a format that can be analysed <i>No sufficient information to calculate 2x2 table.</i>
Bausic, Alexandra, Coroleuca, Ciprian, Coroleuca, Catalin et al. (2022) Transvaginal Ultrasound vs. Magnetic Resonance Imaging (MRI) Value in Endometriosis Diagnosis . Diagnostics (Basel, Switzerland) 12(7)	<ul style="list-style-type: none"> - Systematic review used as source of primary studies <i>Relevant primary studies have already been included in the review</i>
Bazot, M., Delaveau, M.-C., Darai, E. et al. (2021) Value of sonography in assessing parametrial endometriotic involvement: Preliminary results . Journal of Endometriosis and Pelvic Pain Disorders 13(1): 58-65	<ul style="list-style-type: none"> - Data not reported in an extractable format or a format that can be analysed <i>Data not reported by outcomes of interest in PICO</i>
Bazot, Marc and Darai, Emile (2017) Diagnosis of deep endometriosis: clinical examination, ultrasonography, magnetic resonance imaging, and other techniques . Fertility and sterility 108(6): 886-894	<ul style="list-style-type: none"> - Study design not relevant to this review protocol <i>Non-systematic review</i>
Bendifallah, Sofiane, Suisse, Stephane, Puchar, Anne et al. (2022) Salivary MicroRNA Signature for Diagnosis of Endometriosis . Journal of clinical medicine 11(3)	<ul style="list-style-type: none"> - Inappropriate reference standard <i>Not all participants received reference standard, some had MRI imaging which does not match the reference standard in the review protocol – proportion not specified</i>
Berger, Judith P, Rhemrev, Johann, Smeets, Maddy et al. (2019) Limited Added Value of Magnetic Resonance Imaging After Dynamic Transvaginal Ultrasound for Preoperative Staging of Endometriosis in Daily Practice: A Prospective Cohort Study . Journal of ultrasound in medicine : official journal of the American Institute of Ultrasound in Medicine 38(4): 989-996	<ul style="list-style-type: none"> - Inappropriate index test <i>Test is imaging along with history and examination - the index test in the protocol is imaging only</i>
Biscaldi, Ennio, Barra, Fabio, Scala, Carolina et al. (2020) Magnetic Resonance Rectal Enema Versus Computed Tomographic Colonography in the Diagnosis of Rectosigmoid Endometriosis . Journal of computer assisted tomography 44(4): 501-510	<ul style="list-style-type: none"> - Inappropriate reference standard <i>Not all participants underwent surgery with histology (51% did not) - only those with rectosigmoid nodules on imaging</i>
Brunelli, Ana Claudia, Brito, Luiz Gustavo	<ul style="list-style-type: none"> - Systematic review used as source of primary

Study	Code [Reason]
<p>Oliveira, Moro, Flavia Assad Salum et al. (2023) Ultrasound Elastography for the Diagnosis of Endometriosis and Adenomyosis: A Systematic Review with Meta-analysis. <i>Ultrasound in medicine & biology</i> 49(3): 699-709</p>	<p>studies <i>Included studies checked but none met protocol criteria</i></p>
<p>Bulut, Eser, Peker, Mustafa, Kupeli, Ali et al. (2021) The efficiency of susceptibility-weighted MRI in the differentiation of endometriomas from haemorrhagic ovarian cysts. <i>Abdominal radiology (New York)</i> 46(11): 5337-5343</p>	<p>- Population not relevant to this review protocol <i>Not suspected endometriosis</i></p>
<p>Carfagna, P, De Cicco Nardone, C, De Cicco Nardone, A et al. (2018) Role of transvaginal ultrasound in evaluation of ureteral involvement in deep infiltrating endometriosis. <i>Ultrasound in obstetrics & gynecology : the official journal of the International Society of Ultrasound in Obstetrics and Gynecology</i> 51(4): 550-555</p>	<p>- Data not reported in an extractable format or a format that can be analysed <i>Data not reported by outcomes of interest in PICO</i></p>
<p>Celentano, Valerio, Di Donato, Nadine, Buccomino, Giusy E et al. (2020) Prospective Evaluation of Outpatient Flexible Sigmoidoscopy in Patients With Deep Infiltrating Endometriosis. <i>Surgical laparoscopy, endoscopy & percutaneous techniques</i> 30(6): 508-510</p>	<p>- Data not reported in an extractable format or a format that can be analysed <i>Data not reported by outcomes of interest in PICO</i></p>
<p>Celli, Veronica, Ciulla, Sandra, Dolciemi, Miriam et al. (2021) Magnetic Resonance Imaging in endometriosis-associated pain. <i>Minerva obstetrics and gynecology</i> 73(5): 553-571</p>	<p>- Study design not relevant to this review protocol <i>Non-systematic review</i></p>
<p>Chen, Hong, Wang, Guoliang, Wang, Xuexue et al. (2022) Diagnostic value of susceptibility-weighted imaging for endometrioma: preliminary results from a retrospective analysis. <i>Acta radiologica (Stockholm, Sweden : 1987)</i> 63(7): 976-981</p>	<p>- Data not reported in an extractable format or a format that can be analysed <i>Data not reported by outcomes of interest in PICO</i></p>
<p>Chen, Lifeng, Wang, Xinyan, Shu, Jing et al. (2019) Diagnostic value of serum D-dimer, CA125, and neutrophil-to-lymphocyte ratio in differentiating ovarian cancer and endometriosis. <i>International journal of gynaecology and obstetrics: the official organ of the International Federation of Gynaecology and Obstetrics</i> 147(2): 212-218</p>	<p>- Population not relevant to this review protocol <i>Not women with suspected endometriosis - women with ovarian cancer</i></p>
<p>Chen, Ting, Wei, Jia-Ling, Leng, Ting et al. (2021) The diagnostic value of the combination of hemoglobin, CA199, CA125, and HE4 in endometriosis. <i>Journal of clinical laboratory analysis</i> 35(9): e23947</p>	<p>- Study design not relevant to this review protocol <i>Case-control</i></p>

Study	Code [Reason]
<p>Chen, Ying, Zhu, Hong-Lan, Tang, Zhe-Wen et al. (2017) Evaluation of Circulating Endometrial Cells as a Biomarker for Endometriosis. Chinese medical journal 130(19): 2339-2345</p>	<p>- Study design not relevant to this review protocol <i>Case-control</i></p>
<p>Cho, Hye-Yon and Kyung, Min Sun (2019) CYFRA 21-1 and Placental Growth Factor as Screening Markers for Endometriosis. Medical science monitor : international medical journal of experimental and clinical research 25: 1087-1092</p>	<p>- Population not relevant to this review protocol <i>Population not those with suspected endometriosis - population are those who have benign ovarian tumours diagnosed on ultrasonography</i></p>
<p>Chowdary, Prathima, Stone, Kate, Ma, Tony et al. (2019) Multicentre retrospective study to assess diagnostic accuracy of ultrasound for superficial endometriosis-Are we any closer?. The Australian & New Zealand journal of obstetrics & gynaecology 59(2): 279-284</p>	<p>- Inappropriate reference standard <i>Reference standard does not match review protocol</i></p>
<p>Collin, Megane, Barat, Maxime, Oudjit, Ammar et al. (2023) Comparison between CT-enterography and MR-enterography for the diagnosis of right-sided deep infiltrating endometriosis of the bowel. European journal of radiology 161: 110730</p>	<p>- Inappropriate reference standard <i>Not all participants received the reference standard as specified in the protocol (true negatives were not assessed histologically)</i></p>
<p>Cosma, Stefano, Salgarello, Matteo, Ceccaroni, Marcello et al. (2016) Accuracy of a new diagnostic tool in deep infiltrating endometriosis: Positron emission tomography-computed tomography with 16alpha-[18F]fluoro-17beta-estradiol. The journal of obstetrics and gynaecology research 42(12): 1724-1733</p>	<p>- Inappropriate index test <i>Study assesses diagnostic accuracy of PET/CT.</i></p>
<p>Daher, R M F, Rosa-E-Silva, J C, Poli-Neto, O B et al. (2016) Diagnosis of endometriosis in women with chronic pelvic pain. Clinical and experimental obstetrics & gynecology 43(4): 512-515</p>	<p>- Study design not relevant to this review protocol <i>Case-control</i></p>
<p>Deslandes, Alison, Parange, Nayana, Childs, Jessie T et al. (2020) Current Status of Transvaginal Ultrasound Accuracy in the Diagnosis of Deep Infiltrating Endometriosis Before Surgery: A Systematic Review of the Literature. Journal of ultrasound in medicine : official journal of the American Institute of Ultrasound in Medicine 39(8): 1477-1490</p>	<p>- Systematic review used as source of primary studies <i>Included studies checked and relevant studies have already been included in the review</i></p>
<p>Deslandes, Alison, Parange, Nayana, Childs, Jessie T et al. (2023) What is the accuracy of transvaginal ultrasound for endometriosis mapping prior to surgery when performed by a</p>	<p>- Inappropriate reference standard <i>Not all participants had the reference standard as specified in the protocol, proportions not specified</i></p>

Study	Code [Reason]
<p>sonographer within an outpatient women's imaging centre?. Journal of medical imaging and radiation oncology 67(3): 267-276</p>	
<p>Di Giovanni, Alessandra, Casarella, Lucia, Coppola, Marina et al. (2018) Combined Transvaginal/Transabdominal Pelvic Ultrasonography Accurately Predicts the 3 Dimensions of Deep Infiltrating Bowel Endometriosis Measured after Surgery: A Prospective Study in a Specialized Center. Journal of minimally invasive gynecology 25(7): 1231-1240</p>	<p>- Inappropriate reference standard</p> <p><i>Not all participants received the reference standard as specified in the protocol. 37% were excluded due to not visualising lesions during surgery, although endometriosis was suspected prior to surgery.</i></p>
<p>Ding, Ding, Chen, Yishan, Liu, Xishi et al. (2020) Diagnosing Deep Endometriosis Using Transvaginal Elastasonography. Reproductive sciences (Thousand Oaks, Calif.) 27(7): 1411-1422</p>	<p>- Data not reported in an extractable format or a format that can be analysed</p> <p><i>Data not reported by outcomes of interest in PICO</i></p>
<p>Florin, M., Vaussy, A., Macron, L. et al. (2021) Evaluation of Iterative Denoising 3-Dimensional T2-Weighted Turbo Spin Echo for the Diagnosis of Deep Infiltrating Endometriosis. Investigative radiology</p>	<p>- Inappropriate reference standard</p> <p><i>Reference standard does not match the review protocol</i></p>
<p>Gajbhiye, Rahul, Bendigeri, Trupti, Ghuge, Arun et al. (2017) Panel of Autoimmune Markers for Noninvasive Diagnosis of Minimal-Mild Endometriosis. Reproductive sciences (Thousand Oaks, Calif.) 24(3): 413-420</p>	<p>- Study design not relevant to this review protocol</p> <p><i>Case-control</i></p>
<p>Gerges, B, Li, W, Leonardi, M et al. (2021) Meta-analysis and systematic review to determine the optimal imaging modality for the detection of bladder deep endometriosis. European journal of obstetrics, gynecology, and reproductive biology 261: 124-133</p>	<p>- Systematic review used as source of primary studies</p> <p><i>Included studies checked and relevant studies have already been included in the review</i></p>
<p>Gerges, B, Li, W, Leonardi, M et al. (2021) Meta-analysis and systematic review to determine the optimal imaging modality for the detection of uterosacral ligaments/torus uterinus, rectovaginal septum and vaginal deep endometriosis. Human reproduction open 2021(4): hoab041</p>	<p>- Systematic review used as source of primary studies</p> <p><i>Included studies checked and relevant studies have been included in the review</i></p>
<p>Gerges, B, Li, W, Leonardi, M et al. (2021) Optimal imaging modality for detection of rectosigmoid deep endometriosis: systematic review and meta-analysis. Ultrasound in obstetrics & gynecology : the official journal of the International Society of Ultrasound in Obstetrics and Gynecology 58(2): 190-200</p>	<p>- Systematic review used as source of primary studies</p> <p><i>Included studies checked and relevant studies included in review</i></p>

Study	Code [Reason]
<p>Gordts, S, Puttemans, P, Segaert, I et al. (2023) Diagnosis and treatment of early-stage endometriosis by Transvaginal Hydro laparoscopy. Facts, views & vision in ObGyn 15(1): 45-52</p>	<p>- Data not reported in an extractable format or a format that can be analysed</p> <p><i>Study does not report primary or secondary outcomes as in the protocol</i></p>
<p>Gu, Cheng-Lei, Zhang, Zhe, Fan, Wen-Sheng et al. (2020) Identification of MicroRNAs as Potential Biomarkers in Ovarian Endometriosis. Reproductive sciences (Thousand Oaks, Calif.) 27(9): 1715-1723</p>	<p>- Data not reported in an extractable format or a format that can be analysed</p> <p><i>Outcomes not reported as per format specified in the protocol</i></p>
<p>Guerriero, S, Ajossa, S, Orozco, R et al. (2016) Accuracy of transvaginal ultrasound for diagnosis of deep endometriosis in the rectosigmoid: systematic review and meta-analysis. Ultrasound in obstetrics & gynecology : the official journal of the International Society of Ultrasound in Obstetrics and Gynecology 47(3): 281-9</p>	<p>- Systematic review used as source of primary studies</p> <p><i>Included studies checked but none meet protocol criteria</i></p>
<p>Guerriero, S, Ajossa, S, Pascual, M A et al. (2020) Ultrasonographic soft markers for detection of rectosigmoid deep endometriosis. Ultrasound in obstetrics & gynecology : the official journal of the International Society of Ultrasound in Obstetrics and Gynecology 55(2): 269-273</p>	<p>- Inappropriate reference standard</p> <p><i>Reference standard does not match the review protocol (ultrasound used for reference standard not laparoscopy with histology)</i></p>
<p>Guerriero, S, Martinez, L, Gomez, I et al. (2021) Diagnostic accuracy of transvaginal sonography for detecting parametrial involvement in women with deep endometriosis: systematic review and meta-analysis. Ultrasound in obstetrics & gynecology : the official journal of the International Society of Ultrasound in Obstetrics and Gynecology 58(5): 669-676</p>	<p>- Systematic review used as source of primary studies</p> <p><i>Included studies checked and relevant studies included in the review</i></p>
<p>Guerriero, S, Saba, L, Pascual, M A et al. (2018) Transvaginal ultrasound vs magnetic resonance imaging for diagnosing deep infiltrating endometriosis: systematic review and meta-analysis. Ultrasound in obstetrics & gynecology : the official journal of the International Society of Ultrasound in Obstetrics and Gynecology 51(5): 586-595</p>	<p>- Systematic review used as source of primary studies</p> <p><i>Included studies checked and none meet protocol criteria</i></p>
<p>Guerriero, Stefano, Alcazar, Juan Luis, Pascual, Maria Angela et al. (2018) Deep Infiltrating Endometriosis: Comparison Between 2-Dimensional Ultrasonography (US), 3-Dimensional US, and Magnetic Resonance Imaging. Journal of ultrasound in medicine : official journal of the American Institute of Ultrasound in Medicine 37(6): 1511-1521</p>	<p>- Inappropriate reference standard</p> <p><i>Reference standard (surgical visualisation without histology) does not match the review protocol</i></p>

Study	Code [Reason]
<p>Guo, Cuishan and Zhang, Chiyuan (2022) Platelet-to-Lymphocyte Ratio and CA125 Level as a Combined Biomarker for Diagnosing Endometriosis and Predicting Pelvic Adhesion Severity. <i>Frontiers in oncology</i> 12: 896152</p>	<p>- Study design not relevant to this review protocol <i>Case-control</i></p>
<p>Gupta, Devashana, Hull, M Louise, Fraser, Ian et al. (2016) Endometrial biomarkers for the non-invasive diagnosis of endometriosis. <i>The Cochrane database of systematic reviews</i> 4: cd012165</p>	<p>- Date <i>Included studies all pre-2016 date cut-off specified in the protocol</i></p>
<p>Harma, Kirsi, Binda, Aleksandra, Ith, Michael et al. (2020) Cloverleaf Sign in Pelvic Magnetic Resonance Imaging for Deep Infiltrating Endometriosis: Association With Longer Operation Times, Greater Blood Loss, and Higher Rates of Bowel Resection. <i>Investigative radiology</i> 55(1): 53-59</p>	<p>- Data not reported in an extractable format or a format that can be analysed <i>Data not reported by outcomes of interest in PICO</i></p>
<p>Herranz-Blanco, B., Daoud, E., Vigano, P. et al. (2023) Development and Validation of a novel in vitro diagnostic test for endometriosis. <i>medRxiv</i></p>	<p>- Study design not relevant to this review protocol <i>Case-control</i></p>
<p>Hirsch, M, Duffy, Jmn, Davis, C J et al. (2016) Diagnostic accuracy of cancer antigen 125 for endometriosis: a systematic review and meta-analysis. <i>BJOG : an international journal of obstetrics and gynaecology</i> 123(11): 1761-8</p>	<p>- Systematic review used as source of primary studies <i>Included studies and none meet protocol criteria</i></p>
<p>Hirsch, Martin, Duffy, James M N, Deguara, Christine S et al. (2017) Diagnostic accuracy of Cancer Antigen 125 (CA125) for endometriosis in symptomatic women: A multi-center study. <i>European journal of obstetrics, gynecology, and reproductive biology</i> 210: 102-107</p>	<p>- Inappropriate reference standard <i>Those with no macroscopic pathology did not go on to receive the reference standard which was histology.</i></p>
<p>Hudelist, Gernot, Montanari, Eliana, Salama, Mohamed et al. (2021) Comparison between Sonography-based and Surgical Extent of Deep Endometriosis Using the Enzian Classification - A Prospective Diagnostic Accuracy Study. <i>Journal of minimally invasive gynecology</i> 28(9): 1643-1649e1</p>	<p>- Inappropriate reference standard <i>Participants did not receive the reference standard described in the protocol (surgical visualisation with histological confirmation).</i></p>
<p>Indrielle-Kelly, T, Fruhauf, F, Fanta, M et al. (2020) Diagnostic Accuracy of Ultrasound and MRI in the Mapping of Deep Pelvic Endometriosis Using the International Deep Endometriosis Analysis (IDEA) Consensus. <i>BioMed research international</i> 2020: 3583989</p>	<p>- Inappropriate reference standard <i>Some participants only received visualisation on surgery, without histology, as reference standard, proportions not specified.</i></p>

Study	Code [Reason]
<p>Ito, Traci E, Abi Khalil, Elias D, Taffel, Myles et al. (2017) Magnetic resonance imaging correlation to intraoperative findings of deeply infiltrative endometriosis. Fertility and sterility 107(2): e11-e12</p>	<p>- Study design not relevant to this review protocol <i>Study used videos from their surgeries to highlight the appearance of endometriosis corresponding to MRI images</i></p>
<p>James, Theodore W, Fan, Y Claire, Schiff, Lauren D et al. (2019) Lower endoscopic ultrasound in preoperative evaluation of rectosigmoid endometriosis. Endoscopy international open 7(6): e837-e840</p>	<p>- Inappropriate reference standard <i>Not all participants receive the reference standard as specified in the protocol (11.3% did not).</i></p>
<p>Kante, F., Belghiti, J., Roseau, G. et al. (2017) Comparison of the accuracy of rectal endoscopic sonography and magnetic resonance imaging in the diagnosis of colorectal endometriosis. Gynecologie Obstetrique Fertilité et Senologie 45(3): 131-136</p>	<p>- Study not reported in English <i>Study in French</i></p>
<p>Kim, Arane, Fernandez, Pedro, Martin, Brigitte et al. (2017) Magnetic Resonance Imaging Compared with Rectal Endoscopic Sonography for the Prediction of Infiltration Depth in Colorectal Endometriosis. Journal of minimally invasive gynecology 24(7): 1218-1226</p>	<p>- Inappropriate reference standard <i>Reference standard (laparoscopy without histology) does not match the review protocol</i></p>
<p>Kim, Heeyon, Choi, Young Sik, Kim, Jeong Sook et al. (2020) Identification of Serum Biomarkers for Diagnosis of Endometriosis Using Multiplex Immunoassays. Reproductive sciences (Thousand Oaks, Calif.) 27(5): 1139-1147</p>	<p>- Population not relevant to this review protocol <i>Not all participants had suspected endometriosis - proportion not given. Some participants with pelvic masses.</i></p>
<p>Koninckx, Philippe R, Giovanni, Alessandra Di, Ussia, Anastasia et al. (2023) Predictive Value of Ultrasound Imaging for Diagnosis and Surgery of Deep Endometriosis: A Systematic Review. Journal of minimally invasive gynecology</p>	<p>- Systematic review used as source of primary studies <i>Included studies checked and relevant studies are included in the review</i></p>
<p>Kovalak, Evrim Ebru, Karacan, Tolga, Zengi, Oguzhan et al. (2023) Evaluation of new biomarkers in stage III and IV endometriosis. Gynecological endocrinology : the official journal of the International Society of Gynecological Endocrinology 39(1): 2217290</p>	<p>- Study design not relevant to this review protocol <i>Case-control</i></p>
<p>Laudanski, Piotr, Rogalska, Gabriela, Warzecha, Damian et al. (2023) Autoantibody screening of plasma and peritoneal fluid of patients with endometriosis. Human reproduction (Oxford, England) 38(4): 629-643</p>	<p>- Study design not relevant to this review protocol <i>Case control</i></p>

Study	Code [Reason]
<p>Leonardi, M, Robledo, K P, Espada, M et al. (2020) SonoPODography: A new diagnostic technique for visualizing superficial endometriosis. European journal of obstetrics, gynecology, and reproductive biology 254: 124-131</p>	<p>- Inappropriate reference standard</p> <p><i>Reference standard was laparoscopy only for some participants. Proportions not specified.</i></p>
<p>Leonardi, M, Uzuner, C, Mestdagh, W et al. (2022) Diagnostic accuracy of transvaginal ultrasound for detection of endometriosis using International Deep Endometriosis Analysis (IDEA) approach: prospective international pilot study. Ultrasound in obstetrics & gynecology : the official journal of the International Society of Ultrasound in Obstetrics and Gynecology 60(3): 404-413</p>	<p>- Inappropriate reference standard</p> <p><i>Reference standard laparoscopy only for some participants (only suspicious lesions on visualisation were sent for histology in 74% of participants). Proportions not specified.</i></p>
<p>Leonardi, Mathew, Espada, Mercedes, Choi, Sarah et al. (2020) Transvaginal Ultrasound Can Accurately Predict the American Society of Reproductive Medicine Stage of Endometriosis Assigned at Laparoscopy. Journal of minimally invasive gynecology 27(7): 1581-1587e1</p>	<p>- Inappropriate reference standard</p> <p><i>Not all participants received the reference standard as described in the protocol (some had surgical visualisation without histological confirmation). Proportions not specified.</i></p>
<p>Leone Roberti Maggiore, U, Biscaldi, E, Vellone, V G et al. (2017) Magnetic resonance enema vs rectal water-contrast transvaginal sonography in diagnosis of rectosigmoid endometriosis. Ultrasound in obstetrics & gynecology : the official journal of the International Society of Ultrasound in Obstetrics and Gynecology 49(4): 524-532</p>	<p>- Inappropriate reference standard</p> <p><i>Not all participants underwent histological assessment - only participants with positive scans had resections. Proportions not specified.</i></p>
<p>Li, Jingjie, Guan, Lihuan, Zhang, Huizhen et al. (2018) Endometrium metabolomic profiling reveals potential biomarkers for diagnosis of endometriosis at minimal-mild stages. Reproductive biology and endocrinology : RB&E 16(1): 42</p>	<p>- Study design not relevant to this review protocol</p> <p><i>Case-control</i></p>
<p>Li, Yanhui and Chen, Qionghua (2019) Circulating non-coding RNAs as non-invasive diagnostic markers of endometriosis: a comprehensive meta-analysis. Archives of gynecology and obstetrics 300(5): 1099-1112</p>	<p>- Systematic review used as source of primary studies</p> <p><i>Systematic review, included studies checked but non meet protocol criteria</i></p>
<p>Lier, Marit C I, Vlek, Stijn L, Ankersmit, Marjolein et al. (2020) Comparison of enhanced laparoscopic imaging techniques in endometriosis surgery: a diagnostic accuracy study. Surgical endoscopy 34(1): 96-104</p>	<p>- Inappropriate index tests</p> <p><i>Index tests do not match review protocol</i></p>
<p>Lima, Raquel, Abdalla-Ribeiro, Helizabet, Nicola, Ana Luisa et al. (2017) Endometriosis on the</p>	<p>- Inappropriate reference standard</p>

Study	Code [Reason]
<p>uterosacral ligament: a marker of ureteral involvement. Fertility and sterility 107(6): 1348-1354</p>	<p><i>Reference standard (laparoscopy only) does not match review protocol</i></p>
<p>Lin, Yenpo, Hsieh, Ching-Yi, Huang, Yen-Ling et al. (2021) Magnetic Resonance Spectroscopy for Risk Stratification of Sonographically Indeterminate Ovarian Neoplasms: Preliminary Study. Diagnostics (Basel, Switzerland) 11(10)</p>	<p>- Population not relevant to this review protocol <i>Population are those with suspected ovarian tumour. Endometriosis population less than 60%</i></p>
<p>Maged, Ahmed M, Deeb, Wesam S, El Amir, Azza et al. (2018) Diagnostic accuracy of serum miR-122 and miR-199a in women with endometriosis. International journal of gynaecology and obstetrics: the official organ of the International Federation of Gynaecology and Obstetrics 141(1): 14-19</p>	<p>- Inappropriate reference standard <i>Not all participants received the reference standard as described in the protocol (surgical visualisation with histological confirmation). Proportions not reported.</i></p>
<p>Maheux-Lacroix, Sarah, Belanger, Mathieu, Pinard, Lorence et al. (2020) Diagnostic Accuracy of Intraoperative Tools for Detecting Endometriosis: A Systematic Review and Meta-analysis. Journal of minimally invasive gynecology 27(2): 433-440e1</p>	<p>- Systematic review used as source of primary studies <i>Included studies checked but none met protocol criteria</i></p>
<p>Maillard, Charlotte, Cherif Alami, Zineb, Squifflet, Jean-Luc et al. (2021) Diagnosis and Treatment of Vulvo-Perineal Endometriosis: A Systematic Review. Frontiers in surgery 8: 637180</p>	<p>- Data not reported in an extractable format or a format that can be analysed <i>Systematic review with studies not looking at diagnostic accuracy outcomes</i></p>
<p>Maple, Shae, Chalmers, K Jane, Bezak, Eva et al. (2023) Ultrasound Characteristics and Scanning Techniques of Uterosacral Ligaments for the Diagnosis of Endometriosis: A Systematic Review. Journal of ultrasound in medicine : official journal of the American Institute of Ultrasound in Medicine 42(6): 1193-1209</p>	<p>- Systematic review used as source of primary studies <i>Included studies checked and relevant studies included</i></p>
<p>Misir, Sema, Hepokur, Ceylan, Oksasoglu, Bugra et al. (2021) Circulating serum miR-200c and miR-34a-5p as diagnostic biomarkers for endometriosis. Journal of gynecology obstetrics and human reproduction 50(4): 102092</p>	<p>- Study design not relevant to this review protocol <i>Case-control</i></p>
<p>Moura, Ana Paula Carvalhal, Ribeiro, Helizabet Salomao Abdalla Ayroza, Bernardo, Wanderley Marques et al. (2019) Accuracy of transvaginal sonography versus magnetic resonance imaging in the diagnosis of rectosigmoid endometriosis: Systematic review and meta-analysis. PloS one 14(4): e0214842</p>	<p>- Systematic review used as source of primary studies <i>Included studies checked and relevant studies included in the review</i></p>

Study	Code [Reason]
<p>Moustafa, Sarah, Burn, Martina, Mamillapalli, Ramanaiah et al. (2020) Accurate diagnosis of endometriosis using serum microRNAs. American journal of obstetrics and gynecology 223(4): 557e1-557e11</p>	<p>- Population not relevant to this review protocol <i>Population mixed for suspected benign gynaecological conditions - proportion with suspected endometriosis not reported</i></p>
<p>Ni, Jia, Han, Bingbing, Liang, Jiabin et al. (2019) Three-dimensional 3D ultrasound combined with power Doppler for the differential diagnosis of endometrial lesions among infertile women. International journal of gynaecology and obstetrics: the official organ of the International Federation of Gynaecology and Obstetrics 145(2): 212-218</p>	<p>- Population not relevant to this review protocol <i>Not all with suspected endometriosis. 78% had normal endometrium, and 22% had a mix of suspected endometriosis and other non-endometriosis lesions.</i></p>
<p>Nisenblat, Vicki, Bossuyt, Patrick M M, Farquhar, Cindy et al. (2016) Imaging modalities for the non-invasive diagnosis of endometriosis. The Cochrane database of systematic reviews 2: cd009591</p>	<p>- Date <i>Included studies all pre-2016 date cut-off specified in the protocol</i></p>
<p>Nisenblat, Vicki, Bossuyt, Patrick M M, Shaikh, Rabia et al. (2016) Blood biomarkers for the non-invasive diagnosis of endometriosis. The Cochrane database of systematic reviews: cd012179</p>	<p>- Date <i>Included studies all pre-2016 date cut-off specified in the protocol</i></p>
<p>Nisenblat, Vicki, Prentice, Lucy, Bossuyt, Patrick M M et al. (2016) Combination of the non-invasive tests for the diagnosis of endometriosis. The Cochrane database of systematic reviews 7: cd012281</p>	<p>- Date <i>Included studies all pre-2016 date cut-off specified in the protocol</i></p>
<p>Noventa, Marco, Scioscia, Marco, Schincariol, Michele et al. (2019) Imaging Modalities for Diagnosis of Deep Pelvic Endometriosis: Comparison between Trans-Vaginal Sonography, Rectal Endoscopy Sonography and Magnetic Resonance Imaging. A Head-to-Head Meta-Analysis. Diagnostics (Basel, Switzerland) 9(4)</p>	<p>- Systematic review used as source of primary studies <i>Included studies checked and relevant studies have been included in the review</i></p>
<p>Nyangoh Timoh, Krystal, Stewart, Zelda, Benjoar, Mikhael et al. (2018) Magnetic Resonance Enterography to Assess Multifocal and Multicentric Bowel Endometriosis. Journal of minimally invasive gynecology 25(4): 697-705</p>	<p>- Inappropriate index test <i>MRE test is the index test. Participants had an MRI prior to the MRE.</i></p>
<p>Papari, Elahe, Noruzinia, Mehrdad, Kashani, Ladan et al. (2020) Identification of candidate microRNA markers of endometriosis with the use of next-generation sequencing and quantitative real-time polymerase chain reaction. Fertility and</p>	<p>- Study design not relevant to this review protocol <i>Case-control</i></p>

Study	Code [Reason]
sterility 113(6): 1232-1241	
<p>Pateisky, Petra, Pils, Dietmar, Szabo, Ladislaus et al. (2018) hsa-miRNA-154-5p expression in plasma of endometriosis patients is a potential diagnostic marker for the disease. Reproductive biomedicine online 37(4): 449-466</p>	<p>- Data not reported in an extractable format or a format that can be analysed</p> <p><i>Data not reported by outcomes of interest in PICO</i></p>
<p>Pattanasri, Melinda; Ades, Alex; Nanayakkara, Pav (2020) Correlation between ultrasound findings and laparoscopy in prediction of deep infiltrating endometriosis (DIE). The Australian & New Zealand journal of obstetrics & gynaecology 60(6): 946-951</p>	<p>- Data not reported in an extractable format or a format that can be analysed</p> <p><i>Sensitivity or specificity, or PPV and NPV, not reported. Also not enough information to calculate 2x2 table.</i></p>
<p>Pereira, Ana Maria Gomes, Brizon, Valeria Silva Candido, Carvas Junior, Nelson et al. (2020) Can Enhanced Techniques Improve the Diagnostic Accuracy of Transvaginal Sonography and Magnetic Resonance Imaging for Rectosigmoid Endometriosis? A Systematic Review and Meta-analysis. Journal of obstetrics and gynaecology Canada : JOGC = Journal d'obstetrique et gynecologie du Canada : JOGC 42(4): 488-499e4</p>	<p>- Systematic review used as source of primary studies</p> <p><i>Included studies checked and relevant studies included in the review</i></p>
<p>Philip, C.-A. and Dubernard, G. (2018) Performances and place of sonography in the diagnostic of endometriosis: CNGOF-HAS Endometriosis Guidelines. Gynecologie Obstetrique Fertilité et Senologie 46(3): 185-199</p>	<p>- Study not reported in English</p> <p><i>Study in French</i></p>
<p>Philip, Charles-Andre, Prouvot, Catherine, Cortet, Marion et al. (2020) Diagnostic Performances of Tridimensional Rectosonography and Magnetic Resonance Imaging in Rectosigmoid Endometriosis: A Prospective Cohort Study on 101 Patients. Ultrasound in medicine & biology 46(2): 225-232</p>	<p>- Inappropriate reference standard</p> <p><i>Not all participants received the reference standard as specified in the protocol (surgical visualisation with histological confirmation). Proportions not specified.</i></p>
<p>Pin, Louis, Monseau-Thiburce, Anne-Coline, Ziade-Coularis, Caroline et al. (2019) Exploratory study of the interest of MR susceptibility-weighted imaging for the pre-operative assessment of pelvic endometriosis extent. European journal of radiology 118: 245-250</p>	<p>- Inappropriate reference standard</p> <p><i>Reference standard (laparoscopy only) does not match review protocol</i></p>
<p>Prodromidou, Anastasia, Machairas, Nikolaos, Paspala, Anna et al. (2020) Diagnosis, surgical treatment and postoperative outcomes of hepatic endometriosis: A systematic review. Annals of hepatology 19(1): 17-23</p>	<p>- Study design not relevant to this review protocol</p> <p><i>Systematic review - included studies are case reports or cases series</i></p>

Study	Code [Reason]
<p>Raafat, M., Talaat, S.H., Abdelghaffar, S.M. et al. (2021) Can diffusion and T2 star-weighted magnetic resonance imaging aid in the diagnosis of ectopic endometrium?. Egyptian Journal of Radiology and Nuclear Medicine 52(1): 137</p>	<p>- Inappropriate reference standard <i>Reference standard (laparoscopy only) does not match the review protocol</i></p>
<p>Rao, Tanushree; Condous, George; Reid, Shannon (2022) Ovarian Immobility at Transvaginal Ultrasound: An Important Sonographic Marker for Prediction of Need for Pelvic Sidewall Surgery in Women With Suspected Endometriosis. Journal of ultrasound in medicine : official journal of the American Institute of Ultrasound in Medicine 41(5): 1109-1113</p>	<p>- Population not relevant to this review protocol <i>Population includes women with endometriosis - proportion in total sample not given</i></p>
<p>Reid, Shannon, Espada, Mercedes, Lu, Chuan et al. (2018) To determine the optimal ultrasonographic screening method for rectal/rectosigmoid deep endometriosis: Ultrasound "sliding sign," transvaginal ultrasound direct visualization or both?. Acta obstetrica et gynecologica Scandinavica 97(11): 1287-1292</p>	<p>- Inappropriate reference standard <i>Not all women had histological assessment - some only had laparoscopy. 16% had histological assessment.</i></p>
<p>Rindos, Noah B and Mansuria, Suketu (2017) Diagnosis and Management of Abdominal Wall Endometriosis: A Systematic Review and Clinical Recommendations. Obstetrical & gynecological survey 72(2): 116-122</p>	<p>- Study design not relevant to this review protocol <i>Non-systematic review</i></p>
<p>Robinson, A.J., Rombauts, L., Ades, A. et al. (2018) Poor sensitivity of transvaginal ultrasound markers in diagnosis of superficial endometriosis of the uterosacral ligaments. Journal of Endometriosis and Pelvic Pain Disorders 10(1): 10-17</p>	<p>- Inappropriate reference standard <i>Not all participants received the reference standard as specified in the protocol, 16% did not.</i></p>
<p>Ros, Cristina, Martinez-Serrano, Maria Jose, Rius, Mariona et al. (2017) Bowel Preparation Improves the Accuracy of Transvaginal Ultrasound in the Diagnosis of Rectosigmoid Deep Infiltrating Endometriosis: A Prospective Study. Journal of minimally invasive gynecology 24(7): 1145-1151</p>	<p>- Inappropriate reference standard <i>Not all participants received the reference standard as only visible lesions were removed for histology. Proportions not reported.</i></p>
<p>Rousset, Pascal, Bischoff, Elodie, Charlot, Mathilde et al. (2021) Bladder endometriosis: Preoperative MRI analysis with assessment of extension to ureteral orifices. Diagnostic and interventional imaging 102(4): 255-263</p>	<p>- Data not reported in an extractable format or a format that can be analysed <i>No sufficient information to calculate 2x2 table</i></p>
<p>Sadiqhi, N., Moradi, B., Gity, M. et al. (2022)</p>	<p>- Inappropriate reference standard</p>

Study	Code [Reason]
<p>Diagnostic Accuracy of Transvaginal Sonography for Deeply Infiltrating Endometriosis and Pouch of Douglas Obliteration in the Presence or Absence of Ovarian Endometrioma. Iranian Journal of Radiology 19(4): e127068</p>	<p><i>Reference standard (laparoscopy without histology) does not match protocol</i></p>
<p>Sandre, Amelie, Philip, Charles-Andre, De-Saint-Hilaire, Pierre et al. (2019) Comparison of three-dimensional rectosonography, rectal endoscopic sonography and magnetic resonance imaging performances in the diagnosis of rectosigmoid endometriosis. European journal of obstetrics, gynecology, and reproductive biology 240: 288-292</p>	<p>- Inappropriate reference standard</p> <p><i>Not all participants received the reference standard as specified in the protocol (surgical visualisation with histological confirmation)</i></p>
<p>Sasamoto, Naoko, DePari, Mary, Vitonis, Allison F et al. (2020) Evaluation of CA125 in relation to pain symptoms among adolescents and young adult women with and without surgically-confirmed endometriosis. PloS one 15(8): e0238043</p>	<p>- Study design not relevant to this review protocol</p> <p><i>Case-control</i></p>
<p>Sloss, Samantha, Mooney, Samantha, Ellett, Lenore et al. (2022) Preoperative Imaging in Patients with Deep Infiltrating Endometriosis: An Important Aid in Predicting Depth of Infiltration in Rectosigmoid Disease. Journal of minimally invasive gynecology 29(5): 633-640</p>	<p>- Inappropriate reference standard</p> <p><i>Not all participants underwent surgery with histology.</i></p>
<p>Stoppa, Margaux, Agostini, Aubert, Pivano, Audrey et al. (2023) Mild endometriosis of the uterosacral ligaments: a retrospective study of magnetic resonance imaging performance for diagnosis. Reproductive biomedicine online 46(6): 947-955</p>	<p>- Inappropriate reference standard</p> <p><i>Study reports only some women having ablation of tissue for histology, therefore not all the participants received the reference standard of surgery with histology. Proportions not reported.</i></p>
<p>Tadros, M.Y. and Keriakos, N.N. (2016) Diffusion MRI versus ultrasound in superficial and deep endometriosis. Egyptian Journal of Radiology and Nuclear Medicine 47(4): 1765-1771</p>	<p>- Inappropriate reference standard</p> <p><i>Reference standard is laparoscopy- no histology.</i></p>
<p>Tanmahasamut, P.; Preukthanathorn, R.; Dangrat, C. (2018) Serum interleukin 6 and cancer antigen 125 in the non-invasive diagnosis of endometriosis. Journal of Endometriosis and Pelvic Pain Disorders 10(2): 116-122</p>	<p>- Study design not relevant to this review protocol</p> <p><i>Case-control</i></p>
<p>Tian, Zhao, Zhang, Yi-Chao, Sun, Xian-Hua et al. (2022) Accuracy of transvaginal ultrasound and magnetic resonance imaging for diagnosis of deep endometriosis in bladder and ureter: a meta-analysis. Journal of obstetrics and gynaecology : the journal of the Institute of</p>	<p>- Systematic review used as source of primary studies</p> <p><i>Included studies checked and relevant studies included in review</i></p>

Study	Code [Reason]
Obstetrics and Gynaecology 42(6): 2272-2281	
Tokmak, Aytekin, Yildirim, Gulcin, Oztas, Efser et al. (2016) Use of Neutrophil-to-Lymphocyte Ratio Combined With CA-125 to Distinguish Endometriomas From Other Benign Ovarian Cysts. Reproductive sciences (Thousand Oaks, Calif.) 23(6): 795-802	- Study design not relevant to this review protocol <i>Case-control study</i>
Vanhie, A, O, D, Peterse, D et al. (2019) Plasma miRNAs as biomarkers for endometriosis. Human reproduction (Oxford, England) 34(9): 1650-1660	- Study design not relevant to this review protocol <i>Case-control</i>
Venkatesh, Spoorthy, Anjali, M, Vasudeva, Akhila et al. (2020) Sliding Sign and Gel Sonovaginography: A Sneak Peek Prior to Laparoscopy in Patients with Endometriosis. Journal of human reproductive sciences 13(1): 26-30	- Inappropriate reference standard <i>Reference standard (laparoscopy without histology) does not match the review protocol</i>
Vitagliano, A., Andrisani, A., Dessole, F. et al. (2019) Rectovaginal endometriosis: Head to head comparison between sonovaginography and magnetic resonance imaging. Clinical and Experimental Obstetrics and Gynecology 46(6): 888-891	- Inappropriate reference standard <i>Only those with positive scans underwent surgery, therefore not all participants received surgery and histology reference standard,</i>
Vlek, Stijn L, Lier, M C I, Ankersmit, M et al. (2016) Laparoscopic Imaging Techniques in Endometriosis Therapy: A Systematic Review. Journal of minimally invasive gynecology 23(6): 886-92	- Date <i>systematic review - included studies checked but all are pre-2016 date cut off stated in the review protocol</i>
Wang, Fang, Wang, Hongxia, Jin, Danting et al. (2018) Serum miR-17, IL-4, and IL-6 levels for diagnosis of endometriosis. Medicine 97(24): e10853	- Study design not relevant to this review protocol <i>Case-control</i>
Wessels, Jocelyn M, Kay, Vanessa R, Leyland, Nicholas A et al. (2016) Assessing brain-derived neurotrophic factor as a novel clinical marker of endometriosis. Fertility and sterility 105(1): 119-5	- Study design not relevant to this review protocol <i>Case-control</i>
Xiang, Yuanhua, Wang, Gang, Zhou, Lingjuan et al. (2022) A systematic review and meta-analysis on transvaginal ultrasonography in the diagnosis of deep invasive endometriosis. Annals of palliative medicine 11(1): 281-290	- Systematic review used as source of primary studies <i>Included studies checked but none meet protocol criteria</i>
Xu, Yifan, Yao, Yuan, Pylypenko, Dmytro et al. (2023) Diagnosis of pelvic endometriosis: a	- Inappropriate reference standard <i>Not all participants received reference standard,</i>

Study	Code [Reason]
preliminary study on the added value of R2*MFGRE sequence in magnetic resonance imaging. Acta radiologica (Stockholm, Sweden : 1987) 64(3): 1255-1262	<i>some received surgery only without histology</i>
Yadav, Garima, Rao, Meenakshi, Gothwal, Meenakshi et al. (2021) Detection of nerve fibers in the eutopic endometrium of women with endometriosis, uterine fibroids and adenomyosis. Obstetrics & gynecology science 64(5): 454-461	<p>- Population not relevant to this review protocol</p> <p><i>Only approximately 30% of population had suspected endometriosis. Results for the target population could not be extracted separately.</i></p>
Yin, Shaoli, Lin, Qi, Xu, Fanhua et al. (2020) Diagnosis of Deep Infiltrating Endometriosis Using Transvaginal Ultrasonography. Frontiers in medicine 7: 567929	<p>- Inappropriate reference standard</p> <p><i>Unclear whether all participants had the reference standard surgery with histology.</i></p>
Young, Scott W, Dahiya, Nirvikar, Patel, Maitray D et al. (2017) Initial Accuracy of and Learning Curve for Transvaginal Ultrasound with Bowel Preparation for Deep Endometriosis in a US Tertiary Care Center. Journal of minimally invasive gynecology 24(7): 1170-1176	<p>- Inappropriate reference standard</p> <p><i>Not all participants received the reference standard specified in the protocol. Proportions not specified.</i></p>
Zafari, Narges, Bahramy, Afshin, Majidi Zolbin, Masoumeh et al. (2022) microRNAs as novel diagnostic biomarkers in endometriosis patients: a systematic review and meta-analysis. Expert review of molecular diagnostics 22(4): 479-495	<p>- Systematic review used as source of primary studies</p> <p><i>Included studies checked but none meet criteria specified in the protocol</i></p>
Zhang, Xiao; He, Tao; Shen, Wen (2020) Comparison of physical examination, ultrasound techniques and magnetic resonance imaging for the diagnosis of deep infiltrating endometriosis: A systematic review and meta-analysis of diagnostic accuracy studies. Experimental and therapeutic medicine 20(4): 3208-3220	<p>- Systematic review used as source of primary studies</p> <p><i>Included studies checked and relevant studies included in the review</i></p>
Zheng, Tingting and Yang, Jing (2017) Differential expression of EWI-2 in endometriosis, its functional role and underlying molecular mechanisms. The journal of obstetrics and gynaecology research 43(7): 1180-1188	<p>- Inappropriate index test</p> <p><i>Index test (EWI-2 mRNA) does not match those specified in the review protocol</i></p>
Zhou, Ling, Chen, Yan, Gao, Jianhua et al. (2020) Diagnostic Value of Circulating MicroRNAs for Endometriosis: a Meta-analysis. Reproductive sciences (Thousand Oaks, Calif.) 27(3): 793-805	<p>- Systematic review used as source of primary studies</p> <p><i>Included studies checked and none meet protocol criteria</i></p>
Zhou, Yuli, Su, Youhuan, Liu, Huiyu et al. (2021) Accuracy of transvaginal ultrasound for diagnosis of deep infiltrating endometriosis in the	<p>- Systematic review used as source of primary studies</p> <p><i>Included studies checked and relevant studies</i></p>

Study	Code [Reason]
uterosacral ligaments: Systematic review and meta-analysis . Journal of gynecology obstetrics and human reproduction 50(3): 101953	<i>included in review</i>
Zhu, H, Lei, H, Wang, Q et al. (2016) Serum carcinogenic antigen (CA)-125 and CA 19-9 combining pain score in the diagnosis of pelvic endometriosis in infertile women . Clinical and experimental obstetrics & gynecology 43(6): 826-829	- Inappropriate reference standard <i>Reference standard not specified in the protocol</i>

1

2 Excluded economic studies

Study	Code [Reason]
Ferrier, C., Bendifallah, S., Suisse, S. et al. (2022) Saliva miRNA signature to diagnose endometriosis: a cost-effectiveness evaluation of the Endotest . BJOG : an international journal of obstetrics and gynaecology	- Duplicate
Leonardi, M, Martin, E, Reid, S et al. (2019) Deep endometriosis transvaginal ultrasound in the workup of patients with signs and symptoms of endometriosis: a cost analysis . BJOG : an international journal of obstetrics and gynaecology 126(12): 1499-1506	- Cost analysis only

3

1 **Appendix K Research recommendations – full details**

2 **Research recommendations for review question: What is the accuracy of the**
3 **following tests in diagnosing endometriosis:**

- 4 • **imaging**
- 5 • **biomarkers**
- 6 • **surgical diagnosis (open surgery or laparoscopic surgery)?**

7

8 No research recommendations were made for this review question.